

Rescue of pulmonary artery intra-stent re-stenosis by unzipping an under-sized stent in an adult patient with fibrosing mediastinitis

Yi-Chao Duan¹, Hong-Ling Su², Yan Zhu², Xin Pan³, Kai-Yu Jiang², A-Qian Wang², Guan-Ming Qi⁴, Yan Zhang⁵, Yun-Shan Cao²

¹Department of Cardiology, Xianyang Central Hospital, Xianyang, Shaanxi 712000, China;

²Department of Cardiology, Gansu Provincial Hospital, Lanzhou, Gansu 730000, China;

³Department of Cardiology, Shanghai Chest Hospital, Shanghai Jiao Tong University, Shanghai 200000, China;

⁴Critical Care and Sleep Division, Tufts Medical Center, Boston, MA 02111, USA;

⁵Tianjin Key Laboratory of Retinal Functions and Diseases, Tianjin International Joint Research and Development Centre of Ophthalmology and Vision Science, Eye Institute and School of Optometry, Tianjin Medical University Eye Hospital, Tianjin 300384, China.

To the Editor: A 71-year-old male was admitted to the hospital for progressive exertional dyspnea. He had a history of fibrosing mediastinitis (FM)-induced pulmonary vascular stenosis. His right interlobar pulmonary artery had been severely stenosed and implanted with a 6-mm diameter stent (6 mm × 18 mm; PALMAZ®BLUE™, Cordis, Shanghai, China) 6 months before admission, and his left superior pulmonary vein had been implanted with a 9-mm diameter stent (9 mm × 29 mm; Express™ Vascular LD, Boston Scientific, Marlborough, MA, USA) 1 month before admission.

After admission, the patient complained of aggravated dyspnea. Physical examinations detected accentuation of the second heart sound at the pulmonary valve auscultation area and right axis deviation. Laboratory tests showed that D-dimer was 0.4 µg/mL, and N-terminal pro B-type natriuretic peptide was 146 pg/mL. Arterial blood gas showed 89.3% of blood oxygen saturation, indicating type I respiratory failure.

The patient was evaluated as World Health Organization (WHO) functional class III. Computed tomographic pulmonary angiography (CTPA) and selective pulmonary artery/vein angiography revealed intra-stent re-stenosis in the right interlobar pulmonary artery [Figure 1A and 1B]. We consulted with the radiologists in our hospital and analyzed the CTPAs performed before and after the 6-mm diameter stent implantation and then determined that the patient's interlobar pulmonary artery was 10 mm in diameter, and the previously implanted 6-mm diameter stent was under-sized. Subsequently, the 6-mm diameter

stent was unzipped using 5 × 30 mm (Sterling™, Boston Scientific), 7 × 30 mm (Sterling™, Boston Scientific), and 8 × 30 mm (MUSTANG™, Boston Scientific) balloons (10–14 atmosphere [atm]) [Figure 1C and 1D]. Pulmonary artery angiography (PAG) showed that the 6-mm diameter stent was completely unzipped [Figure 1E]. Then, a 10 × 25 mm stent (Express™ Vascular LD, Boston Scientific) (18 atm) was implanted into the unzipped 6-mm diameter stent [Figure 1F and 1G]. Additional PAG showed that the 10-mm diameter stent was well expanded and that no complications occurred [Figure 1H and 1I].

After implantation of the 10-mm diameter stent, the patient's symptoms improved significantly. At 1-year follow-up post-procedure, the patient's functionality improved to WHO functional class I. Six-minute walking distance increased from 272 m upon admission to 365 m at follow-up; mean pulmonary artery pressure, as measured by right heart catheterization, decreased from 41 to 20 mmHg, and tricuspid annular plane systolic excursion increased from 15 to 19 mm during the same time period; CTPA indicated no intra-stent re-stenosis.

FM is a rare fibro-inflammatory disease in the mediastinum.^[1] In North America, *Histoplasma capsulatum* infection is the main cause, whereas tuberculosis infection may be the most prevalent etiology in China.^[1] FM often causes symptoms through compressing mediastinal structures. Drug therapy is meant to relieve symptoms but is limited in efficacy.^[1] Moreover, the FM-induced mediastinal infiltration of fibrous tissue forms abnormal anatomy, hereby substantially increases the risk of death in surgical treatments.^[2] In recent years, percutaneous pulmonary vascular stent implantation has become a new therapeutic

Access this article online

Quick Response Code:



Website:

www.cmj.org

DOI:

10.1097/CM9.0000000000001493

Correspondence to: Dr. Yun-Shan Cao, Department of Cardiology, Gansu Provincial Hospital, Lanzhou, Gansu 730000, China
E-Mail: yunshancao@126.com

Copyright © 2021 The Chinese Medical Association, produced by Wolters Kluwer, Inc. under the CC-BY-NC-ND license. This is an open access article distributed under the terms of the Creative Commons Attribution-Non Commercial-No Derivatives License 4.0 (CCBY-NC-ND), where it is permissible to download and share the work provided it is properly cited. The work cannot be changed in any way or used commercially without permission from the journal.

Chinese Medical Journal 2021;134(15)

Received: 20-03-2020 Edited by: Pei-Fang Wei

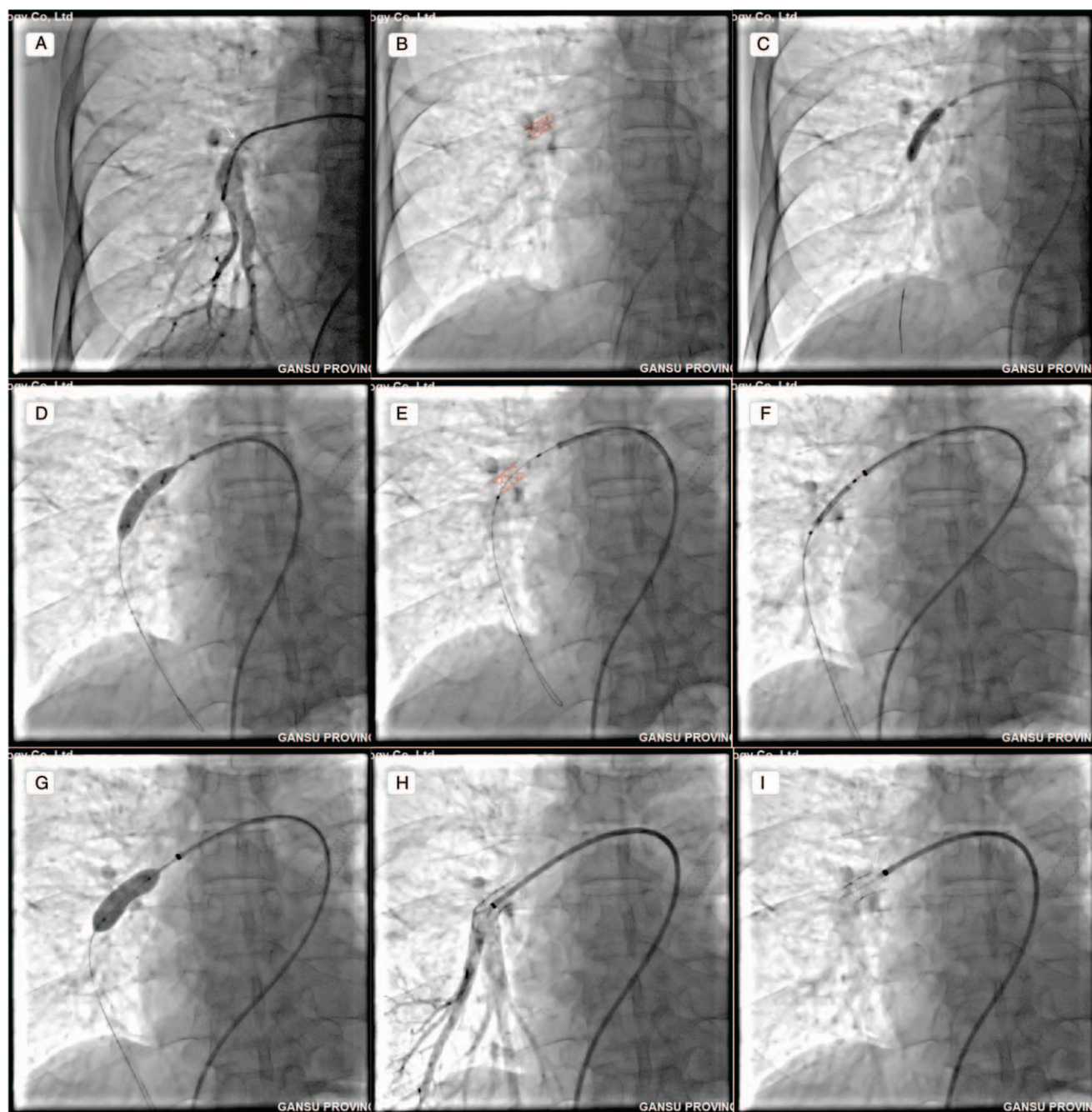


Figure 1: PAG and percutaneous transluminal pulmonary angioplasty. (A) Intra-stent re-stenosis in right interlobar pulmonary artery (white arrow). (B) Outline of the 6 mm-diameter stent (red dashed line). (C, D) Unzipping the 6 mm-diameter stent using 5 to 8 mm-diameter balloons. (E) The unzipped stent (red dashed line). (F, G) A 10 mm-diameter stent was implanted. (H, I) The implanted 10 mm-diameter stent was well expanded (white arrow). PAG: Pulmonary artery angiography.

modality for FM-induced vascular stenosis.^[3] However, implanting a stent appropriate to the diameter of the target vessel is of importance, since an under-sized stent may lead to intra-stent re-stenosis. Unzipping a small-diameter stent has been reported in congenital pulmonary artery stenosis to accommodate body growth in children.^[4,5] However, it is not known whether unzipping an under-sized stent in adults under the pathological context of FM-induced pulmonary artery stenosis would be feasible or not, because it is challenging to expand the stenotic pulmonary artery surrounded by fibrous structures. Herein, we report the unzipping of an under-sized stent followed by implantation

of another with appropriate size in a senile patient with FM-induced pulmonary artery stenosis, suggesting that unzipping an under-sized stent and implanting a proper-sized one may be safe and feasible to adult patients with FM-induced pulmonary artery stenosis.

Funding

This work was supported by a grant from the National Natural Science Foundation of China (Nos. 81770300, 81860059, 81460072, 82070052), Chinese Academy of Sciences “Light of West China” Program, International

Joint Research Program of Gansu Province (No. 18YF1WA046), Innovation and Entrepreneurship Program of Lanzhou City (No. 2018-RC-78), and the Science Foundation of Gansu Provincial Hospital (No. 18GSSY5-4).

Conflicts of interest

None.

References

1. Cao YS, Duan YC, Su HL. Advances in diagnosis and therapy of pulmonary vascular stenosis induced by fibrosing mediastinitis [in Chinese]. *Chin J Cardiol* 2020;48:823–830. doi: 10.3760/cma.j.cn112148-20200214-00081.
2. Mathisen DJ, Grillo HC. Clinical manifestation of mediastinal fibrosis and histoplasmosis. *Ann Thorac Surg* 1992;54:1053–1057. doi: 10.1016/0003-4975(92)90069-g.
3. Albers EL, Pugh ME, Hill KD, Wang L, Loyd JE, Doyle TP. Percutaneous vascular stent implantation as treatment for central vascular obstruction due to fibrosing mediastinitis. *Circulation* 2011;123:1391–1399. doi: 10.1161/CIRCULATIONAHA.110.949180.
4. Sathanandam SK, Kumar TK, Hoskoppal D, Haddad LM, Subramanian S, Sullivan RD, *et al*. Feasibility and safety of unzipping small diameter stents in the blood vessels of piglets. *JACC Cardiovasc Interv* 2016;9:1138–1149. doi: 10.1016/j.jcin.2016.02.035.
5. Morray BH, McElhinney DB, Marshall AC, Porras D. Intentional fracture of maximally dilated balloon-expandable pulmonary artery stents using ultra-high-pressure balloon angioplasty: a preliminary analysis. *Circ Cardiovasc Interv* 2016;9:e003281. doi: 10.1161/CIRCINTERVENTIONS.115.003281.

How to cite this article: Duan YC, Su HL, Zhu Y, Pan X, Jiang KY, Wang AQ, Qi GM, Zhang Y, Cao YS. Rescue of pulmonary artery intra-stent restenosis by unzipping an under-sized stent in an adult patient with fibrosing mediastinitis. *Chin Med J* 2021;134:1880–1882. doi: 10.1097/CM9.0000000000001493