

# MR Imaging of the Brain in Fukuyama-Type Congenital Muscular Dystrophy

Mieko Yoshioka,<sup>1</sup> Shigeo Saiwai,<sup>2</sup> Shigekazu Kuroki,<sup>1</sup> and Hiroyuki Nigami<sup>1</sup>

Cerebral malformations in conjunction with congenital muscular dystrophy are unusual. Three such combinations have been described, including Walker-Warburg syndrome [1, 2]; muscle, eye, and brain disease [3]; and Fukuyama-type congenital muscular dystrophy (FCMD) [4]. FCMD occurs with particularly high frequency in Japan, where it is the second most prevalent form of progressive muscular dystrophy. FCMD comprises a particular clinicopathologic syndrome. Clinical signs include mental retardation, progressive muscle weakness, joint contractures, and seizures in 50% of cases. Pachygyria and polymicrogyria are the most consistent neuropathologic findings [5]. CT findings are low-density areas involving the cerebral white matter in almost half of all cases [6]. Delay in myelination has been suspected as the pathogenesis of these low-density white matter areas [7]. Pathologic studies have been inconclusive as to the presence of degenerative cerebral lesions. We present here the MR imaging findings for three typical cases of FCMD.

## Case Reports

### Case 1

This girl was born at 39 weeks gestation by vaginal delivery without complications after an uneventful pregnancy. Birth weight was 2782 g. The patient had one older sister (case 2), who also suffered from FCMD. Her serum creatine kinase (CK) activity was 11,500 IU/l 5 days after delivery (normal range is <130 IU/l). The patient did well until 5 months of age, when she displayed hypotonia and flexion contractures of both knees. Psychomotor development was delayed with head control at age 6 months. She also could not roll over, sit alone, or speak any words at 18 months. Hyporeflexia and pseudohypertrophy of the calves were evident. After 1 year of age, convulsions developed during febrile illnesses, however EEG revealed no paroxysmal discharges.

MR was performed on a 1.5-T imaging system (Siemens, Erlangen, Germany). T1-weighted inversion-recovery images and T2-weighted spin-echo images were obtained. The first series of MR images was made at the age of 11 months (Figs. 1A and 1B); the second series at the age of 18 months (Figs. 1C and 1D). On inversion-recovery images at the age of 11 months (Fig. 1A), myelination was present in

the internal capsule, corpus callosum, occipital, and paracentral regions. But the temporoparietal and frontal white matter demonstrated an absence of myelination and showed symmetric low intensity. At the age of 18 months (Fig. 1C), progression of myelination was shown, but the frontal white matter attained less myelination. This was a grossly immature pattern for 18 months of age. On T2-weighted images (Figs. 1B and 1D), unmyelinated white matter demonstrated extensive high intensity. Pachygyria was also present.

### Case 2

This girl was born 2 years and 10 months prior to her sibling, who was case 1. Because the infant showed hyper CK-emia during the neonatal period, a muscle biopsy was done at 39 days. Marked fibrosis and extensive scattered degenerated fibers were seen and the patient was diagnosed as having FCMD. At 4 years of age she still demonstrated persistent head lag and was unable to roll over or sit alone.

The first series of MR images was made at the age of 9 months; the second series at the age of 42 months. Myelination progressed, but a small portion of the frontal white matter demonstrated an absence of myelination. Pachygyria was also present.

### Case 3

This boy was the second child of healthy unrelated parents. He was delivered at term after a normal pregnancy with a birth weight of 2500 g. Because he was unable to roll over at the age of 5 months, he was referred to our institution. Physical examination revealed generalized muscular hypotonia and decreased deep tendon reflexes. Contractures of the hip and knee joints were present. Serum CK levels were elevated, and a muscle biopsy revealed striking pathologic changes consistent with a dystrophic process. Developmentally, the patient obtained head control at 3 months, sat alone at 18 months, and rolled over at 34 months.

The first series of MR images was made at the age of 8 months (Figs. 2A and 2B); the second series at the age of 18 months (Figs. 2C and 2D). On inversion-recovery images at the age of 8 months (Fig. 2A), myelination was present except for the frontal white matter. At the age of 18 months (Fig. 2C), progression of myelination was shown but a small portion of the frontal white matter showed symmetric low intensity, which revealed an immature pattern for 18

Received April 8, 1990; revision requested May 14, 1990; revision received July 17, 1990; accepted July 19, 1990.

This work was supported by grant no. 62-3 from the National Center of Neurology and Psychiatry (NCNP) of the Ministry of Health and Welfare, Japan.

<sup>1</sup> Department of Pediatrics, Kobe General Hospital, 4-6 Minatojima-Nakamachi, Chuo-ku, Kobe 650, Japan. Address reprint requests to M. Yoshioka.

<sup>2</sup> Department of Radiology, Kobe General Hospital, Kobe 650, Japan.

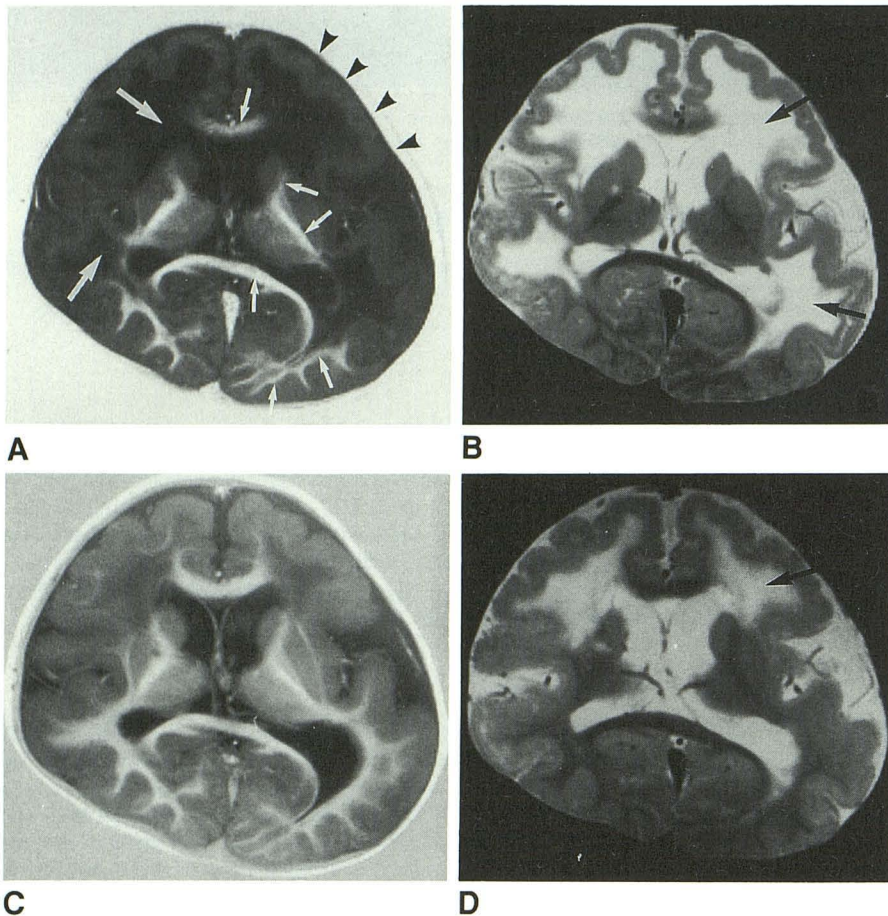


Fig. 1.—Case 1.

A–D, MR images at age 11 months (A and B) and at age 18 months (C and D). A and C are inversion recovery sequences (3000/400/22/1); B and D are T2-weighted spin-echo sequences (3000/90/1). In A, myelination is present in the internal capsule, corpus callosum, and occipital region (*small arrows*). The temporoparietal and frontal white matter show an absence of myelination and symmetric low intensity (*large arrows*). Pachygyria is also apparent (*arrowheads*). In C, progression of myelination from posterior to anterior is shown, but the frontal white matter remains less myelinated. This is a grossly immature pattern for 18 months of age. In B and D, unmyelinated white matter demonstrates high intensity (*arrows*).

months of age. On T2-weighted images (Figs. 2B and 2D), unmyelinated white matter showed high intensity. Pachygyria was less present in this case than in cases 1 and 2.

### Discussion

Myelination is a dynamic process beginning during intra-uterine life and continuing after birth and can thus be used as an index of brain maturation [8]. This is particularly true in the first 2 years of life, when changes are occurring most rapidly. MR is well suited for assessing myelination of the brain because it surpasses both CT and sonography in sensitivity to contrast differentials [9, 10]. In particular, the high degree of gray-white contrast provides a basis for visualizing normal myelination, as well as delays or deficits in this process.

Our previous CT studies of FCMD showed that the low-density areas in the cerebral white matter were most apparent around the age of 1 year and that they decreased or disappeared by 2 to 3 years of age [7, 11]. Delayed myelination was suspected as the pathogenesis of the low-density areas. Previous autopsy studies of FCMD have shown that the white matter change was not striking [5, 12]. A mild gliosis or edema of the cerebral white matter or myelin pallor in the centrum semiovale was sometimes reported; however, most cases showed no remarkable abnormalities in the cerebral white matter. In most cases, the age at autopsy was greater

than 5 years. In contrast to these findings, hypomyelination of the cerebrum was noted in one case autopsied at the age of 11 months.

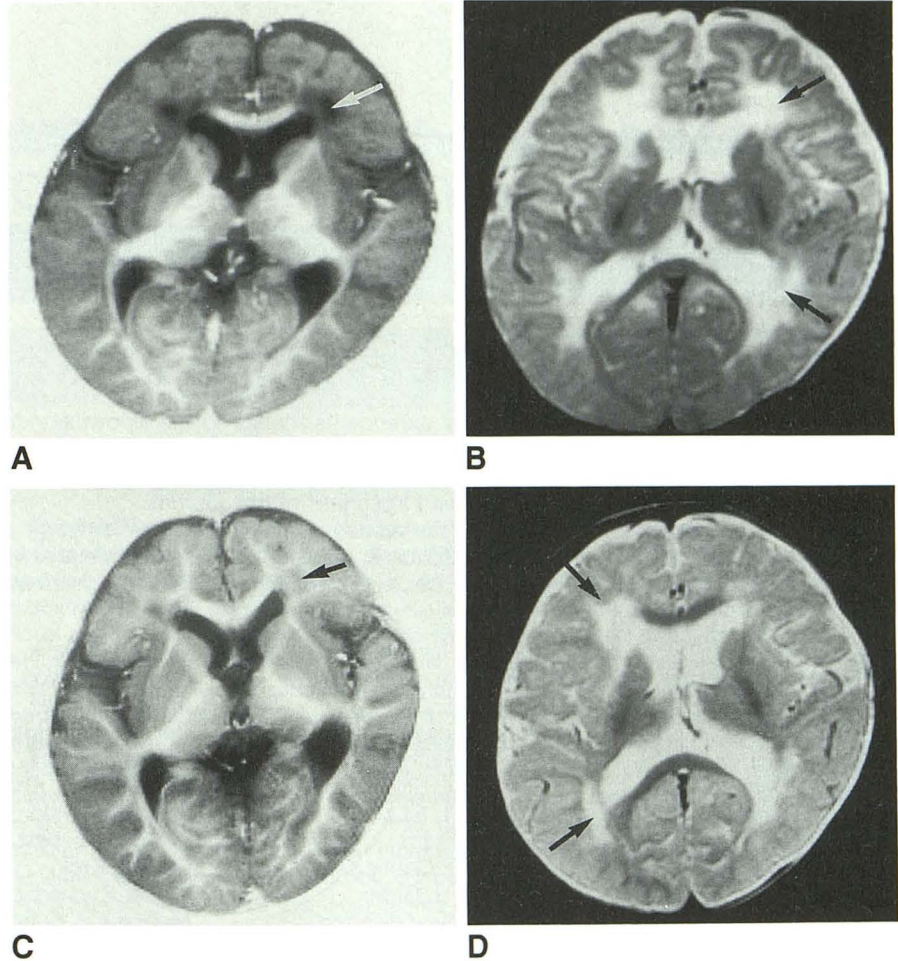
Our present results, both in cross-sectional and serial MR studies of three infants with FCMD, demonstrate that myelination was delayed, but continued to follow the stages in an orderly and predictable manner. Although the abnormal signal in the frontal lobes did not go away completely as the children got older, it became smaller when we performed the third MR study of case 2 at the age of 59 months. These areas are thought to represent the areas of last myelination, as are the "terminal zones" [9] or the pathway of unmyelinated fibers in these dystrophic patients. From these observations it might be suggested that the low-density areas found in FCMD on CT scanning are mainly due to a delay in myelination rather than to a demyelination or a dysmyelination process.

Another characteristic finding revealed by our MR study is the presence of pachygyria. All three cases studied displayed this finding. Previous neuropathologic studies have described pachygyria and polymicrogyria as the most consistent findings of FCMD [5].

Such developmental abnormalities as delayed myelination and arrested migration (pachygyria) may be due to either faulty programming or a destructive process in fetal life. Faulty programming would be the result of an abnormal genetic code. Both of these processes have been reported as possi-

Fig. 2.—Case 3.

A–D, MR images at age 8 months (A and B) and at age 18 months (C and D). A and C are inversion-recovery sequences (3000/400/22/1); B and D are T2-weighted spin-echo sequences (3000/90/1). In A, myelination is present except in the frontal white matter (arrow). In C, progression of myelination is shown but a small portion of the frontal white matter shows symmetric low intensity (arrow). This is an immature pattern for 18 months of age. Pachygyria is less apparent in this case than in case 1. In B and D, there is high intensity in the white matter (arrows). We believe that this represents unmyelinated fiber tracts.



ble causes of FCMD [4, 12], but further study will be necessary to determine the exact mechanism responsible.

#### REFERENCES

1. Warburg M. Hydrocephaly, congenital retinal non-attachment, and congenital falciform fold. *Am J Ophthalmol* 1978;85:88–94
2. Tachi N, Tachi M, Sasaki K, Tanabe C, Minagawa K. Walker-Warburg syndrome in a Japanese patient. *Pediatr Neurol* 1988;4:236–240
3. Santavuori P, Leisti J, Kruus S, Raitta C. Muscle, eye and brain disease: a new syndrome. *Doc Ophthalmol* 1978;17:393–396
4. Fukuyama Y, Osawa M, Suzuki H. Congenital progressive muscular dystrophy of Fukuyama type: clinical, genetic and pathological considerations. *Brain Dev* 1981;3:1–29
5. Takada K, Nakamura H, Tanaka J. Cortical dysplasia in congenital muscular dystrophy with central nervous system involvement (Fukuyama type). *J Neuropathol Exp Neurol* 1984;43:395–407
6. Yoshioka M, Okuno T, Honda Y, Nakano Y. Central nervous system involvement in progressive muscular dystrophy. *Arch Dis Child* 1980;55:589–594
7. Yoshioka M, Saiwai S. Congenital muscular dystrophy (Fukuyama type): Changes in the white matter low density on CT. *Brain Dev* 1988;10:41–44
8. Yakovlev PI, Lecours AR. The myelogenetic cycles of regional maturation of the brain. In: Mankowski A, ed. *Regional development of the brain in early life*. Philadelphia: Davis, 1967:3–69
9. Barkovich AJ, Kjos BO, Jackson DE, Norman D. Normal maturation of the neonatal and infant brain: MR imaging at 1.5 T. *Radiology* 1988;166:173–180
10. Johnson MA, Penneck JM, Bydder GM, et al. Clinical NMR imaging of the brain in children: normal and neurologic disease. *AJNR* 1983;141:1005–1018
11. Yoshioka M, Okuno T, Ito M, Konishi Y, Itagaki Y, Sakamoto Y. Congenital muscular dystrophy (Fukuyama type): repeated CT studies in 19 children. *Comput Tomogr* 1981;5:81–88
12. Kamoshita S, Konishi Y, Segawa M, Fukuyama Y. Congenital muscular dystrophy as a disease of the central nervous system. *Arch Neurol* 1975;33:513–516