

MR Imaging in Patients with Intracranial Aneurysm Clips

Ronald L. Becker¹
 Joseph F. Norfray²
 George P. Teitelbaum³
 William G. Bradley, Jr.³
 J. Bruce Jacobs⁴
 Lyle Wacaser⁵
 Raymond L. Rieman⁶

Four patients with intracranial aneurysm clips made from a variety of alloys were studied without incidence by MR imaging at field strengths ranging from 0.35 to 0.6 T. Knowledge of the type of alloy used in the manufacturing of an aneurysm clip is important in determining whether the clip will or will not deflect in a magnetic field. Ferromagnetic clips show deflection and torque in a magnetic field and have the potential to dislodge from the aneurysm. Nonferromagnetic or weakly ferromagnetic aneurysm clips such as the Sugita (Elgiloy), Yasargil (316 LVM stainless steel), Heifetz (Elgiloy), Yasargil (Phynox), and Vari-Angle McFadden (MP35N) do not deflect or deflect weakly in the magnetic field and therefore would not be expected to dislodge during MR.

The option of imaging many patients with intracranial aneurysm clips with MR extends the usefulness of the technique to a previously excluded population.

The presence of an intracranial aneurysm clip has come to represent an absolute contraindication to the use of MR imaging [1-4]. This is related to the potential risk for the creation of forces and torques by the magnetic field that might be sufficient to create dislodgment of an aneurysm clip with subsequent injury to the patient [5]. Neurosurgeons currently can choose from a wide variety of aneurysm clips. Knowing the specific type of aneurysm clip used in a given patient gives metallurgic information about the type of alloy used in the manufacture of the clip and hence allows its characterization from a ferromagnetic standpoint [5, 6]. This knowledge can be used to predict whether a patient with an aneurysm clip can or cannot be imaged safely with MR.

Materials and Methods

The MR studies and records of four patients with intracranial aneurysm clips examined at different centers were reviewed. MR units included a Dasonics 0.35-T, a Picker Vista 0.5-T, and a Technicare 0.6-T scanner. Spin-echo pulse sequences were used. T1-weighted images were obtained with 500-800/20-40/2-4 (TR/TE/excitations). T2-weighted images were obtained with 1.5-2.5/60-80. The four patients were 35, 35, 58, and 74 years old (mean age, 50 years).

Two patients required MR of the spine, one to exclude a posttraumatic syringomyelia and the other to confirm and further characterize an intramedullary cystic mass suggested earlier on postmyelographic CT. A third patient had symptoms suggesting possible intracranial mass effect. CT was nondiagnostic because of an aneurysm-clip-related artifact. Therefore, MR was requested. In the fourth case MR was requested as a baseline postoperative study.

In two patients, MR was performed knowing that the clips were nonferromagnetic. In the patient with a suspected posttraumatic syrinx the neurosurgeon knew that the Vari-Angle McFadden aneurysm clip used was nonferromagnetic on the basis of the studies of Dujovny et al. [6]. In the patient with suspected intracranial mass effect a clip identical to that used in the patient's aneurysm clipping was tested for deflection at the portal of a Dasonics 0.35-T magnet according to the technique described by New et al. [5] and was shown to be nondeflecting. The patient with an intramedullary cystic mass in the thoracic cord was erroneously thought to have a nonferromagnetic clip. Confirmatory tests were not done.

Received December 14, 1987; accepted after revision April 25, 1988.

¹ Department of Diagnostic Radiology, Torrance Memorial Hospital Medical Center, 3330 Lomita Blvd., Torrance, CA 90590. Address reprint requests to R. L. Becker.

² Department of Radiology, Humana Hospital Springfield, Springfield, IL 62703.

³ Department of Radiology, Huntington Medical Research Institutes, Pasadena, CA 91105-3201.

⁴ Medical Imaging Center of Southern California, Santa Monica, CA 90403.

⁵ Neurosurgery, Ltd., Springfield, IL 62702-4988.

⁶ Department of Radiology, St. John's Regional Medical Center, Oxnard, CA 93030.

AJNR 9:885-889, September/October 1988.
 0195-6108/88/0905-0885

© American Society of Neuroradiology

Results

Three patients with nonferromagnetic aneurysm clips and one patient with a ferromagnetic aneurysm clip were scanned without incident. None of the patients were aware of sensations such as tugging or pulling. No patient had symptoms to suggest clip dislodgment.

The information gained from MR was useful in patient management. In case 1, a posttraumatic syrinx was excluded and myelomalacia of the cervical cord was diagnosed (Fig. 1). In case 2, MR excluded a mass lesion; further patient evaluation was considered unnecessary (Fig. 2). In case 3, examination of the brain was nondiagnostic because of an extensive

ferromagnetic artifact (Fig. 3). Nevertheless, evaluation of the thoracic cord revealed a cystic neoplasm. Because of the large distance between the ferromagnetic clip and the lower thoracic spinal cord, the area of primary clinical concern, no artifacts were observed here. MR in case 4 provided a post-surgical baseline.

Case Reports

Case 1

A 35-year-old man had sudden onset of severe headache. A left-sided posterior communicating artery aneurysm was demonstrated

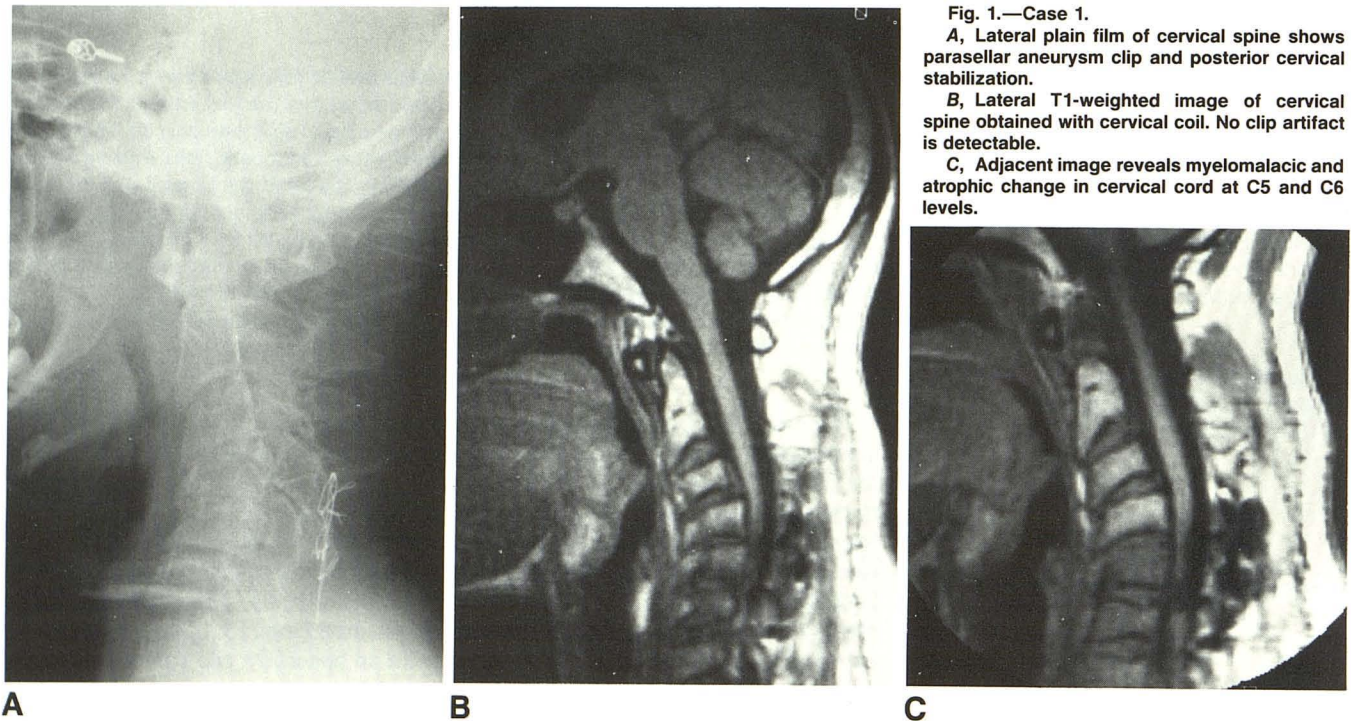


Fig. 1.—Case 1.

A, Lateral plain film of cervical spine shows parasellar aneurysm clip and posterior cervical stabilization.

B, Lateral T1-weighted image of cervical spine obtained with cervical coil. No clip artifact is detectable.

C, Adjacent image reveals myelomalacic and atrophic change in cervical cord at C5 and C6 levels.

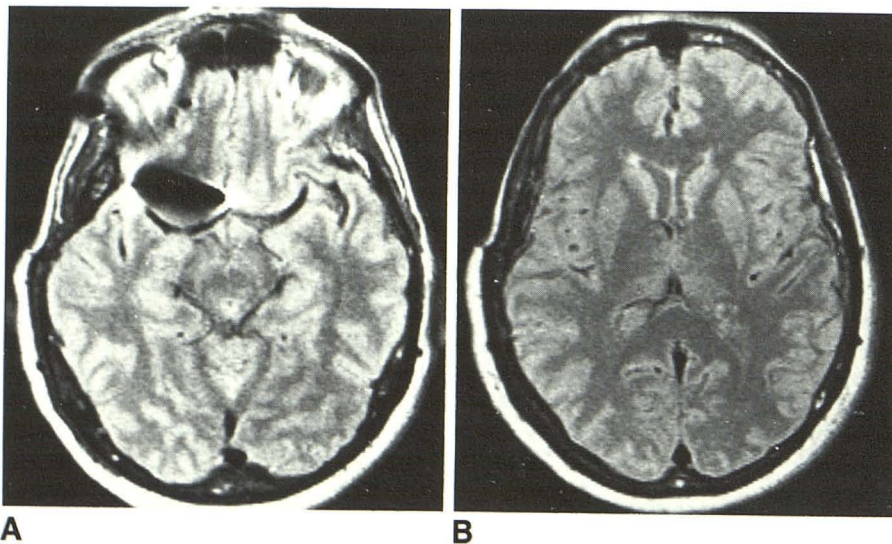


Fig. 2.—Case 2.

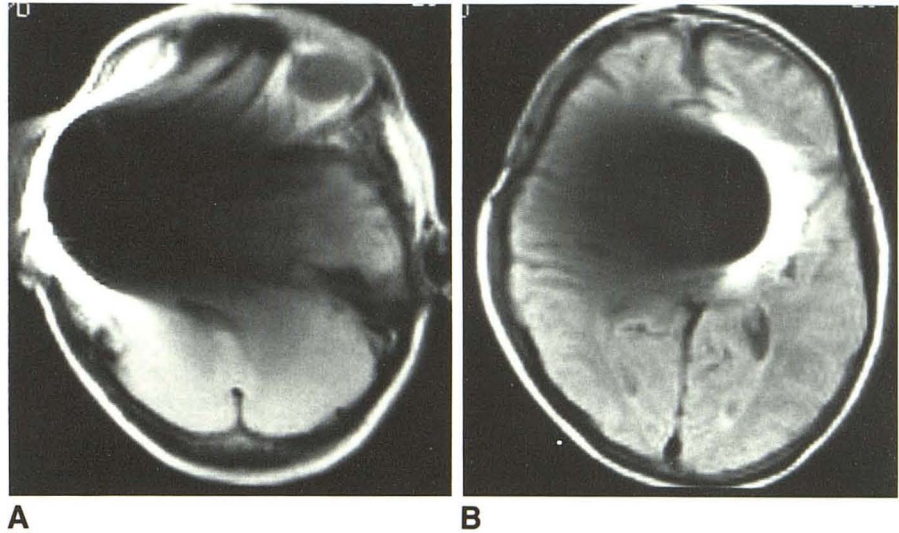
A, Axial section at level of Yasargil (316 LVM stainless steel) aneurysm clip shows ovoid artifact characteristically seen with nonferromagnetic or weakly ferromagnetic clip.

B, Axial section at level of lateral ventricles is free of artifact.

Fig. 3.—Case 3.

A, Axial section at level of Heifetz (17-7PH) aneurysm clip shows extensive image degradation due to ferromagnetic artifact.

B, Extensive artifact persists at higher axial section.



angiographically. The aneurysm was clipped with a Vari-Angle McFadden clip. Nine months later, the patient was rendered quadriplegic after a motorcycle accident. His sensory level stabilized at the C6 level; however, 4 months later the sensory level ascended to C5. A posttraumatic syringomyelia was suspected. MR was ordered with the knowledge that the Vari-Angle McFadden clip was nonferromagnetic [6]. The patient was slowly and carefully advanced into a Picker 0.5-T scanner. No unusual sensations or adverse effects were noted. Myelomalacic changes rather than a syrinx of the cervical spinal cord were found (Fig. 1), so surgery was unnecessary.

Case 2

A 58-year-old woman with long-standing right frontal headaches was found on angiography to have a 2.5-cm aneurysm of the right internal carotid artery just superior to the right ophthalmic artery. Successful clipping was achieved by using a 316 LVM stainless steel curved Yasargil clip.* Approximately 1½ years after surgery, the patient presented with worsening bifrontal headaches and visual loss in the left eye. Because of the extensive clip artifact on CT, MR was believed to be indicated. Before imaging the patient, a Yasargil clip of an allow identical to that used to clip the patient's aneurysm was tested for deflection at the portal of a Dasonics 0.35-T MR scanner according to the technique described by New et al. [5]. No deflection was observed. The patient was then imaged in the same MR unit after being advanced slowly into the scanner. No adverse effects were encountered. Although a regional artifact was noted adjacent to the aneurysm clip (Fig. 2), a diagnostic study excluded major pathologic abnormalities.

Case 3

A 74-year-old woman, in whom a right internal carotid artery aneurysm had been ligated with a Heifetz clip 13 years earlier, presented with bilateral lower extremity numbness, weakness, pain, and incoordination. Myelography via cervical and lumbar approaches and postmyelographic CT indicated a cystic lesion extending from T5 to T8 suggestive of a neoplasm. It was believed that the aneurysm clip was nonferromagnetic; however, the extensive artifacts noted indicated that the clip was ferromagnetic (Fig. 3). No adverse symptoms were noted. Subsequently, the spinal cord lesion proved to be a cystic astrocytoma at surgery.

Case 4

A 35-year-old man had symptoms of a subarachnoid hemorrhage. At angiography a left internal carotid bifurcation aneurysm was demonstrated. Clipping was accomplished with a Vari-Angle McFadden aneurysm clip. MR was requested 2 months after surgery to serve as a baseline examination. This was performed without incident on a Technicare 0.6-T MR unit.

Discussion

To our knowledge the four cases described represent the first reported examples of patients studied by MR who had intracranial aneurysm clips. While previously the radiologic literature has regarded the presence of an intracranial aneurysm clip as a contraindication to the use of MR [1-4], no awareness of unusual sensations or adverse effects was noted at field strengths of 0.35-0.6 T; Dujovny similarly noted no adverse effects at 1.5 T (M. Dujovny, personal communication). The MR risk in patients with aneurysm clips can be eliminated by selecting patients for MR who have aneurysm clips known to be insufficiently ferromagnetic to be deflected or torqued at the static field strength to be used [5, 6].

In a systematic study designed to assess the ferromagnetic properties of aneurysm and hemostatic clips, New et al. [5] found that longitudinal forces and torques were exerted on 16 of 21 clips tested. These forces and torques were potentially capable of causing clip dislodgment and subsequent hemorrhage from a clipped aneurysm or injury to adjacent structures. The risk of dislodgment was proportional to the degree of ferromagnetism of the clip. Clips made of alloys containing 10-14% nickel appeared to be free of notable ferromagnetism by virtue of nickel's ability to stabilize iron in a form that reduces the magnetic susceptibility of stainless steel [5]. The "nonferromagnetic" clips studied in this report had nickel contents of 13.5-35% (see Table 1).

"Cold working" refers to the cutting or shaping of a material in the absence of heat. Although a stainless steel may be nonmagnetic, significant ferromagnetic domains can be induced within the steel during cold working [5]. This creates a

* Aesculap Instruments Corp., Burlingame, CA.

TABLE 1: Composition of Some Commonly Used Aneurysm Clips

Magnetic Properties: Clip	Alloy	Composition (%)							
		Cr	Ni	C	Mn	Si	Mo	Co	Fe
Non- or weakly ferromagnetic:									
Sugita, Heifetz Elgiloy	Elgiloy	20	15	0.15	2	—	7	40	16
Yasargil	316 LVM stainless steel	17	13.5	0.01	1.4	0.6	2	—	65
Vari-Angle McFadden	MP35N	20	35	—	—	—	10	35	—
Ferromagnetic:									
Sundt-Kees, McFadden, Drake, Mayfield	301	16–18	6–8	0.15	2.0	1.0	—	—	—
Kapp	404	—	—	—	—	—	—	—	—
Heifetz (PRE-1984), Vari-Angle Micro, Vari-Angle Spring, Pivot, Sundt-Kees Multi-Angle	17–7PH	17	7	0.09	1.0	1.0	—	—	72.9
Scoville-Lewis	EN57J stainless steel	16–17	9–10	0.2	—	0.5	3	—	—

Note.—Modified from New et al. [5], Dujovny et al. [7], and Brown et al. [8]. A dash (—) reflects an absence of the material in the clip.

potential hazard to the MR imaging of patients with aneurysm clips. Teitelbaum et al. [9] demonstrated that 316 L stainless steel, which in bulk form is nonmagnetic, acquires weak ferromagnetic domains during the cold working required to create the unique and complex shapes of intravascular filters, stents, and coils. In an in vitro canine model, magnetic forces and torque did not cause filter dislodgment at 1.5 T.

Aneurysm clips are made from a variety of stainless steels and proprietary alloys. The most desirable form of steel is an austenitic type [10] containing in excess of 10% nickel for stabilization at ambient temperatures, while chromium in excess of 14% is added for corrosion resistance. New et al. [5] noted that 10–14% nickel-containing clips were without sufficient ferromagnetism to induce hazard. Aneurysm clips can be evaluated for ferromagnetism by measuring their torque, deflection, and imaging artifacts. Truly nonferromagnetic clips will lack deflection and torque when tested by the technique of New et al. A Yasargil clip made from 316 LVM stainless steel and containing 13.5% nickel typifies the austenitic aneurysm clip variety, although it is weakly ferromagnetic [5, 8, 9]. At 1.5 T, a 316 LVM stainless steel ligation clip did orient weakly, but this small interaction is believed to be relatively safe [8]. The testing of clips for ferromagnetism by the New et al. technique represents an empiric and qualitative assessment of force. This is the method established in the literature and conclusions are field-strength-related. Non-austenitic alloys such as 301 stainless steel, 17–7PH, and 405SS are significantly ferromagnetic.

Some newer alloys used in aneurysm clip manufacturing are cobalt-based and by definition are not steels since they contain little or no iron [10]. They include the Vari-Angle McFadden clip made of MP35N and the Sugita and Heifetz clips made of Elgiloy, which are nonferromagnetic and do not show deflection when tested in a magnetic field (Table 1). These cobalt alloys are stronger and more elastic than austenitic stainless steels.

In cases 1, 2, and 4 the aneurysm clips were either known or proved to be not notably ferromagnetic, while in case 3 a ferromagnetic Heifetz clip (17–7PH) placed in 1974 was

thought to be nonferromagnetic. Fortunately, the MR procedure in case 3 was uneventful, presumably due to local tissue fixation adjacent to the aneurysm clip.

Image distortions and artifacts may be related to materials that alter the local magnetic field; that is, magnetic susceptibility effects. Magnetic susceptibility is a quantity that characterizes the extent to which an applied external magnetic field can be modified by the presence of matter [11]. Diamagnetic, paramagnetic, and ferromagnetic substances will cause susceptibility artifacts depending on the strength of the applied field. Diamagnetic substances have minimal negative susceptibilities and their artifacts are so minimal as to be invisible on clinical MR images. The additional field created by a paramagnetic substance is 1×10^5 times larger than a diamagnetic substance. The magnetic susceptibility of a paramagnetic substance has a linear proportionality to field strength, and therefore increasing field strength increases the susceptibility artifact [12]. With a ferromagnetic substance there is a very large initial increase in the induced magnetization, and creation of large artifacts with relatively small increase in the applied field. A saturation point is reached when further increase in the applied field causes only very small increases in susceptibility artifacts [12]. The major magnetic field interactions for most metals used in medical implants are either paramagnetic or ferromagnetic; ferromagnetic materials produce substantially greater local field inhomogeneities than do paramagnetic materials.

In cases 2 (Fig. 2) and 4 similar focal artifacts in the region of the aneurysm clips were seen, but they did not substantially degrade the diagnostic quality of the examination. These artifacts were typified by an oval or spherical zone of signal void surrounded by a zone of hyperintensity, which was present despite the lack of significant ferromagnetism in the aneurysm clip used. This is related primarily to the development of induced currents within the paramagnetic aneurysm clip by the fluctuating gradient magnetic fields. These induced (eddy) currents create secondary magnetic field inhomogeneities that result in distortion of the field flux lines, resulting in a spatially misregistered signal and image distortion [11, 13,

14]. The magnitude of eddy current formation is determined by the rate of change of the magnetic field, the composition and resistance of the metal, as well as the size and shape of the device [14]. Magnetic susceptibility and eddy currents both result in local field homogeneities, a "final common pathway" whose individual contributions toward image artifacts currently are not separable.

In case 3 (Fig. 3) a much larger image-degrading artifact was seen. This was related to the presence of a ferromagnetic Heifetz aneurysm clip (17-7PH) within the imaged volume. Ferromagnetic alloys have far greater magnetic susceptibility effects than paramagnetic alloys do. This greater magnetic susceptibility effect of ferromagnetic alloys creates more field inhomogeneity and much greater image distortion compared with paramagnetic alloys [14].

MR evaluation of patients with intracranial aneurysm clips is requested often by neurosurgeons, and recent articles in their literature document the lack of deflection of nonferromagnetic aneurysm clips in the magnetic field [6]. The neurosurgeon may be able to provide specific information to characterize the aneurysm clip used, or that information may be available from the surgery report. Plain skull films are not reliable for the characterization of aneurysm clips. This is exemplified by the currently available Heifetz Elgiloy clips, which are nonferromagnetic. Before 1984 the Heifetz clips were manufactured from the ferromagnetic 17-7PH alloy. On plain skull films the external features of these Heifetz clip varieties are identical. Therefore, no assumption regarding the magnetic properties of a Heifetz aneurysm clip can be made on the basis of screening skull radiographs.

While it is not our intent to minimize the potential hazards of MR in patients with ferromagnetic aneurysm clips, the complete exclusion of all patients with aneurysm clips from study by MR appears to be unnecessary. Several criteria should be met in patient selection: (1) the aneurysm clip is known or verified to be not substantially ferromagnetic, (2) MR is believed to be the imaging procedure of choice, and (3) no other contraindications to MR exist. Although our cases were concerned with MR applications to the brain and spinal cord, body applications for MR are numerous and expanding. The options of both CNS and body imaging with MR in patients with nonferromagnetic or weakly ferromagnetic aneurysm clips extend the usefulness of the technique to a previously excluded population.

In view of the wide availability of a variety of nonferromagnetic aneurysm clips, their use in neurosurgery should be encouraged. In addition to their demonstrated MR compatibility, these alloys are more corrosion-resistant than ferromagnetic alloys. The use of MR in patients known to have nonferromagnetic or weakly ferromagnetic aneurysm clips is not contraindicated.

REFERENCES

1. Kelly WM. Image artifacts and technical limitations. In: Brandt-Zawadzki M, Norman D, eds. *Magnetic resonance imaging of the central nervous system*. New York: Raven, 1986:43-82
2. Laakman RW, Kaufman B, Han JS, et al. MR imaging in patients with metallic implants. *Radiology* 1985;157:711-714
3. Kelly WM, Paglen PG, Pearson JA, San Diego AG, Solomon MA. Ferromagnetism of intraocular foreign body causes unilateral blindness after MR study. *AJNR* 1986;7:243-245
4. Kean DM, Worthington BS, Firth JL, Hawkes RC. The effects of magnetic resonance imaging on different types of microsurgical clips. *J Neurol Neurosurg Psychiatry* 1985;48(3):286-287
5. New PFJ, Rosen BR, Brady TJ, et al. Potential hazards and artifacts of ferromagnetic and non-ferromagnetic surgical and dental materials and devices in nuclear magnetic resonance imaging. *Radiology* 1983;147:139-148
6. Dujovny M, Kossovsky N, Kossowsky R, et al. Aneurysm clip motion during magnetic resonance imaging: in vivo experimental study with metallurgical factor analysis. *Neurosurgery* 1985;17:543-548
7. Dujovny M, Kossovsky N, Kossowsky R, et al. Vascular clips: an historic and biomechanical perspective. In: Fein JN, Flamm E, eds. *Cerebral vascular surgery*. New York: Springer-Verlag, 1985:997-1046
8. Brown MA, Carden JA, Coleman RE, McKinney R, Spicer LD. *Magnetic field effects on surgical ligation clips*. Technical report. Research Triangle Park, NC: Edward Weck, 1986
9. Teitelbaum GA, Bradley WG, Klein BD. MR imaging artifacts, ferromagnetism, and magnetic torque of intravascular filters, stents, and coils. *Radiology* 1988;166:657-664
10. Kossowsky R, Dujovny M, Kossovsky N, Diaz FG, Ausman JI. Corrosion of aneurysm clips: evaluation and clinical implications. Part 1: Metallurgical foundations of stress corrosion failure. *ACTA Neurochir (Wien)* 1984;72:31-43
11. Sacco DC, Steiger DA, Bellon EM, Coleman PE, Haacke EM. Artifacts caused by cosmetics in MR imaging of the head. *AJR* 1987;148:1001-1004
12. Purcell EM. *Electricity and magnetism*, 2nd ed. New York: McGraw-Hill, 1985:255-286, 397-450
13. Ludeke KM, Roschmann P, Tischler R. Susceptibility artifacts in NMR imaging. *Magn Reson Imaging* 1985;3:329-343
14. Fache JS, Price C, Hawbolt EB, Li DKB. MR imaging artifacts produced by dental materials. *AJNR* 1987;8:837-840