

Arachnoid Cyst of the Velum Interpositum

S. M. Spiegel,¹ B. Nixon,² K. TerBrugge,¹ M. C. Chiu,¹ and H. Schutz²

Arachnoid cysts are thin-walled fluid-filled cavities that are uncommon causes of intracranial mass lesions [1, 2]. These lesions have been found in various locations, both supratentorial and infratentorial [1, 3–7]. This report describes a case in which the arachnoid cyst arose from the tela choroidea and occupied the cistern of the velum interpositum. The cyst caused symptoms similar to those seen with a third ventricular mass [8, 9]. To our knowledge, this is the first report of an arachnoid cyst in this location.

Case Report

A 43-year-old woman was admitted to the hospital because of two episodes of sudden loss of consciousness within a period of a few months. The patient stated that after regaining consciousness she immediately felt dizzy, disoriented, and confused. However, she was able to get up almost immediately after regaining consciousness. After awakening from the first of these episodes, the patient also had blurred vision, which persisted for 24 hr and then resolved. She reported no seizure activity or incontinence. On further questioning, the patient stated there had been other episodes of loss of consciousness and several episodes of headache over many years.

Cranial CT with IV contrast demonstrated a lesion of CSF density lying between the third and lateral ventricles posteriorly (Fig. 1). The wall of the lesion demonstrated mild enhancement. There was asymmetric enlargement of the bodies of the lateral ventricles, with the right lateral ventricle larger than the left.

The next day, via lumbar puncture, 5 ml of Omnipaque (180 mg/ml) was injected intrathecally to determine if the cystic lesion communicated with the subarachnoid space [2–5]. CT scans of the head were obtained 1 hr and 8 hr after the instillation of contrast material (Fig. 2). On the first CT scan, contrast was noted in the basal cisterns, the third ventricle, and the fourth ventricle. No contrast was seen in the lateral ventricles. The cystic structure between the third and lateral ventricles demonstrated a small amount of contrast within it. On examination 8 hr after the intrathecal injection, the contrast was no longer seen in the third or fourth ventricles. The contrast within the subarachnoid space was of decreased attenuation relative to the previous scan. The cystic structure previously noted had the same attenuation as the subarachnoid space. Thus, this cyst had a partial communication with the subarachnoid space and filled slowly.

Axial, coronal, and sagittal MR images were obtained (Fig. 3). A cystic lesion was noted in the velum interpositum, extending posteriorly toward the quadrigeminal plate cistern without reaching the level of the quadrigeminal plate.

The lesion was assumed to be an arachnoid cyst and surgery was planned for decompression. By way of a right parietal craniotomy, an interhemispheric transcallosal approach was used to expose the cyst. After the cyst was punctured, the roof was removed and tissue was submitted for pathologic study. The fluid within the cyst proved to be identical to CSF. The cyst was then marsupialized to the third ventricle.

The sample received for pathologic study consisted of a moderately cellular, collagenous tissue with a small amount of brain parenchyma. The lining of the tissue consisted of flattened cells. The appearance was typical of the wall of an arachnoid cyst.

After surgery, the patient had no further episodes of loss of consciousness or headache.

Discussion

The tela choroidea is vascular connective tissue lying in the triangular space between the lateral and third ventricles. The components of the boundaries are the fornices, the corpus callosum that forms the roof, and the roof of the third ventricle that forms its floor [10]. The tissue of the tela choroidea is continuous with the vascular core of the choroid plexuses of the lateral ventricles under the fornices [10]. Embryologically, the tela choroidea develops as the fusion of two layers of pia arachnoid, between the roof of the third ventricle and the under-surface of the corpus callosum [8, 11]. The cistern of the velum interpositum represents a potential space between the tela choroidea below and the columns of the fornices above [6, 11]. This potential space is actually a forward extension of the quadrigeminal plate cistern [6]. As arachnoid cysts have been shown to arise between the layers of the arachnoid tissue [1, 3–7], this arachnoid cyst probably arose from the tela choroidea and bulged upward into the space of the cistern of the velum interpositum.

The location of this cyst is unusual. Supratentorially, arachnoid cysts are most commonly situated in the middle cranial fossa [5–7]. Other locations are over the convexity of the brain parasagittally, with less frequent locations being the suprasellar region and the interhemispheric fissure [2, 3, 5–7]. Arachnoid cysts lying in the posterior fossa are more commonly noted behind the cerebellum in the midline and in the cerebellopontine angles [3]. Less likely locations are laterally about the cerebellar hemispheres, behind the clivus,

Received January 28, 1987; accepted after revision May 7, 1987.

¹ Department of Radiology, Toronto Western Hospital, 399 Bathurst St., Toronto, Ontario, Canada M5T 2S8. Address reprint requests to S. M. Spiegel.

² Department of Neurosurgery, Toronto Western Hospital, Toronto, Canada.

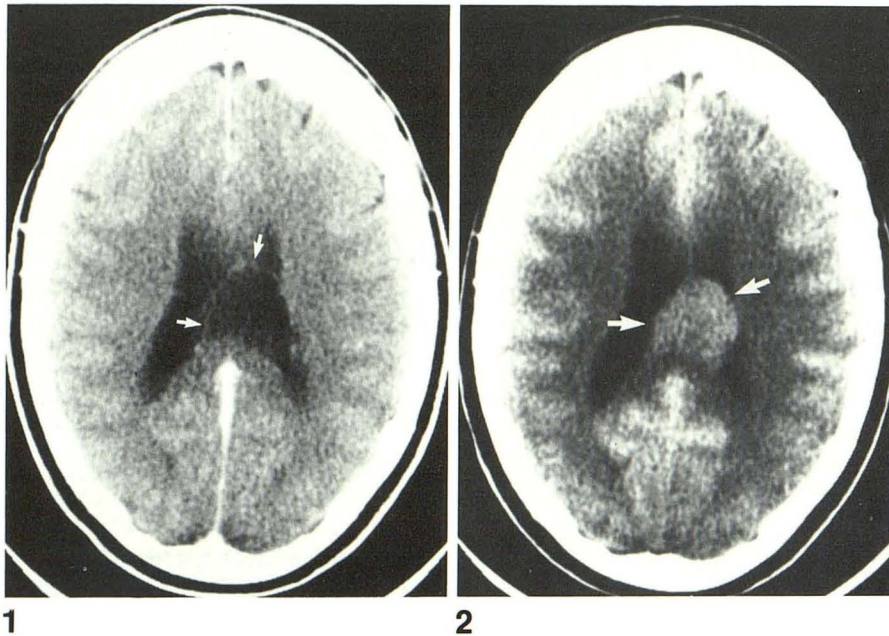


Fig. 1.—CT scan shows cyst in velum interpositum (arrows) at level of lateral ventricle bodies.

Fig. 2.—CT scan 8 hr after intrathecal injection of contrast material shows moderately dense contrast within cyst (arrows), while a CT scan (not shown) done only 1 hr after this injection showed uptake within subarachnoid space but not yet within cyst.

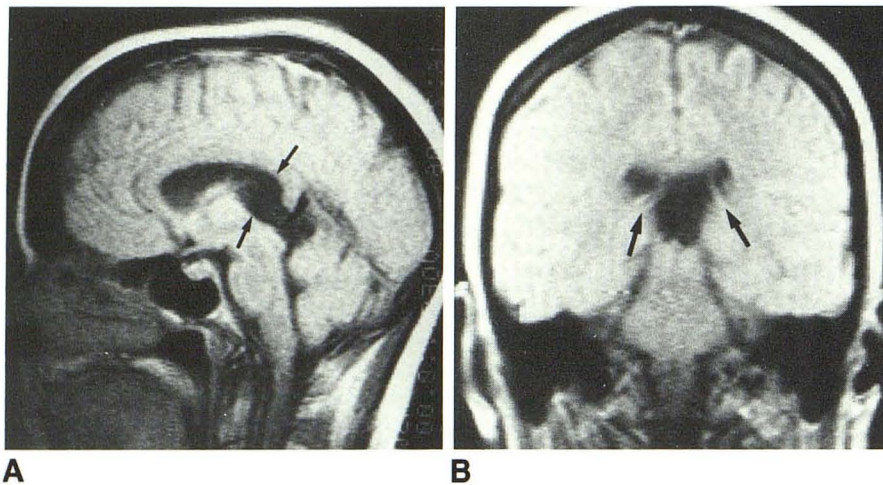


Fig. 3.—A, Sagittal T1-weighted MR image shows cyst in velum interpositum (arrows) and extending posteriorly.

B, Coronal MR image shows cystic structure (arrows) between lateral ventricles.

and in the quadrigeminal plate cistern [3, 4]. To our knowledge, there has been no report in the literature describing an arachnoid cyst in the velum interpositum. In the present case, the arachnoid cyst extended posteriorly from the cistern of the velum interpositum toward the quadrigeminal plate cistern, but was not visualized at the level of the quadrigeminal plate. Twenty-nine cases of arachnoid cysts in the quadrigeminal plate cistern have been described since 1940 [3].

In none of the published reports was there extension into the velum interpositum. Furthermore, these cysts are usually seen in a younger age group, although six of the cases have been reported in adults [3, 4]. Because of their location, arachnoid cysts in the quadrigeminal plate cistern cause enlargement of the lateral and third ventricles by compression of the aqueduct of Sylvius [3, 4, 6, 7].

A variety of supratentorial neuroepithelial cysts has also been previously described [5, 6, 12–15]. An interhemispheric location is unusual and is always associated with partial or total agenesis of the corpus callosum [6, 12]. Histologically, these cysts are quite variable, with components of the reported cysts including arachnoid, glial tissue, choroid plexus epithelium, and ependyma [6, 12–15]. The interhemispheric cysts arise in the midline above the third ventricle and extend superiorly into the interhemispheric fissure [12]. In one such case reported, there was contiguity of the cystic lesion with the roof of the lateral ventricles. In that case, the posterior portion of the corpus callosum was absent [12]. In the present case, the corpus callosum was intact and the arachnoid cyst extended posteriorly rather than superiorly.

Other cystic and cystlike structures can occur in this region.

A cavum velum interpositum or interventricular cavum could give a similar appearance on cranial CT; however, there should be free communication with the basal cisterns [7]. A cavum vergae is often present in a similar location, but it communicates with the lateral and third ventricles. Colloid cysts are encountered mainly in the third ventricle, but they can also be found in the cerebral parenchyma and in the meningeal spaces [5]. The usual appearance of a colloid cyst on cranial CT is an increased attenuation lesion. Epidermoid cysts may develop in the diploe, perisellar area, other leptomeningeal spaces, or in the posterior fossa [5]. These have ill-defined irregular borders and their cystic spaces may not communicate with the subarachnoid space. This would be a very rare location for an epidermoid cyst.

The patient's symptoms were compatible with a mass in the region of the tela choroidea [8]. In a previous case report of a meningioma in the tela choroidea, the patient's symptoms were headache, blurred vision, and atonic seizures [8], somewhat similar to the symptoms noted in our case.

The precise mechanism whereby a lesion in the tela choroidea may produce these symptoms is unclear [8, 9]. The arachnoid cyst in the present case extended anteriorly to just behind the foramen of Monro. Intermittent obstruction to the normal flow of CSF at the level of the foramina of Monro has been proposed as a mechanism of production of these clinical symptoms [9]. Other investigators have suggested that obstruction of the thalamostriate vein complex at the level of the foramina of Monro by an adjacent mass lesion may cause symptoms related to retrograde congestion in this venous system [16]. Intermittent symptoms could be caused by the valvelike mechanism that is presumed to exist in arachnoid cysts, allowing fluid to enter but not to exit at the same speed [1, 5, 7].

In conclusion, we have reported a rare case of an arachnoid cyst arising from the tela choroidea of the third ventricle, in which the patient presented with headache, episodes of loss of consciousness, and transient blurred vision, and in whom these clinical symptoms disappeared after surgical treatment of the lesion.

ACKNOWLEDGMENTS

We acknowledge with gratitude the contribution of M. Stechison, who provided us with pictures of the pathology slides.

REFERENCES

1. Dyck P, Gruskin P. Supratentorial arachnoid cysts in adults. *Arch Neurol* 1977;34:276-279
2. Gentry LR, Smoker WRK, Turksi PA, Menezes AH, Ramirez L, Cornell SH. Suprasellar arachnoid cyst: I. CT recognition and II. Evaluation of CSF dynamics. *AJNR* 1986;7:79-96
3. Choi SK, Starshak RJ, Meyer GA, Kovnar EH, Sty JR. Arachnoid cyst of the quadrigeminal plate cistern: Report of two cases. *AJNR* 1986;7:725-728.
4. Wakisaka S, Yoneda K, Kitano I, Kinoshita K, Matsuoka S. Arachnoid cyst in the quadrigeminal cistern. *Surg Neurol* 1986;26:52-58
5. Giudicelli G, Hassoun J, Shoux M, Tonon C. Supratentorial "Arachnoia" cyst. *J Neuroradiol* 1982;9:179-201
6. Angiography, vol. II, book IV: Specific disease processes. In: Newton TH, Potts DG, eds. *Radiology of the skull and brain*. St. Louis: Mosby, 1974:2719-2727
7. Taveras JM, Woods EH. *Diagnostic neuroradiology*. Baltimore: Williams & Wilkins, 1976:538-539
8. Ito J, Kadokaru T, Hayano M, Kurita I, Okada K, Yoshida Y. Meningioma in the tela choroidea of the third ventricle: CT and angiographic correlations. *Neuroradiology* 1981;21:207-211
9. Ryder JW, Kleinschmidt-DeMasters BK, Keller TS. Sudden deterioration and death in patients with benign tumours of the third ventricle area. *J Neurosurg* 1986;64:216-223
10. Barr ML. *The human nervous system: an anatomical viewpoint*, 2nd ed. Hagerstown, MD: Harper & Row, 1974:168-170
11. Taveras JM, Woods EH. *Diagnostic neuroradiology*. Baltimore: Williams & Wilkins, 1976:359-360
12. Solt LC, Deck JHN, Baim RS, TerBrugge K. Interhemispheric cyst of neuroepithelial origin in association with partial agenesis of the corpus callosum: case report and review of the literature. *J Neurosurg* 1980;52:399-403
13. MacGregor BJL, Gawler J, South JR. Intracranial epithelial cyst: report of two cases. *J Neurosurg* 1976;44:109-115
14. Palma L. Supratentorial neuroepithelial cysts: report of two cases. *J Neurosurg* 1975;42:353-357
15. Pearl GS, Takey Y, Tindall GT, Hoffman JC. Supratentorial subarachnoid epithelial cyst: case report and ultrastructural study. *Neurosurgery* 1982;11:48-51
16. Parkinson D. Sudden death due to third ventricle tumours. *J Neurosurg* 1986;65:128