

Cataract surgery in retinitis pigmentosa

Samrat Chatterjee, Deepshikha Agrawal, Deepanshu Agrawal¹, Swapnil M Parchand¹, Anupam Sahu²

Purpose: The aim of this study was to evaluate visual outcomes of cataract surgery in patients with retinitis pigmentosa. **Methods:** This retrospective case series includes a review of the medical records of all patients with retinitis pigmentosa undergoing cataract surgery between 2005 and 2018. The primary outcome measure was corrected distant visual acuity and change in vision impairment after surgery. **Results:** Of the 103 (132) patients, 60 (58.3%) were men and 43 (41.7%) were women. The mean age of the study population was 51.3 ± 11.3 (22–74) years. The mean symptom duration was 35.4 ± 44.5 (1–300) months. The most common morphology of cataracts was a combination of nuclear sclerosis, posterior subcapsular, and cortical cataract ($n = 65$ eyes, 49.3%). Phacoemulsification (87 eyes, 65.9%) was the preferred surgical technique. The mean preoperative corrected distant visual acuity of 1.21 ± 0.87 log MAR units improved significantly ($P < 0.001$) to 0.60 ± 0.56 log MAR units after surgery. The number of *blind* patients reduced from 27 (26.2%) to 8 (7.8%) patients. Zonular dialysis and posterior capsule tear were seen in six (4.5%) eyes each. Good preoperative vision (odds ratio: 6.1 [95% confidence interval: 2.9–13.0], $P < 0.0001$) was associated with better outcome, whereas reduced central macular thickness (odds ratio: 3.5 [95% confidence interval: 1.3–9.2], $P = 0.011$) was associated with poor outcome. **Conclusion:** A considerable number of patients presented with advanced cataracts and severe vision impairment. Significant improvement in visual acuity and alleviation of vision impairment was seen after surgery, with few complications. Good preoperative visual acuity predicted a good outcome, whereas macular thinning predicted a poor outcome.

Key words: Cataract, cataract surgery, phacoemulsification, retinitis pigmentosa, visual acuity, vision impairment

Cataract is an important secondary cause of vision impairment in retinitis pigmentosa (RP). It is characterized by an early onset, and the most common morphological type reported in the literature is posterior subcapsular cataract.^[1–5] Although with the onset of cataract, contrast sensitivity is the most commonly affected visual function in patients with RP,^[6] with cataract progression, there is an overall reduction in vision. Most of the patients with RP are young to middle-aged adults. Therefore, the onset of cataract leads to further deterioration of vision in these patients, which has a significant effect not only on their general well-being, but also on their economic productivity.

Generally, the results from most studies indicate that vision significantly improves in patients with RP after cataract surgery.^[7–13] However, there are also few reports with contrary results.^[14,15] All the published studies are from western or developed Asian countries, where patient characteristics, severity of RP, grade of cataract, and vision impairment are different from India. The severity of vision impairment in Indian patients is greater than in patients from the west.^[16–18] Two recent population-based studies from India have reported the prevalence of RP to be 0.13%^[16] and 0.17%.^[17] In both these studies, greater than 50% of patients had visual acuity worse than 20/200, compared to only 8% of patients in the United

States.^[18] Cataract is reported to affect 23.4%–53% eyes with RP.^[2–5] Therefore, the overall burden of vision impairment in Indian patients is expected to be higher. There are no previous studies that have evaluated the severity of vision impairment due to cataract in Indian patients with RP. Therefore, the aim of this study was to report the visual outcome after cataract surgery in patients with RP, and also to identify factors for prognosticating the outcome.

Methods

This retrospective case series included all the patients with RP who had undergone cataract surgery at a tertiary eye care institute in central India between January 2005 and April 2018. RP was diagnosed by retina specialists based on fundus features of attenuated retinal vessels, typical bony-spicule retinal pigmentation, pigment clumping, and hypopigmentation of the retinal pigment epithelium in the mid-peripheral retina. History of night blindness and presence of optic disc pallor when present corroborated the diagnosis. Patients with sectoral, unilateral, or other atypical forms of RP were excluded. The study adhered to the Declaration of Helsinki and was approved by the Institutional Ethics Committee.

This is an open access journal, and articles are distributed under the terms of the Creative Commons Attribution-NonCommercial-ShareAlike 4.0 License, which allows others to remix, tweak, and build upon the work non-commercially, as long as appropriate credit is given and the new creations are licensed under the identical terms.

For reprints contact: WKHLRPMedknow_reprints@wolterskluwer.com

Cite this article as: Chatterjee S, Agrawal D, Agrawal D, Parchand SM, Sahu A. Cataract surgery in retinitis pigmentosa. Indian J Ophthalmol 2021;69:1753–7.

Access this article online

Website:

www.ijo.in

DOI:

10.4103/ijo.IJO_2916_20

Quick Response Code:



Cornea and Anterior Segment Services, ¹Vitreo-retina Services and ²Pediatric Ophthalmology and Strabismus Services, MGM Eye Institute, Raipur, Chhattisgarh, India

Correspondence to: Dr. Samrat Chatterjee, MGM Eye Institute, 5th Mile, Vidhan Sabha Road, Raipur 493111, Chhattisgarh, India. E-mail: samrat@mgmeye.org

Received: 09-Sep-2020

Revision: 26-Jan-2021

Accepted: 27-Feb-2021

Published: 18-Jun-2021

The medical records of the selected patients were reviewed for demographic factors, duration of symptoms, presence of night blindness, corrected distance visual acuity (CDVA) at preoperative, 1 and the last follow-up visits, the morphology of cataract, zonular integrity, coexisting ocular or systemic comorbidities, the status of the optic disc and macula, techniques of cataract surgery, type of intraocular lens (IOL) implanted, intra- and postoperative complications, and follow-up duration.

Before surgery, all patients had undergone a complete ocular evaluation that included history taking, visual acuity assessment, refraction, slit-lamp examination, intraocular pressure measurements, and fundus evaluation. Visual field analysis or optical coherence tomography (OCT) were done in only selected patients. Phacoemulsification with acrylic hydrophobic monofocal IOLs (Alcon Surgical, Bengaluru, India, or Appasamy Associates, Chennai, India) was the preferred method, but in eyes with hard brunescence or total cataract, manual small incision cataract surgery, or extra-capsular cataract extraction were also performed. Our institute caters to patients from various economic backgrounds. In patients from economically disadvantaged circumstances who cannot afford the cost of surgery or the IOL, treatment is either subsidized or free. In this group of patients, polymethyl methacrylate (PMMA) IOLs (Aurolab, Madurai, India) were implanted even if the patients underwent phacoemulsification. Postoperatively, patients were reviewed at 1 day, 1 week, and 1 and thereafter advised 6-monthly reviews. They were treated with topical broad-spectrum ofloxacin 0.3% eye drops for 2 weeks and topical prednisolone acetate 1% eye drops in tapering doses for 4–6 weeks.

The main outcome measure was CDVA at 1 month. A good outcome was defined as CDVA of 20/200 or better, and poor outcome was CDVA less than 20/200. For statistical analysis, Snellen's visual acuity in feet was converted into the logarithmic value of minimal angle of resolution (log MAR).^[19] Light perception, which is not a measure of visual acuity but that of a visual stimulus, was assigned a score of 2.9 based on a previous study.^[20] The severity of *vision impairment* was categorized as per World Health Organization recommendations [ICD-11 for Mortality and Morbidity Statistics (Version: 04/2019). 9D90 Vision impairment including blindness [Appendix 1]; [Available from: <https://icd.who.int/browse11/l-m/en#/http%3a%2f%2fid.who.int%2f%2f%2f%2f1103667651>. Accessed November 2019].

Statistical analysis was carried out with SPSS for Windows, version 23.0 (SPSS, Chicago, Illinois). Quantitative and qualitative variables were expressed as mean \pm standard deviation and percentages, respectively. Continuous variables were analyzed with the Student's *t* test. Pearson's Chi-square test was used to measure the association between individual variables and outcome measures and Spearman's rank correlation coefficient to correlate different variables. A multiple logistic regression model was used to identify independent risk factors. A two-tailed *P* value <0.05 was considered statistically significant.

Results

Demographics: During the study period, RP was diagnosed in 1141 patients of whom 103 (9%) patients underwent cataract surgery in 132 eyes. There were 60 (58.3%) male and 43 (41.7%)

female patients. The mean age of the patients at the time of surgery was 51.3 ± 11.3 (22–74) years. There were 16 (15.5%) patients who were 20–40 years of age, 58 (56.3%) patients who were 41–59 years of age, and 29 (28.1%) patients who were 60 years or more. There were 43 (41.7%) patients from a lower economic section with a mean age of 54.5 ± 12.0 years. The mean age of this group was significantly greater ($P = 0.02$) than the mean age (51.3 ± 11.3 years) of the rest of the patients.

Clinical presentation: Only 12 (11.7%) patients had been previously diagnosed with RP. A history of night blindness could be elicited in 40 (38.8%) patients. The interval between the onset of visual symptoms and cataract surgery was 35.4 ± 44.5 (1–300, median: 13) months. Bilateral cataract was present in 82 (79.6%) patients and unilateral cataract in 21 (20.4%) patients. The details of the morphological type of cataract present in the operated eyes in different categories of *vision impairment* is given in Appendix 2. The prevalent types of cataract were nuclear sclerosis in 44 (33.3%) eyes, posterior subcapsular cataract in 19 (14.4%) eyes and a combination of nuclear sclerosis, posterior subcapsular cataract, and cortical cataract in 65 (49.3%) eyes. Total cataract was present in four (3%) eyes. Preoperatively, zonular dehiscence was observed in four eyes. Important co-existing ocular morbidities were anterior uveitis in five eyes, corneal scar in four eyes, and macular abnormalities such as epi-retinal membrane, macular scar, and macular pigment degeneration in seven eyes. In 11 eyes, optic atrophy was present. Diabetes mellitus was present in 11 patients, hypertension in 6 patients, ischemic heart disease in 5 patients, and Hansen's disease in 1 patient.

Surgical details: Cataract surgery was performed in both eyes in 29 (28.2%) patients and in one eye in 74 (71.8%) patients. Phacoemulsification was performed in 87 (65.9%) eyes, manual small incision cataract surgery in 42 (31.8%) eyes, and extracapsular cataract extraction in 3 (2.3%) eyes. Overall, a rigid PMMA IOL was implanted in 86 (65.2%) eyes and acrylic hydrophobic monofocal IOL was implanted in 44 (33.3%) eyes, and 2 (1.5%) eyes were left aphakic. In the 87 eyes which had undergone phacoemulsification, an acrylic hydrophobic IOL was implanted in 44 (50.6%) eyes and a rigid PMMA IOL was implanted in 43 (49.4%) eyes. In 42 eyes where manual small incision cataract surgery was performed, a rigid PMMA IOL was implanted in 40 (95.2%) eyes but due to a large posterior capsule rupture 2 (4.8%) eyes were left aphakic. All (100%) the three eyes undergoing extra-capsular cataract surgery received rigid PMMA IOL. Intraoperatively, zonular laxity was noted in an additional four (3%) eyes. A capsular tension ring was inserted in eight eyes.

Visual acuity: The mean follow-up duration was 13.5 ± 25.1 (1–144) months. The mean preoperative CDVA was 1.21 ± 0.87 log MAR units. At the 1-postoperative visit, the mean CDVA improved ($P < 0.001$) to 0.60 ± 0.56 log MAR units and was 0.66 ± 0.64 at the last follow-up ($P < 0.001$). The difference between CDVA at 1 and at the last follow-up visit was statistically not significant ($P = 0.75$). The proportion of patients with improvement in visual acuity is given in Table 1. Following surgery, 111 (84.1%) eyes had CDVA 20/200 or better, of whom 44 (36.4%) eyes achieved a vision of 20/40 or better [Table 1]. The gain in postoperative vision by at least 1-line or more of Snellen's acuity was seen in 122 (92.4%) eyes, and a loss was seen in 3 (2.4%) eyes [Fig. 1]. Following surgery, 32 (24.2%) patients improved by 10 lines or more. The loss in visual acuity at 1 in one eye was due to acute anterior

Table 1: Corrected distant visual acuity (CDVA) before and after cataract surgery

Grade of CDVA	Preoperative	Postoperative 1 month	Postoperative at last follow-up visit
20/40 or better	8 (6.1)	48 (36.4)	48 (36.4)
20/50-20/200	64 (48.5)	63 (47.7)	58 (43.9)
Less than 20/200	60 (45.4)	21 (15.9)	26 (19.7)

Numbers within parentheses indicate percentages

Table 2: Vision impairment in patients (n=103) before and after surgery

Category	Before surgery Number (percent)	After surgery Number (percent)
No vision impairment	17 (16.5)	42 (40.8)
Mild vision impairment	25 (24.3)	32 (31.1)
Moderate vision impairment	27 (26.2)	18 (17.5)
Severe vision impairment	7 (6.8)	3 (2.9)
Blindness	27 (26.2)	8 (7.8)

uveitis that recovered after prolonged treatment with topical corticosteroids, and CDVA improved to 20/50. No cause could be attributed to the other 2 patients.

The improvements in *vision impairment* after surgery are given in Table 2. There was improvement across all the categories. For example, before surgery, 27 (26.2%) patients were classified as *blind*. Following surgery, nine (33.3%) patients in this category were re-classified as *moderate vision impairment*, five (18.5%) patients as *mild vision impairment*, and four (14.8%) as *no vision impairment* [Table 3]. Only eight (29.6%) patients remained in the *blind* category and one (3.7%) patient in the *severe vision impairment* category.

Complications: Intraoperative complications included zonular dialysis in four (3%) eyes and posterior capsule rupture in two (1.5%) eyes. Postoperative complications were posterior capsule opacification in 22 (16.7%) eyes, cystoid macular edema in 6 (4.5%) eyes, foveal thinning in 33 (25%) eyes, optic atrophy in 58 (43.9%) eyes, and postoperative uveitis in 5 (3.8%) eyes.

Prognostic factors: A good outcome (CDVA 20/200 or better) was observed in 111 (84.1%) eyes and poor outcome (CDVA less than 20/200) in 21 (15.9%) eyes. Preoperative CDVA (in log MAR units) was better in patients who had shorter symptom duration (Spearman’s rho = 0.300, $P < 0.0001$). Preoperative CDVA also correlated strongly with postoperative CDVA (Spearman’s rho = 0.684, $P < 0.0001$). Binary logistic regression analysis identified preoperative CDVA to be significantly (odds ratio: 6.1 [95% confidence interval: 2.9–13.0], $P < 0.0001$) associated with poor outcomes. Age (odds ratio: 1.0 [95% confidence interval: 0.96–1.01], $P < 0.695$) and symptom duration (odds ratio: 1.0 [95% confidence interval: 0.99–1.0], $P < 0.215$) showed no such associations. Reduced central macular thickness was significantly associated with poor outcomes (odds ratio: 3.5 [95% confidence interval: 1.3–9.2], $P = 0.011$).

Discussion

Our study comprises the largest cohort of RP patients undergoing cataract surgery in a developing country. Our

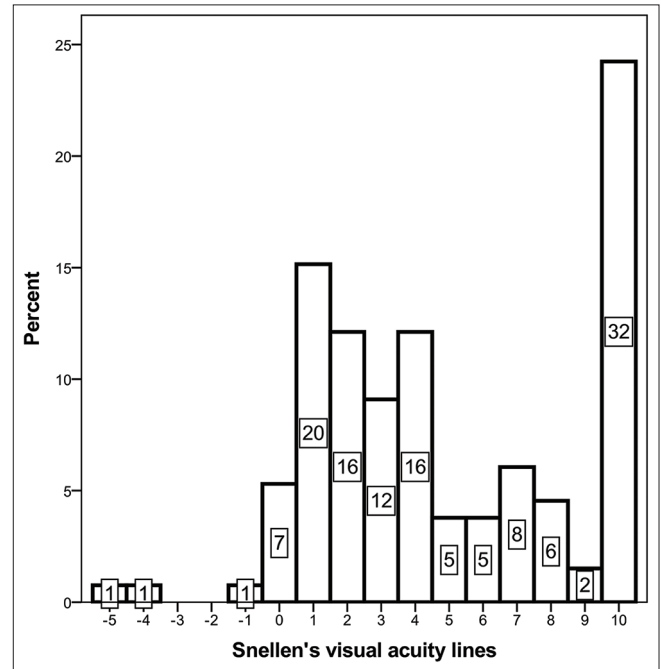


Figure 1: Postoperative improvement in lines of visual acuity as measured in a log MAR visual acuity chart (Category 10 includes improvement by 10 or more lines)

analysis indicated an overall improvement in vision following cataract surgery across all categories of *vision impairment* and *blindness*. This was more remarkable in those who were blind or severely vision impaired before surgery. There was a threefold reduction in patients in the *blind* category, and a twofold reduction in the *severe vision impairment* category after cataract removal, which emphasizes the beneficial effect of surgery.

Nearly half of our patients belonged to the poor economic section of society. This underscores the fact that the study was set in a developing country. Most of our patients were diagnosed with RP for the first time, despite having visual symptoms for a considerable period. Only a few reported night blindness. Although night blindness may be masked because of widespread use of electrical illumination,^[21] the delayed presentation and diagnosis reflects on the still existing barriers to eye care in India. The predominant presence of nuclear sclerosis type of cataract in our study differs from other reports,^[7,10-12,14,15] where posterior subcapsular cataract is more common. This is due to chronic exposure to bright sunlight during outdoor activities in our tropical climate. Low-grade inflammation may be the cause of posterior sub-capsular cataract.^[22] The age of presentation in western studies was 47.0–52.4 years,^[7,10-12,14] and in Asian studies 59.2–62.6 years.^[13,15] Our patients presented nearly a decade earlier than the patients in Asian studies. This may be due to genetic and racial

Table 3: Improvement in different categories of vision impairment after cataract surgery

Before surgery		After surgery	
Category	Number	Category	Number (percent)
No vision impairment	17	No vision impairment	17 (100)
Mild vision impairment	25	No vision impairment	14 (56)
		Mild vision impairment	10 (40)
		Moderate vision impairment	1 (4)
Moderate vision impairment	27	No vision impairment	6 (22.2)
		Mild vision impairment	14 (51.9)
		Moderate vision impairment	7 (25.9)
Severe vision impairment	7	No vision impairment	1 (14.3)
		Mild vision impairment	3 (42.9)
		Moderate vision impairment	1 (14.3)
		Severe vision impairment	2 (28.6)
Blind	27	No vision impairment	4 (14.8)
		Mild vision impairment	5 (18.5)
		Moderate vision impairment	9 (33.3)
		Severe vision impairment	1 (3.7)
		Blind	8 (29.6)

differences.^[13,15] However, the younger age of presentation specially in individuals in their fifth and sixth decades of life who are economically more productive, has a far-reaching socio-economic adverse effect on the individual and the family, which is expected to be alleviated by cataract surgery.

The gain in vision amongst our patients after surgery was similar to the other studies.^[1,7-13] In our study, 36.4% of patients achieved CDVA 20/40 and most of the eyes (92.4%) had improved by at least 1-line of Snellen's acuity, and in only a few eyes (2.4%) visual acuity had worsened. Jackson *et al.*, in a large series of 142 eyes, reported improvement in 77% eyes, no change in 20.5% eyes, and worsening in 2.5% eyes.^[10] In another study, Dikopf *et al.*, reported improvement in postoperative visual acuity in 87.5% of eyes undergoing phacoemulsification.^[11] The improvement in vision was more marked in those who had preoperative visual acuity 20/40-20/200 and was less in those who had vision worse than 20/400. There are only a few studies where the postoperative outcomes have been reported to be less than satisfactory. Bayyoud *et al.* reported a worsening of visual acuity in 12% eyes and no change in 37% eyes after surgery.^[14] In approximately 50% of their patients, cataract surgery was complicated, and required a capsular supporting device. It was only in this particular group that the postoperative visual outcome was poor. In comparison, we had fewer intraoperative complications in our patients. Yoshida *et al.* reported no change in vision in 30/56 (53.6%) eyes following surgery in their study.^[15] The mean age of their patients was a decade older (62.6 years) than ours, and worsening photoreceptor function was the main reason for their poor outcome.

Automated perimetry, OCT, and electroretinography are useful tools to assess and monitor retinal function in RP patients. They have been used extensively in the west to prognosticate visual outcomes after surgery.^[15,23-25] In our study, we identified reduced central macular thickness in OCT as a risk factor for poor visual outcomes. Macular thinning indicates deteriorating photoreceptor activity and central retinal function.^[21] We did not routinely perform these tests in the preoperative workup, because all these tests have high variability and poor reliability

in the presence of dense cataract.^[25] They also increase the costs, a constraint in developing economies. We identified preoperative visual acuity to be an important prognostic factor. Those with better preoperative visual acuity had a better outcome. A contrary view can be found in the study by Dikopf *et al.*, who reported that preoperative visual acuity correlated poorly with postoperative results. This is because patients in their study had more extensive retinal involvement, whereas the severity of lenticular changes was less, which was the opposite in our patients.

Although we encountered certain intraoperative complications, most of these could be managed adequately. Postoperatively, cystoid macular edema or posterior capsule opacification was also less in our patients compared to other studies.^[7,10-15] As OCT was not performed routinely in all patients, subclinical cystoid macular edema may have been missed. The short follow-up period in many patients may be the reason for detecting a lesser number of eyes with posterior capsule opacification. Another limitation was the lack of pedigree charting in many of our patients, and we could not analyze the effect of inheritance pattern on visual outcomes. The large cohort from a developing world setting, clinical features which differ from studies published from western countries, and evaluation of *vision impairment* and its improvement, which had not been explored in previous studies, are some of the strengths of the present study. The identification of a clinical parameter (preoperative CDVA) as a prognostic factor is advantageous in limited-resource settings where other expensive investigations like OCT cannot be routinely performed.

Conclusion

In conclusion, our study shows that visual acuity significantly improves after cataract surgery in most patients with RP. The burden of *vision impairment* and *blindness* had significantly reduced after surgery, and the improvement was more marked in patients with *more severe vision impairment*. The surgery was safe, and outcomes did not differ between eyes undergoing phacoemulsification or manual small incision cataract surgery.

Patients presenting early with good preoperative visual acuity are likely to achieve a better postoperative visual outcome. A reduced foveal thickness was a prognostic factor for poor visual outcomes.

Financial support and sponsorship

Nil.

Conflicts of interest

There are no conflicts of interest.

References

- Knapp A. Cataract in retinitis pigmentosa; its pathology and treatment. *Trans Am Ophthalmol Soc* 1918;16:59-64.
- Heckenlively J. The frequency of posterior subcapsular cataract in the hereditary retinal degenerations. *Am J Ophthalmol* 1982;93:733-8.
- Pruett RC. Retinitis pigmentosa: Clinical observations and correlations. *Trans Am Acad Ophthalmol Soc* 1983;81:693-735.
- Fishman GA, Anderson RJ, Lourenco P. Prevalence of posterior subcapsular lens opacities in patients with retinitis pigmentosa. *Br J Ophthalmol* 1985;69:263-6.
- Liew G, Strong S, Bradley P, Severn P, Moore AT, Webster AR, *et al.* Prevalence of cystoid macular oedema, epiretinal membrane and cataract in retinitis pigmentosa. *Br J Ophthalmol* 2019;103:1163-6.
- Oomachi K, Ogata K, Sugawara T, Hagiwara A, Hata A, Yamamoto S. Evaluation of contrast visual acuity in patients with retinitis pigmentosa. *Clin Ophthalmol* 2011;5:1459-63.
- Bastek JV, Heckenlively JR, Straatsma BR. Cataract surgery in retinitis pigmentosa patients. *Ophthalmology* 1982;89:880-4.
- Newsome DA, Stark WJ, Maumenee IH. Cataract extraction and intraocular lens implantation in patients with retinitis pigmentosa and Usher's syndrome. *Arch Ophthalmol* 1986;104:852-4.
- Reccia R, Scala A, Bosone G. Posterior chamber intraocular lens implantation in patients with retinitis pigmentosa. *Doc Ophthalmol* 1989;72:115-8.
- Jackson H, Garway-Heath D, Rosen P, Bird AC, Tuft SJ. Outcome of cataract surgery in patients with retinitis pigmentosa. *Br J Ophthalmol* 2001;85:936-8.
- Dikopf MS, Chow CC, Mieler WF, Tu EY. Cataract extraction outcomes and the prevalence of zonular insufficiency in retinitis pigmentosa. *Am J Ophthalmol* 2013;156:82-8.
- Davies EC, Pineda R. Cataract surgery outcomes and complications in retinal dystrophy patients. *Can J Ophthalmology* 2017;52:543-7.
- Chan TCY, Lam SC, Mohamed S, Wong RLM. Survival analysis of visual improvement after cataract surgery in advanced retinitis pigmentosa. *Eye (Lond)* 2017;31:1747-8.
- Bayyoud T, Bartz-Schmidt KU, Yoeruek E. Long-term clinical results after cataract surgery with and without capsular tension ring in patients with retinitis pigmentosa: A retrospective study. *BMJ Open* 2013;3:e002616.
- Yoshida N, Ikeda Y, Murakami Y, Nakatake S, Fujiwara K, Notomi S, *et al.* Factors affecting visual acuity after cataract surgery in patients with retinitis pigmentosa. *Ophthalmology* 2015;122:903-8.
- Nangia V, Jonas JB, Khare A, Sinha A. Prevalence of retinitis pigmentosa in India: The central India eye and medical study. *Acta Ophthalmol* 2012;90:e649-50.
- Sen P, Bhargava A, George R, Ramesh SV, Hemamalini A, Prema R, *et al.* Prevalence of retinitis pigmentosa in south Indian population aged above 40 years. *Ophthalmic Epidemiol* 2008;15:279-81.
- Grover S, Fishman GA, Alexander KR, Anderson RJ, Derlacki DJ. Visual impairment in patients with retinitis pigmentosa. *Ophthalmology* 1996;103:1593-600.
- Holladay JT. Visual acuity measurements. *J Cataract Refract Surg* 2004;30:287-90.
- Botelho PJ, Johnson LN, Arnold AC. The effect of aspirin on the visual outcome of nonarteritic anterior ischemic optic neuropathy. *Am J Ophthalmol* 1996;121:450-1.
- Hartong DT, Berson EL, Dryja TP. Retinitis pigmentosa. *Lancet* 2006;368:1795-809.
- Fujiwara K, Ikeda Y, Murakami Y, Funatsu J, Nakatake S, Tachibana T, *et al.* Risk factors for posterior subcapsular cataract in retinitis pigmentosa. *Invest Ophthalmol Vis Sci* 2017;58:2534-7.
- Aizawa S, Mitamura Y, Baba T, Hagiwara A, Ogata K, Yamamoto S. Correlation between visual function and photoreceptor inner/outer segment junction in patients with retinitis pigmentosa. *Eye* 2009;23:304-8.
- Oishi A, Nakamura H, Tatsumi I, Sasahara M, Kojima H, Kurimoto M. Optical coherence tomographic pattern and electroretinogram in patients with retinitis pigmentosa. *Eye* 2009;23:299-303.
- Garcia-Martin E, Rodriguez-Mena D, Dolz I, Almarcegui C, Gil-Arribas L, Bambo MP, *et al.* Influence of cataract surgery on optical coherence tomography and neurophysiology measurements in patients with retinitis pigmentosa. *Am J Ophthalmol* 2013;156:293-303.

Commentary: Cataract surgery in retinitis pigmentosa

Retinitis pigmentosa is a group of inherited retinal degenerative diseases resulting from photoreceptor cell death. According to the literature, over 1.5 million individuals suffer from retinitis pigmentosa globally.^[1] The complicated cataract formation is most likely the result of retinitis pigmentosa-related inflammation response. The most common morphologic category is the posterior subcapsular cataract.^[2] Phacoemulsification with intraocular lens (IOL) implantation remains the most preferred method to manage cataracts.

The incidence of intraoperative and postoperative complications following cataract-IOL surgery is higher in retinitis pigmentosa cases. These include intraoperative phototoxic retinal damage, posterior capsular opacification,

capsular contraction syndrome, pseudophakic cystoid macular edema, increased postoperative intraocular pressure, and capsular bag-intraocular lens dislocation. Therefore, a close follow-up is mandatory in these cases to detect and treat postoperative sequelae. It is important to explain in details about the possibility of aforementioned complications. *An informed consent should be taken from each and every case of retinitis pigmentosa undergoing cataract-IOL surgery. These patients should be explained that cataract-IOL surgery will be helpful to improve central vision. The night vision or peripheral vision will not be improved after cataract-IOL surgery.*

Various authors have published their experience of cataract surgery and intraocular lens implantation in retinitis pigmentosa cases. In a retrospective study published in the current issue of the *Indian Journal of Ophthalmology*, Chatterjee and associates^[3] evaluated visual outcomes of cataract surgery in patients with retinitis pigmentosa. This retrospective case series includes