

Letter to the Editor

Neuropathy/intranuclear inclusion bodies in oculopharyngodistal myopathy: A case report



ARTICLE INFO

Keywords

Trinucleotide repeat diseases
 Oculopharyngodistal myopathy
 Neuropathy
 Low-density lipoprotein receptor-related protein 12 gene (*LRP12*)

Dear Editor,

Oculopharyngodistal myopathy (OPDM) is a slowly progressive adult-onset muscle disease characterized by ptosis, ophthalmoparesis, dysphagia, and weakness of the facial, masseter, bulbar, and distal limbs muscles [1]. Ishiura et al. revealed that OPDM is caused by noncoding CGG repeat expansions in the low-density lipoprotein receptor-related protein 12 gene (*LRP12*) [2]. Ishiura et al. also found similar non-coding CGG repeat expansions in two clinically similar conditions: neuronal intranuclear inclusion disease (NIID) and oculopharyngeal myopathy with leukoencephalopathy (OPML), in the *NBPF19* (*NOTCH2NLC*) and *LOC642361/NUTM2B-AS1* genes, respectively [2]. As is the case between NIID and OPML as well as between OPML and OPDM, clinical or pathological similarities between OPDM and NIID are also expected. In fact, the presence of neuronal intranuclear inclusions in OPDM patients has been demonstrated [3,4]. However, the findings in neuromuscular tissues, such as the sural nerve, where biopsies are often performed, are not yet established. Here, we report a genetically confirmed case of OPDM that shared clinicopathological neuromuscular characteristics with NIID (Fig. 1A).

A 70-year-old man without a family history of neuromuscular disease presented with an eight-year history of hoarseness and dysphagia, followed by bilateral ptosis and weakness and atrophy of the muscle of the distal upper limb, as well as paresthesia in the toes of both feet. His past medical history included juvenile baldness, sick sinus syndrome with atrial fibrillation, and bilateral cataracts. Neurological examination revealed limited horizontal eye movements. Further examination revealed a myopathic face with facial muscle atrophy and bilateral ptosis, bilateral muscle weakness in the distal upper extremities, atrophic thenar and hypothenar muscles, and absent deep tendon reflexes in all four extremities. The other examinations revealed normal findings. Laboratory study results were normal, except for an elevated serum creatine kinase level of 339 IU/L. Brain magnetic resonance imaging did not reveal leukoencephalopathy. Computed tomography revealed bilateral partial adipose tissue replacement of the paraspinal and

gastrocnemius muscles. The patient underwent a biopsy of the biceps brachii muscle, which revealed variation in the fiber size, increased number of internalized nuclei, scattered pyknotic nuclear clumps, and occasional atrophic fibers with rimmed vacuoles. No necrotic or inflammatory changes or ragged red fibers were observed.

At age 80 years, he was admitted for heart failure, which improved after diuretic therapy. At this time, he exhibited evident limited eye movements in all directions, bulbar weakness, and distal-predominant muscle atrophy as well as distal paresthesia. The patient had daytime hypercapnia, with a pCO₂ of 52 mmHg on arterial blood gas analysis. His vital capacity by spirometry was 40.1% of the predicted value. Nerve conduction studies disclosed mixed axonal and demyelinating features characterized by reduction of amplitude of motor and sensory action potentials and conduction slowing, which were more prominent in his lower extremities. Needle electromyography disclosed fibrillation potentials and positive sharp waves in the biceps brachii and tibialis anterior muscles. Blood tests did not identify an underlying cause for the neuropathy. To examine the cause of the unexpected symptoms and findings suggesting neuropathy, biopsies of the biceps brachii muscle and sural nerve were performed. The histopathological findings of the muscle were similar to those of his first biopsy (Fig. 1B). Immunohistochemistry revealed a few p62- and ubiquitin-immunoreactive intranuclear inclusions. The sural nerve showed severe axonal loss (Fig. 1C). Even here, p62-immunoreactive intranuclear inclusions in fibroblasts were observed (Fig. 1D). Further, electron microscopy demonstrated intranuclear aggregations consisting of haphazardly arranged filaments of 10- to 15-nm diameter, admixed with granular substances, in the fibroblasts of both biceps brachii muscle and sural nerve (Fig. 1E–F). Subsequently, genetic analysis using repeat-primed polymerase chain reaction and Southern blot demonstrated CGG repeat expansion (106 CGG repeats) in the *LRP12* gene (Fig. 1A). CTG repeat expansion in the *DMPK* gene was 12 and 13, thus, within the normal range.

The patient followed a clinical course typical of OPDM, and

Abbreviations: OPDM, oculopharyngodistal myopathy; LRP12, lipoprotein receptor-related protein 12 gene; NIID, neuronal intranuclear inclusion disease; OPML, oculopharyngeal myopathy with leukoencephalopathy.

<https://doi.org/10.1016/j.ensci.2021.100348>

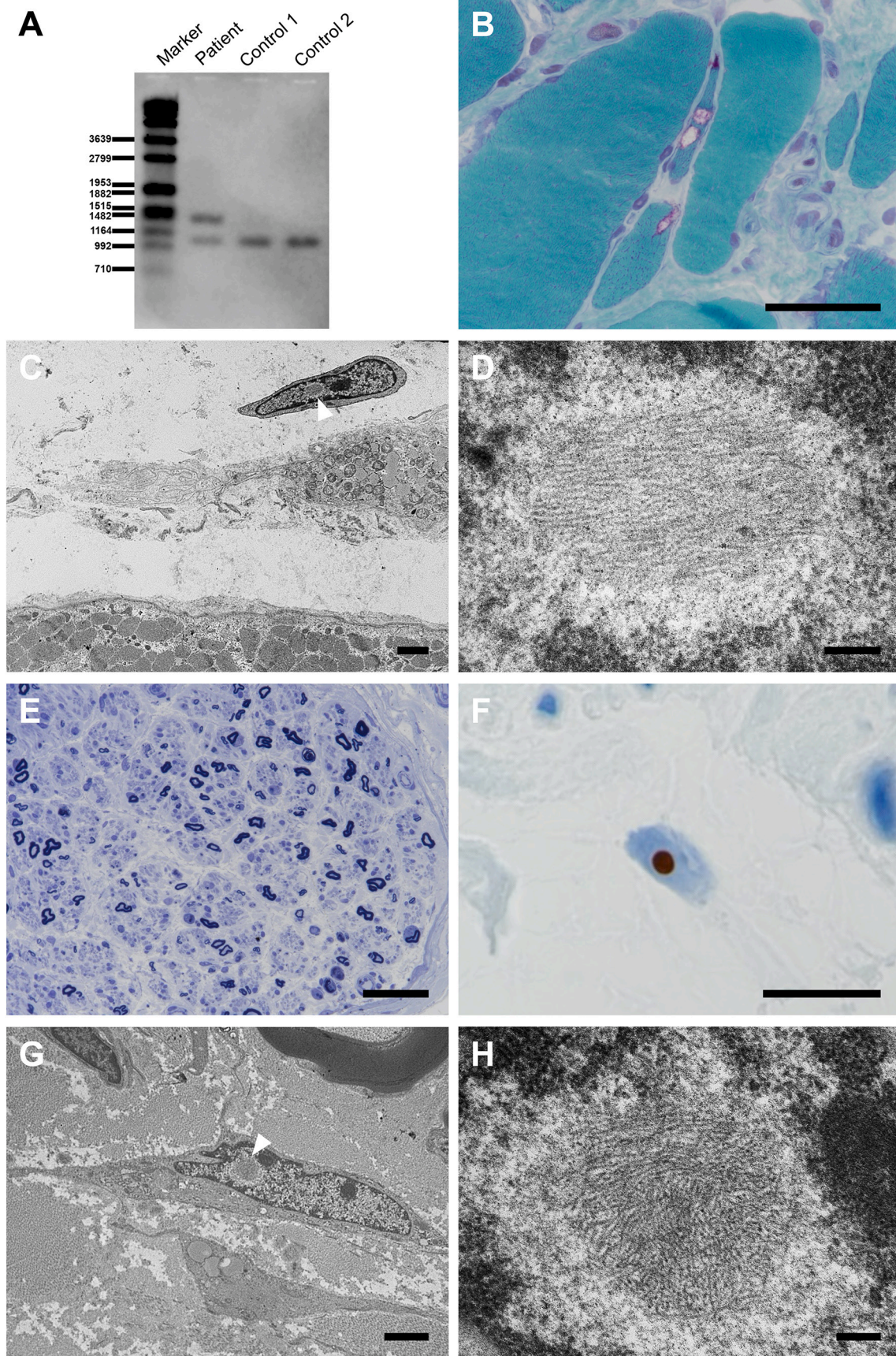
Received 12 April 2021; Received in revised form 19 May 2021; Accepted 1 June 2021

Available online 4 June 2021

2405-6502/© 2021 The Authors.

Published by Elsevier B.V. This is an open access article under the CC BY-NC-ND license

(<http://creativecommons.org/licenses/by-nc-nd/4.0/>).



(caption on next page)

Fig. 1. Southern blot analysis demonstrates CGG repeat expansion in the *LRP12* gene (A). Histopathological findings at age 80 years. In the biceps brachii muscle, modified Gomori trichrome staining demonstrates atrophic fibers with rimmed vacuoles (B). Electron microscopy reveals that a fibroblast adjacent to the degenerated muscles contains intranuclear inclusion (arrowhead) surrounded by amorphous rough halos without limiting membrane (C). High magnification of the area indicated by arrowhead in panel C demonstrates intermingled granulofilamentous profiles (D)]. Toluidine blue staining of the sural nerve indicates severe axonal loss (E) and p62-immunoreactive intranuclear inclusions (F). Electron microscopy shows identical intranuclear inclusions in the fibroblast (arrowhead) of the sural nerve as those in the biceps brachii muscle [low (G) and high (H) magnification]. Scale bars: 50 μ m (B, E); 10 μ m (C, G); 0.2 μ m (D, H). (For interpretation of the references to colour in this figure legend, the reader is referred to the web version of this article.)

developed respiratory complications, which are less frequent but known to occur in OPDM [5]. Moreover, he also developed neuropathy. Histopathological examination revealed findings consistent with OPDM in addition to severe axonal neuropathy and intranuclear inclusions comprising filaments as well as anti p62- and ubiquitin-immunoreactivity.

Neuropathy and intranuclear inclusions are representative features of NIID [6,7]. Considering that OPDM and NIID share similar genetic abnormalities (noncoding CGG repeat expansions), we believe that OPDM can present with neuropathy and intranuclear inclusions. In fact, a previous report of OPDM with genetic validation described OPDM with neuropathy [4]. Going a step further, in the current case, we clinicopathologically confirmed the presence of neuropathy and demonstrated intranuclear inclusion bodies in the fibroblasts of the sural nerve. The current case also showed intranuclear inclusions in the fibroblasts of the biceps brachii muscle. The presence of such inclusions should also be noted even in the muscle biopsies for OPDM.

In conclusion, our report of genetically confirmed OPDM showed that OPDM could share both genetic and clinicopathological characteristics of neuropathy with NIID. We suggest that neuropathy and intranuclear inclusions should be checked with more focus when examining OPDM cases.

Contributors

TM analyzed and interpreted the data and drafted and revised the manuscript. YS and SM designed and conceptualized the study and analyzed and interpreted the data. TK and MH contributed clinical data equitation and analyzed and interpreted the data. MO, AI, and IN performed genetic analyses and interpreted the data. FH, TA, and AK analyzed and interpreted the data. All authors read and approved the final manuscript.

Declarations of Competing Interest

The authors report no disclosures.

Study funding

This work was supported by Grants-in-Aid from the Research Committee of CNS Degenerative Diseases, Research on Policy Planning and Evaluation for Rare and Intractable Diseases, Health, Labour and Welfare Sciences Research Grants, the Ministry of Health, Labour and Welfare, Japan, MEXT/JSPS KAKENHI Grant Number JP16H06277 (SM), AMED under Grant Number JP18dm0107103 (YS, SM) and JP20ek0109490h0001 (IN), Intramural Research Grant (2–5 and 29–4 to IN; 2–5 and 30–9 to AI) for Neurological and Psychiatric Institutes of NCNP, and Joint Usage and Joint Research Programs, the Institute of Advanced Medical Sciences, Tokushima University (2020, 2A19 to AI). The funding bodies did not play any role in the design of the study, the collection, analysis, and interpretation of data, or the writing of the manuscript.

Acknowledgements

The authors would like to thank Dr. Narihiro Minami for the genetic analysis of *DMPK*, Mr. Yutaka Koga, Ms. Mieko Harada, Ms. Kyoko Okamoto, Ms. Nobuko Naoi, and Ms. Sachiko Imai for providing

technical assistance.

References

- [1] E. Satoyoshi, M. Kinoshita, Oculopharyngodistal myopathy, *Arch Neurol* 34 (1977) 89–92, <https://doi.org/10.1001/archneur.1977.00500140043007>.
- [2] H. Ishiura, S. Shibata, J. Yoshimura, Y. Suzuki, W. Qu, K. Doi, M.A. Almansour, J. K. Kikuchi, M. Taira, J. Mitsui, Y. Takahashi, Y. Ichikawa, T. Mano, A. Iwata, Y. Harigaya, M.K. Matsukawa, T. Matsukawa, M. Tanaka, Y. Shiota, R. Ohtomo, H. Kowa, H. Date, A. Mitsue, H. Hatsuta, S. Morimoto, S. Murayama, Y. Shio, Y. Saito, A. Mitsutake, M. Kawai, T. Sasaki, Y. Sugiyama, M. Hamada, G. Ohtomo, Y. Terao, Y. Nakazato, A. Takeda, Y. Sakiyama, Y. Umeda-Kameyama, J. Shinmi, K. Ogata, Y. Kohno, S.Y. Lim, A.H. Tan, J. Shimizu, J. Goto, I. Nishino, T. Toda, S. Morishita, S. Tsuji, Noncoding CGG repeat expansions in neuronal intranuclear inclusion disease, oculopharyngodistal myopathy and an overlapping disease, *Nat. Genet.* 51 (2019) 1222–1232, <https://doi.org/10.1038/s41588-019-0458-z>.
- [3] R. Saito, H. Shimizu, T. Miura, N. Hara, N. Mezaki, Y. Higuchi, A. Miyashita, I. Kawachi, K. Sanpei, Y. Honma, O. Onodera, T. Ikeuchi, A. Kakita, Oculopharyngodistal myopathy with coexisting histology of systemic neuronal intranuclear inclusion disease: Clinicopathologic features of an autopsied patient harboring CGG repeat expansions in *LRP12*, *Acta Neuropathol Commun* 8 (2020) 75, <https://doi.org/10.1186/s40478-020-00945-2>.
- [4] M. Ogasawara, A. Iida, T. Kumutpongpanich, A. Ozaki, Y. Oya, H. Konishi, A. Nakamura, R. Abe, H. Takai, R. Hanajima, H. Doi, F. Tanaka, H. Nakamura, I. Nonaka, Z. Wang, S. Hayashi, S. Noguchi, I. Nishino, CGG expansion in *NOTCH2NL* is associated with oculopharyngodistal myopathy with neurological manifestations, *Acta Neuropathol Commun* 8 (2020) 204, <https://doi.org/10.1186/s40478-020-01084-4>.
- [5] H. Durmus, S.H. Laval, F. Deymeier, Y. Parman, E. Kiyani, M. Gokyigit, C. Ertekin, I. Ercan, S. Solakoglu, V. Karcagi, V. Straub, K. Bushby, H. Lochmuller, P. Serdaroglu-Oflazer, Oculopharyngodistal myopathy is a distinct entity: clinical and genetic features of 47 patients, *Neurology*. 76 (2011) 227–235, <https://doi.org/10.1212/WNL.0b013e318207b043>.
- [6] J. Sone, K. Mori, T. Inagaki, R. Katsumata, S. Takagi, S. Yokoi, K. Araki, T. Kato, T. Nakamura, H. Koike, H. Takashima, A. Hashiguchi, Y. Kohno, T. Kurashige, M. Kuriyama, Y. Takiyama, M. Tsuchiya, N. Kitagawa, M. Kawamoto, H. Yoshimura, Y. Suto, H. Nakayasu, N. Uehara, H. Sugiyama, M. Takahashi, N. Kokubun, T. Konno, M. Katsuno, F. Tanaka, Y. Iwasaki, M. Yoshida, G. Sobue, Clinicopathological features of adult-onset neuronal intranuclear inclusion disease, *Brain* 139 (2016) 3170–3186, <https://doi.org/10.1093/brain/aww249>.
- [7] S. Morimoto, H. Hatsuta, T. Komiya, K. Kanemaru, A.M. Tokumaru, S. Murayama, Simultaneous skin-nerve-muscle biopsy and abnormal mitochondrial inclusions in intranuclear hyaline inclusion body disease, *J Neurol Sci* 372 (2017) 447–449, <https://doi.org/10.1016/j.jns.2016.10.042>.

Tomoyasu Matsubara^a, Yuko Saito^a, Takashi Kurashige^{b,1},
 Mana Higashihara^b, Fumio Hasegawa^a, Masashi Ogasawara^{c,d},
 Aritoshi Iida^d, Ichizo Nishino^{c,d}, Tadashi Adachi^{a,2}, Akatsuki Kubota^e,
 Shigeo Murayama^{a,b,f,*}

^a Department of Neuropathology (Brain Bank for Aging Research), Tokyo Metropolitan Geriatric Hospital & Institute of Gerontology (TMGHIG), Tokyo, Japan

^b Department of Neurology, TMGHIG, Tokyo, Japan

^c Department of Neuromuscular Research, National Institute of Neuroscience, National Center of Neurology and Psychiatry (NCNP), Tokyo, Japan

^d Medical Genome Center, NCNP, Tokyo, Japan

^e Department of Neurology, Graduate School of Medicine, The University of Tokyo, Tokyo, Japan

^f United Graduate School of Child Development, Osaka University, (Brain Bank for Neurodevelopmental, Neurological and Psychiatric Disorders), Osaka, Japan

* Corresponding author at: Department of Neurology and Neuropathology (Brain Bank for Aging Research), Tokyo Metropolitan Geriatric Hospital & Institute of Gerontology, 35-2 Sakae-cho, Itabashi-ku, Tokyo 173-0015, Japan.

E-mail addresses: tomoyasu_matsubara@tmghig.jp (T. Matsubara), yukosm@bbarjp.net (Y. Saito), takashi-kurashige@hiroshima-u.ac.jp (T. Kurashige), mana_higashihara@tmghig.jp (M. Higashihara), f_hasega@tmig.or.jp (F. Hasegawa), masashi.o0611@ncnp.go.jp (M.

Ogasawara), iidaa@ncnp.go.jp (A. Iida), nishino@ncnp.go.jp (I. Nishino), adachi8@med.tottori-u.ac.jp (T. Adachi), akatsuki-tky@umin.net (A. Kubota), smurayam@bbarjp.net (S. Murayama).

¹ Current affiliation: Department of Neurology, National Hospital Organization Kure Medical Center and Chugoku Cancer Center, Hiroshima, Japan

² Current affiliation: Division of Neuropathology, Department of Brain and Neurosciences, Faculty of Medicine, Tottori University, Tottori, Japan