

Place of intravitreal dexamethasone implant in the treatment armamentarium of diabetic macular edema

Omer Karti, Ali Osman Saatci

ORCID number: Omer Karti 0000-0001-5085-0079; Ali Osman Saatci 0000-0001-6848-7239.

Author contributions: Karti O and Saatci AO contributed to the conception of the paper, literature review, critical revision, and approval of the final version.

Conflict-of-interest statement: The authors declare no conflicts of interest.

Open-Access: This article is an open-access article that was selected by an in-house editor and fully peer-reviewed by external reviewers. It is distributed in accordance with the Creative Commons Attribution NonCommercial (CC BY-NC 4.0) license, which permits others to distribute, remix, adapt, build upon this work non-commercially, and license their derivative works on different terms, provided the original work is properly cited and the use is non-commercial. See: <http://creativecommons.org/licenses/by-nc/4.0/>

Manuscript source: Invited manuscript

Specialty type: Ophthalmology

Country/Territory of origin: Turkey

Peer-review report's scientific quality classification

Omer Karti, Department of Ophthalmology, İzmir Democracy University, İzmir 35330, Turkey

Ali Osman Saatci, Department of Ophthalmology, Dokuz Eylül University, İzmir 35330, Turkey

Corresponding author: Ali Osman Saatci, MD, Professor, Department of Ophthalmology, Dokuz Eylül University, İnciraltı Mahallesi Mithatpaşa cad. No. 1606 Balçova, İzmir 35330, Turkey. osman.saatci@yahoo.com

Abstract

Diabetic macular edema (DME) is a very important and well-known cause of visual loss in diabetics. Blood-retina barrier disruption and consequent intraretinal fluid accumulation may lead to retinal thickening at the posterior pole namely DME. Even though it is not clearly understood, current evidence suggests that chronic low-grade inflammation characterized with various cytokines has a major role in the occurrence of DME. Clinical trials are continuously shaping our treatment approaches for the eyes with DME. Today, vascular endothelial growth factor (VEGF) inhibitor and steroid administrations are the main alternatives in DME treatment. Dexamethasone (DEX) implant (Ozurdex® Allergan, Inc., Irvine, CA, United States) was approved by the United States Food & Drug Administration in 2014 for DME treatment. The implant is made up of a biodegradable solid copolymer that is broken down by releasing its active ingredient into the vitreous cavity over time. Biphasic release feature of this sustained-release drug delivery system ensures its efficacy for up to 6 mo with an acceptable and manageable safety profile. DEX implant provides a favorable anatomical and functional outcome in DME as shown in several randomized-controlled studies but has a relatively higher ocular side-effect profile such as increased risk of cataract formation and raised intraocular pressure when compared to the gold standard anti-VEGF agents. Thus, DEX implant becomes the second-line treatment option demonstrating inadequate clinical response to anti-VEGF therapy. However, it can be preferred as the first-line treatment in vitrectomized and pseudophakic eyes. Even in some selected conditions DEX implant is favored over anti-VEGF agents where the use of VEGF-inhibitors is either inappropriate or contraindicated such as the patients with a recent history of a major cardiovascular or cerebrovascular event, pregnancy and noncompliant to frequent visits. This mini-review briefly overviews the efficacy, safety profile and complications of DEX implant and summarizes the outcome of DEX implant administration in major clinical studies on DME treatment.

Grade A (Excellent): 0
 Grade B (Very good): B, B, B
 Grade C (Good): 0
 Grade D (Fair): 0
 Grade E (Poor): 0

Received: December 27, 2020

Peer-review started: December 27, 2020

First decision: April 20, 2021

Revised: April 25, 2021

Accepted: July 7, 2021

Article in press: July 7, 2021

Published online: August 15, 2021

P-Reviewer: El-Sayyad HI, Lee SJ, Nicoara SD

S-Editor: Liu M

L-Editor: Filipodia

P-Editor: Ma YJ



Key Words: Dexamethasone implant; Diabetic macular edema; Diabetic retinopathy; Drug-delivery system; Glaucoma; Pharmacotherapy

©The Author(s) 2021. Published by Baishideng Publishing Group Inc. All rights reserved.

Core Tip: Administration of dexamethasone (DEX) implant is among the main therapeutic alternatives for treating the diabetic macular edema (DME). Though DEX implant provides a long-standing anatomic and visual improvement, implant induced cataract progression and intraocular pressure elevation limit its clinical use as the first-line treatment but DEX implant can sometimes be the preferred option in previously vitrectomized eyes, pseudophakic eyes, and in some specific conditions where the use of vascular endothelial growth factor inhibitors is either contraindicated or suboptimal. In this mini-review, we overviewed the randomized-controlled trials, real-life clinical experiences, and meta-analyses on DEX implant treatment in DME.

Citation: Karti O, Saatci AO. Place of intravitreal dexamethasone implant in the treatment armamentarium of diabetic macular edema. *World J Diabetes* 2021; 12(8): 1220-1232

URL: <https://www.wjgnet.com/1948-9358/full/v12/i8/1220.htm>

DOI: <https://dx.doi.org/10.4239/wjd.v12.i8.1220>

INTRODUCTION

Diabetic macular edema (DME) is a common cause of vision loss in the working-age population suffering from diabetes mellitus (DM) and characterized by retinal thickening at the posterior pole, intraretinal and/or subretinal fluid accumulation due to hyperpermeable retinal vasculature and microenvironmental alterations[1-3]. DME may occur at any stage of diabetic retinopathy (DR) varying from mild non-proliferative to proliferative DR and is often closely associated with systemic and ocular risk factors. Long disease duration, elevated systolic blood pressure and high HbA1c level are among the systemic risk factors whereas main ocular risk factor is the severity of DR[3]. Prevalence of DME varies between 2.7% and 11.1% among the patients having DR and the prevalence is affected by the type of DM, race, ethnicity and the disease duration[4-9]. Patients with a longer duration of diabetes have a higher prevalence of DME. It is estimated that 20% of patients who have diabetes for more than 10 years and 30% of patients having diabetes for more than 25 years will likely develop DME [10].

Although the exact molecular mechanisms remain unclear, building evidence has indicated the role of inflammation and angiogenesis in its pathogenesis. However, the sequence of the pathophysiological events is quite complex and not still fully understood. Chronic hyperglycemia is the main culprit initiating the pathologic process by triggering the endothelial dysfunction and subsequent blood-retina barrier disruption[11,12]. Capillary basement membrane thickening, pericyte loss, capillary dilation, and increased vascular permeability are the early retinal microvascular abnormalities that stimulate the pro-inflammatory and pro-angiogenic processes in DME[12]. Although vascular endothelial growth factor (VEGF), a potent cytokine and vasopermeability factor, seems to be the key player in the DME, it is definitely not the sole responsible inflammatory cytokine. Moreover, it is still obscure whether increased VEGF production is the cause or consequence of the inflammation or not[11]. Chronic low-grade inflammatory response involves leukostasis, macrophage accumulation and elevation of pro-inflammatory factors (cytokines, chemokines, adhesion molecules and angiogenic factors) such as interleukin (IL)-1 β , IL-6, IL-8, interferon gamma-induced protein 10, stromal cell-derived factor 1, monocyte chemoattractant protein 1, intercellular adhesion molecule-1, vascular cell adhesion molecule-1, VEGF, platelet-derived growth factor, transforming growth factor-beta, placental growth factor, tumor necrosis factor- α , matrix metalloproteinase 1 and 9 and results in blood-retina barrier disruption characterized with damaged endothelial cell junctions and increased vasopermeability. Pathophysiological process and biochemical pathways of DME are illustrated in [Figure 1](#)[3,9-16].

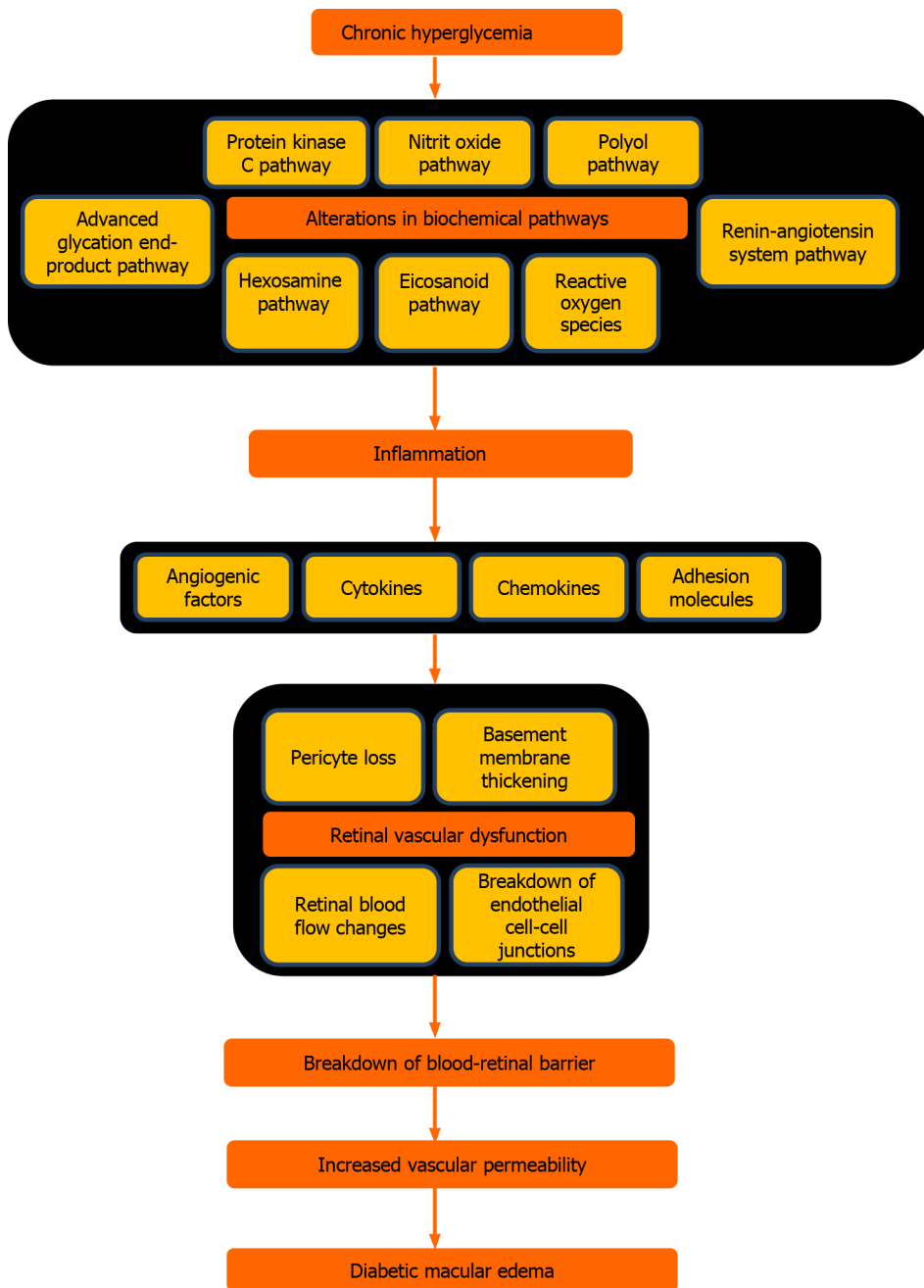


Figure 1 Pathophysiology and biochemical pathways of diabetic macular edema.

Currently, focal or grid laser photocoagulation, intravitreal VEGF-inhibitors, intravitreal steroids and pars plana vitrectomy are among the treatment options for the DME treatment[12]. However, their sequencing is still a matter of debate. Earlier studies have reported that focal laser, where laser beam is directed mainly at the leaking microaneurysms selectively and grid laser photocoagulation where laser beam is administered over the diffuse leakage areas generally reduces the risk of moderate vision loss in patients with fovea-involved DME, but does not usually provide any visual gain but laser treatment does not target at the molecular pathways underlying the formation of DME[10,17-19]. Nowadays, grid laser photocoagulation is very rarely used and focal laser photocoagulation is used only in a minority of patients due to success story of intravitreal therapies. Currently, pharmacotherapy (VEGF-inhibitors and steroids) is considered as a better therapeutic option than the laser therapy and widely employed especially for the center-involved DME as it targets the underlying molecular pathways[10,20,21]. The efficacy of VEGF-inhibitors has already been proven in many major randomized-controlled clinical trials as they provided a better anatomic and visual outcome. For the time being, European society of retina specialists (EURETINA) guideline is recommending the intravitreal anti-VEGF agents as the first-

line therapy for the center involved DME[22]. However, the necessity of frequent even monthly intravitreal injections creates a great inconvenience for the majority of patients especially with persistent or recurrent DME due to their relatively short vitreous half-life and thereby anti-VEGF treatment causes a tremendous burden not only for the patients but also to the caregivers[20]. Physicians generally prefer to switch from one anti-VEGF agent to other or to a DEX implant in patients who do not respond well or show an inadequate response to ongoing anti-VEGF therapy or add laser treatment[21,22].

Intravitreal corticosteroid administration is utilized in eyes with DME as the paramount role of inflammation is evident. Steroids inhibit phospholipase A2 and arachidonic acid pathways and display their effects not only by reducing the VEGF expression but also suppressing the other inflammatory cytokines and thereby blocking the leukostasis and improving the vascular permeability[9,10]. Intravitreal drug administration is very efficacious as higher intraocular drug concentrations can be achieved with infrequent systemic side-effects[10]. Dexamethasone (DEX) phosphate, triamcinolone acetonide (TA), and fluocinolone acetonide (FA) are the three currently available synthetic steroids administered intravitreally and have different glucocorticoid-receptor binding activity and lipophilicity with contrasting relative potencies[9]. DEX, a steroid with potent anti-inflammatory effect, is five-times more effective than the TA, but has a shorter half-life in the vitreous cavity. TA has a lower anti-inflammatory effect but a longer half-life than DEX. Due to short half-life of DEX, TA has long been used for the management of DME intravitreally[9,17].

The sustained-release steroid implants have been developed in conjunction with the technological advances and innovations. Besides their long-acting anti-inflammatory effect, the implants look more advantageous as satisfactory anatomical and functional outcomes can be achieved with significantly fewer number of intravitreal injections[9, 20,22,23]. DEX implant (Ozurdex®; Allergan, Inc., Irvine, CA, United States) is a biodegradable solid polymer drug-delivery system and contains 0.7 mg of DEX. The implant is administered intravitreally by a single-use injection device with a 23-gauge needle[23]. An example of Ozurdex intravitreal injection device is displayed in Figure 2. The drug-delivery system is based on the diffusion principle by releasing DEX into the vitreous cavity in two phases: an initial high-concentration phase, followed by a second low-concentration phase. Biphasic release fashion of the implant can extend its treatment effect up to 6 mo according to its label. However, the maximum effect of DEX implant occurs approximately 2 mo after the injection and then treatment effect slowly wanes[9,20,22,24]. The implant is initially metabolized into lactic and glycolic acid due to its biodegradable property, and then subsequently cleared from the vitreous by being metabolized into water and carbon dioxide[17]. Its effect is also predictable in vitrectomized eyes as vitreous surgery does not affect the pharmacokinetics of the implant. The appearance of a DEX implant in an eye with DME is illustrated in Figure 3.

According to the EURETINA guidelines, steroids have been recommended as a second-line treatment for the DME treatment as they are fraught with a relatively higher ocular side effect profile than the VEGF-inhibitors, and generally preferred in patients with persistent DME who do not respond despite having 3-6 consecutive anti-VEGFs injections[22]. However, steroids can sometimes be preferred as the first-line treatment on some special occasions where VEGF inhibitors are either contraindicated (such as the patients with a history of major cardiovascular event and pregnancy) or expected to achieve suboptimal treatment outcome such as in vitrectomized and non-compliant patients[9,20,22].

While DEX implant is currently the most popular and commonly used corticosteroid implant, FA implant has also been employed for the treatment of chronic DME with a similar anti-inflammatory potency. Iluvien (Alimera Sciences, Aldershot, United Kingdom) is a commercially available, non-biodegradable steroid implant loaded with 0.19 mg FA. The implant is injected into the vitreous cavity with a 25-gauge needle and its effect may extend up to 36 mo. Iluvien is approved by United States Food & Drug Administration (FDA) for the treatment of chronic DME in patients who do not experience steroid induced intraocular pressure (IOP) rise previously based on the fluocinolone acetate for macular edema studies in September 2014. EURETINA guidelines have suggested that DEX implant should be preferred over FA implant. However, the guidelines have also suggested that FA implant may be considered for nonsteroid responder (patients who do not develop steroid-induced IOP elevation) with chronic DME who is unresponsive to other treatments[20-22]. Since TA is off-label and associated with more cataract formation and IOP elevation, EURETINA guidelines have recommended that TA should only be administered when patients cannot reach the FDA approved steroid agents[22].

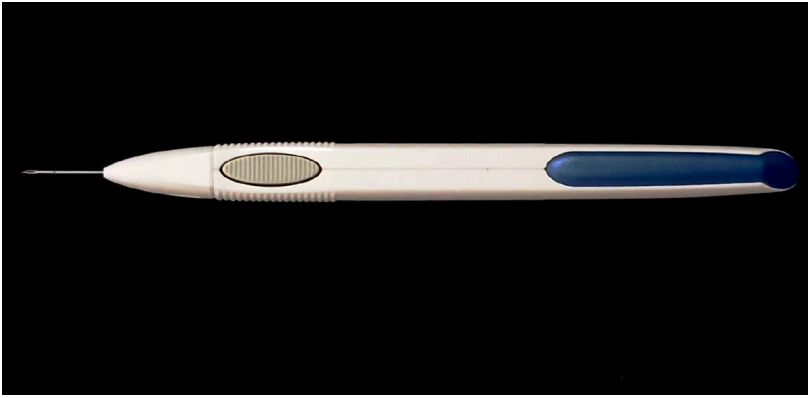


Figure 2 Ozurdex single-use intravitreal injection device with a 23-gauge needle.

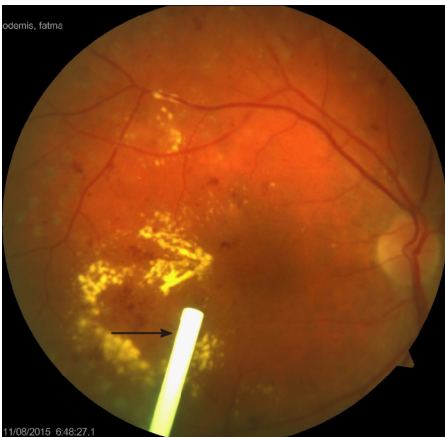

Figure 3 Color fundus picture of a right eye showing the diabetic macular edema related circinate hard exudates, intraretinal hemorrhages and old laser burns together with a Dexamethasone implant located in the vitreous cavity (black-arrow).

MAJOR DEX IMPLANT TRIALS FOR THE TREATMENT OF DME

DEX implant was first approved for retinal vein occlusion treatment by FDA in 2009 and then was approved for the management of DME in 2014[20]. Table 1 summarizes the major clinical studies about DEX implant administration in patients with DME[24-33]. Most of these studies investigated the efficacy and safety profile of DEX implant in phakic and/or pseudophakic patients including previously vitrectomized eyes either as a monotherapy or in combination with laser photocoagulation or VEGF-inhibitors.

MEAD (two randomized, multicenter, masked, sham-controlled, phase III trials with identical protocols) is the registering trial evaluating the safety and efficacy of DEX implant in patients with DME[24]. 1048 patients with center-involved DME were randomized for the administration of 0.7 mg and 0.35 mg of DEX implant or a sham procedure and followed up for 3 years with an average of 4-5 injections. MEAD trials elucidated that the percentage of patients with ≥ 15 -letter improvement in best-corrected visual acuity (BCVA) and mean average reduction in central macular thickness (CMT) at the end of the 3-year follow-up from the baseline was higher in patients treated with 0.7 mg or 0.35 mg of DEX implants than the sham procedure with a favorable safety profile. 0.7 mg DEX implant was approved by the FDA based on the MEAD trials[24].

In a prospective, multicenter, phase II clinical study conducted by Ozurdex CHAMPLAIN study group[26], the efficacy and safety of 0.7 mg DEX implant were evaluated in difficult to treat previously vitrectomized eyes with DME. Statistically significant improvement in BCVA and reduction in CMT was reported following the first injection at 2 and 6 mo[26].

Multicenter Ozurdex[®] assessment for DME (MOZART)[29] study retrospectively investigated the efficacy and safety of 0.7 mg DEX implant in DME patients with visual impairment. The authors concluded that favorable anatomical and functional outcomes were obtained with an acceptable and manageable side effect profile as

Table 1 Summary of major clinical trials of dexamethasone implant in patients with diabetic macular edema

Ref.	Study design, number of patients, mean or median follow-up period after the first injection	Treatment indications	Anatomical and functional outcomes
Boyer <i>et al</i> [24], Ozurdex MEAD study group	Multicenter, randomized, sham-controlled, phase III clinical study	DME	Statistically significantly higher mean CMT reduction from baseline during the study in both DEX implant groups than the sham group
	1048 patients		DEX implant 0.7 mg: -111.6 μ m
	DEX implant 0.7 mg (351)		DEX implant 0.35 mg: -107.9 μ m
	DEX implant 0.35 mg (347)		Sham group: - 41.9 μ m
	Sham (350)		Statistically significant improvement in BVCA with DEX implant at year 3. A significantly greater percentage of patients with a \geq 15-letter improvement in BCVA from baseline in both DEX implant groups than sham at year 3
Haller <i>et al</i> [25]	Multicenter, randomized-controlled clinical trial	DME	A statistically significant improvement in CMT and fluorescein leakage after DEX implant compared with the observation group. Change in CMT from baseline at month 3: 0.7 mg DEX implant: -132 μ m, observation group: +30 μ m
	315 patients		A statistically significantly higher proportion of eyes improving in BCVA (\geq 10 letters) in 0.7 mg DEX implant (26% and 33%) than in observation group (9% and 12%) at months 2 and 3. The difference between the 0.7 mg DEX implant (30%) and observation group (23%) was maintained through month 6, but not statistically significant after month 3
	DEX implant 0.7 mg (105)		
	DEX implant 0.35 mg (105)		
	Observation group (105)		
Boyer <i>et al</i> [26], Ozurdex CHAMPLAIN study group	Multicenter, prospective, open-label, phase II clinical study	DME	Significant decrease in CMT at 2 mo and 6 mo after the first injection. The mean change from baseline CMT (403 μ m): -156 μ m at month 2 and -39 μ m month 6
	55 patients		Significant improvement in BCVA at month 2 and 6. The mean increase in BCVA from baseline (54.5 letters): 6.0 letters at month 2 and 3.0 letters at month 6. 30.4% of patients gained \geq 10 letters in BCVA at month 2
	6 mo		
Callanan <i>et al</i> [27], Ozurdex PLACID study group	Multicenter, randomized, sham-controlled, double-masked, phase II clinical study	DME	Significant decrease in CMT and area of leakage in the combination of DEX implant with the laser than in the laser alone
	253 patients		The percentage of patients who gained \geq 10 letters in BVCA in the combination of DEX implant with laser was significantly higher at week 1 and months 1, 4, and 9 (ranged from 22.2%-30.3%), but not month 12
	DEX implant plus laser (126 patients)		
	Laser alone (127 patients)		
Gillies <i>et al</i> [28], BEVORDEX Study Group	Multicenter, prospective, randomized, phase II study	DME	Greater mean CMT reduction in the DEX group than in bevacizumab
	88 eyes of 61 patients		DEX implant: -187 μ m
	Bevacizumab (42 eyes)		Bevacizumab: -122 μ m
	DEX implant (46 eyes)		The percentage of patients with a \geq 10-letter improvement in BCVA
	12 mo		Bevacizumab: 40% (17 eyes of 42)

			DEX implant: 41% (19 eyes of 46)
Guigou <i>et al</i> [29], MOZART study	Multicenter, retrospective study 74 patients 6 mo	DME	Decrease in mean CMT: 239 μ m at month 2 and 135 μ m at month 6 Improvement in mean BCVA from the baseline: 8.5 letters at month 2 and 7.6 letters at month 6. The percentage of patients who gained greater than 15 letters in BVCA at month 6 was 27%
Singer <i>et al</i> [30], REINFORCE Study	Multicenter, prospective, observational, phase IV clinical study 177 patients (180 eyes) 12 m	DME	Statistically significant decrease in CMT (from -121.2 μ m to -140.3 μ m) from the baseline after the first three DEX injections at all months through month 12 Statistically significant improvement in BCVA (ranged from +7.0 approximate ETDRS letters to +9.1 letters from baseline) after the first three DEX injections. The percentage of patients who gained greater than 15 approximate ETDRS letters in BVCA: 36%
Mello Filho <i>et al</i> [31]	Multicenter, retrospective observational clinical study 282 patients (329 eyes)	DME	Statistically significant reduction in median CMT Baseline: 425 μ m After DEX implant: 270 μ m Statistically significant improvement in median BCVA. Baseline: 0.7 log-MAR/50 letters After DEX implant: 0.3 logMAR/70 letters
Malclès <i>et al</i> [32] RELEX study	128 eyes of 89 patients 16 mo	DME	A statistically significant improvement in CMT Baseline: 451 μ m, month 12: 370 μ m, month 24: 377 μ m, and month 36: 280 μ m Statistically significant improvement in mean BCVA from the baseline (50.5 letters): 54 letters at month 2, 54.7 letters at month 12, 56 letters at month 24 and 60.6 letters at month 36. The percentage of eyes achieving at least a 15-letter improvement from the baseline at month 36: 25.4%
Rosenblatt <i>et al</i> [33], ARTES study group	Multicenter, retrospective, cohort study 287 patients (340 eyes) 1.7 yr	DME	Statistically significant CMT reduction was obtained throughout the first 6 mo. This effect diminished after month 3 but maintained until month 6. Mean change in CMT: -174 μ m Significant improvement in BCVA during the first six months. The percentage of eyes with a \geq 10-letter improvement in BCVA after DEX implant injections: 37.8%

BCVA: Best-corrected visual acuity; CMT: Central macular thickness; DEX: Dexamethasone phosphate; DME: Diabetic macular edema; EDTRS: Early treatment diabetic retinopathy study.

previously published studies[29].

In another study conducted by Ozurdex PLACID group[27], authors evaluated the efficacy of a combination of DEX implant with laser photocoagulation and compared it with the laser photocoagulation alone for the treatment of diffuse DME. They found that the percentage of patients who gained \geq 10 letters in BVCA was significantly greater in the combination group at 1 and 9 mo, but no significant difference was noted between the two treatment arms at 12 mo. Similarly, the reduction in CMT and the leakage area were found significantly greater in the combination group than the group treated with laser photocoagulation alone. They suggested that the combination of DEX implant with laser reduced the vascular leakage and retinal edema and improved the BCVA than the laser treatment in eyes with diffuse DME[27].

The BEVORDEX study[28] compared DEX implant with bevacizumab administration for the center-involving DME and reported the clinical outcome at 12 mo. Although similar rates of improvement in BCVA were achieved in both treatment groups, the anatomical improvement was better in the DEX implant group. Also, improvement in anatomic and visual outcomes was attained with fewer injections in the DEX implant group than the bevacizumab group[28].

REINFORCE[30], a multicenter prospective phase IV clinical study, evaluated the real-world efficacy and safety of 0.7 mg DEX implant in patients with treatment-naïve and previously treated patients. This study reported that DEX implant was effective in improving BCVA and CMT in real-world clinical practice with similar administration frequency and safety profile as in previous reports[30].

In RELDEX study conducted by Malclès *et al*[32], the efficacy and safety profile of DEX implant were evaluated retrospectively in patients with DME. The authors reported that DEX implant administered in real-life situations provided favorable anatomical and visual acuity outcomes with a good safety profile over the 3-year follow-up[32].

In a very recent multicenter study conducted by ARTES study group[33], the real-life efficacy and safety of DEX implant in DME patients were evaluated. Patients were divided into groups as early (< 6 mo) and late (\geq 6 mo) stage DME, naïve and previously treated eyes, and controlled and uncontrolled DM. As a result of this retrospective cohort study comprising of 340 eyes of 287 patients, a statistically significant improvement in BCVA and reduction in CMT was reported after the DEX implant injections. However, its effect started to diminish after the 3 mo but still maintained till 6 mo. In addition, the authors reported that vision improvement was greater in treatment naïve patients than the previously treated patients. CMT reduction was more in patients with controlled DM than in uncontrolled DM. More eyes with early-stage DME gained \geq 10 letters and lost \geq 10 letters than the late-stage DME patients[33].

Castro-Navarro *et al*[34], in another study comparing the naïve and previous treated DME patients demonstrated a significant improvement in BCVA in both naïve and previous treated eyes with the DEX implant treatment. However, the proportion of DME patients who gained \geq 10 letters was significantly greater in the naïve group. Mean CMT was decreased significantly in both groups but a greater mean CMT reduction was reported in the naïve group. The authors also reported favorable outcomes with the DEX implant even in the refractory patients who failed to respond to previous treatments[34].

As mentioned above, VEGF-inhibitors are generally the first-choice in center-involved DME management. However, DME may persist despite continuous anti-VEGF therapy in some patients. A Diabetic Retinopathy Clinical Research Network study Protocol U, a phase II multicenter randomized clinical trial, investigated the efficacy of DEX implant addition into the treatment regimen for the patients with persistent DME who have previously received ranibizumab injections without any clinical improvement. The study included 129 eyes of 116 patients who received at least three injections of ranibizumab before a run-in phase and had persistent DME with a BCVA \leq 20/32. After the run-in phase, patients with persistent DME and poor vision was randomized into one of the two treatment group; a combination group (ranibizumab plus DEX implant, 64 eyes) and a ranibizumab only group (64 eyes). Then the patients were followed up monthly and received continued ranibizumab re-treatment in both groups every 4 wk based on a structured re-treatment protocol. This study demonstrated that there was no significant difference in BCVA between the combination (+ 2.7 letters) and ranibizumab only groups (+ 3 letters) at 6 mo. However, a significant difference between the two groups in terms of anatomical outcome was noted in favor of combination group (-110 μ m *vs* -62 μ m). In addition, the percentage of DME resolution was 52% in the combination group *vs* 31% in the ranibizumab only group. The authors stated that adding DEX implant to the ongoing ranibizumab treatment did not improve BCVA at 6 mo in patients with persistent DME, but CMT was reduced significantly[35].

In a retrospective study, Busch *et al*[36] have assessed the efficacy of DEX implant administered after three consecutive anti-VEGF injections in patients with persistent DME when compared to patients with continuous mono anti-VEGF treatment. The authors found that anatomical outcome was better in the group of patients switched early to DEX implant following three anti-VEGF injections at 12 mo than those patients kept on anti-VEGF injections[36].

Besides the studies reporting the efficacy of DEX implant either alone or sequential use with the VEGF-inhibitors, there are a few studies evaluating the simultaneous use of the DEX implant with an anti-VEGF agent for the DME treatment. These studies suggested that simultaneous intravitreal injections of anti-VEGF and DEX implant might be a superior treatment option than the anti-VEGF treatment alone with a favorable anatomic and visual outcome and an acceptable safety profile[37-39]. However, the size of these studies was small.

META-ANALYSES ON THE DME TREATMENT WITH DEX IMPLANT

In a recent meta-analysis conducted by He *et al*[20] comparing the effectiveness and safety of DEX implant and VEGF-inhibitors in DME treatment, visual improvement is comparable in both DEX implant and VEGF-inhibitor groups. However, better anatomic outcomes were obtained with the DEX implant at 6 mo with fewer injections. The researchers reported that there was no significant difference between the two groups in terms of reduction in CMT at 12 mo and added that the visual benefit was not fully reflected in patients who received DEX implants due to cataract progression. Because of its ocular side effects, the authors suggested that DEX implant can only be recommended as the first-line treatment in selected cases including patients unresponsive to anti-VEGF agents, pseudophakic patients and reluctant patients who did not want to have frequent visits and intravitreal injections[20].

In a current meta-analysis study conducted by Khan *et al*[40], 3859 patients from 15 studies were analyzed to evaluate the efficacy of DEX implant in patients with recalcitrant DME who do not respond despite having at least six previous anti-VEGFs injections. The mean follow-up period of the patients was 6 mo, ranging from 3-36 mo. Significant improvement in mean BCVA (four lines or 20 ETDRS letters) was reported with DEX implant. The authors suggested that clinicians fortunately have a chance to employ many treatment alternatives for DME management nowadays and they concluded that DME patients resistant to anti-VEGF therapy should be recognized and steroid therapy should be considered to reach better anatomic and visual outcomes. Authors noted that the efficacy of the DEX implant will decrease over time and repeated injections may be required to maintain the visual gain[40].

Kodjikian *et al*[41], have reported the efficacy of pharmacotherapy in patients with DME by assessing real-life observational studies and compared anti-VEGF agents with DEX implant. Overall, they have analyzed 63 studies evaluating the efficacy of VEGF-inhibitors (*n*: 32) and DEX implant (*n*: 31). The final BCVA value was 61.2 letters in the DEX implant group and 62 letters in the anti-VEGF group. Additionally, BCVA gains from the baseline were reported as + 9.6 letters in DEX implant group and + 4.7 letters anti-VEGF group. Although the final BVCA was similar in both groups, BCVA gains from the baseline were higher in DEX implant group. This meta-analyses has suggested that gain of more letters with the DEX implant might be partially explained by the lower baseline BCVA in patients receiving the DEX implant or less frequent anti-VEGF injections administered in observational studies than in the interventional studies[41].

EXPERT RECOMMENDATIONS FOR THE MANAGEMENT OF DME WITH DEX IMPLANT IN REAL-LIFE PRACTICE

Recommendations of EURETINA guidelines were based on the randomized-controlled trials, which do not fully reflect the real-life scenarios due to their designs. Experts of several countries have prepared their own consensus documents using a Delphi approach regarding the use of DEX implant for the management of DME in daily practice.

Spanish MOMENTUM-D study group has concluded that DEX implant is particularly beneficial in the DME treatment in patients with a history of major cardiovascular event, vitrectomized patients, pseudophakic patients, non-compliant patients, patients requiring cataract surgery, and patients with substantial inflammatory component. The consensus paper has also recommended that switching to DEX implant should be considered after three anti-VEGF injections[42].

Italian experts have stated that DEX implant has the best ocular tolerance among the other intravitreally administered steroids and should be considered first over TA and FA especially in pseudophakic and vitrectomized patients. According to them, switching to DEX implant should be employed after the loading-phase of anti-VEGF therapy in resistant DME patients. Experts have concluded that pro-re-nata is an appropriate treatment regimen for further DEX implant administrations and the clinicians should not wait for 6 mo for re-treatment[43].

German consensus paper suggested that switching to DEX implant should be performed in patients with inadequate treatment response following 3-6 monthly anti-VEGF injections. They also suggested that the implant might be useful in patients with long-term DME characterized with massive lipid exudates. BCVA, CMT and IOP have been stated to be the major parameters for the re-treatment decision. Similar to other consensus documents and EURETINA guidelines, DEX implant is recommended as

the first-line therapy in pseudophakic patients, reluctant patients who do not want to attend frequent visits and receive frequent injections, and patients with known vascular diseases. They also stated that the implant should not be implemented in both eyes on same day[44].

SAFETY OF DEX IMPLANT ADMINISTRATIONS

DEX implant may cause some undesirable ocular complications during or after the administration[22-50]. Foreign body sensation, eye pain and pruritus, conjunctival hyperemia, conjunctival edema, conjunctival hemorrhage, anterior chamber cell and flare, increased IOP, cataract, vitreous hemorrhage, and myodesopsia are among the reported ocular adverse events[12,24-26]. Retinal tear, retinal detachment, vitreous loss, intralenticular injection of the implant and endophthalmitis have been reported as the rare ocular adverse events associated with any type of intravitreal injection[12, 50]. In addition, DEX implant may migrate into the anterior chamber in aphakic eyes, vitrectomized eyes, eyes with sutured intraocular lens implantation, patients with weak lens zonules or a posterior capsule defect related to a previous complicated cataract surgery[48,49] and cause further ocular complications. Cataract progression and steroid-induced ocular hypertension or glaucoma are the most frequent and important ocular side-effects associated with the implant[47] DEX binds less to the trabecular meshwork and lens as it is less lipophilic than the TA and FA. Understandably, DEX implant is associated with a lower risk of glaucoma and cataract formation. Although the precise mechanism of IOP rise is not fully understood increased aqueous outflow resistance due to structural and biochemical changes in the trabecular meshwork is thought to be the cause for IOP elevation[9,12]. Many studies have been reported different rates of IOP elevation[24-33,46]. An IOP increase of ≥ 10 mmHg was reported between 6.8%-27.7% of the patients[24,25,27,28,30-33,46]. IOP of ≥ 25 mmHg was reported in 6.6%-32% of patients[24-33,46]. Also, IOP of ≥ 35 mmHg was reported in 0.9%-6.6% of patients[24,26,27,30-33,46]. IOP-lowering medication was required in 6.3% and 41.5% of the patients[24,26,27,30,32,33,46]. While 0.9% of the patients in the MEAD study required glaucoma surgery[24,46] some studies reported no need for glaucoma surgery[25-33]. Cataract formation or progression is the most common ocular complication of DEX implant leading to decrease in visual acuity and the need for cataract surgery usually increases after the second year of treatment[12]. This almost inevitable complication is reported between 4% and 67.9% of patients in several manuscripts[24,26,27,28,31,33,46]. Besides ocular adverse events, systemic adverse events such as worsening of hypertension, chest pain, angina, and renal failure have been rarely reported[28].

CONCLUSION

DEX implant can provide visual and anatomical improvement with a fewer number of intravitreal injections in eyes with DME as briefly summarized above. It has a well-accepted efficacy profile in DME treatment but is generally preferred as the second-line treatment option due to its less favorable safety profile than the anti-VEGF agents. On the other hand, it can be a primary option in a selected group of patients such as vitrectomized patients, pseudophakic patients, patients with a recent cerebrovascular or cardiovascular event history and patients who experienced suboptimal treatment benefit with anti-VEGF therapy. Cataract and increased IOP are the most common implant-related ocular adverse events but in most instances they are clinically acceptable and well-manageable. Although combined utilization of the anti-VEGF agents and DEX implant either consecutively or simultaneously is possible it is still not proven whether there is an additional treatment benefit in administering them in combination.

REFERENCES

- 1 **Bandello F**, Battaglia Parodi M, Lanzetta P, Loewenstein A, Massin P, Menchini F, Veritti D. Diabetic Macular Edema. *Dev Ophthalmol* 2017; **58**: 102-138 [PMID: 28351052 DOI: 10.1159/000455277]
- 2 **Chakravarthy U**, Yang Y, Lotery A, Ghanchi F, Bailey C, Holz FG, Downey L, Weber M, Eter N,

- Dugel PU. Clinical evidence of the multifactorial nature of diabetic macular edema. *Retina* 2018; **38**: 343-351 [PMID: 28257378 DOI: 10.1097/IAE.0000000000001555]
- 3 **Browning DJ**, Stewart MW, Lee C. Diabetic macular edema: Evidence-based management. *Indian J Ophthalmol* 2018; **66**: 1736-1750 [PMID: 30451174 DOI: 10.4103/ijo.IJO_1240_18]
 - 4 **Xie XW**, Xu L, Wang YX, Jonas JB. Prevalence and associated factors of diabetic retinopathy. The Beijing Eye Study 2006. *Graefes Arch Clin Exp Ophthalmol* 2008; **246**: 1519-1526 [PMID: 18604548 DOI: 10.1007/s00417-008-0884-6]
 - 5 **Rubino A**, Rousculp MD, Davis K, Wang J, Girach A. Diagnosed diabetic retinopathy in France, Italy, Spain, and the United Kingdom. *Prim Care Diabetes* 2007; **1**: 75-80 [PMID: 18632023 DOI: 10.1016/j.pcd.2007.02.002]
 - 6 **Wong TY**, Klein R, Islam FM, Cotch MF, Folsom AR, Klein BE, Sharrett AR, Shea S. Diabetic retinopathy in a multi-ethnic cohort in the United States. *Am J Ophthalmol* 2006; **141**: 446-455 [PMID: 16490489 DOI: 10.1016/j.ajo.2005.08.063]
 - 7 **Varma R**, Torres M, Peña F, Klein R, Azen SP; Los Angeles Latino Eye Study Group. Prevalence of diabetic retinopathy in adult Latinos: the Los Angeles Latino eye study. *Ophthalmology* 2004; **111**: 1298-1306 [PMID: 15234129 DOI: 10.1016/j.ophtha.2004.03.002]
 - 8 **Eldem B**, Ozdek S, Saatci AO, Ozmert E, Ulay E, Nomak G. Clinical Characteristics of Patients with Newly Diagnosed Diabetic Macular Edema in Turkey: A Real-Life Registry Study-TURK-DEM. *J Ophthalmol* 2017; **2017**: 3596817 [PMID: 28316835 DOI: 10.1155/2017/3596817]
 - 9 **Urbančić M**, Gardašević Topčić I. Dexamethasone implant in the management of diabetic macular edema from clinician's perspective. *Clin Ophthalmol* 2019; **13**: 829-840 [PMID: 31190726 DOI: 10.2147/OPTH.S206769]
 - 10 **Bucolo C**, Gozzo L, Longo L, Mansueto S, Vitale DC, Drago F. Long-term efficacy and safety profile of multiple injections of intravitreal dexamethasone implant to manage diabetic macular edema: A systematic review of real-world studies. *J Pharmacol Sci* 2018; **138**: 219-232 [PMID: 30503676 DOI: 10.1016/j.jphs.2018.11.001]
 - 11 **Romero-Aroca P**, Baget-Bernaldiz M, Pareja-Rios A, Lopez-Galvez M, Navarro-Gil R, Verges R. Diabetic Macular Edema Pathophysiology: Vasogenic versus Inflammatory. *J Diabetes Res* 2016; **2016**: 2156273 [PMID: 27761468 DOI: 10.1155/2016/2156273]
 - 12 **Dugel PU**, Bandello F, Loewenstein A. Dexamethasone intravitreal implant in the treatment of diabetic macular edema. *Clin Ophthalmol* 2015; **9**: 1321-1335 [PMID: 26213460 DOI: 10.2147/OPTH.S79948]
 - 13 **Dong N**, Xu B, Wang B, Chu L. Study of 27 aqueous humor cytokines in patients with type 2 diabetes with or without retinopathy. *Mol Vis* 2013; **19**: 1734-1746 [PMID: 23922491]
 - 14 **Jonas JB**, Jonas RA, Neumaier M, Findeisen P. Cytokine concentration in aqueous humor of eyes with diabetic macular edema. *Retina* 2012; **32**: 2150-2157 [PMID: 22617833 DOI: 10.1097/IAE.0b013e3182576d07]
 - 15 **Boyer DS**, Hopkins JJ, Sorof J, Ehrlich JS. Anti-vascular endothelial growth factor therapy for diabetic macular edema. *Ther Adv Endocrinol Metab* 2013; **4**: 151-169 [PMID: 24324855 DOI: 10.1177/2042018813512360]
 - 16 **Tripathy K**, Sharma YR, R K, Chawla R, Gogia V, Singh SK, Venkatesh P, Vohra R. Recent advances in management of diabetic macular edema. *Curr Diabetes Rev* 2015; **11**: 79-97 [PMID: 25801496 DOI: 10.2174/1573399811999150324120640]
 - 17 **Augustin AJ**, Kuppermann BD, Lanzetta P, Loewenstein A, Li XY, Cui H, Hashad Y, Whitcup SM; Ozurdex MEAD Study Group. Dexamethasone intravitreal implant in previously treated patients with diabetic macular edema: subgroup analysis of the MEAD study. *BMC Ophthalmol* 2015; **15**: 150 [PMID: 26519345 DOI: 10.1186/s12886-015-0148-2]
 - 18 **Photocoagulation for diabetic macular edema**. Early Treatment Diabetic Retinopathy Study report number 1. Early Treatment Diabetic Retinopathy Study research group. *Arch Ophthalmol* 1985; **103**: 1796-1806 [PMID: 2866759]
 - 19 **Diabetic Retinopathy Clinical Research Network**. A randomized trial comparing intravitreal triamcinolone acetonide and focal/grid photocoagulation for diabetic macular edema. *Ophthalmology* 2008; **115**: 1447-1449 [PMID: 18662829 DOI: 10.1016/j.ophtha.2008.06.015]
 - 20 **He Y**, Ren XJ, Hu BJ, Lam WC, Li XR. A meta-analysis of the effect of a dexamethasone intravitreal implant versus intravitreal anti-vascular endothelial growth factor treatment for diabetic macular edema. *BMC Ophthalmol* 2018; **18**: 121 [PMID: 29784048 DOI: 10.1186/s12886-018-0779-1]
 - 21 **Banaee T**, Ashraf M, Conti FF, Singh RP. Switching Anti-VEGF Drugs in the Treatment of Diabetic Macular Edema. *Ophthalmic Surg Lasers Imaging Retina* 2017; **48**: 748-754 [PMID: 28902336 DOI: 10.3928/23258160-20170829-10]
 - 22 **Schmidt-Erfurth U**, Garcia-Arumi J, Bandello F, Berg K, Chakravarthy U, Gerendas BS, Jonas J, Larsen M, Tadayoni R, Loewenstein A. Guidelines for the Management of Diabetic Macular Edema by the European Society of Retina Specialists (EURETINA). *Ophthalmologica* 2017; **237**: 185-222 [PMID: 28423385 DOI: 10.1159/000458539]
 - 23 **Demirel S**, Argo C, Agarwal A, Parriott J, Sepah YJ, Do DV, Nguyen QD. Updates on the Clinical Trials in Diabetic Macular Edema. *Middle East Afr J Ophthalmol* 2016; **23**: 3-12 [PMID: 26957834 DOI: 10.4103/0974-9233.172293]
 - 24 **Boyer DS**, Yoon YH, Belfort R Jr, Bandello F, Maturi RK, Augustin AJ, Li XY, Cui H, Hashad Y, Whitcup SM; Ozurdex MEAD Study Group. Three-year, randomized, sham-controlled trial of dexamethasone intravitreal implant in patients with diabetic macular edema. *Ophthalmology* 2014;

- 121: 1904-1914 [PMID: 24907062 DOI: 10.1016/j.ophtha.2014.04.024]
- 25 **Haller JA**, Kuppermann BD, Blumenkranz MS, Williams GA, Weinberg DV, Chou C, Whitcup SM; Dexamethasone DDS Phase II Study Group. Randomized controlled trial of an intravitreal dexamethasone drug delivery system in patients with diabetic macular edema. *Arch Ophthalmol* 2010; **128**: 289-296 [PMID: 20212197 DOI: 10.1001/archophthalmol.2010.21]
- 26 **Boyer DS**, Faber D, Gupta S, Patel SS, Tabandeh H, Li XY, Liu CC, Lou J, Whitcup SM; Ozurdex CHAMPLAIN Study Group. Dexamethasone intravitreal implant for treatment of diabetic macular edema in vitrectomized patients. *Retina* 2011; **31**: 915-923 [PMID: 21487341 DOI: 10.1097/IAE.0b013e318206d18c]
- 27 **Callanan DG**, Gupta S, Boyer DS, Ciulla TA, Singer MA, Kuppermann BD, Liu CC, Li XY, Hollander DA, Schiffman RM, Whitcup SM; Ozurdex PLACID Study Group. Dexamethasone intravitreal implant in combination with laser photocoagulation for the treatment of diffuse diabetic macular edema. *Ophthalmology* 2013; **120**: 1843-1851 [PMID: 23706947 DOI: 10.1016/j.ophtha.2013.02.018]
- 28 **Gillies MC**, Lim LL, Campain A, Quin GJ, Salem W, Li J, Goodwin S, Aroney C, McAllister IL, Fraser-Bell S. A randomized clinical trial of intravitreal bevacizumab versus intravitreal dexamethasone for diabetic macular edema: the BEVORDEX study. *Ophthalmology* 2014; **121**: 2473-2481 [PMID: 25155371 DOI: 10.1016/j.ophtha.2014.07.002]
- 29 **Guigou S**, Hajjar C, Parrat E, Merite PY, Pommier S, Matonti F, Prost-Magnin O, Meyer F. [Multicenter Ozurdex® assessment for diabetic macular edema: MOZART study]. *J Fr Ophthalmol* 2014; **37**: 480-485 [PMID: 24813119 DOI: 10.1016/j.jfo.2014.03.001]
- 30 **Singer MA**, Dugel PU, Fine HF, Capone A Jr, Maltman J. Real-World Assessment of Dexamethasone Intravitreal Implant in DME: Findings of the Prospective, Multicenter REINFORCE Study. *Ophthalmic Surg Lasers Imaging Retina* 2018; **49**: 425-435 [PMID: 29927470 DOI: 10.3928/23258160-20180601-07]
- 31 **Mello Filho P**, Andrade G, Maia A, Maia M, Biccas Neto L, Muralha Neto A, Moura Brasil O, Minelli E, Dalloul C, Igllicki M. Effectiveness and Safety of Intravitreal Dexamethasone Implant (Ozurdex) in Patients with Diabetic Macular Edema: A Real-World Experience. *Ophthalmologica* 2019; **241**: 9-16 [PMID: 30408801 DOI: 10.1159/000492132]
- 32 **Malclès A**, Dot C, Voirin N, Agard É, Vié AL, Bellocq D, Denis P, Kodjikian L. Real-life study in diabetic macular edema treated with dexamethasone implant: The Reldex Study. *Retina* 2017; **37**: 753-760 [PMID: 27471826 DOI: 10.1097/IAE.0000000000001234]
- 33 **Rosenblatt A**, Udaondo P, Cunha-Vaz J, Sivaprasad S, Bandello F, Lanzetta P, Kodjikian L, Goldstein M, Habet-Wilner Z, Loewenstein A; ARTES Study Group. A Collaborative Retrospective Study on the Efficacy and Safety of Intravitreal Dexamethasone Implant (Ozurdex) in Patients with Diabetic Macular Edema: The European DME Registry Study. *Ophthalmology* 2020; **127**: 377-393 [PMID: 31932090 DOI: 10.1016/j.ophtha.2019.10.005]
- 34 **Castro-Navarro V**, Cervera-Taulet E, Navarro-Palop C, Monferrer-Adsua C, Hernández-Bel L, Montero-Hernández J. Intravitreal dexamethasone implant Ozurdex® in naïve and refractory patients with different subtypes of diabetic macular edema. *BMC Ophthalmol* 2019; **19**: 15 [PMID: 30634940 DOI: 10.1186/s12886-018-1022-9]
- 35 **Maturi RK**, Glassman AR, Liu D, Beck RW, Bhavsar AR, Bressler NM, Jampol LM, Melia M, Punjabi OS, Salehi-Had H, Sun JK; Diabetic Retinopathy Clinical Research Network. Effect of Adding Dexamethasone to Continued Ranibizumab Treatment in Patients With Persistent Diabetic Macular Edema: A DRCR Network Phase 2 Randomized Clinical Trial. *JAMA Ophthalmol* 2018; **136**: 29-38 [PMID: 29127949 DOI: 10.1001/jamaophthalmol.2017.4914]
- 36 **Busch C**, Zur D, Fraser-Bell S, Láins I, Santos AR, Lupidi M, Cagini C, Gabrielle PH, Couturier A, Mané-Tauty V, Giampoli E, Ricci GD, Cebeci Z, Rodríguez-Valdés PJ, Chaikitmongkol V, Amphornphruet A, Hindi I, Agrawal K, Chhablani J, Loewenstein A, Igllicki M, Rehak M; International Retina Group. Shall we stay, or shall we switch? Continued anti-VEGF therapy versus early switch to dexamethasone implant in refractory diabetic macular edema. *Acta Diabetol* 2018; **55**: 789-796 [PMID: 29730822 DOI: 10.1007/s00592-018-1151-x]
- 37 **Kaya M**, Kocak N, Ozturk T, Bolluk V, Ayhan Z, Kaynak S. Intravitreal ranibizumab and dexamethasone implant injections as primary treatment of diabetic macular edema: simultaneously double protocol. *Eye (Lond)* 2021; **35**: 777-785 [PMID: 32398852 DOI: 10.1038/s41433-020-0949-2]
- 38 **de Andrade FL**, Lopes FS, de Andrade GC, Prata TS, Maia A. Simultaneous Therapy with Intravitreal Dexamethasone Implant and Bevacizumab for the Treatment of Macular Edema. *Med Hypothesis Discov Innov Ophthalmol* 2016; **5**: 4-9 [PMID: 28289686]
- 39 **Saatci AO**, Ayhan Z, Engin CD. Simultaneous Intravitreal Ranibizumab and Dexamethasone Implant Administration at the Same Setting in Eyes with Severe Diabetic Macular Edema. *Open j ophthalmol* 2016; **6**: 112-118 [DOI: 10.4236/ojoph.2016.62016]
- 40 **Khan Z**, Kuriakose RK, Khan M, Chin EK, Almeida DR. Efficacy of the Intravitreal Sustained-Release Dexamethasone Implant for Diabetic Macular Edema Refractory to Anti-Vascular Endothelial Growth Factor Therapy: Meta-Analysis and Clinical Implications. *Ophthalmic Surg Lasers Imaging Retina* 2017; **48**: 160-166 [PMID: 28195619 DOI: 10.3928/23258160-20170130-10]
- 41 **Kodjikian L**, Bellocq D, Mathis T. Pharmacological Management of Diabetic Macular Edema in Real-Life Observational Studies. *Biomed Res Int* 2018; **2018**: 8289253 [PMID: 30246026 DOI: 10.1155/2018/8289253]
- 42 **García Layana A**, Adán A, Ascaso FJ, Cabrera F, Donate J, Escobar Barranco JJ, Peralta G, Reyes

- García R, Rodríguez Maqueda M, Ruiz-Moreno JM, Vinagre I; MOMENTUM-D Study Group. Use of intravitreal dexamethasone implants in the treatment of diabetic macular edema: Expert recommendations using a Delphi approach. *Eur J Ophthalmol* 2020; **30**: 1042-1052 [PMID: 31291782 DOI: 10.1177/1120672119861623]
- 43 **Giovannini A**, Parravano M, Ricci F, Bandello F. Management of diabetic macular edema with intravitreal dexamethasone implants: Expert recommendations using a Delphi-based approach. *Eur J Ophthalmol* 2019; **29**: 82-91 [PMID: 29882421 DOI: 10.1177/1120672118781236]
- 44 **Augustin AJ**, Feltgen N, Haritoglou C, Hoerauf H, Maier MM, Mardin CY, Schargus M. [Clinical Decision Making for Treatment of Diabetic Macular Oedema with DEX Implant: a Consensus Paper]. *Klin Monbl Augenheilkd* 2021; **238**: 73-84 [PMID: 31770786 DOI: 10.1055/a-1024-4089]
- 45 **Karti O**, Saatci AO. Intraocular Pressure Changes Following the Administration of Intravitreal Dexamethasone Implant: A Mini -Review. *Int J Ophthalmic Res* 2019; **5**: 302-307 [DOI: 10.17554/j.issn.2409-5680.2019.05.86]
- 46 **Maturi RK**, Pollack A, Uy HS, Varano M, Gomes AM, Li XY, Cui H, Lou J, Hashad Y, Whitcup SM; Ozurdex MEAD Study Group. Intraocular pressure in patients with diabetic macular edema treated with dexamethasone intravitreal implant in the 3-year mead study. *Retina* 2016; **36**: 1143-1152 [PMID: 26871523 DOI: 10.1097/IAE.0000000000001004]
- 47 **Rajesh B**, Zarranz-Ventura J, Fung AT, Busch C, Sahoo NK, Rodriguez-Valdes PJ, Sarao V, Mishra SK, Saatci AO, Udaondo Mirete P, Querques G, Farah ME, Lanzetta P, Arevalo JF, Kodjikian L, Chhablani J; for International Ozurdex Study Group. Safety of 6000 intravitreal dexamethasone implants. *Br J Ophthalmol* 2020; **104**: 39-46 [PMID: 31040132 DOI: 10.1136/bjophthalmol-2019-313991]
- 48 **Kayıkcoğlu Ö**, Doğruya S, Sarıgül C, Mayalı H, Kurt E. Anterior Chamber Migration of Ozurdex Implants. *Turk J Ophthalmol* 2020; **50**: 115-122 [PMID: 32367704 DOI: 10.4274/tjo.galenos.2019.43778]
- 49 **Röck D**, Bartz-Schmidt KU, Röck T. Risk factors for and management of anterior chamber intravitreal dexamethasone implant migration. *BMC Ophthalmol* 2019; **19**: 120 [PMID: 31138164 DOI: 10.1186/s12886-019-1122-1]
- 50 **Sekeroglu MA**, Anayol MA, Koc F, Tirhis H, Ozkan SS, Yilmazbas P. Intralenticular Sustained-Release Dexamethasone Implant: Is It Still Effective on Macular Edema? *Case Rep Ophthalmol* 2016; **7**: 85-89 [PMID: 27293406 DOI: 10.1159/000444163]



Published by **Baishideng Publishing Group Inc**
7041 Koll Center Parkway, Suite 160, Pleasanton, CA 94566, USA

Telephone: +1-925-3991568

E-mail: bpgoffice@wjgnet.com

Help Desk: <https://www.f6publishing.com/helpdesk>

<https://www.wjgnet.com>

