

Images in clinical medicine

High cholesterol in COVID-19 leading to lung consolidation and bronchiectasis

Tasneem Sajjad Burhani,  Waqar Mohsin Naqvi

Corresponding author: Waqar Mohsin Naqvi, Department of Community Health Physiotherapy, Ravi Nair Physiotherapy College, Wardha, Maharashtra, India. waqar.naqvi@dmimsu.edu.in

Received: 22 May 2021 - **Accepted:** 01 Jun 2021 - **Published:** 09 Jun 2021

Keywords: High cholesterol, COVID-19, lung, bronchiectasis

Copyright: Tasneem Sajjad Burhani et al. Pan African Medical Journal (ISSN: 1937-8688). This is an Open Access article distributed under the terms of the Creative Commons Attribution International 4.0 License (<https://creativecommons.org/licenses/by/4.0/>), which permits unrestricted use, distribution, and reproduction in any medium, provided the original work is properly cited.

Cite this article: Tasneem Sajjad Burhani et al. High cholesterol in COVID-19 leading to lung consolidation and bronchiectasis. Pan African Medical Journal. 2021;39(115). 10.11604/pamj.2021.39.115.29961

Available online at: <https://www.panafrican-med-journal.com//content/article/39/115/full>

High cholesterol in COVID-19 leading to lung consolidation and bronchiectasis

Tasneem Sajjad Burhani¹, Waqar Mohsin Naqvi^{1,&}

¹Department of Community Health Physiotherapy, Ravi Nair Physiotherapy College, Wardha, Maharashtra, India

&Corresponding author

Waqar Mohsin Naqvi, Department of Community Health Physiotherapy, Ravi Nair Physiotherapy College, Wardha, Maharashtra, India

Image in medicine

A 60-years-old male with high cholesterol and a Modified Medical Research Council (mMRC) dyspnoea score of 2 was admitted with a history of fever, cough, dyspnoea. Initial chest radiograph (A) showed bronchiectasis in right base with pneumonia in the left base. A diagnosis of COVID-19 was confirmed with positive SARS-CoV-2 RT-PCR on nasal swab. There were some typical findings on CT images. According to the CT images (B), the case was classified as of stage I consolidation with multiple peripheral ground glass opacities with interlobular septal thickening were seen in anterior and inferior lingular segment

of left upper lobe, posterior basal segment of left lower lobe, posterior segment of right upper lobe, and medial segment of right middle lobe. Initially he was on IV steroids and therapeutic doses of heparin. He was maintaining his oxygen saturation to 96%. Ten (10) days after hospitalization and normalization of all inflammatory markers, he has Modified Medical Research Council (mMRC) dyspnoea score 1 and oxygen-independent. The patient was asked for follow up in 6 weeks. Due to

the mMRC of 1 and short history, it is assumed that the fibrosis was not present prior to the COVID-19 diagnosis. The early use of antifibrotics may prevent this devastating complication, but it is difficult to predict who is likely to progress to pulmonary fibrosis. Early rehabilitation protocol for post-acute COVID-19 patients can minimize dyspnea and shortness of breath even for minimal activities.

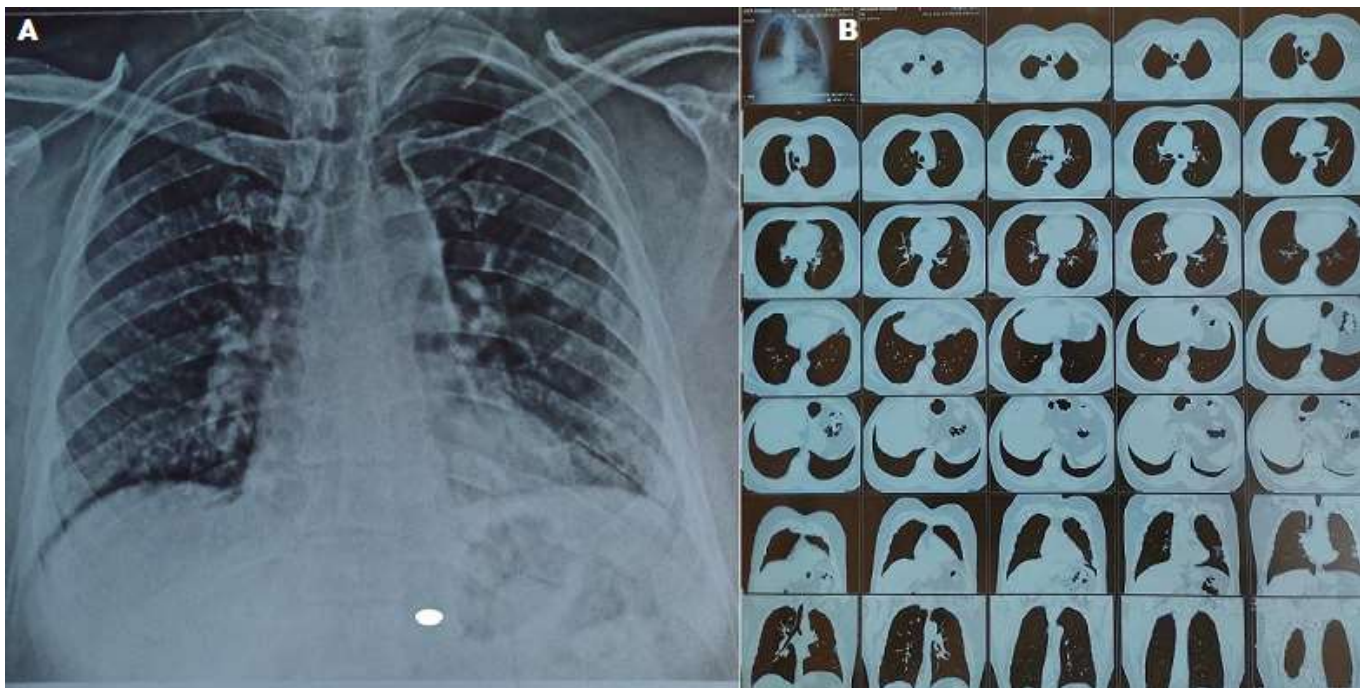


Figure 1: A) honeycomb appearance of bronchiectasis is evident in left upper lobe, posterior basal segment of left lower lobe, posterior segment of right upper lobe, and medial segment of right middle lobe; B) multiple peripheral ground glass opacities with interlobular septal thickening is evident in high-resolution computed tomography (HRCT)