



Tehran University of Medical
Sciences Publication
<http://tums.ac.ir>

Iran J Parasitol

Open access Journal at
<http://ijpa.tums.ac.ir>



Iranian Society of Parasitology
<http://isp.tums.ac.ir>

Original Article

The Protective Effect of *Artemisia spicigera* Ethanolic Extract against *Cryptosporidium parvum* Infection in Immunosuppressed Mice

*Parisa Shahbazi¹, Ahmad Nematollahi¹, Sanaz Arshadi¹, Hosein Hashemzadeh Farhang², Amir Ali Shahbazfar¹

1. Department of Pathobiology, Faculty of Veterinary Medicine, University of Tabriz, Tabriz, Iran

2. Department of Pathobiology, Faculty of Veterinary Medicine, Islamic Azad University Tabriz branch, Tabriz, Iran

Received 20 Jul 2020

Accepted 04 Oct 2020

Keywords:

Artemisia spicigera;
Extract;
Cryptosporidium parvum;
Treatment;
Mice

***Correspondence**

Email:

p.shahbazi56@gmail.com

Abstract

Background: A specific treatment has not yet developed for cryptosporidiosis, and some of the used drugs had side effects in immunodeficient patients. The goal of an appropriate remedy is to remove symptoms and improve immune responses in hosts. The current study was designed to evaluate the therapeutic efficacy of *Artemisia spicigera* ethanolic extract in experimentally infected immunosuppressed mice.

Methods: Thirty six NMRI mice, 4-6 wk old, were randomly divided into six equal groups. C1: uninfected, treated control; C2: infected, untreated control; T1, T2, T3, and P: infected, treated with 0.2, 2, and 20 mg/ml extract, and 5mg/ml paromomycin, respectively. Mice were experimentally infected by oral administration of 10⁴ oocysts/animal of *Cryptosporidium parvum* and treated orally for eight days per 12h, starting 12h before experimental infection. The presence of oocyst shedding, weight gain/loss, and the histopathology of ileum sections were examined.

Results: Results revealed that oocyst shedding was significantly ($P<0.05$) reduced in treatment groups. There was no significant difference between the mean of weight gain/loss in the infected control and treated groups. Histopathological analysis of ileum sections further supported the parasitological findings.

Conclusion: *Artemisia spicigera* had acceptable efficacy as a therapeutic agent for cryptosporidiosis.



Introduction

Cryptosporidium parvum is an obligate, intracellular protozoan parasite in a wide range of hosts that develops within the microvillus layer of epithelial cells throughout the gastrointestinal tract (GI) and even the respiratory tract. *Cryptosporidium* has a worldwide spread and zoonotic importance (1-3). Cryptosporidiosis is primarily a self-limiting disease in immunocompetent hosts. But, in immunodeficient and immunocompromised hosts and children with malnutrition, this infection could cause an extra-intestinal form, chronic diarrhea, and death (3, 4). In livestock, cryptosporidiosis has both economic and clinical importance. Young animals are more vulnerable to infection, and high mortality rates were reported in neonates of various species, particularly ruminants (1-3).

Effective therapy for cryptosporidiosis is already unspecified. Despite the evaluation of over 200 chemotherapeutic agents for their anti-*Cryptosporidium* effects, appropriate treatments to eliminate these parasites of the host are unavailable yet (3, 5, 6). In recent years the herbal compositions with anti-*Cryptosporidium* activity were recognized. They suggested safe and effective in the treatment and control of cryptosporidiosis.

Artemisia genus (Family: Asteraceae) encompasses almost 500 species in the world (7), of which 34 species are in Iran (8). Pharmacological researches have indicated antimalarial (7, 9), antibacterial (10), antifungal (11), antioxidant (10), nematocidal, and cestocidal activities (12, 13), for *Artemisia* species. Known as «dermane ye sonbole» in Persian, *A. spicigera* C. Koch is growing in Armenia, Middle Anatolia, Northwest and North of Iran (14). This species has traditionally been used in medicine. According to the researches, this species of *Artemisia* have insecticidal, antibacterial, and antioxidant but not cytotoxic activity. So, it was recommended that this species is suitable

to be utilized as a natural insecticide or antibacterial agent (8).

Even though *Artemisia* species are efficient in parasitic diseases and digestive system disorders (7, 9, 12, 13, 15), no declared factual data are available regarding the anti-*Cryptosporidium* effect of *Artemisia* in vivo. Among laboratory animals, immunocompromised or immunosuppressed mice are the best candidate for experimental infection with *C. parvum* (16).

So, the present study was conducted to appraise the efficacy of *A. spicigera* ethanolic extract (As-EtOH) compared to paromomycin as a commercial drug against cryptosporidiosis in an immunosuppressed mouse model.

Materials and Methods

Preparation of Cryptosporidium parvum oocysts

Oocysts of *C. parvum* were obtained from naturally infected calves (Aminabad Institute, Tehran University, Tehran, Iran) and microscopically examined using the modified Ziehl-Neelsen (MZN) staining, and then purified (17). The isolated oocysts were treated in 10 % sodium hypochlorite. Afterward, they were washed three times in double distilled water, and then were diluted to the needed concentration in PBS and stored at 4 °C until use (18). Species confirmation of the collected oocysts carried out using PCR assay. After the extraction of DNA using the DNA extraction kit (MBST, Tehran, Iran), DNA was amplified using a pair of primer obtained from the entire 18S rRNA gene of *C. parvum* isolate, according to Sturbaum et al. 2001 (19) that amplify an 840-bp fragment from *C. parvum* genotype 2.

Preparation of Artemisia spicigera ethanolic extract and analysis

The plant material for this study was collected from East Azerbaijan province, Iran. For this collection, a Voucher specimen (14966)

was deposited at the Herbarium of the Faculty of Pharmacy, Tabriz University of Medical Sciences, Tabriz, Iran. After collection in a dark room with fresh air circulation, the plant leaf, root, and stalk were separated, cleaned, and air-dried. Then, all the parts were ground, packed individually, and cached in a dark place. The ethanolic extract was prepared by percolation method as previously described (20). Next, phenol and flavonoids contents measured (21). All the extracts were dissolved in distilled water to reach the final concentrations of 0.2, 2, and 20 mg/ml and were stored at 4 °C until use.

Paromomycin

Paromomycin (125 mg/ 5ml syrup, Alhavi CO., Tehran, Iran) was purchased and used as a standard control drug.

Animals and housing

Thirty six female NMRI mice aged four to six weeks (Pasteur Institute, Tehran, Iran) were divided into six groups: C1 (negative control): uninfected, treated group, C2 (positive control): infected, untreated group, T1-T3: infected, treated groups with AS-EtOH extract and P: infected, treated group with paromomycin. Six mice of equal mean body weight housed per cage. Before beginning the study, all the mice kept for ten days to adapt to the keeping place (animal house, University of Tabriz) and new conditions. In this period, they were evaluated for GI parasite infections

using fecal smears and flotation methods, and they resulted in free from endo-parasites. Also, the result of *Cryptosporidium* oocysts in the examination of fecal smears stained with modified Ziel-Neelsen acid-fast staining in mice was negative. The animals were maintained under controlled temperatures of about 24 °C, with a photoperiod of 12 h light/dark and with humidity at approximately 45-50%.

Experimental infection and treatment

NMRI female mice from all the groups were dosed on alternate days with 120 mg tetracycline or 7.2 ml of 1% dexamethasone 21-phosphate solution in 250 ml drinking water per cage (16). After completing the fourth dexamethasone dose, the mice in five groups (C2, T1, T2, T3, and P) were orally inoculated with 10^4 *C. parvum* oocysts in 100 ml PBS (18). After the experimental infection, mice in T1-T3 groups were treated with 250 μ l of 0.2 mg/ml, 2mg/ml, and 20 mg/ml (5mg/dose) of *A. spicigera* extract, respectively. Uninfected mice in the C1 group received 20 mg/ml of AS extract, and infected control group (C2) received only distilled water. The P group was treated with 200 μ l of paromomycin (5 mg/dose). Administration of herbal extract, distilled water, and paromomycin was performed 12h before oocyst inoculation, and lasted per 12 h for the next eight days (18, 22, 23). The mouse challenge graphically was shown in short in Fig.1.

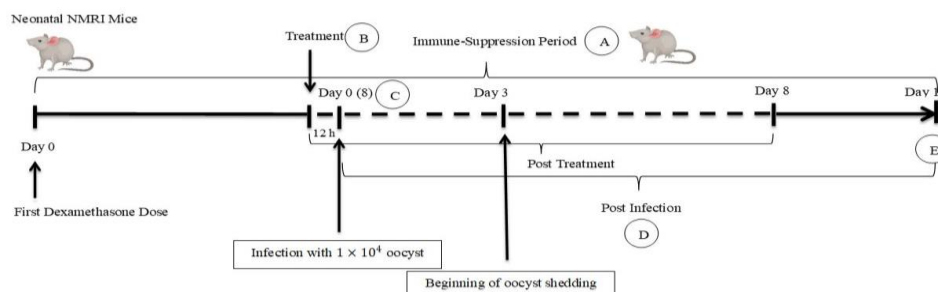


Fig. 1: Experimental infection and treatment in NMRI mice model.

A: Dexamethasone and tetracycline were dosed on alternate days. B: First dose of treatment that repeated per 12 h. C: Day 8 of Immune-Suppression Period. D: Oocyst counting and weight measuring daily. E: Histo-pathological evaluation

Diagnostic methods

Oocyst counts and body weight gain

The fecal pellets were gathered daily from each group for ten days. These fecal samples were suspended in 50 ml of distilled water and were left at room temperature for 5 min. Next, 1ml of the upper suspension was put into a 1.5-ml Eppendorf tube. Then, this part of the suspension was centrifuged at $8,000\times g$ for 3 min, and the supernatant was removed. Besides, the pellet was re-suspended in a 1 ml solution of sucrose (1.2 g/cm^3). The oocysts were counted by a light microscope at a magnification of 1×400 and a hemocytometer. Furthermore, the number of oocysts per gram (OPG) was determined (24). Throughout the study, each of the mice was weighed daily, and the mean was used in data analysis.

Histopathological analysis

On day 10 post-infection (3 days after the end of treatment), using a diethyl ether overdose, all mice of the groups were humanely killed and then necropsied. Additionally, for histological examination, the intestine was removed and placed in 10% formalin. The intestines were paraffin-embedded, and $3\text{-}\mu\text{m}$ sections were prepared, and then were studied by hematoxylin–eosin (H&E) staining. Using a digital-camera microscope (EclipseE200-coolpix-4500, Nikon, Tokyo, Japan), the ileum terminal portion (2 cm before the ileocecolic valve) of the sections were observed and photographed.

Statistical analysis

Statistical significance was determined by the one-way analysis of variance as well as t-tests. Using Statistical SPSS for Windows, issue 22, the data are presented as means \pm standard error (SE) with $P \leq 0.05$ as the significant level.

Ethics approval

This study was undertaken by the bioethics committee of the University of Tabriz

(<http://ethics.research.ac.ir/IR.TABRIZU.REC.1398.018>) and approved with code no. IR.TABRIZU.REC.1398.018

Results

Microscopic and Molecular analysis of *Cryptosporidium* oocysts

As expected, the *Cryptosporidium* oocysts were observed in the obtained feces by MZN staining. In the PCR, the primer set amplified 840bp fragments (Fig. 2).

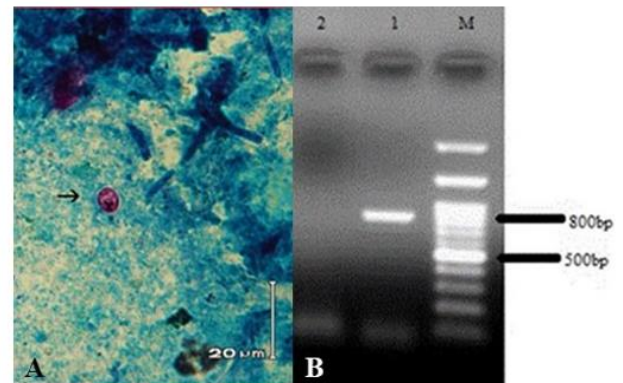


Fig. 2: Microscopic and Molecular analysis of *Cryptosporidium* oocysts. A: The oocyst in MZN staining showed by an arrow. B: PCR amplification of the 18S rRNA gene of *Cryptosporidium*; Lanes 1: *C. parvum* with 840 bp fragment, Lanes 2: negative control, Lanes M: 100-bp molecular marker (CinnaGen Co.Iran)

Evaluation of *A.spicigera* extract on fecal oocyst counts and mean body weight

All the examined mice from infected groups (C2, T1, T2, T3, and P) were considered *Cryptosporidium*-positive, but symptoms such as diarrhea, were not seen in any of the infected mice. During or after the treatment period, no mouse died or exhibited drug toxicity symptoms or side effects. Three days after oocyst inoculation, oocyst shedding in infected test and control groups (C2, T1, T2, T3, and P) was determined and continued until the end of the experiment. The results demonstrated that at day four post-treatment, the test groups presented a decrease of the mean oocysts

number in comparison to day 3 ($P<0.05$), which remained constant throughout the treatment period. However, the C2 group exhibited a high number of mean oocysts until day 10 (Table 1). Although parasite eradication could not be shown in any of the groups, the excreted oocysts number in the test groups was significantly lower than in the C2 group from day 3 to day 10 post-infection ($P<0.05$; Table 1). The T1 and T2 groups had a lower number of mean oocysts than that of group C2 from day 3 ($P<0.05$), but a higher number of mean oocysts than those of P and T3 groups from day 6 to 10 ($P<0.05$) (Table 1). On the last day of treatment (day 8), T3 and P groups exhibited a lower number of mean oo-

cysts than those of C2, T1, and T2 groups ($P<0.05$), and the percentages of decreased oocysts shedding were achieved to be over 70% for these groups. But, they resumed increasing in oocyst shedding after the end of treatment (days 9 and 10) (Table 1). In the uninfected control group (C1), no excretion of oocyst was observed throughout the experiment.

Body weight gain/loss: Infected mice in the test and the C2 control groups showed a significant reduction in mean body weight compared to the healthy control (C1) ($P<0.05$). No significant decrease in mean body weight was noticed in treated groups compared to the C2 group ($P>0.05$).

Table 1: Fecal oocyst counts (Mean \pm SE) in mice groups

	<i>*Day 3</i>	<i>*Day 4</i>	<i>*Day 6</i>	<i>*Day 8</i>	<i>*Day 9</i>	<i>*Day 10</i>
**C1	0	0	0	0	0	0
C2	5.40 \pm 4.59 ^a	5.45 \pm 4.60 ^{a1}	5.51 \pm 4.50 ^{a12}	5.53 \pm 4.52 ^{a123}	5.59 \pm 4.38 ^{a234}	5.6 \pm 4.6 ^{a12345}
T1	5.22 \pm 4.08 ^a	5.16 \pm 4.29 ^{ab1}	5.10 \pm 4.20 ^{ab12}	4.95 \pm 4.34 ^{ab123}	5.08 \pm 4.53 ^{ab1234}	5.12 \pm 4.22 ^{ab12345}
T2	5.20 \pm 4.36 ^{abc}	5.10 \pm 4.38 ^{abc1}	5 \pm 4.35 ^{abc12}	4.86 \pm 4.08 ^{bc123}	4.9 \pm 4.25 ^{abc1234}	4.93 \pm 4.33 ^{bc2345}
T3	4.98 \pm 4.08 ^{ab}	4.93 \pm 4.28 ^{abc1}	4.84 \pm 4.16 ^{abcd12}	4.61 \pm 4.14 ^{abcd123}	4.77 \pm 4.35 ^{abcd1234}	4.74 \pm 4.19 ^{abcd12345}
P	4.86 \pm 4.08 ^{ab}	4.71 \pm 3.97 ^{ab1}	4.52 \pm 3.69 ^{abcde12}	4.12 \pm 3.32 ^{abde123}	4.77 \pm 4.58 ^{abcde1234}	4.42 \pm 3.39 ^{abcde12345}

Data are shown as Mean \pm SE (in log 10). *Days post-infection. **: Groups a,b,c,d,e: $P<0.05$ comparison of the same day of treatment in the different groups a. The statistical difference with the group C1; b. Statistical difference with the group C2; c. The statistical difference with the group T1; d. Statistical difference with the group T2; e. The statistical difference with the group T3; 1, 2, 3, 4, 5: $P<0.05$ comparison between days of treatment in the same group

Histopathological analysis

Histopathological examination of intestinal mucosa in 6 groups revealed differences concerning villus/crypt (V/C) length ratios. The ileal sections of the infected control group (C2) demonstrated the existence of *Cryptosporidium* oocysts on the luminal surface of the epithelium lining the villi. These sections also exhibited altered mucosal architecture, with blunting, widening, and shortening of the intestinal villi and goblet cell hyperplasia (Fig. 3 A-B). In any infected groups, the parasite was not completely eradicated from the intestine;

however, ileal sections of infected, treated mice (T1, T2, T3, and P groups) showed a reduced number of *Cryptosporidium* oocysts. It was observed that the intestinal sections of all extract treated groups regained a typical architecture with standard villus/crypt length ratios, and brush borders were restored. (Fig.3C). No pathological changes and no parasites were identified in the intestinal sections of the C1 group (uninfected, treated control group), which indicates that *A. spicigera* extract at the highest dose in this study (20mg/ml) did not negatively affect the health of the intestine (Fig. 3D).

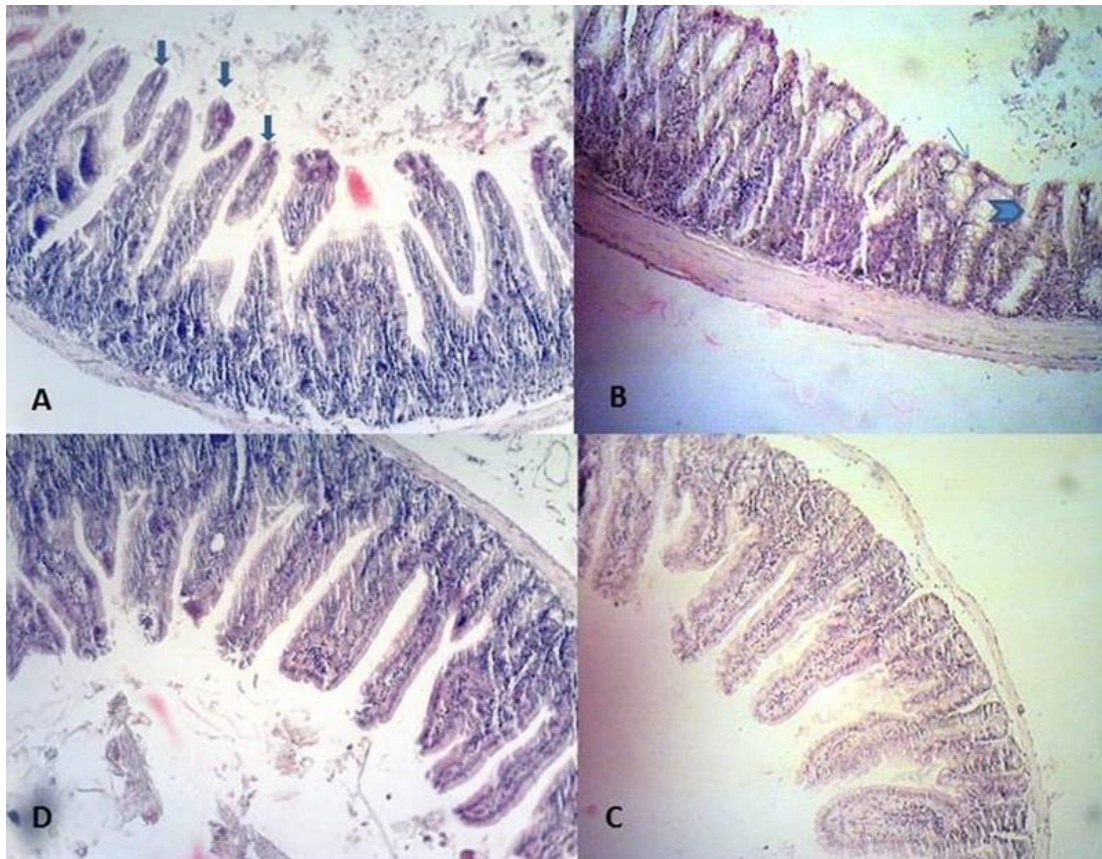


Fig. 3: Ileum histopathological findings in different experimental mice groups: In the C2, A: Desquamation (big arrows) B: villous atrophy ($V/C < 1/3$) (head arrow) and hyperplasia of goblet cells (little arrow) (B) are observed. C: In the T3, the villus/crypt length ratios are standard ($V/C: 1/3$) (C). D: In the C1, the villus/crypt length ratios are standard ($V/C: 1/3$)

Discussion

Finding a natural product with anti-*Cryptosporidium* properties used as a feed additive, was the initial hope underlying this experiment. Since, in cryptosporidiosis treatment, the possibility of using plant extracts and derivatives has been studied, such as Pine bark (25), Mangiferin (23), *Allium sativum* (garlic) (26), *Punica granatum* (27), Egyptian propolis (28), *Oliva europaea* (29) and curcumin (30,31).

The therapeutic potential of *A. spicigera* in the present study was assessed based on oocyst shedding pattern, histopathological findings, and weight gain/loss. The doses of *A. spicigera* used in this experiment were effective in treating mice infected with *C. parvum* and

resulted in no side effects. No changes in weight gain, behavior, or intestinal histopathology were observed in uninfected mice treated with *A. spicigera* (C2).

Our results revealed that *A. spicigera* at 20 mg/ml has remarkable anti-*Cryptosporidium* activity in mice. Furthermore, its activity was similar to that proved by the proposed dose of paromomycin in the past works (5, 32). In agreement with some previous researches, our findings showed that paromomycin and *Artemisia* could not eliminate *Cryptosporidium* infection. When garlic was used to treat HIV patients with confirmed cryptosporidiosis, complete and partial remission occurred in some patients (33). Both paromomycin and mangiferin could not inhibit the intestinal coloni-

zation of *C. parvum* completely, but they reduced it (23). Furthermore, water and ethanol extracts of propolis failed to eradicate the infection, but they reduced the oocyst shedding (28). These results are contrary to findings in other former studies into the anti-*Cryptosporidium* activity of paromomycin and herbal extracts, which showed complete remission of infection (26-27, 30-31). In comparison to the untreated mice, oocyst shedding was reduced in *Artemisia*-treated groups with time and dose-dependent patterns. The effect of time and dose of treatment on the reduction or elimination of *Cryptosporidium* infection has been shown in previous studies (23, 25, 26, 30,31). Oocyst shedding was significantly decreased in the *P. granatum*-treated mice by day 14 PI ($P < .05$) and was removed by day 28 PI (27). Moreover, the current study, like some previous researches, confirmed that the beginning and duration of treatment and intervals of repetitions affected the results (26, 28). Propolis extracts exhibited more efficacies in reducing oocysts excretion when given three days before the infection and continued for seven successive days (28). Riad et al demonstrated the strong prophylactic effect of garlic when given before the infection (34).

C. parvum infection negatively affects weight gain and feeding in infants and nursing animals like calves (5, 35). Low absorption arising from mucosal surface loss and chronic malabsorption may be the cause of weight loss (36). Despite more reduction in weight gain in the infected/untreated group (C2), extract treated mice showed no significant weight gains during the treatment period ($P \geq .05$). This finding is against another study (27), and it maybe because of the experimentation's limited length.

In the present study, histopathological alterations included atrophy of the villi, increased desquamation, and goblet cell hyperplasia. Some previous studies indicated similar structural abnormalities in the ileal villi in *Cryptosporidium* infection in mice, rats, pigs, cats, man,

lambs, and calves (26-28, 37, 38). Goblet cell hyperplasia could be a sign of infection because the cells have a crucial role in producing antimicrobial antibodies (39). Similarly, the villi from infected/extract-treated mice exhibited decreased atrophy and hyperplasia and enhanced architectural symmetry (26, 27). Conversely, some examined extracts could not restore the symmetry of ileal villi and mucosa (28).

The anti-coccidial activity of *Artemisia* species has been demonstrated previously (40). *Artemisia* species contain considerable amounts of artemisinin and polymethoxy flavonoids that they are important for the overall bioactivity of *Artemisia* plants (41). Like *A. indica* and *A. abrotanum* and some other species, artemisinin was not detected in *A. spicigera* extract (42, 7). Also, artemisinin and its derivatives previously showed ineffectiveness against *C. parvum* and exhibited toxicity when given approximately 200 mg/kg to neonatal mice intra-rectally or subcutaneously (43). In this way, *Artemisia* species may have alternative sources of other useful compounds with diverse modes of action.

All solvent extracts of *A. indica* were found to contain typical poly methoxy flavonoids, and the highest levels of these contents were detected in the EtOH extract (42). In *A. abrotanum* L., a range of several flavonoids, coumarins and sesquiterpenes have been detected (7). In essential oil and extracts of *A. spicigera*, significant amounts of phenol, flavonoids contents have been detected (14, 15, 44). A positive result was seen between total phenol and flavonoid levels of samples and the free radical scavenging activity potential (44, 28). Phenolic compounds are the major antioxidants of some herbal extracts like Propolis against *Cryptosporidium* (28). Antibacterial and antifungal activity of *A. spicigera* is related to high levels of these compounds (11, 14), found in this study as major compounds in As -EtOH extract. Therefore the activity of *A. spicigera* ethanolic extract against *Cryptosporidium* may be

owing to its rich contents of phenolic compounds and flavonoids, demonstrated to be responsible for the anti-protozoal effect by enhancing oxidative defense mechanisms.

Conclusion

According to the pharmacological properties resulted from *A. spicigera* C. Koch in the current study, we proposed that it is a safe and effective treatment for cryptosporidiosis in a mouse model. Considering that *Artemisia* is native in Iran, and because of its easy and cheap accessibility, the use of this plant can propose. Nevertheless, more studies are necessary to assess the applications of *Artemisia* spp. as complementary medicine in the management of *Cryptosporidium* infections.

Acknowledgments

The authors are grateful to the University of Tabriz for financial supporting and Mahmoudi R. for technical and scientific assistance. This work was supported by the Research Deputy of the University of Tabriz (number: 2233405).

Conflicts of interest

The authors declare that there is no conflict of interests.

References

1. O'Donoghue PJ. *Cryptosporidium* and cryptosporidiosis in man and animals. *Int J Parasitol.* 1995; 25(2):139-95.
2. Fayer R, Xiao L. (2nd ed) *Cryptosporidium* and Cryptosporidiosis. 2007; CRC Press, New York, USA.
3. Ryan U, Zahedi A, Papanin A. *Cryptosporidium* in humans and animals - a one health approach to prophylaxis. *Parasite Immunol.* 2016; 38(9):535-47.
4. Hunter RP and Nichols G. Epidemiology and clinical features of *Cryptosporidium* infection in immunocompromised patients. *Clin Microbiol Rev.* 2002; 15 (1): 145-54.
5. Theodos CM, Griffiths JK, D'Onfro J, et al. Efficacy of nitazoxanide against *Cryptosporidium parvum* in cell culture and in animal models. *Antimicrob Agents Chemother.* 1998; 42: 1959-1965.
6. Sparks H, Nair G, Castellanos-Gonzalez A, et al. Treatment of *Cryptosporidium*. What We Know, Gaps, and the Way Forward. *Curr Trop Med Rep.* 2015; 2(3): 181-187.
7. Pellicera J, Salsis-Lagoudakisb CH, Carrió E, et al. A phylogenetic road map to antimalarial *Artemisia* species. *J Ethnopharmacol.* 2018; 225:1-9.
8. Naghavi MR, Alaeimoghadam F, Ghafoori H. *Artemisia* Species from Iran as Valuable Resources for Medicinal Uses. *International Scholarly and Scientific Research & Innovation.* 2014; 8(11).
9. Willcox M. Improved traditional phytomedicines in current use for the clinical treatment of malaria. *Planta Med.* 2011; 77(6): 662-71.
10. Juteau F, Masotti V, Bessiere JM, et al. Antibacterial and antioxidant activities of *Artemisia annua* essential oil. *Fitoterapia.* 2002; 73(6):532-5.
11. Kordali S, Kotan R, Mavi A, et al. Determination of the chemical composition and antioxidant activity of the essential oil of *Artemisia dracunculus* and of the antifungal and antibacterial activities of Turkish *Artemisia absinthium*, *A. dracunculus*, *Artemisia santonicum*, and *Artemisia spicigera* essential oils. *J Agric Food Chem.* 2005; 53(24):9452-8.
12. Yildiz K, Basalan M, Duru O, et al. Antiparasitic efficiency of *Artemisia absinthium* on *Toxocara cati* in naturally infected cats. *Turkiye Parazitolo Derg.* 2011; 35(1): 10-4.
13. Shahbazi P, Arshadi S. Effect of *Artemisia spicigera* ethanolic extract on digestive system parasitic worms in mice. *JSSU.* 2018; 26(2): 141-150.
14. Chehregani A, Atri M, Yousefi S, et al. "Essential oil variation in the populations of *Artemisia spicigera* from northwest of Iran: chemical composition and antibacterial activity". *Pharm Biol.* 2013; 51(2):246-52.
15. Abad MJ, Bedoya LM, Apaza L, et al. The *Artemisia* L. genus: a review of bioactive essential oils. *Molecules.* 2012; 17(3):2542-66.

16. Miller TA and Schaefer FW. Changes in mouse circulating leukocyte numbers in C57BL/6 mice immunosuppressed with dexamethasone for *Cryptosporidium parvum* oocyst production. *Vet Parasitol.* 2007; 149(3-4): 147-57.
17. Rossi P, Pozio E, Besse MG, et al. Experimental cryptosporidiosis in hamsters. *J Clin Microbiol.* 1990; 28(2):356-7.
18. Omidian Z, Ebrahimzadeh E, Shahbazi P, et al. Application of recombinant *Cryptosporidium parvum* P23 for isolation and prevention. *Parasitol Res.* 2014; 113(1):229-37.
19. Sturbaum GD, Reed C, Hoover PJ, et al. Species-specific, nested PCR-restriction fragment length polymorphism detection of single *Cryptosporidium parvum* oocysts. *Appl Environ Microbiol.* 2001; 67(6): 2665-8.
20. Mahmoudi R, Amini K, Fakhri O, et al. Aroma profile and antimicrobial properties of alcoholic and aqueous extracts from root, leaf and stalk of nettle (*Urtica dioica* L). *J Microbiol, Biotechnol Food Sci.* 2014; 4(3): 220-224.
21. Ghajarbeygi P, Mohammadi A, Mahmoudi R, et al. *Artemisia spicigera* Essential Oil: Assessment of Phytochemical and Antioxidant Properties. *Biotechnol Health Sci.* 2015; 2(4): 11-16.
22. Jenkins MC, O'Brien C, Trout J, et al. Hyperimmune bovine colostrum specific for recombinant *Cryptosporidium parvum* antigen confers partial protection against cryptosporidiosis in immunosuppressed adult mice. *Vaccine.* 1999; 17(19):2453-60.
23. Perruci S, Fichi G, Buggiani C, et al. Efficacy of mangiferin against *Cryptosporidium parvum* in a neonatal mouse model. *Parasitol Res.* 2006; 99(2):184-8.
24. Kobayashi C, Yokoyama H, Nguyen S A, et al. Effect of egg yolk antibody on experimental *Cryptosporidium parvum* infection in SCID mice. *Vaccine.* 2004; 23(2):232-5.
25. Kim CH, Healey JM. Effects of pine bark extract administered to immunosuppressed adult mice infected with *Cryptosporidium parvum*. *Am J Chin Med.* 2001; 29(3-4): 469-75.
26. Gaafar MR. Efficacy of *Allium sativum* (garlic) against experimental cryptosporidiosis. *Alexandria J Med.* 2012; 48: 59-66.
27. Al-Mathal EM, Alsalem AM. Pomegranate (*Punica granatum*) peel is effective in a murine model of experimental *Cryptosporidium parvum*. *Exp Parasitol.* 2012; 131(3): 350-7.
28. Soufy H, El-Beih MN, Nasr SM, et al. Effect of Egyptian Propolis on cryptosporidiosis in immunosuppressed rats with special emphasis on oocysts shedding, leukogram, protein profile and ileum histopathology. *Asian Pac J Trop Med.* 2017; 10(3): 253–262.
29. Khater MM, El-Sayed SH, Yousof HAS, et al. Anti-*Cryptosporidium* efficacy of *Olea europaea* and *Actinidia deliciosa* in a neonatal mouse model. *Kasr Al Ainy Medical Journal.* 2017; 23: 32-37.
30. Asadpour M, Namazi F, Razavi SM, et al. Comparative efficacy of curcumin and paromomycin against *Cryptosporidium parvum* infection in a BALB/c model. *Vet Parasitol.* 2018; 250: 7-14.
31. Asadpour M, Namazi F, Razavi SM, et al. Curcumin: A promising treatment for *Cryptosporidium parvum* infection in immunosuppressed BALB/c mice. *Exp Parasitol.* 2018; 195:59-65.
32. Healey M, Yang C, Rasmussen S, et al. Therapeutic efficacy of paromomycin in immunosuppressed adult mice infected with *Cryptosporidium parvum*. *J Parasitol.* 1995; 81(1):114-6.
33. Fareed G, Scolaro M, Jordan W, et al. The use of a high-dose garlic preparation for the treatment of *Cryptosporidium parvum* diarrhea. *Int Conf AIDS.* 1996; 11:288-92.
34. Riad NHA, Taha HA, Mahmoud YI. Effects of garlic on albino mice experimentally infected with *Schistosoma mansoni*: A parasitological and ultrastructural study. *Trop Biomed.* 2009; 26(1):40-50.
35. Enemark HL, Bille-Hansen V, Lind P, et al. Pathogenicity of *Cryptosporidium parvum*-evaluation of an animal infection model. *Vet Parasitol.* 2003; 113(1):35-57.
36. Sloper KS, Dourmashkin RR, Bird RB, et al. Chronic malabsorption due to cryptosporidiosis in a child with immunoglobulin deficiency. *Gut.* 1982; 23(1): 80–82.
37. Poonacha K B, Pippin C. Intestinal Cryptosporidiosis in a cat. *Vet Pathol.* 1982; 19: 708-10.
38. Klein P, Kleinova T, Volek Z, et al. Effect of *Cryptosporidium parvum* infection on the absorptive capacity and paracellular permeability of the small intestine in neonatal calves. *Vet Parasitol.* 2008; 152(1–2): 53-9.
39. Bourlioux P, Koletzko B, Guarner F, et al. The intestine and its microflora are partners for the

- protection of the host: report on the Danone Symposium 'The Intelligent Intestine', held in Paris, June 14, 2002. *Am J Clin Nutr.* 2003; 78(4): 675-83.
40. Pirali Kheirabadi K, Kaboutari Katadj J, Bahadoran S, et al. Comparison of the anticoccidial effect of granulated extract of *Artemisia sieberi* with monensin in experimental coccidiosis in broiler chickens. *Exp Parasitol.* 2014; 141:129-33.
 41. Klayman DL, Lin AJ, Acton N, et al. Isolation of artemisinin (qinghaosu) from *Artemisia annua* growing in the United States. *J Nat Prod.* 1984; 47: 715–717.
 42. Tasdemir D, Tierney M, Sen R, et al. Antiprotozoal Effect of *Artemisia indica* Extracts and Essential Oil. *Planta Med.* 2015; 81(12-13):1029-37.
 43. Fayer R, Ellis W. Qinghaosu (artemisinin) and derivatives fail to protect neonatal BALB/c mice against *Cryptosporidium parvum* (Cp) infection. *J Eukaryot Microbiol. Microbiol.* 1994; 41(5):41S.
 44. Afshar FH, Delazar A, Nazemiyeh H, et al. Comparison of the total phenol, flavonoid contents and antioxidant activity of methanolic extracts of *Artemisia spicigera* and *A. splendens* growing in Iran. *Pharmaceutical sciences.* 2012; 18(3), 165-170.