

## Static vs dynamic short nail in pertrochanteric fractures: experience of two center in Northern Italy

Quattrini Fabrizio<sup>1</sup>, Ortolani Alessandro<sup>2</sup>, Corrado Ciatti<sup>1</sup>, Puma Pagliariello Calogero<sup>1</sup>, Martucci Antonio<sup>2</sup>, Gurrieri Luca<sup>1</sup>, Stallone Stefano<sup>2</sup>, Giuseppe Melucci<sup>2</sup>, Tigani Domenico<sup>2</sup>, Maniscalco Pietro<sup>3</sup>

<sup>1</sup>Department of Trauma and Orthopaedics Surgery “Guglielmo da Saliceto” Hospital, Via Taverna 49, 29121 Piacenza, Italy;

<sup>2</sup>Department of Trauma and Orthopaedic Surgery, Maggiore Hospital, Largo Nigrisoli 2, 40133 Bologna, Italy; <sup>3</sup>Full Professor Orthopaedics and Trauma Surgery University of Parma, Head Orthopaedic and Traumatology Department Piacenza Hospital, Via Tarverna 49, 2121 Piacenza, Italy

**Abstract.** *Background and aim:* Lateral fractures of proximal femur are the most frequent to treat for the traumatologist surgeon. Intramedullary nailing is the gold standard treatment of this type of fracture. The aim of the study is to analyze the results obtained with the Elos Intrauma nail by the experience of two Departments of Orthopedics and Traumatology (“Guglielmo da Saliceto” Hospital in Piacenza and the Maggiore hospital in Bologna). *Methods:* We performed a retrospective cohort study of 400 patients with lateral femoral neck fracture surgically treated with Elos Intrauma standard nail. The examined period is from 1<sup>st</sup> January 2018 to 31<sup>st</sup> December 2020. In all patients we implanted Elos® - Intrauma nail, a titanium cervical diaphyseal nail, according to the standard technique. *Results:* We evaluate at a minimum of three months of follow up 286/400 patients. Average follow up was 3.94 months, minimum 3 months and maximum 24 months. We obtain the 96.85 % of fracture healing, recording 33 complications (11.54%). The incidence of surgical revision was 2.8% (8 cases). No mechanical complications was found in stable fractures treated with short nail and without distal locking. *Conclusions:* With the use of Elos nail we obtained 95% of radiographic healings within three months with a complication rate comparable to literature report. Distal locking is absolutely recommended in complex fractures, it may be superfluous after careful evaluation of the fracture pattern and morphological characteristics of the femur to be treated; future in-depth studies may narrow the criteria to choose distal locking or non locking. ([www.actabiomedica.it](http://www.actabiomedica.it))

**Key Words:** proximal femur, femur fracture, nailing, distal locking, Elos nail, pertrochanteric, intertrochanteric

### Introduction

Although the current SARS Covid 19 pandemic has decreased the number of fractures overall (1,2), lateral fractures of proximal femur remain by far the most frequent to treat for the traumatologist surgeon. Intramedullary nailing is the gold standard treatment of this type of fracture (3); cervical-diaphyseal nails allowed to reach excellent clinical results and a rapid recovery in elderly patients who usually fracture the proximal femur.

The socio-economic impact of proximal femur fractures (PFF) in terms of public health is significant. It has been shown that the incidence and costs of PFF for elderly in Italy are comparable to myocardial infarction (4) with additional social costs, resulting from emergence of new comorbidities, sarcopenia, disability and mortality. Moreover pertrochanteric fractures are expected to double in the next few decades to the aging of the population (5).

The choice of a stable and reliable synthesis tool is essential to allow an early mobilization and rehabilita-

tion of patients, usually elderly, who risk potentially fatal complications related to prolonged bed rest (3).

Many types of cervical diaphyseal nails are produced with different materials (6) and with different designs and also developed during time (7); in this work we will analyze the results obtained with the Elos Intrauma nail by the experience of two Departments of Orthopedics and Traumatology ("Guglielmo da Saliceto" Hospital in Piacenza and the Maggiore hospital in Bologna).

## Materials and methods

We performed a retrospective cohort study of 400 patients with lateral femoral neck fracture surgically treated with Elos Intrauma standard nail at the Orthopedic and Traumatology Unit of the *Ospedale Maggiore "C.A. Pizzardi"* in Bologna and *Ospedale "Guglielmo da Saliceto"* of Piacenza during the period from 1<sup>st</sup> January 2018 to 31<sup>st</sup> December 2020.

The patients distribution of two hospitals is shown in tables 1 and 2.

Our population consists of 400 patients with an average age of 83.27, IQR 89-79 and range 42-101: 309 females (mean age 83.96 range 42-101) and 91 males (mean age 80.91 range 52-97), 216 fracture type A1 according to AO-OTA Classification and 184 type A2, follow up average 3.94 months (range 0-24 months).

In all patients we implanted Elos®- Intrauma nail which is a titanium cervical diaphyseal nail with a proxi-

mal end of trapezoidal section and a maximum side of 15 mm, distal diameter 10 mm, a lateral bending of 5 degrees and a flat lateral wall, it allows the implantation of a cephalic screw with a fixed angle of 127 degrees and a possible second screw antirotational, short straight nails are 180 or 240 mm and available longer nail sizes from 300 to 460mm with the possibility of a dedicated distal hole centering guide up to 300mm. It presents an expanded side wall of cephalic screw hole to increase mechanical resistance in this critical area, a canulated screw pre-assembled proximally to lock cephalic screw.

In both study centers nails were set up according to the standard technique, as described by the producer (Intrauma S.p.A. - Via Genova, 19, 10098 Rivoli (TO) Italy), with patient positioned on orthopaedic bed and with leg traction, reaming only the proximal part of intramedullary canal with a dedicated tool; cephalic screw was positioned after insertion of the guide wire, and a second optional antirational screw could be placed (no definitive second screw was implanted in our series).

About distal locking screw, it was placed in a static configuration in all 184 A2 fractures and in 138/139 A1 fractures treated in Bologna while no screw in all A1 fractures treated in Piacenza (77 cases). Fig.2

All patients were subjected to early progressive loading within the first week, depending on the general subjective clinical conditions. Clinical and radiographic controls were scheduled at 1-2-3-6-12 months.

We considered as inclusion criteria of our study:

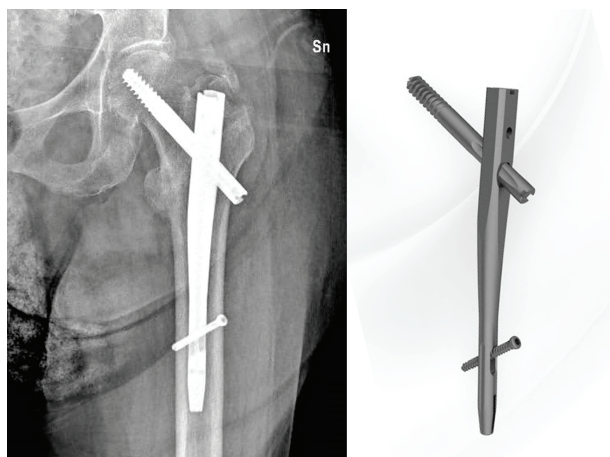
- Elos nail short implant without second proximal antirotational screw

**Table 1.** Ospedale Maggiore Bologna starting cohort

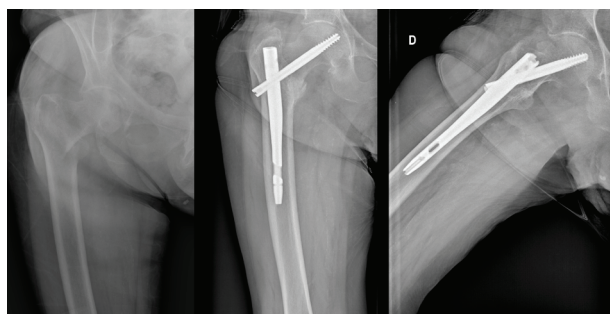
	Patients	Mean age	Fracture AO type		Distal Locking	
			A1	A2	No	Static
<b>Males</b>	62	80.16	42	20	1	61
<b>Females</b>	215	84.09	97	118	0	215
<b>tot</b>	277	83.21	139	138	1	276

**Table 2.** Ospedale Piacenza starting cohort

	Patients	Mean age	Fracture AO type		Distal Locking	
			A1	A2	No	Static
<b>Males</b>	29	82.51	20	9	20	9
<b>Females</b>	94	83.65	57	37	57	37
<b>tot</b>	123	83.39	77	46	77	46



**Figure 1.** Proximal femur fracture treated with Elos nail



**Figure 2.** Male 85 years old, 31A1 fracture AO classification, healing at 6 months

- Lateral proximal femur fractures type A1 and A2 according to the AO classification, not A3 where we usually use intermediate or long nails which would also be excluded from the study
- minimum follow-up of 3 months to be able to give credible judgment on the patient's clinic and radiographic recovery.

Considering these criteria the definitive cohort resulted of 286 patients, 62 males and 224 females, mean age 82.41 (min 42 – max 99), IQR 88-78 (table 3).

## Results

We evaluate at a minimum of three months of follow up 286/400 patients (71.5 %); 62/91 males (68.13%), 224/309 females (72.49%), 145/216 patients with A1 fractures (67.13%), 141/184 patients with A2 fractures (76.63%), 42/78 patients without distal locking screw (53.85%) and 244/322 with a distal static screw (75.78%). Average follow up was 3.94 months, minimum 3 months and maximum 24 months.

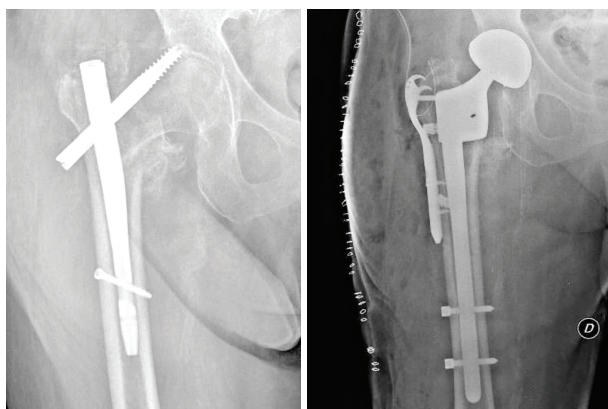
We obtain with Elos nail 96.85 % (277/286) of fracture healing; we recorded 33 complications (11.54%) in our series (see table 4).

**Table 3.** Definitive cohort

	Patients	Mean age	Fracture AO type		Distal Locking	
			A1	A2	No	Static
<b>Males</b>	62	79.12 (52-97)	41	21	10	52
<b>Females</b>	224	83.32 (42-99)	104	120	32	192
<b>Tot</b>	286	82.41	145	141	42	244

**Table 4.** Complications

Complications	Total	Bologna	Piacenza	Treatment
cut out	3	2	1	3 revision with endoprosthesis
refractures at distal screw level	2	0	2	2 revision with long nail
non union	4	3	1	3 no treatment (1 bad general condition, 2 no walking patient) 1 endprosthesis
superficial infection	3	2	1	antibiotic therapy
deep vein thrombosis	4	2	2	blood thinning therapy
ictus cerebri	2	1	1	
lateral screw protrusion for fracture compaction	6	4	2	5 no treatment, 1 screw replacement
coxarthrosis	3	2	1	2 no treatment, 1 hip arthroplasty
malunion	3	2	1	no treatment (hypometry)
knee arthrosis	3	1	2	2 no treatment, 1 knee prosthesis



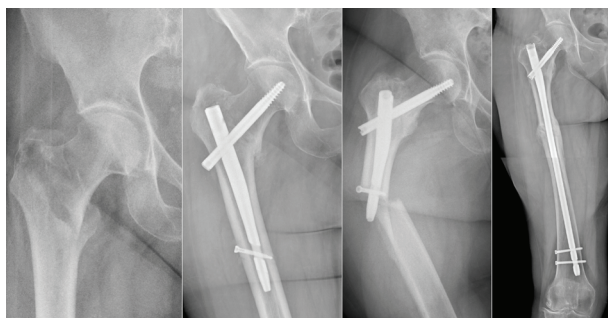
**Figure 3.** Cut out and revision with Dual Mobility Cup and locked Stem

The incidence of surgical revision was 2.8% (8 cases), and could have doubled (another 8 cases) but the comorbidities or poor general conditions of elderly patients advised against a further surgical approach.

The most frequent revision surgery was nail removal and prosthetic replacement in 5 cases (Fig. 3), 2 cases of new synthesis with long nail for peri-implant fracture, one case of proident cephalic screw replacement for impingement on the fascia lata.

The Bologna group believes in distal static fixation even in stable fractures (A1) to control proximal rotation and fracture shortening, and to prevent axial and rotational instability.

On the other hand, none of the A1 pertrochanteric fractures treated in Piacenza were blocked distally to avoid the distal nail jamming which could compromise dynamic compression at the fracture site during loading, inducing nonunion of fracture or leading to breakage of the osteosynthesis device.



**Figure 4.** Stable fracture treated with short nail and distal locking; refracture at distal screw level, revision with long nail.

We didn't find any mechanical complications in stable fractures (ie 31 A1 according to AO classification) (8) treated with short nail and without distal locking all healed but in the same fracture type distally locked, we noted 2 cases of peri-implant fracture both at distal locking screw level (Fig. 4).

## Discussion

Carrying out studies on the treatment of pertrochanteric fractures can certainly be difficult as it concerns the elderly population, already fragile and with multiple comorbidities (9,10,11); frequently the patients do not show up even at early checks in fact the literature reports about 30% mortality one year after surgery (12). In addition checks during 2020, included in our series, were even more difficult for ongoing Covid 19 pandemic, which mowed down elderly population and limited outpatient re-evaluations to strictly necessary.

For reasons just mentioned, it is extremely difficult to obtain medium or long follow ups in this type of patients / fractures. We considered a minimum time of three months to be able to evaluate fractures healing which has been reported, in some literature, an average time of 70 days (13).

Certainly a limitation of our study is that we limited to consider outcomes as the fracture healing and the onset of complications; we did not consider clinical criteria or functional rating scales. We chose this approach to evaluate the validity and reliability of internal fixation rather than the functional results in patients who are often compromised before surgery and who often worsen for trauma sequelae and for factors related to surgery, but not related to osteosynthesis quality and tool choice.

The different view between the two groups in the execution or not of the distal locking of the nail to treat the A1 fracture allowed us to evaluate the literature and compare our data.

It is necessary to note that the technical sheets and relative surgical techniques of the most commonly used cervical diaphyseal nails always include distal locking, allowing static or dynamic assembly position but do not indicate the option to not implant the screw. However, there are numerous literature works



that propose to avoid distal locking, especially in stable pertrochanteric fractures (14,15,16,17).

Rosenblum et al. (18) found that the use of distal locking screw does not change femoral stress load for stable intertrochanteric fractures, and the tension of the proximal femoral bone does not change. Other authors as well reported various complications in the use of distal locking of intramedullary nails, including fascia lata irritation, additional operative time, intraoperative bleeding, radiation exposure, superficial femoral artery tear, implant loosening, and secondary femoral fractures. (13,14,15,16,18)

Our numbers are too small to express a static significance but in our serie there were no cut outs (although present in 3 cases but in more complex A2 type fractures) or mechanical complications related A1 pertrochanteric fractures treated without distal screw. However, we reported two cases of peri-nail fractures at the level of locking screw occurred a few months after surgery. Leed's group refered thigh pain, erosion of the femoral cortex, and femoral fracture as consequences of the stress load at the distal screw (19).

A recent metaanalysis of Li YH et al demonstrate that distal unlocking of stable intertrochanteric fractures can shorten the operation time, reduce intraoperative bleeding, and reduce the blood transfusion rate; furthermore the use of locked or unlocked intramedullary nailing does not affect long-term outcomes regarding complications and function. (20)

More complex fractures deserve a different approach, especially in case of medial support deficit (for example with dislocation of the lesser trochanter) and in case of a large femoral medullary canal, in these cases biomechanical studies show a risk of varus deviation of the nail and fracture so high to make distal locking necessary. (21) Furthermore, the cephalic screw is rotationally unstable within the bone; especially the flexion-extension of the limb causes the loosening of the bone-screw interface, with the screw secondarily "cutting" (21).

The Elos nail has a particular shape, designed with a trapezoidal proximal end which may prevent uncontrolled shortening during fracture healing and limit varus collapse. Furthermore proximal trapezoidal geometry improves rotational stability by allowing a press-fit into the femoral metaphysis where more ma-

terial is placed laterally. This combined with a press-fit insertion and medialization of the nail at the time of lag screw compression seems to minimize the rate of implant fatigue and/or failure (22). These design features guarantee an advantage for the possible complications previously explained.

## Conclusions

The Elos nail we implanted brought us well over 95% of radiographic healings within three months with a complication rate comparable to literature report. The characteristics of the nail in particular the proximal trapezoidal section can give a biomechanical advantage. Distal locking (23,24) is absolutely recommended in complex fractures, it may be superfluous after careful evaluation of the fracture pattern and morphological characteristics of the femur to be treated; future in-depth studies may narrow the criteria to choose distal locking or non locking.

**Conflicts of interest:** Each author declares that he or she has no commercial associations (e.g. consultancies, stock ownership, equity interest, patent/licensing arrangement etc.) that might pose a conflict of interest in connection with the submitted article.

## References

1. Maniscalco P, Quattrini F, Ciatti C, Gattoni S, Puma Paggiarello C, Burgio V, Di Stefano G, Cauteruccio M, Giovanelli M, Magro A, Capelli P. The Italian Covid-19 Phase 2 in Piacenza: results of the first semester of 2020 and future prospective of new orthopedics surgical procedures. *Acta Biomed.* 2020 Nov 10;91(4):e2020159. doi: 10.23750/abm.v91i4.10377. PMID: 33525208; PMCID: PMC7927514.
2. Hernigou J, Morel X, Callewier A, Bath O, Hernigou P. Staying home during "COVID-19" decreased fractures, but trauma did not quarantine in one hundred and twelve adults and twenty eight children and the "tsu-nami of recommendations" could not lockdown twelve elective operations. *Int Orthop.* 2020 Aug;44(8):1473-1480. doi: 10.1007/s00264-020-04619-5. Epub 2020 May 25. PMID: 32451655; PMCID: PMC7247744.
3. <https://www.sirm.org/wp-content/uploads/2020/11/Linee-Guida-SIOT.pdf>.
4. Piscitelli P, Iolascon G, Gimignano F. SIOMMS study group, CERSUM research group. Incidence and costs of hip fractures compared to acute myocardial infarction in the Italian population: a 4 year survey. *Osteoporos Int.* 2007

- Feb; 18(2):211-9.
5. Gullberg B, Duppe H, Nilsson B, Redlund-Johnell I, Sernbo I, Obrant K, Johnell O. Incidence of hip fractures in Malmö, Sweden (1950-1991). *Bone*. 1993;14 Suppl 1:S23-9. doi: 10.1016/8756-3282(93)90345-b. PMID: 8110516.
  6. Maniscalco P, Quattrini F, Ciatti C, Burgio V, Rivera F, Di Stefano G, Pavone V. A preliminary experience with a new intramedullary nail for trochanteric fractures. *Acta Biomed*. 2020 May 30;91(4-S):122-127. doi: 10.23750/abm.v91i4-S.9726. PMID: 32555087; PMCID: PMC7944840.
  7. Pascarella R, Fantasia R, Maresca A, Bettuzzi C, Amendola L, Violini S, Cuoghi F, Sangiovanni P, Cerbasi S, Boriani S, Tigani DS. How evolution of the nailing system improves results and reduces orthopedic complications: more than 2000 cases of trochanteric fractures treated with the Gamma Nail System. *Musculoskelet Surg*. 2016 Apr;100(1):1-8. doi: 10.1007/s12306-015-0391-y. Epub 2015 Dec 14. PMID: 26667625.
  8. AOFoundation. <https://www2.aofoundation.org/wps/portal/surgery?showPage=diagnosis&bone=Femur&segment=Proximal>
  9. Catania P, Passaretti D, Montemurro G, Ripanti S, Carbone S, Candela V, Carnovale M, Gumina S, Pallotta F. Intramedullary nailing for pertrochanteric fractures of proximal femur: a consecutive series of 323 patients treated with two devices. *J Orthop Surg Res*. 2019 Dec 18;14(1):449. doi: 10.1186/s13018-019-1506-1. PMID: 31852485; PMCID: PMC6921538.
  10. National Clinical Guideline Centre. The Management of Hip Fracture in Adults. NICE clinical guideline 124. London: National Institute for Health and Care Excellence (NICE), Jun 2011.
  11. Hwang LC, Lo WH, Chen WM, Lin CF, Huang CK, Chen CM. Intertrochanteric fractures in adults younger than 40 years of age. *Arch Orthop Trauma Surg*. 2001;121(3):123-6. doi: 10.1007/s004020000190. PMID: 11262774.
  12. Dzupa V, Bartonicek J, Skála-Rosenbaum J, Příkazský V. Umrtí pacient se zlomeninou proximálního femuru v prvním roce po úrazu [Mortality in patients with proximal femoral fractures during the first year after the injury]. *Acta Chir Orthop Traumatol Cech*. 2002;69(1):39-44. Czech. PMID: 11951568.
  13. Heinz T, Vécsei V. Komplikationen und Fehler bei der Anwendung des Gammanagels. Ursachen und Prävention [Complications and errors in use of the gamma nail. Causes and prevention]. *Chirurg*. 1994 Nov;65(11):943-52. German. PMID: 7821075.
  14. Caiaffa V, Vicenti G, Mori C, Panella A, Conserva V, Corina G, Scialpi L, Abate A, Carrozzo M, Petrelli L, Picca G, Aloisi A, Rollo G, Filippini M, Fredda V, Pansini A, Puce A, Solarino G, Moretti B. Is distal locking with short intramedullary nails necessary in stable pertrochanteric fractures? A prospective, multicentre, randomised study. *Injury*. 2016 Oct;47 Suppl 4:S98-S106. doi: 10.1016/j.injury.2016.07.038. Epub 2016 Aug 11. PMID: 27523625.
  15. Buruian A, Silva Gomes F, Roseiro T, et al. Distal interlocking for short trochanteric nails: static, dynamic or no locking? Review of the literature and decision algorithm. *EFORT Open Rev*. 2020;5(7):421-429. Published 2020 Aug 1. doi:10.1302/2058-5241.5.190045.
  16. Li YH, Yu T, Shao W, Liu Y, Zhu D, Tan L. Distal locked versus un-locked intramedullary nailing for stable intertrochanteric fractures, a systematic review and meta-analysis. *BMC Musculoskelet Disord*. 2020;21(1):461. Published 2020 Jul 13. doi:10.1186/s12891-020-03444-6.
  17. Chouhan D, Meena S, Kamboj K, Meena MK, Narang A, Sinha S. Distal Locked versus Unlocked Intramedullary Nailing in Intertrochanteric Fracture; A Systematic Review and Meta-Analysis of Randomized and Non-Randomized Trials. *Bull Emerg Trauma*. 2020 Apr;8(2):56-61. doi: 10.30476/BEAT.2020.46444. PMID: 32420389; PMCID: PMC7211383.
  18. Lanzetti RM, Caraffa A, Lupariello D, Ceccarini P, Gambaracci G, Mecariello L, Manfreda F, Maiettini D, Vicente CI, Scialpi M, Bisaccia O, Rino-napoli G, Bisaccia M. Comparison between locked and unlocked intramedullary nails in intertrochanteric fractures. *Eur J Orthop Surg Traumatol*. 2018 May;28(4):649-658. doi: 10.1007/s00590-018-2143-9. Epub 2018 Feb 9. PMID: 29427093.
  19. Rosenblum SF, Zuckerman JD, Kummer FJ, Tam BS. A biomechanical evaluation of the Gamma nail. *J Bone Joint Surg Br*. 1992 May;74(3):352-7. doi: 10.1302/0301-620X.74B3.1587875. PMID: 1587875.
  20. Kanakaris NK, Tosounidis TH, Giannoudis PV. Nailing intertrochanteric hip fractures: short versus long; locked versus nonlocked. *J Orthop Trauma*. 2015 Apr;29 Suppl 4:S10-6. doi: 10.1097/BOT.0000000000000286. PMID: 25756821.
  21. Li YH, Yu T, Shao W, Liu Y, Zhu D, Tan L. Distal locked versus un-locked intramedullary nailing for stable intertrochanteric fractures, a systematic review and meta-analysis. *BMC Musculoskelet Disord*. 2020 Jul 13;21(1):461. doi: 10.1186/s12891-020-03444-6. PMID: 32660560; PMCID: PMC7359611.
  22. Ceynowa M, Zerdzicki K, Klosowski P, Pankowski R, Ročlawski M, Mażurek T. The early failure of the gamma nail and the dynamic hip screw in femurs with a wide medullary canal. A biomechanical study of intertrochanteric fractures. *Clin Biomech (Bristol, Avon)*. 2020 Jan;71:201-207. doi: 10.1016/j.clinbiomech.2019.11.006. Epub 2019 Nov 14. PMID: 31775090.
  23. Ruecker AH, Rupperecht M, Gruber M, Gebauer M, Barvencik F, Briem D, Rueger JM. The treatment of intertrochanteric fractures: results using an intramedullary nail with integrated cephalocervical screws and linear compression. *J Orthop Trauma*. 2009 Jan;23(1):22-30. doi: 10.1097/BOT.0b013e31819211b2. Erratum in: *J Orthop Trauma*. 2009 May-Jun;23(5):378. PMID: 19104300.
  24. Li X, Zhang L, Hou Z, Meng Z, Chen W, Wang P, Zhang Y. Distal locked and unlocked nailing for pertrochanteric fractures--a prospective comparative randomized study. *Int Orthop*. 2015 Aug;39(8):1645-52. doi: 10.1007/s00264-

- 015-2771-1. Epub 2015 Apr 26. PMID: 25913263.
25. Skála-Rosenbaum J, Bartoníček J, Bartoska R. Is distal locking with IMHN necessary in every pertrochanteric fracture? *Int Orthop*. 2010 Oct;34(7):1041-7. doi: 10.1007/s00264-009-0874-2. Epub 2009 Nov 1. PMID: 19882156; PMCID: PMC2989034.

Received: 5 May 2021 – Accepted: 1 July 2021

Correspondence:

Quattrini Fabrizio

Ospedale “Guglielmo da Saliceto” Piacenza, Via Taverna 49,  
29121 Piacenza, Italy

Email: [fabrizioquattrini@yahoo.it](mailto:fabrizioquattrini@yahoo.it)