

## Antler stem cells and their potential in wound healing and bone regeneration

Wei Zhang, Chang-Hong Ke, Hai-Hua Guo, Li Xiao

**ORCID number:** Wei Zhang 0000-0003-2740-9394; Chang-Hong Ke 0000-0003-4128-6175; Hai-Hua Guo 0000-0001-9376-3768; Li Xiao 0000-0001-8857-7792.

**Author contributions:** Zhang W and Ke CH contributed equally to this work; Zhang W, Ke CH, and Xiao L designed this paper; Zhang W and Ke KH wrote the paper; Guo HH and Xiao L made the pictures and revised the paper; all authors have read and approved the final manuscript.

**Conflict-of-interest statement:** The authors declare that they have no conflict of interest to disclose.

**Open-Access:** This article is an open-access article that was selected by an in-house editor and fully peer-reviewed by external reviewers. It is distributed in accordance with the Creative Commons Attribution NonCommercial (CC BY-NC 4.0) license, which permits others to distribute, remix, adapt, build upon this work non-commercially, and license their derivative works on different terms, provided the original work is properly cited and the use is non-commercial. See: <http://creativecommons.org/licenses/by-nc/4.0/>

**Manuscript source:** Invited manuscript

**Wei Zhang**, Medical Imaging Center, The First Affiliated Hospital of Jinan University, Guangzhou 510080, Guangdong Province, China

**Wei Zhang, Chang-Hong Ke**, Research & Development Center, YZ Health-tech Inc., Zhuhai 519000, Guangdong Province, China

**Chang-Hong Ke**, School of Pharmacy, Jinan University, Guangzhou 510080, Guangdong Province, China

**Hai-Hua Guo**, Institute of Biomedical and Pharmaceutical Sciences, Guangdong University of Technology, Guangzhou 510006, Guangdong Province, China

**Li Xiao**, Guangdong Laboratory Animals Monitoring Institute and Guangdong Provincial Key Laboratory of Laboratory Animals, Guangzhou 510080, Guangdong Province, China

**Corresponding author:** Li Xiao, MS, Assistant Professor, Guangdong Laboratory Animals Monitoring Institute and Guangdong Provincial Key Laboratory of Laboratory Animals, No. 11 Fengxin Road, Science City, Guangzhou 510080, Guangdong Province, China. [xiaoli19900202@163.com](mailto:xiaoli19900202@163.com)

### Abstract

Compared to other vertebrates, the regenerative capacity of appendages in mammals is very limited. Deer antlers are an exception and can fully regenerate annually in postnatal mammals. This process is initiated by the antler stem cells (AnSCs). AnSCs can be divided into three types: (1) Antlerogenic periosteum cells (for initial pedicle and first antler formation); (2) Pedicle periosteum cells (for annual antler regeneration); and (3) Reserve mesenchyme cells (RMCs) (for rapid antler growth). Previous studies have demonstrated that AnSCs express both classic mesenchymal stem cells (MSCs) and embryonic stem cells (ESCs), and are able to differentiate into multiple cell types *in vitro*. Thus, AnSCs were defined as MSCs, but with partial ESC attributes. Near-perfect generative wound healing can naturally occur in deer, and wound healing can be achieved by the direct injection of AnSCs or topical application of conditioned medium of AnSCs in rats. In addition, in rabbits, the use of both implants with AnSCs and cell-free preparations derived from AnSCs can stimulate osteogenesis and repair defects of bone. A more comprehensive understanding of AnSCs will lay the foundation for developing an effective clinical therapy for wound healing and bone repair.

**Specialty type:** Biology

**Country/Territory of origin:** China

**Peer-review report's scientific quality classification**

Grade A (Excellent): 0  
Grade B (Very good): B  
Grade C (Good): C  
Grade D (Fair): 0  
Grade E (Poor): 0

**Received:** February 27, 2021

**Peer-review started:** February 27, 2021

**First decision:** April 20, 2021

**Revised:** May 10, 2021

**Accepted:** July 27, 2021

**Article in press:** July 27, 2021

**Published online:** August 26, 2021

**P-Reviewer:** Collart-Dutilleul PY, Yuan FL

**S-Editor:** Yan JP

**L-Editor:** Wang TQ

**P-Editor:** Liu JH



**Key Words:** Antler; Stem cells; Regeneration; Wound healing; Bone repair

©The Author(s) 2021. Published by Baishideng Publishing Group Inc. All rights reserved.

**Core Tip:** With the development of regenerative medicine in recent years, stem cell-based strategies for wound healing and bone repair have received increasing attention. Deer are the only mammals that can fully regenerate a complex organ (antler) annually. In this paper, by reviewing current publications, we summarize the molecular characterizations, locations, and functions of antler stem cells (AnSCs) to deepen our understanding of the unique stem cell-based epimorphic process in mammals. We also describe the research progress and future directions of AnSCs-based/cell-free therapies for wound healing and bone repair, focusing on the use of antlerogenic periosteum cells, pedicle periosteum cells, reserve mesenchyme cells, and extracellular molecules derived from AnSCs.

**Citation:** Zhang W, Ke CH, Guo HH, Xiao L. Antler stem cells and their potential in wound healing and bone regeneration. *World J Stem Cells* 2021; 13(8): 1049-1057

**URL:** <https://www.wjgnet.com/1948-0210/full/v13/i8/1049.htm>

**DOI:** <https://dx.doi.org/10.4252/wjsc.v13.i8.1049>

## INTRODUCTION

The purpose of regenerative medicine is to restore the function of damaged, malfunctioning, or missing tissues. Recently, scientists have focused on the explanation of stem cells in regeneration and applying this knowledge to meet human needs and finding newer and more efficient therapeutic methods. The discovery of stem cells has revolutionized regenerative medicine and brought new hope for the treatment of some currently incurable diseases[1,2]. Stem cells are roughly divided into two categories based on their origin: Embryonic (from the inner cell mass of blastocysts) and adult stem cells (from multiple tissue types, such as bone marrow, fat, and Wharton's jelly) [3]. Stem cells are extraordinary because they can self-renew and differentiate into multiple cell lineages, particularly embryonic stem cells (ESCs)[4]. Even so, it is still incredible that a single type and limited number of stem cell-attributed cells can initiate *de novo* generation of appendages/organs in postnatal mammals. However, deer antlers provide a rare anomaly to this rule.

Antlers can be used as an ideal model to examine the regeneration processes of tissues, because they are the only mammalian appendage organs that can regenerate annually[5]. The basis of antler renewal is dependent on the proliferation and differentiation of antler stem cells (AnSCs); their progeny can maintain the full regeneration of the antler every year, and the cells derived from the progeny can drive an astonishing growth of the antler (up to 2 cm/d)[6]. Real-time PubMed searches using the terms "antler stem cell", "antler AND stem cell", and "adipose derived stem cell" led to 11, 45, and 12277 results, respectively. Therefore, as a relative new field, a more comprehensive understanding of AnSCs will lay the foundation for developing an effective clinical therapy for regenerative medicine.

## ANNUAL RENEWAL OF DEER ANTLERS: THE ONLY EPIMORPHIC REGENERATION CASE IN MAMMALS

Deer antlers and osseous cranial appendages are secondary sexual appendages in males and can be fully regenerated once lost[7,8]. Antlers are located on the frontal bone (the bone forming the forehead and the upper parts of the orbits) and enable stem cell-based organogenesis, annual casting, and *de novo* regeneration.

The annual antler renewal cycle is as follows: In spring, old ossified antlers are cast and nascent antlers start to grow from the permanent bony protuberances, known as pedicles; in summer, antlers rapidly grow and elongate; the growth of antlers slows down in late summer/early autumn and the antler is completely calcified in late

autumn. In winter, fully calcified antlers are firmly attached to their pedicles until the following spring, when they are cast again to trigger a new round of antler regeneration[9,10] (Figure 1). Antlers of deer provide us the unique opportunity to learn how nature has achieved full mammalian organ regeneration.

## ANSCS

Deer are not born with pedicles; they develop from their frontal crests when they approach puberty[11,12]. Pedicles and first antlers (Figure 2B) are originally formed from the frontal crest periosteum, termed as the antlerogenic periosteum (AP). The removal of AP eliminates the formation of the pedicle and the first antler, and transplantation of AP on the deer's body can induce the formation of an ectopic antler [13,14]. Morphological and histological studies have shown that the growth center of regenerating antlers (Figure 2C) is initially formed by the proliferation and differentiation of pedicle periosteum cells (PPCs)[15]. Tissue deletion[16] and membrane insertion[17] experiments further confirmed that annual antler regeneration depends entirely on the presence of PP tissue. The growth center of the antler (Figure 2D) is located at its tips[18,19]. An antler's rapid growth is mainly achieved through the activity of cells residing in the proliferation zone, *i.e.*, the reserve mesenchyme (RM) [20]. Therefore, RM cells (RMCs) must have a substantial potential for proliferation to sustain such a formidable growth rate (Figure 2).

The pedicle and antlers are structurally comprised of internal (cartilage and bone) and external components (skin, blood vessels, and nerves)[21,22]. The development and histogenesis of pedicles originate from the AP and occur during puberty[23]. As for the antler itself, it has been confirmed to be regenerated from PPCs[16]. It is important to note that the formation of the antler (the first set) occurs after birth, and it is derived from AP rather than PP.

The term "antler stem cells (AnSCs)" has been proposed to define the cells from the AP and PP. Cells from the AP[24], PP[25,26], and RM[27,28] have been isolated, cultured, and partially identified by several laboratories. Li *et al*[7] reported that *Oct4*, *Sox2*, and *Nanog*, known as core genes for pluripotency, exist in both AP cells (APCs) and PPCs, and these cells can be induced to differentiate into adipocytes, chondrocytes, osteocytes, and neuron-like cells *in vitro*. Wang *et al*[29] revealed that AnSCs expressed classic MSC markers, including CD73, CD90, CD105, and Stro-1. Some of the ESC and other stem cell markers, including Tert, Nestin, S100A4, nucleostemin, and c-Myc, can also be detected in AnSCs. Rolf *et al*[25] isolated Stro-1+ cells from the PP and RM and defined these cells as a type of MSCs. Seo *et al*[27] and Dąbrowska *et al* [30] cultured antler-derived multipotent cells from antler tips (roughly equivalent to RMCs), and found that the majority of them expressed CD105 and Oct4, as well as Oct4, Sox2, Klf4, Nanog, C-myc, Stat3, and CD9. These studies convincingly show that APCs, PPCs, and RMCs have stem cell attributes. Therefore, antler regeneration is a stem cell-based epimorphic process. The characterization of stem cell markers of AnSCs is summarized in Table 1[7,25,27,29-33]. These will be beneficial in advancing our understanding of AnSCs and their potential in regenerative medical science.

## ROLE OF ANSCS IN WOUND HEALING

Wound healing is a stopgap measure that normally results in scar formation, even under favorable conditions[34,35]. However, giant wounds on top of the pedicles can rapidly heal and leave almost no visible scar[15,36]. Goss[8] concluded that antler regeneration is a very special process because, in contrast to other wound healing processes in adult mammals, scar formation is completely avoided. Therefore, antlers offer us a rare opportunity to learn about how nature has solved the problem of scarring in wound healing in mammals.

### **Wound healing in deer is a natural process**

Each year, antler casting creates a large wound (up to 10 cm in diameter) on top of the pedicle (Figure 3A1). Interestingly, this wound can heal at an unprecedented speed of within a week (Figure 3A2 and A3) and achieve near-perfect regenerative healing (Figure 3A4). A combination of tissue deletion and transplantation demonstrated that PP bestows the power of scar-less wound healing on the distal pedicle skin[16,17]. If PP is totally or partially deleted prior to antler regeneration, wound healing over the

Table 1 Stem biomarkers shown to be present in antler stem cells

Marker	APC		PPC		RMC		Ref.
	Protein	mRNA	Protein	mRNA	Protein	mRNA	
Oct4		Y		Y	Y	Y	[7,27,30]
Nanog						Y	[30]
Sox2	Y		Y			Y	[30,31]
CD73	Y	Y	Y	Y	Y	Y	[29]
CD90	Y	Y	Y	Y	Y	Y	[29]
CD105	Y	Y	Y	Y	Y	Y	[29]
Stro-1	Y		Y		Y		[25,29]
Nestin	Y		Y		Y		[29]
CD9	Y		Y		Y	Y	[7,29,30,32,33]
CD29	Y		Y		Y		[29]
CD44	Y	Y	Y	Y	Y	Y	[29]
CD146	Y		Y		Y		[29]
Nucleostemin	Y						[7]
Telomerase	Y						[7]
Klf4						Y	[30]
C-myc	Y		Y		Y	Y	[29,30]
Statt3						Y	[30]
Tert	Y		Y		Y		[29]
S100A4	Y		Y		Y		[29,31]
CD63					Y		[32]
Calnexin					Y		[32]
Nanog	Y		Y				[31]

APC: Antlerogenic periosteum cells; PPC: Pedicle periosteum cells; RMC: Reserve mesenchyme cells.


top of the pedicle results in scarring.

Compared to typical deer scalp/pedicle skin, velvet skin is shiny and more sparsely populated with hairs. Histologically[37], this type of skin has a thicker epidermis and is adorned with hair follicles at different developmental stages. Underneath the velvet skin, there is a thin layer of compressed subcutaneous connective tissue that contains nerves and blood vessels. Compared to their conventional counterparts, blood vessels in velvet skin are peculiar, in that they have a much thicker wall and narrower lumen. Overall, velvet skin is a well-structured tissue rather than a disorganized scar.

### **Regenerative wound healing is not animal species-specific, but a stem cell-based process**

PP can induce regenerative wound healing in deer. To test if PPCs could function similarly in mammals other than deer, Li *et al*[38] summarized that full thickness punch-cut wounds in rats were completely healed on day 34 by direct injection of PPCs through the tail vein, whereas the healing rates lagged far behind in both the human mesenchymal stem cells and 3T3 fibroblasts control groups. At the same time, no visible scar can be detected in the PPCs-treated group. In addition, Rong *et al*[39] found that treatment of rats with full-thickness cutaneous wounds (2 cm × 2 cm) *via* direct injection of AnSCs can effectively induce regenerative wound healing (Figure 3B). Therefore, the induction of regenerative wound healing by AnSCs is not species-specific.

Interestingly, topical application of conditioned medium (CM) of AnSCs on cutaneous wounds can also effectively induce regenerative wound healing (Figure 3C)



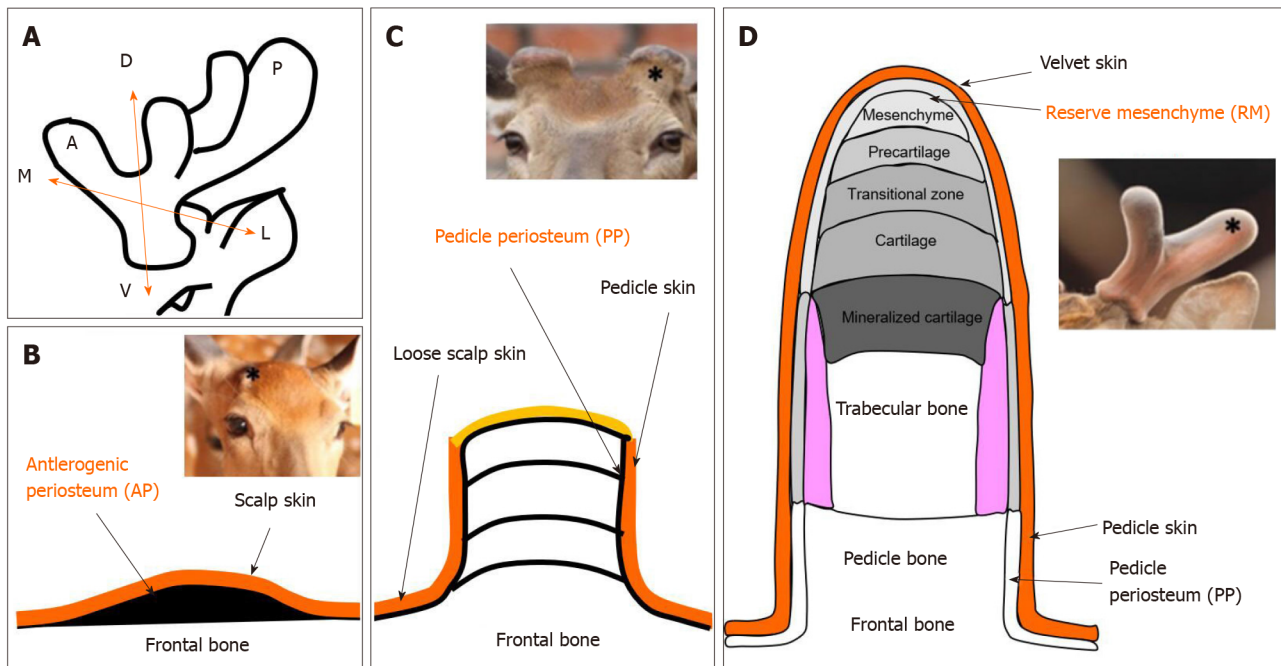
**Figure 1 Antler regeneration cycle**[11]. In spring, bony antlers drop off from their pedicle (permanent bony protuberance). Velvet antler regenerates immediately. In late spring and early summer, rapid antler growth occurs and antlers are covered with velvet skin in their growing phase. In autumn, antlers become completely calcified and the skin covering them starts to shed. In winter, dead bony antlers are attached to their living pedicles and eventually cast in spring next year, triggering a new round of antler regeneration. Citation: Li C, Chu W. The regenerating antler blastema: the derivative of stem cells resident in a pedicle stump. *Front Biosci (Landmark Ed)* 2016; 21: 455-467. Copyright © Frontiers in Bioscience. Published by Frontiers in Bioscience.

[40]. Content analysis of AnSCs-CM by protein chromatography revealed that relative peak area of the AnSCs-CM was significantly larger than those of the two controls, DMEM and MSCs-CM. Besides, the AnSCs-CM had two extra peaks. ELISA tests showed that EGF concentration in AnSCs-CM was significantly higher than that in MSCs-CM. Thus, AnSCs-CM, which contains more soluble components and growth factors, has great potential to be developed as a novel cell-free therapeutic approach for cutaneous wound healing.

## ROLE OF ANSCS IN BONE REGENERATION

Healthy bones possess the ability to auto-regenerate. However, large deficiencies in the bone structure as a result of trauma, congenital deformities, or extensive oncological surgery often require surgical reconstruction[41]. The antler, an osseous cranial appendage of male deer, is located on the frontal bone, enabling stem cell-based regenerating organogenesis[42]. An antler can generate up to 30 kg of bone tissue at rapid growth rates within a few months (up to 2.0 cm/d)[6,22]. Nowadays, the regeneration of antlers, a stem-cell-based process, has been noticed as a unique research model in bone regeneration and repair.

Cegielski *et al*[5] used an implant composed of AnSCs (MIC-1 cells, equal to RMCs) suspended in the reconstruction of ear cartilage lesions in rabbits. The results showed that implanted AnSCs were not rejected and were possibly involved in the reconstruction of missing parts of the rabbit ear cartilage. A two-year follow-up assay of xenogeneic implants of AnSCs into mandibular bone lesions in rabbits showed that



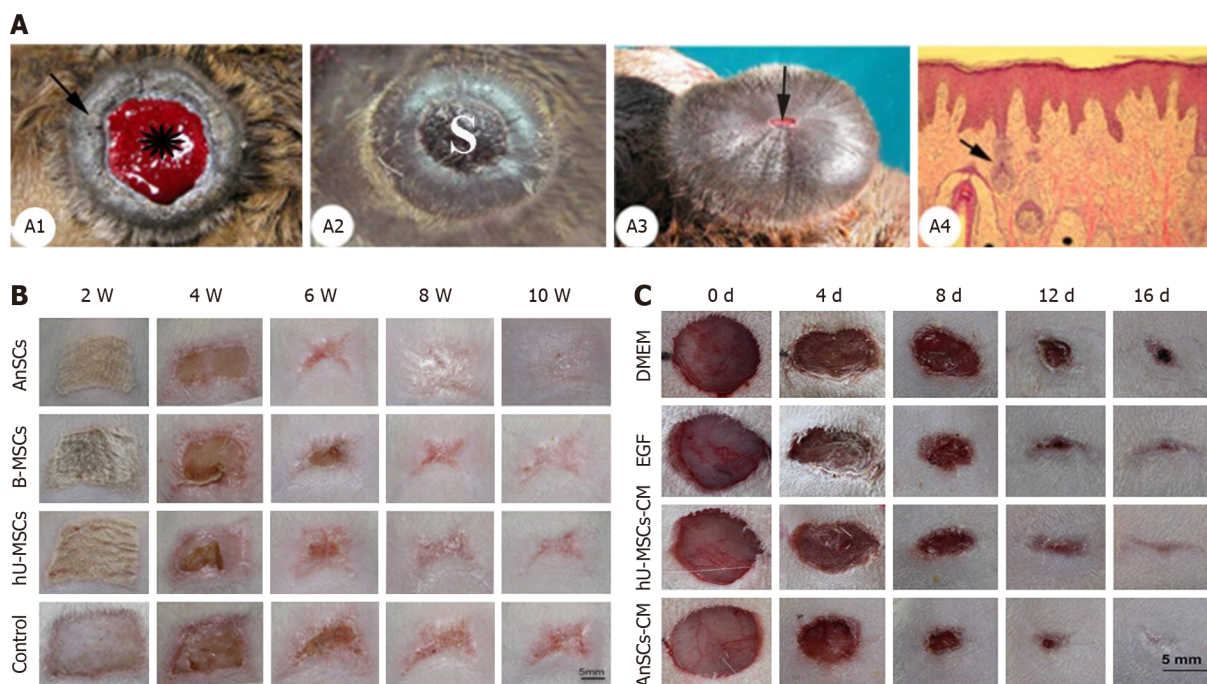
**Figure 2 Schematic diagram of locations of antler stem cells.** A: Schematic diagram to show the three axes of the antler development: A ↔ P: Anterior-posterior axis; D ↔ V: Dorso-ventral axis; M ↔ L: Medio-lateral axis; B: The antlerogenic periosteum is present in the embryo and after birth as a localized thickening of the periosteum of the frontal bone; C: Regeneration of an antler initiated from the cells residing in the pedicle periosteum; D: Endochondral bone growth occurs at the distal tip, and cells in the reserve mesenchyme are responsible for rapid antler growth. Star in insert figure: Location of antler stem cells.

the healing process at implantation sites was normal, with no local inflammatory response[43] (Figure 4). The defects in the bones were replaced by newly formed, thick fibrous bone tissue that underwent mineralization and was later remodeled into lamellar bone. These results suggest that bone regeneration in deer is a stem cell-based process and is not species-specific.

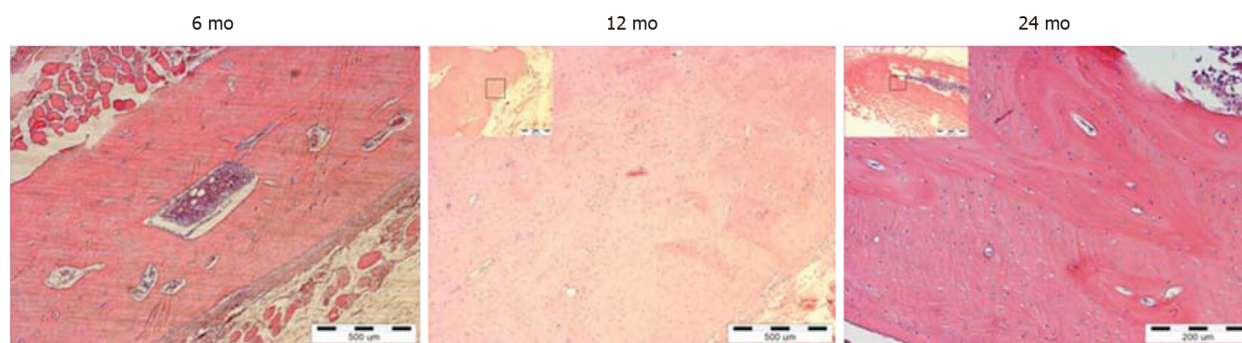
In addition, the same research group also demonstrated that implanted AnSCs have the potential to regenerate rabbit mandibular defects[30]. In addition, their homogenates (collected directly from AnSCs by homogenizer) and culture supernatants (same as CM, prepared by post-culturing the AnSCs) also can effectively repair the mandibular defects in rabbit[30]. Both AnSCs and AnSCs-derived cell-free preparations play important roles in biological stimulation of the recipient organism. These results provide a wide range of possibilities for their use in bone repair.

## FUTURE DIRECTIONS

The regeneration of antlers is not only a natural wonder, but also potentially translatable into clinical use. The fact that AnSCs can induce regenerative wound healing and bone repair in mammals other than deer has opened a new avenue for the development of therapies for clinical use. Collection of AnSCs do not have to kill deer. Preparation of APCs and PPCs just need limited invasive surgeries, while RMCs were originated from tips of fresh commercial antlers. Laboratory data showed that AnSC can be cultured and passed without differentiation, thus, we can efficiently recover AnSCs in GMP conditions after simple optimization. Currently, MSCs from different sources have been widely used for the treatment of wound healing and bone repair, and many countries have approved human MSC products for the treatment of osteoarthritis. Nonetheless, AnSCs are heterologous to humans and cannot be directly injected. Notably, functional contents from cell homogenates and cell post-culture supernatants of AnSCs also have the potential for wound healing and bone regenerative repair. Although the exact ingredients have not been thoroughly studied, these findings undoubtedly offer a potential opportunity to develop a cell-free therapy in the clinic. Further research should unequivocally discover the AnSCs-derived functional molecules, and combine them with ideal materials to treat wounds and bone defects, as well as other defect diseases.



**Figure 3 Antler stem cells-induced wound healing process in deer and rats**[38-40]. A: Wound healing over the top of a pedicle stump following casting of a bony antler. A1: Pedicle with a fresh casting surface. A2: Apical surface of a pedicle a few days after hard antler casting. A3: Apical view of a late wound healing-stage pedicle. The scab becomes negligible. A4: Histological section of sagittal-cut healing skin; B and C: Gross morphological changes during wound healing occurring either *via* direct injection of antler stem cells (AnSCs) into the rats (B) or topical application of conditioned medium of AnSCs on to the wounds (C). hU-MSCs: Human mesenchymal stem cells; B-MSCs: Rat bone marrow mesenchymal stem cells; AnSCs: Antler stem cells. Citation for Figure 3A[38]: Li C, Suttie JM. Histological studies of pedicle skin formation and its transformation to antler velvet in red deer (*Cervus elaphus*). *Anat Rec* 2000; 260: 62-71. Copyright © Li Chunyi. Published by Mapsci Digital Publisher OPC Pvt Ltd. Citation for Figure 3B[39]: Rong X, Zhang G, Yang Y, Gao C, Chu W, Sun H, Wang Y, Li C. Transplanted Antler Stem Cells Stimulated Regenerative Healing of Radiation-induced Cutaneous Wounds in Rats. *Cell Transplant* 2020; 29: 963689720951549. Copyright © The author(s). Published by SAGE Publications Inc. Citation for Figure 3C[40]: Rong X, Chu W, Zhang H, Wang Y, Qi X, Zhang G, Wang Y, Li C. Antler stem cell-conditioned medium stimulates regenerative wound healing in rats. *Stem Cell Res Ther* 2019; 10: 326. Copyright © The author(s). Published by BioMed Central.



**Figure 4 Regeneration of bone lesion after implantation of antler stem cells in mandibular bone lesions in rabbits**[43]. Six and twelve months post antler stem cells implantation, restructuring of coarse fibrous bone into lamellar bone tissue occurred. Twenty-four months after implantation, mature lamellar bone developed, with visible osteons and two or three systemic lamellae around blood vessels. H&E staining in all sections. Citation: Cegielski M, Dziewiszek W, Zabel M, Dziegiel P, Kuryszko J, Izykowska I, Zatoński M, Bochnia M. Experimental xenotransplantation of antlerogenic cells into mandibular bone lesions in rabbits: two-year follow-up. *In Vivo* 2010; 24: 165-172. Copyright © International Institute of Anticancer Research. Published by International Institute of Anticancer Research.

## CONCLUSION

Antler renewal is a stem cell-based epimorphic process, and AnSCs can initiate *de novo* generation of antlers in postnatal mammals. Previous studies have demonstrated that AnSCs express both classic MSC and ESC markers and can be induced to differentiate into multiple cell lineages *in vitro*. Previous studies have also indicated that both AnSCs and preparations derived from AnSCs have biological stimulatory functions in wound healing and osteogenesis. Functional analysis of AnSCs and separation and purification of AnSCs-derived molecules may become popular in the healing of wounds and in the repair of bone in the future.

## REFERENCES

- 1 **Brignier AC**, Gewirtz AM. Embryonic and adult stem cell therapy. *J Allergy Clin Immunol* 2010; **125**: S336-S344 [PMID: 20061008 DOI: 10.1016/j.jaci.2009.09.032]
- 2 **Henningson CT Jr**, Stanislaus MA, Gewirtz AM. Embryonic and adult stem cell therapy. *J Allergy Clin Immunol* 2003; **111**: S745-S753 [PMID: 12592319 DOI: 10.1067/mai.2003.133]
- 3 **Khanlarkhani N**, Baazm M, Mohammadzadeh F, Najafi A, Mehdinejadani S, Sobhani A. Multipotent Stem Cell and Reproduction. *J Stem Cells* 2016; **11**: 219-229 [PMID: 28296874]
- 4 **Slack JMW**. What is a stem cell? *Wiley Interdiscip Rev Dev Biol* 2018; **7**: e323 [PMID: 29762894 DOI: 10.1002/wdev.323]
- 5 **Cegielski M**, Dziewiszek W, Zabel M, Dziegiel P, Izycki D, Zatoński M, Bochnia M. Experimental application of xenogenous antlerogenic cells in replacement of auricular cartilage in rabbits. *Xenotransplantation* 2008; **15**: 374-383 [PMID: 19152665 DOI: 10.1111/j.1399-3089.2008.00497.x]
- 6 **Goss RJ**. Tumor-like growth of antlers in castrated fallow deer: an electron microscopic study. *Scanning Microsc* 1990; **4**: 715-20; discussion 720 [PMID: 2080434 DOI: 10.1002/jemt.1060160113]
- 7 **Li C**, Yang F, Sheppard A. Adult stem cells and mammalian epimorphic regeneration—insights from studying annual renewal of deer antlers. *Curr Stem Cell Res Ther* 2009; **4**: 237-251 [PMID: 19492976 DOI: 10.2174/157488809789057446]
- 8 **Goss RJ**. Future directions in antler research. *Anat Rec* 1995; **241**: 291-302 [PMID: 7755168 DOI: 10.1002/ar.1092410302]
- 9 **Goss RJ**. Photoperiodic control of antler cycles in deer. III. Decreasing versus increasing day lengths. *J Exp Zool* 1976; **197**: 307-312 [PMID: 965912 DOI: 10.1002/jez.1401970302]
- 10 **Li C**, Zhao H, Liu Z, McMahon C. Deer antler—a novel model for studying organ regeneration in mammals. *Int J Biochem Cell Biol* 2014; **56**: 111-122 [PMID: 25046387 DOI: 10.1016/j.biocel.2014.07.007]
- 11 **Li C**, Chu W. The regenerating antler blastema: the derivative of stem cells resident in a pedicle stump. *Front Biosci (Landmark Ed)* 2016; **21**: 455-467 [PMID: 26709786 DOI: 10.2741/4401]
- 12 **Li C**, Suttie JM. Pedicle and antler regeneration following antlerogenic tissue removal in red deer (*Cervus elaphus*). *J Exp Zool* 1994; **269**: 37-44 [PMID: 8207380 DOI: 10.1002/jez.1402690105]
- 13 **Hartwig H**, Schrudde J. Experimentelle Untersuchungen zur Bildung der primären Stirnanswüchse beim Reh (*Capreolus capreolus* L.). *Zeitschrift F Ur Jagdwissenschaft* 1974; **20**: 1-13
- 14 **Goss RJ**, Powel RS. Induction of deer antlers by transplanted periosteum. I. Graft size and shape. *J Exp Zool* 1985; **235**: 359-373 [PMID: 4056697 DOI: 10.1002/jez.1402350307]
- 15 **Li C**, Suttie JM, Clark DE. Morphological observation of antler regeneration in red deer (*Cervus elaphus*). *J Morphol* 2004; **262**: 731-740 [PMID: 15487018 DOI: 10.1002/jmor.10273]
- 16 **Li C**, Mackintosh CG, Martin SK, Clark DE. Identification of key tissue type for antler regeneration through pedicle periosteum deletion. *Cell Tissue Res* 2007; **328**: 65-75 [PMID: 17120051 DOI: 10.1007/s00441-006-0333-y]
- 17 **Li C**, Yang F, Li G, Gao X, Xing X, Wei H, Deng X, Clark DE. Antler regeneration: a dependent process of stem tissue primed via interaction with its enveloping skin. *J Exp Zool A Ecol Genet Physiol* 2007; **307**: 95-105 [PMID: 17177282 DOI: 10.1002/jez.a.352]
- 18 **Price JS**, Oyajobi BO, Oreffo RO, Russell RG. Cells cultured from the growing tip of red deer antler express alkaline phosphatase and proliferate in response to insulin-like growth factor-I. *J Endocrinol* 1994; **143**: R9-16 [PMID: 7829985 DOI: 10.1677/joe.0.143r009]
- 19 **Li C**, Clark DE, Lord EA, Stanton JA, Suttie JM. Sampling technique to discriminate the different tissue layers of growing antler tips for gene discovery. *Anat Rec* 2002; **268**: 125-130 [PMID: 12221718 DOI: 10.1002/ar.10120]
- 20 **Clark DE**, Li C, Wang W, Martin SK, Suttie JM. Vascular localization and proliferation in the growing tip of the deer antler. *Anat Rec A Discov Mol Cell Evol Biol* 2006; **288**: 973-981 [PMID: 16892427 DOI: 10.1002/ar.a.20364]
- 21 **Li C**. Histogenetic aspects of deer antler development. *Front Biosci (Elite Ed)* 2013; **5**: 479-489 [PMID: 23277003 DOI: 10.2741/e629]
- 22 **Price JS**, Allen S, Faucheux C, Althnaian T, Mount JG. Deer antlers: a zoological curiosity or the key to understanding organ regeneration in mammals? *J Anat* 2005; **207**: 603-618 [PMID: 16313394 DOI: 10.1111/j.1469-7580.2005.00478.x]
- 23 **Li C**, Suttie JM. Deer antlerogenic periosteum: a piece of postnatally retained embryonic tissue? *Anat Embryol (Berl)* 2001; **204**: 375-388 [PMID: 11789985 DOI: 10.1007/s004290100204]
- 24 **Li C**, Littlejohn RP, Suttie JM. Effects of insulin-like growth factor I and testosterone on the proliferation of antlerogenic cells in vitro. *J Exp Zool* 1999; **284**: 82-90 [PMID: 10368936]
- 25 **Rolf HJ**, Kierdorf U, Kierdorf H, Schulz J, Seymour N, Schliephake H, Napp J, Niebert S, Wölfel H, Wiese KG. Localization and characterization of STRO-1 cells in the deer pedicle and regenerating antler. *PLoS One* 2008; **3**: e2064 [PMID: 18446198 DOI: 10.1371/journal.pone.0002064]
- 26 **Li C**, Suttie J. Morphogenetic aspects of deer antler development. *Front Biosci (Elite Ed)* 2012; **4**: 1836-1842 [PMID: 22202000 DOI: 10.2741/505]
- 27 **Seo MS**, Park SB, Choi SW, Kim JJ, Kim HS, Kang KS. Isolation and characterization of antler-derived multipotent stem cells. *Cell Transplant* 2014; **23**: 831-843 [PMID: 23294672 DOI: 10.3727/096368912X661391]
- 28 **Sadighi M**, Li C, Littlejohn RP, Suttie JM. Effects of testosterone either alone or with IGF-I on



- growth of cells derived from the proliferation zone of regenerating antlers in vitro. *Growth Horm IGF Res* 2001; **11**: 240-246 [PMID: 11735240 DOI: 10.1054/ghir.2001.0232]
- 29 **Wang D**, Berg D, Ba H, Sun H, Wang Z, Li C. Deer antler stem cells are a novel type of cells that sustain full regeneration of a mammalian organ-deer antler. *Cell Death Dis* 2019; **10**: 443 [PMID: 31165741 DOI: 10.1038/s41419-019-1686-y]
- 30 **Dąbrowska N**, Kielbowicz Z, Nowacki W, Bajzert J, Reichert P, Bieżyński J, Zebrowski J, Haczkiwicz K, Cegielski M. Antlerogenic stem cells: molecular features and potential in rabbit bone regeneration. *Connect Tissue Res* 2016; **57**: 539-554 [PMID: 26076011 DOI: 10.3109/03008207.2015.1045139]
- 31 **Li C**, Harper A, Puddick J, Wang W, McMahon C. Proteomes and signalling pathways of antler stem cells. *PLoS One* 2012; **7**: e30026 [PMID: 22279561 DOI: 10.1371/journal.pone.0030026]
- 32 **Yang C**, Sun S, Zhang Q, Guo J, Wu T, Liu Y, Yang M, Zhang Y, Peng Y. Exosomes of Antler Mesenchymal Stem Cells Improve Postoperative Cognitive Dysfunction in Cardiopulmonary Bypass Rats through Inhibiting the TLR2/TLR4 Signaling Pathway. *Stem Cells Int* 2020; **2020**: 2134565 [PMID: 32300366 DOI: 10.1155/2020/2134565]
- 33 **Wang D**, Ba H, Li C, Zhao Q. Proteomic Analysis of Plasma Membrane Proteins of Antler Stem Cells Using Label-Free LC-MS/MS. *Int J Mol Sci* 2018; **19** [PMID: 30400663 DOI: 10.3390/ijms19113477]
- 34 **Singer AJ**, Clark RA. Cutaneous wound healing. *N Engl J Med* 1999; **341**: 738-746 [PMID: 10471461 DOI: 10.1056/NEJM199909023411006]
- 35 **Hocking AM**. Mesenchymal Stem Cell Therapy for Cutaneous Wounds. *Adv Wound Care (New Rochelle)* 2012; **1**: 166-171 [PMID: 24527299 DOI: 10.1089/wound.2011.0294]
- 36 **Li C**, Suttie JM, Clark DE. Histological examination of antler regeneration in red deer (*Cervus elaphus*). *Anat Rec A Discov Mol Cell Evol Biol* 2005; **282**: 163-174 [PMID: 15641024 DOI: 10.1002/ar.a.20148]
- 37 **Li C**, Suttie JM. Histological studies of pedicle skin formation and its transformation to antler velvet in red deer (*Cervus elaphus*). *Anat Rec* 2000; **260**: 62-71 [PMID: 10967537 DOI: 10.1002/1097-0185(20000901)260:1<62::AID-AR70>3.0.CO;2-4]
- 38 **Li C**. Antler Stem Cells Sustain Regenerative Wound Healing in Deer and in Rats. *J Regenerat Biol Med* 2020; **2**: 1-8 [DOI: 10.37191/Mapsci-2582-385X-2(1)-016]
- 39 **Rong X**, Zhang G, Yang Y, Gao C, Chu W, Sun H, Wang Y, Li C. Transplanted Antler Stem Cells Stimulated Regenerative Healing of Radiation-induced Cutaneous Wounds in Rats. *Cell Transplant* 2020; **29**: 963689720951549 [PMID: 32907381 DOI: 10.1177/0963689720951549]
- 40 **Rong X**, Chu W, Zhang H, Wang Y, Qi X, Zhang G, Li C. Antler stem cell-conditioned medium stimulates regenerative wound healing in rats. *Stem Cell Res Ther* 2019; **10**: 326 [PMID: 31744537 DOI: 10.1186/s13287-019-1457-9]
- 41 **Rotter N**, Haisch A, Bücheler M. Cartilage and bone tissue engineering for reconstructive head and neck surgery. *Eur Arch Otorhinolaryngol* 2005; **262**: 539-545 [PMID: 16091977 DOI: 10.1007/s00405-004-0866-1]
- 42 **Feleke M**, Bennett S, Chen J, Hu X, Williams D, Xu J. New physiological insights into the phenomena of deer antler: A unique model for skeletal tissue regeneration. *J Orthop Translat* 2021; **27**: 57-66 [PMID: 33437638 DOI: 10.1016/j.jot.2020.10.012]
- 43 **Cegielski M**, Dziewiszek W, Zabel M, Dziegiel P, Kuryszko J, Izykowska I, Zatoński M, Bochnia M. Experimental xenotransplantation of antlerogenic cells into mandibular bone lesions in rabbits: two-year follow-up. *In Vivo* 2010; **24**: 165-172 [PMID: 20363989 DOI: 10.1089/hum.2010.1312]



Published by **Baishideng Publishing Group Inc**  
7041 Koll Center Parkway, Suite 160, Pleasanton, CA 94566, USA

**Telephone:** +1-925-3991568

**E-mail:** [bpgoffice@wjgnet.com](mailto:bpgoffice@wjgnet.com)

**Help Desk:** <https://www.f6publishing.com/helpdesk>

<https://www.wjgnet.com>

