


Optical Brain Biopsy with a Fluorescence and Vessel Tracing Probe

Johan Richter, MD, PhD      

Neda Haj-Hosseini, MSc,
PhD 

Peter Milos, MD 

Martin Hallbeck, MD, PhD   

Karin Wårdell, MSc, PhD 

[‡]Department of Biomedical Engineering, Linköping University, Linköping, Sweden; [§]Department of Neurosurgery, Linköping University, Linköping, Sweden; [¶]Department of Biomedical and Clinical Sciences, Linköping University, Linköping, Sweden; ^{||}Department of Clinical Pathology, Linköping University, Linköping, Sweden

*Johan Richter and Neda Haj-Hosseini contributed equally to this work.

Correspondence:

Johan Richter, MD, PhD,
Department of Neurosurgery,
Linköping University,
SE-58185 Linköping, Sweden.
Email:
johan.richter@regionostergotland.se

Received, October 26, 2020.

Accepted, April 29, 2021.

Published Online, June 30, 2021.

© Congress of Neurological Surgeons 2021.

This is an Open Access article distributed under the terms of the Creative Commons Attribution-NonCommercial License (<http://creativecommons.org/licenses/by-nc/4.0/>), which permits non-commercial re-use, distribution, and reproduction in any medium, provided the original work is properly cited. For commercial re-use, please contact journals.permissions@oup.com

BACKGROUND: Accurate stereotactic biopsies of brain tumors are imperative for diagnosis and tailoring of the therapy. Repetitive needle insertions enhance risks of brain lesioning, hemorrhage, and complications due to prolonged procedure.

OBJECTIVE: To investigate clinical benefits of a combined 5-aminolaevulinic acid (5-ALA) fluorescence and laser Doppler flowmetry system for the detection of malignant brain tumor and blood vessels in stereotactic biopsies.

METHODS: Planning of targets and trajectories was followed by optical measurements in 20 patients, using the Leksell Stereotactic System and a manual insertion device. Fluorescence spectra, microvascular blood flow, and tissue grayness were recorded each millimeter along the paths. Biopsies were taken at preplanned positions. The diagnoses were compared with the fluorescence signals. The recordings were plotted against measurement positions and compared. Sites indicating a risk of hemorrhage were counted as well as the time for the procedures.

RESULTS: Signals were recorded along 28 trajectories, and 78 biopsies were collected. The final diagnosis showed 17 glioblastomas, 2 lymphomas, and 1 astrocytoma grade III. Fluorescence was seen along 23 of the paths with 4 having the peak of 5-ALA fluorescence 3 mm or more from the precalculated target. There was increased microcirculation in 40 of 905 measured positions. The measurement time for each trajectory was 5 to 10 min.

CONCLUSION: The probe provided direct feedback of increased blood flow along the trajectory and of malignant tissue in the vicinity of the target. The method can increase the precision and the safety of the biopsy procedure and reduce time.

KEY WORDS: Biopsy, Optical, Tumor, Fluorescence, Spectroscopy, Stereotactic navigation, 5-ALA

Operative Neurosurgery 21:217–224, 2021

<https://doi.org/10.1093/ons/opab216>

Accurate stereotactic biopsies of brain tumors are imperative for diagnosis and tailoring of the therapy.¹ Despite accurate planning, the intracranial conditions can change, eg, by brain shift, conceivably causing misdiagnosis. Diffuse limitations of the tumor do not always correspond to contrast enhancing magnetic resonance imaging (MRI).² Neuronavigation systems^{3,4} can visualize the needle trajectory based on the preoperative MRI but cannot give direct feedback on the tissue at

the target. These are typical reasons for repetitive needle insertions, enhancing risks of brain lesioning, hemorrhage,⁵ and complications due to prolonged procedure. There is therefore a need to improve the precision and reduce the risks of stereotactic biopsies.^{6–8}

Experience in 5-aminolaevulinic acid (5-ALA) fluorescence guidance for brain tumor resection may be applied to biopsies. Hefti et al⁹ presented the use of fluorescence microscopy for direct investigation of tissue samples in the operating room (OR). Widhalm and colleagues¹⁰ applied the blue-light neurosurgical microscope to examine stereotactically acquired tissue samples. Fluorescence microscopy demonstrated potential clinical benefits by the reduced number of biopsy samples and shorter surgical time. The grading was done visually, however, thus subjectively. Also, it was done extracranially, as with all current methods. The concept of utilizing

ABBREVIATIONS: 5-ALA, 5-aminolaevulinic acid; D, diagnostic; HGT, high-grade tumor; LDF, laser Doppler flowmetry; LSS, Leksell Stereotactic System; ND, nondiagnostic; Neg, negative; NM, not measurable; OR, operating room; Pos, positive; PpIX, protoporphyrin IX; TC, tumor cell; TLI, total light intensity

5-ALA fluorescence for biopsies is, however, not entirely new. A fluorescence system with dual laser sources and an optical fiber was evaluated at Linköping University Hospital during stereotactic biopsies in the beginning of the millennium.¹¹ The idea was reinvented as a hand-held probe for fluorescence recording during resection¹² and further modified for stereotactic systems.¹³ Optical fibers were added to also include microcirculation recordings by laser Doppler flowmetry (LDF).¹⁴ In contrast to other techniques,¹⁵⁻¹⁸ LDF presents blood flow as real-time curves, a method originally designed for stereotactic deep brain stimulation (DBS) implantations.^{19,20} These combined features enable the forward-looking probe to act as a “vessel alarm” along the trajectory of the needle and at the same time as a tumor detector.

The aim of the study was to investigate the workability and the safety of the use of the combined 5-ALA fluorescence and LDF probe for possible clinical benefits in patients undergoing stereotactic brain tumor biopsies. Emphasis was set on efficacy of real-time malignant tissue identification and safety by detecting increased blood flow along the trajectory and overall efficiency of the intervention.

METHODS

Patients

Twenty consecutive patients with a suspected brain tumor, not eligible for resection, were referred for biopsy and included in the study. The study was approved by the local ethics board (M 129-07, 2015/138-32), and all patients gave informed written consent. The patients were given 5-ALA orally (20 mg/kg, Gliolan[®], Medac GmbH, Wedel, Germany)²¹ 2 to 3 h prior to surgery.

Imaging and Trajectory Planning

Stereotactic T₁-weighted MRI (Ingenia 3T, Philips Healthcare, Eindhoven, The Netherlands) and/or computed tomography (GE Light-speed Ultra, GE Healthcare, Amersham, United Kingdom) with contrast medium were performed on the day of surgery. Up to 3 trajectories were planned with Surgiplan[®] (Elekta Instrument AB, Stockholm, Sweden) in each case. Biopsy positions were defined at -6 or -5 mm, -3 mm, 0 (target), and +3 and +5 or +6 mm. The biopsy procedure and anesthesia were conducted according to the clinical routine with the addition that the optical probe was used to create the trajectory for the biopsy needle.

Optical Systems and Probe

A forward-looking optical probe combining 5-ALA-induced fluorescence and LDF measurements was used. The probe is compatible with the Leksell Stereotactic System (LSS, G-frame, Elekta Instrument AB, Stockholm, Sweden) at a length of 190 mm and a diameter of 2.2 mm. Blue laser light (wavelength 405 nm) interacts with the tissue and emits a spectrum with autofluorescence, and in the presence of protoporphyrin IX (PpIX), a peak at wavelength 635 nm (red color).^{12,22} The LDF records the tissue's microcirculation (perfusion, range 0-1000 arbitrary units, a.u.), and the gray-white variations (total light intensity [TLI] range 0-10 a.u.).¹⁴ Prior to sterilization with Sterrad[®], the probe was

tested in a standard microsphere solution (PF1001 Motility, Perimed AB, Järfälla, Sweden). This ascertained comparable LDF signal levels.¹³

Stereotactic Biopsy Procedure Using Optical Guidance

To create the trajectory for the biopsy needle and to detect increased blood flow indicative of vessels across the passage and thus to ultimately detect tumor tissue, the probe was conveyed forward from the cerebral cortex toward the planned target. A hand-driven insertion device positioned on the LSS ensured the controlled movement of the probe in 1-mm steps.¹⁴ This method was used in 18 of the surgeries. Frameless navigation (Stealth, S8, Medtronic Inc, Minneapolis, Minnesota) was implemented in combination with the LSS in 1 procedure and as a stand-alone tool in 2 procedures. At each tissue position, perfusion, and TLI were recorded over 5 to 10 s. This was followed by 3 fluorescence spectra (3 s). Immediate feedback on PpIX fluorescence, perfusion, and TLI was displayed on a monitor in the OR. In case of elevated perfusion (>100 a.u.),^{14,15} the measurement was extended.

When the planned positions were reached and the measurements finalized, the probe was removed and replaced with the side-cutting biopsy needle (diameter 2.1 mm, Backlund Catheter Insertion Needle Kit, Elekta Instruments AB, Stockholm, Sweden). Tissue samples were harvested clockwise in 4 quadrants. According to the clinical routine, the samples were sent for immediate smear-based section examination by a neuropathologist. The remaining samples were marked and used for detailed postoperative analysis.

Data Analysis and Statistics

The definitive diagnosis of the biopsies was based on the WHO grading,²³ approximately 2 wk after surgery by a neuropathologist. All biopsies were re-examined by a second, senior neuropathologist (M.H.). The pathological examination is described in earlier publications.^{12,13} Using the LDF movement artifacts between positions as landmarks, the average perfusion, TLI, and PpIX fluorescence were calculated postoperatively for each position. The ratio between PpIX at 635 nm and autofluorescence maximum in the same spectra was calculated according to previous definitions.²² The number of elevated perfusion values was based on defined intervals (A-peak: 101-250, B-peak 251-500, C-peak > 00 a.u.).¹⁴ C-peaks indicate the highest risk of hemorrhaging.

Curves representing the PpIX fluorescence ratio, perfusion, and TLI were plotted against measurement positions along the trajectories. The total trajectory length and length to the first PpIX peak were measured. Times for the measurements, surgery, and the waiting for the pathological investigation were summarized.

RESULTS

A total of 14 males and 6 females, with median age 64 (range 41-84 yr), were included in the study. The combined probe was successfully implemented during all stereotactic brain biopsies. Fluorescence spectra and LDF signals were recorded from 808 and 905 sites, respectively, along 28 trajectories. Biopsies were taken and analyzed using frozen sectioning during the operation. Additional biopsies were collected from a total of 78 sites. PpIX fluorescence was available along 23/28 trajectories. In 2 trajectories, the signal was blocked by blood at the probe tip, and along 3 trajectories, PpIX fluorescence was absent (Table).

TABLE. Fluorescence Response Along the Trajectory Paths, the Intraoperative Pathology Diagnosis, and the Final Diagnosis

Patient no.	No. of paths	Fluorescence along paths	Intraop diagnosis	Final diagnosis	0 mm fluorescence	0 mm diagnosis
1	1 (+1)	Pos	ND	Glioblastoma	Pos	HGT
2	2	Pos	-	Glioblastoma	Pos	HGT
		Pos	D		Neg	Glios + TC
3	1	Pos	D	Glioblastoma	Pos	HGT
4	1	Pos	D	Glioblastoma	Pos	Glios + TC
5	1	Pos	D	Glioblastoma	Pos	HGT
6	2	Neg	-	Glioblastoma	Neg	
		Pos	D		Pos	HGT
7	1	Pos	D	Glioblastoma	Pos	HGT
8	2	Pos	ND	Glioblastoma	Neg	HGT
		Pos	-		Pos	HGT
9	3	NM	D	Lymphoma	No signal	HGT
		Pos	-		Neg	HGT
		Pos	-		Pos	HGT
10	1	Pos	ND	Glioblastoma	Pos	HGT
11	1	Pos	D	Glioblastoma	Neg	Necrosis
12	1	Pos	D	Lymphoma	Pos	Glios + TC
13	1	Pos	D	Glioblastoma	Pos	HGT
14	1	Pos	D	Glioblastoma	Pos	HGT
15	2	NM	D	Glioblastoma	No signal	HGT
		Pos	-		Pos	HGT
16	1	Pos	D	Glioblastoma	Pos	HGT
17	1	Pos	D	Glioblastoma	Pos	HGT
18	3	Neg	-	Glioblastoma	Neg	-
		Neg	-		Neg	-
		Pos	D		Pos	HGT
19	1	Pos	D	Astrocytoma	Pos	HGT
20	1	Pos	D	Glioblastoma	Pos	HGT

ND: nondiagnostic; D: diagnostic; Pos: positive; Neg: negative; TC: tumor cell; HGT: high-grade tumor; NM: not measurable. Dash (-) is assigned to trajectories where no biopsies were taken.

The fluorescence signature usually started with a small peak, and increased when reaching and passing through the tumor, corresponding to the contrast enhancement in the MRI. A decrease of the peaks beyond the tumor could be observed in a few cases. A schematic setting and typical recordings from various locations are presented in Figure 1. The PpIX signals are plotted vs positions along the trajectory and compared to the MRI. In 4/23 trajectories, no PpIX was measured at the precalculated target. In 3 of these trajectories, PpIX fluorescence appeared within 3 mm from the target, and in 1 case, the fluorescence was visible already in the interval -30 to -13 mm (Figure 2) ahead of the intended target. Corresponding MRI with trajectories is presented in Figure 3. In another patient, weak PpIX fluorescence was visible -40 to -20 mm before the precalculated target and strong PpIX fluorescence appeared 0 to +5 mm beyond (Figures 4 and 5). In this patient, increased blood flow (A-peak) was found -11 to -12 mm from the target.

The intraoperative pathology diagnosis was reported within 48 ± 14 min (range 18-90 min, $n = 18$) from the time of biopsy sampling, including transport and pathology examination.

The duration for the pathology examination was 29 ± 10 min (range 15-53 min). For comparison, the optical measurement time varied between 5 and 10 min and depended on the length of the trajectory. The overall diagnostic yield for the intraoperative samples using frozen sectioning, without the aid of fluorescence measurements, was 85% (17 out of 20 patients). In comparison, PpIX fluorescence could be measured along at least 1 trajectory in all cases (Table). The final diagnoses were glioblastoma ($n = 17$), lymphomas ($n = 2$), and astrocytoma grade III ($n = 1$).

The setup with both the LSS and the Stealth system is presented in Figure 6. The PpIX peak is presented on the monitor in the background. One of these measurements was performed continuously and without stopping at each millimeter. PpIX ratio values are plotted against the measurement positions and visualized in Figure 7.

No hemorrhage was detected with LDF along any of the measured trajectories, although in one case, a bleeding was detected inside the tumor necrosis. In general, the blood flow was low along the trajectories. There were 34 A-peaks, 5 B-peaks, and 1 C-peak in 905 measurements. The TLI signals were below

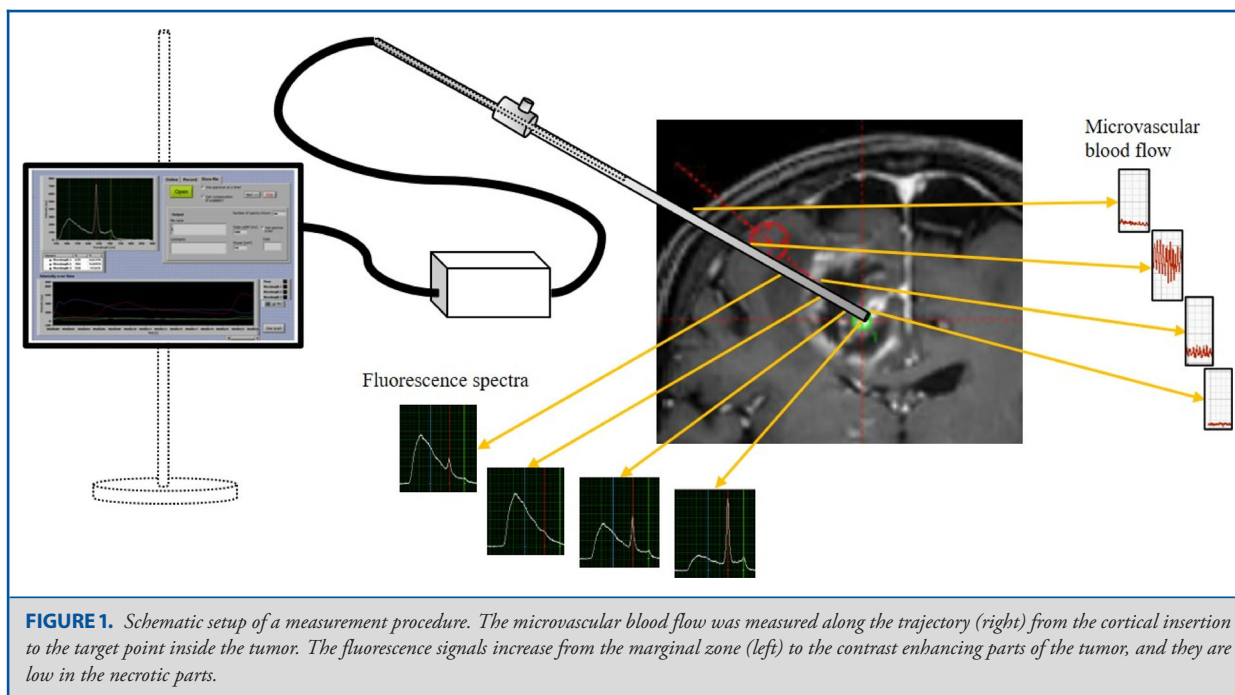


FIGURE 1. Schematic setup of a measurement procedure. The microvascular blood flow was measured along the trajectory (right) from the cortical insertion to the target point inside the tumor. The fluorescence signals increase from the marginal zone (left) to the contrast enhancing parts of the tumor, and they are low in the necrotic parts.

the measurable perfusion threshold in 73 sites. In Figure 4, an example of an A-peak is presented along the trajectory at -11 to -12 mm.

DISCUSSION

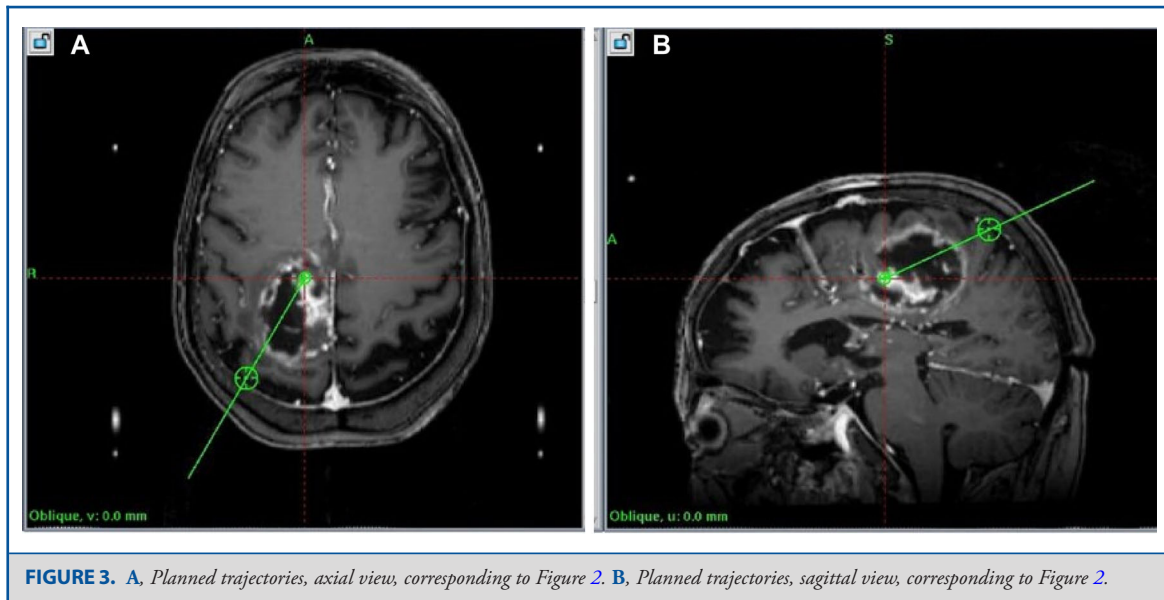
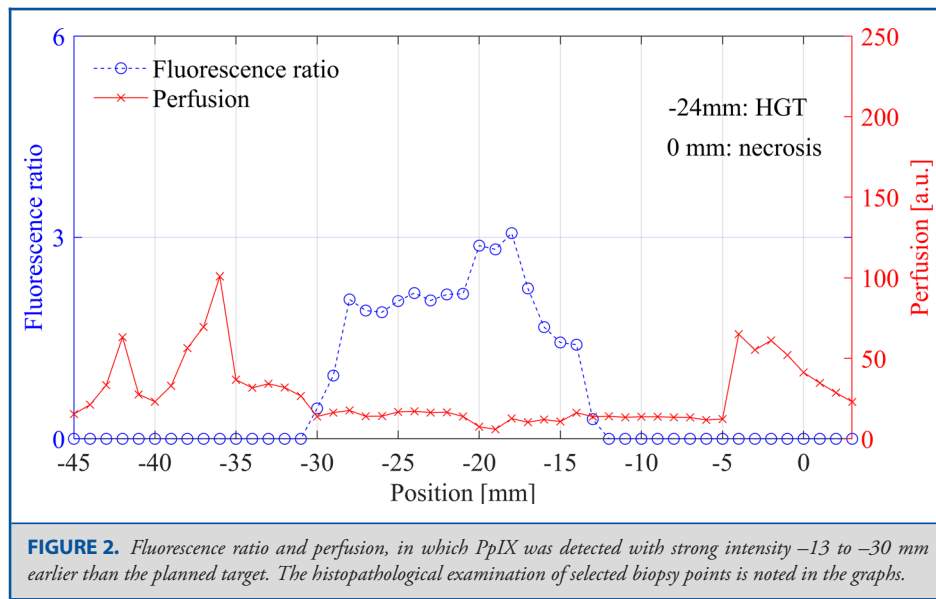
A forward-looking probe for 5-ALA fluorescence and blood flow detection during stereotactic biopsy was evaluated. The probe gave direct feedback of a malignant tumor and increased blood flow, as a warning of blood vessel presence. Both features may help increase the accuracy of tissue sampling as well as reduce the risks associated with repeated insertion of the biopsy needle.

By combining the LSS system and the mechanical insertion device,¹⁴ it was possible to compare the fluorescence spectra, blood flow, and gray-white reflectance with millimeter precision to the biopsy samples. For all surgeries, high PpIX fluorescence was visible along at least one of the planned trajectories. Not all samples taken at the planned target point were diagnostic, but where the fluorescence peak was high, the samples were diagnostic. This suggests that fluorescence may be used to increase the diagnostic yield of stereotactic biopsies.

In the first measurement session, clear PpIX peaks were found along the first trajectory. The first report on the intraoperative histopathology could not confirm the hypothesized diagnosis. For that reason, a second trajectory became necessary, however, without access to the optical equipment. The final histopathology diagnosis confirmed the initial measurement of PpIX fluorescence as a high-grade tumor (Table, case 1). In the following biopsies, optical measurements were made for all trajec-

tories. In another case, a discrepant finding in comparison to the contrast enhancing volume on the MRI was seen. Distinct fluorescence peaks were found along the trajectory before the planned main target point was reached (at -30 to -13 mm; Figures 2 and 3A and 3B). Biopsies at these levels confirmed high-grade tumor both with the intraoperative and postoperative histology. Despite the small number of patients, the findings demonstrate potential clinical benefit by reducing the number of trajectories and biopsies. In addition to the 18 high-grade gliomas, 2 of the patients with fluorescence peaks were diagnosed with lymphoma. Previous investigations with the blue-light microscope have confirmed the applicability for lymphoma in 5-ALA fluorescence guidance.^{10,24,25}

When the system was used with frameless navigation, the probe could be calibrated and used in a similar fashion as previously described with ultrasound navigation.²⁶ Data were collected in real time in a similar way as with the LSS. However, it was difficult to link the exact measurement position along the trajectory without the mechanical drive. The use of the LSS together with the mechanical insertion device made it possible to compare optical data with the histopathological results of the biopsies with a precision of 1 to 2 mm. This procedure, however, is only necessary when investigating the correlation between different modalities in order to demonstrate the accuracy of this novel concept. In clinical practice, it can be omitted. For optimal use with frameless navigation, a future redesign of the probe is necessary. This may be preferable, as modern frameless navigation systems allow for swifter handling in the OR with sufficient accuracy, without the inconveniences associated with the application of the conventional stereotactic frames. However,

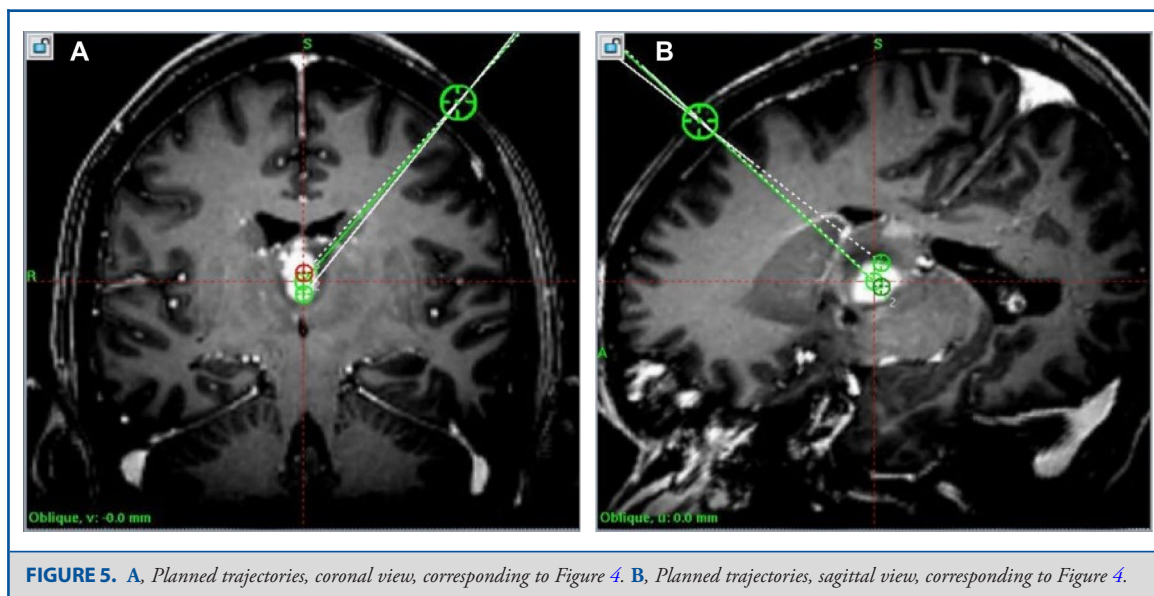
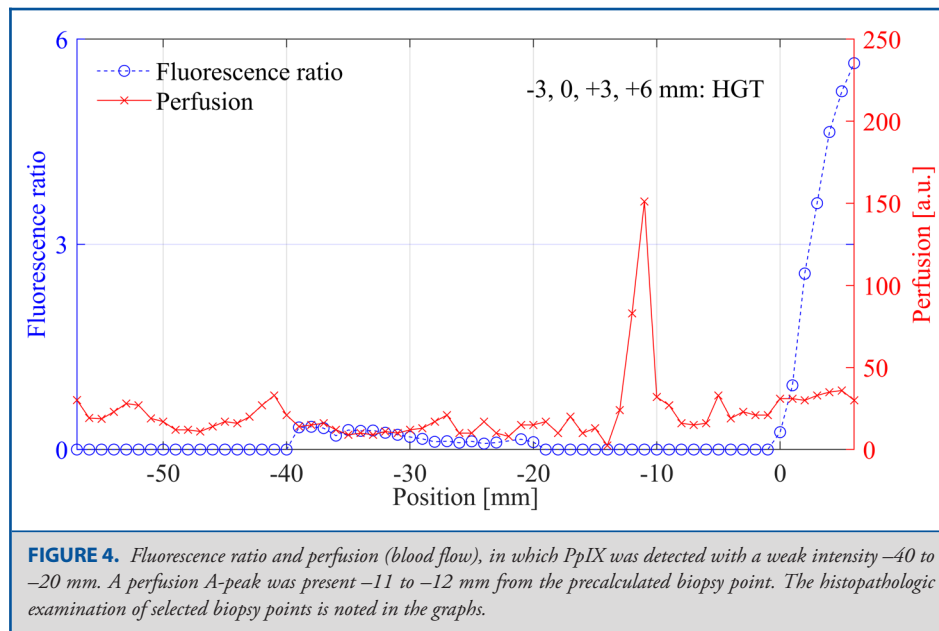


the conventional stereotactic systems are still widespread in use. The new design of the probe will be compatible with these systems as well.

In stereotactic brain biopsies, every new trajectory poses a separate risk of lesioning cerebral tissue or causing hemorrhage. Bleeding caused by the actual tissue collection, due to pathological vessel structures in the tumorous tissue, is thus not always possible to avoid. Some localizations do present higher risks of lesioning vessels, eg, around the insula or the thalamus. If possible, these risks are minimized by meticulous preoperative planning, where a trajectory is directed to avoid radiologically visible blood vessels

on T₁ MRI with contrast media. Nonetheless, the smallest vessels do not always appear on MRI. Also, brain shift may put the most thorough planning of the trajectory at risk. To detect vessels along the trajectory, a forward-looking device is necessary. The LDF component provides this function, as has been documented in more than 130 DBS implantations.^{14,15,20}

The current probe design does not allow for simultaneous measurement at the exact position of the biopsy as suggested by other groups.^{16,19} Considering that the biopsy region already has been monitored with the forward-looking probe when passing the intended biopsy point by 2 to 6 mm, potential high blood



flow spots would have been found with this approach, and the biopsy samples are taken at the highest fluorescence peak. A probe with side-looking windows has previously been presented by us²⁷ in which LDF was combined with a lesioning and impedance measurement. That design is complex to implement in the clinical setting, and it does not provide the safety aspects as intended by our forward-looking probe. Inside the tumor, pathological vessels may still cause hemorrhages, as their structures and patterns are unphysiological and ubiquitous, but these bleeds are usually minor; thus, the effects are not comparable to a lesion of a branch

of cerebral arteries. In total, 4.4% of all LDF recorded locations showed increased blood flow. None were considered as high risk. This corresponds to data found during DBS surgery.^{14,15} Trajectories along high-risk biopsy regions such as the insula would probably increase the number of high blood flow indications from the LDF system.

The total time for controlled optical recording with the LSS and the mechanical device is dependent on the trajectory length. To capture a reliable LDF signal representing perfusion without interference from movement, the probe must be kept still. This

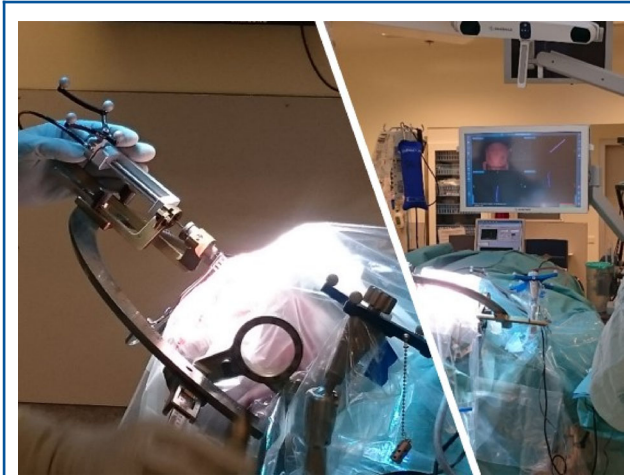


FIGURE 6. The Leksell Stereotactic System and the mechanical insertion device used together with the Stealth Navigation System.

is an inherent drawback with LDF, as the actual movements of the red blood cells in the microvasculature generate the Doppler shift, which is further processed to the LDF signal. Because of a thorough fixation of the probe to the LSS by the mechanical insertion device, no interference from external movements appears during a tissue recording. This only appears when the probe is moved from one site to the next. A typical recording time is 5 to 10 s when held still at the actual site. If the signal is high, the measurement can be prolonged in order to ascertain that there is no vasomotion or a rapid increase or decrease of the blood flow, both of which could indicate a vessel

structure. In a clinical routine implementation, the measurement time for a full-length trajectory of 50 to 60 mm can be reduced to approximately 5 min.

We anticipate that fluorescence-guided biopsies may reduce the number of trajectories required to indicate the optimal biopsy site. In addition, the method may minimize the overall time for surgery because no waiting time for the preliminary histopathological diagnosis is necessary. Further studies are required to extend the findings of the current study.

CONCLUSION

A system for direct optical brain tumor detection and warning for possible blood vessels along the trajectory has been evaluated in 20 patients undergoing stereotactic biopsy. When fully deployed in clinical routine, the real-time feedback in the OR is expected to shorten the time for the procedure and increase the precision of the actual biopsy sites. This should improve diagnostic yield and reduce the risk of bleeding complications.

Funding

The study was financially supported by the LiU Cancer Strategic Research Grant, The Swedish Childhood Cancer Foundation (grant no. MT 2013-0043), ALF Grants Region Östergötland (grant no. LIO-599651), and Swedish Foundation for Strategic Research (RMX18-0056).

Disclosures

Drs Richter, Haj-Hosseini, and Wårdell are inventors of a related patent. The other authors have no personal, financial, or institutional interest in any of the drugs, materials, or devices described in this article. Drs Richter and Wårdell have shares in FluoLink AB, Linköping, Sweden.

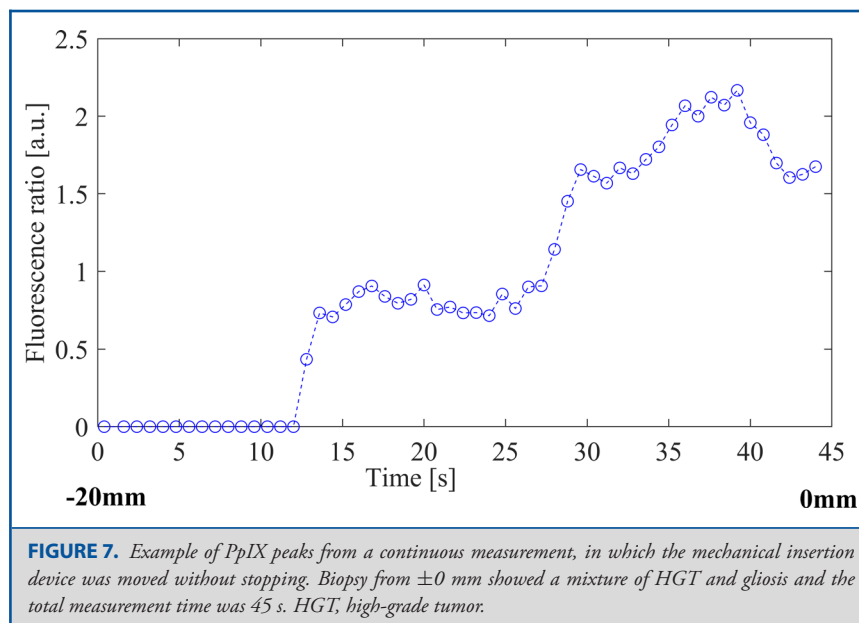


FIGURE 7. Example of PpIX peaks from a continuous measurement, in which the mechanical insertion device was moved without stopping. Biopsy from ± 0 mm showed a mixture of HGT and gliosis and the total measurement time was 45 s. HGT, high-grade tumor.

REFERENCES

1. Sciortino T, Fernandes B, Conti Nibali M, et al. Frameless stereotactic biopsy for precision neurosurgery: diagnostic value, safety, and accuracy. *Acta Neurochir.* 2019;161(5):967-974.
2. Blystad I, Warntjes JBM, Smedby O, Lundberg P, Larsson EM, Tisell A. Quantitative MRI for analysis of peritumoral edema in malignant gliomas. *PLoS One.* 2017;12(5):e0177135.
3. Gempt J, Buchmann N, Ryang YM, et al. Frameless image-guided stereotaxy with real-time visual feedback for brain biopsy. *Acta Neurochir.* 2012;154(9):1663-1667.
4. AEBelo AM, Noer VR, Schulz MK, Kristensen BW, Pedersen CB, Poulsen FR. Frameless stereotactic neuronavigated biopsy: a retrospective study of morbidity, diagnostic yield, and the potential of fluorescence: a single-center clinical investigation. *Clin Neural Neurosurg.* 2019;181:28-32.
5. Kongkham PN, Knifed E, Tamber MS, Bernstein M. Complications in 622 cases of frame-based stereotactic biopsy, a decreasing procedure. *Can J Neurol Sci.* 2008;35(1):79-84.
6. Akshulakov SK, Kerimbayev TT, Biryuchkov MY, Urunbayev YA, Farhadi DS, Byvaltshev VA. Current trends for improving safety of stereotactic brain biopsies: advanced optical methods for vessel avoidance and tumor detection. *Front Oncol.* 2019;9:947.
7. Waters JD, Gonda DD, Reddy H, Kasper EM, Warnke PC, Chen CC. Diagnostic yield of stereotactic needle-biopsies of sub-cubic centimeter intracranial lesions. *Surg Neurol Int.* 2013;4(Suppl 3):S176-S181.
8. Bonnan M. Towards real-time optical brain biopsies? *Clin Neurol Neurosurg.* 2015;134:4-6.
9. Hefli M, von Campe G, Moschopoulos M, Siegner A, Looser H, Landolt H. 5-Aminolevulinic acid induced protoporphyrin IX fluorescence in high-grade glioma surgery: a one-year experience at a single institution. *Swiss Med Wkly.* 2008;138(11-12):180-185.
10. Widhalm G, Minchev G, Woehrer A, et al. Strong 5-aminolevulinic acid-induced fluorescence is a novel intraoperative marker for representative tissue samples in stereotactic brain tumor biopsies. *Neurosurg Rev.* 2012;35(3):381-391; discussion 391.
11. Backlund EO, Pålsson S, Sturnegg P, Eriksson O, Wårdell K, Andersson-Engels S. Exploration of tissue fluorescence in primary brain tumors during stereotactic biopsy—a pilot study. Paper presented at: *European Society for Stereotactic and Functional Neurosurgery; October 9-12, 2002; Toulouse, France.*
12. Richter JCO, Haj-Hosseini N, Hallbeck M, Wårdell K. Combination of hand-held probe and microscopy for fluorescence guided surgery in the brain tumor marginal zone. *Photodiagn Photodyn Ther.* 2017;18:185-192.
13. Haj-Hosseini N, Richter J, Milos P, Hallbeck M, Wårdell K. 5-ALA fluorescence and laser Doppler flowmetry for guidance in a stereotactic brain tumor biopsy. *Biomedical Optics Express.* 2018;9(5):2284-2296.
14. Wårdell K, Zsigmond P, Richter J, Hemm S. Relationship between laser Doppler signals and anatomy during deep brain stimulation electrode implantation toward the ventral intermediate nucleus and subthalamic nucleus. *Neurosurgery.* 2013;72(2 Suppl Operative):ons127-ons140.
15. Picot F, Goyette A, Obaid S, et al. Interstitial imaging with multiple diffusive reflectance spectroscopy projections for in vivo blood vessels detection during brain needle biopsy procedures. *Neurophotonics.* 2019;6(2):025003.
16. Thien A, Rao JP, Ng WH, King NK. The Fluoropen: a simple low-cost device to detect intraoperative fluorescein fluorescence in stereotactic needle biopsy of brain tumors. *Acta Neurochir.* 2017;159(2):371-375.
17. Markwardt NA, Stepp H, Franz G, et al. Remission spectrometry for blood vessel detection during stereotactic biopsy of brain tumors. *J Biophotonics.* 2017;10(8):1080-1094.
18. Ramakonar H, Quirk BC, Kirk RW, et al. Intraoperative detection of blood vessels with an imaging needle during neurosurgery in humans. *Sci Adv.* 2018;4(12):eaav4992.
19. Zsigmond P, Hemm-Ode S, Wårdell K. Optical measurements during deep brain stimulation lead implantation: safety aspects. *Stereotact Funct Neurosurg.* 2017;95(6):392-399.
20. Wårdell K, Blomstedt P, Richter J, et al. Intracerebral microvascular measurements during deep brain stimulation implantation using laser Doppler perfusion monitoring. *Stereotact Funct Neurosurg.* 2007;85(6):279-286.
21. Stummer W, Pichlmeier U, Meinel T, Wiestler OD, Zanella F, Reulen HJ. Fluorescence-guided surgery with 5-aminolevulinic acid for resection of malignant glioma: a randomised controlled multicentre phase III trial. *Lancet Oncol.* 2006;7(5):392-401.
22. Haj-Hosseini N, Richter J, Andersson-Engels S, Wårdell K. Optical touch pointer for fluorescence guided glioblastoma resection using 5-aminolevulinic acid. *Lasers Surg Med.* 2010;42(1):9-14.
23. Louis DN, Perry A, Reifenberger G, et al. The 2016 World Health Organization classification of tumors of the central nervous system: a summary. *Acta Neuropathol.* 2016;131(6):803-820.
24. Kiesel B, Millesi M, Woehrer A, et al. 5-ALA-induced fluorescence as a marker for diagnostic tissue in stereotactic biopsies of intracranial lymphomas: experience in 41 patients. *Neurosurg Focus.* 2018;44(6):E7.
25. Millesi M, Kiesel B, Woehrer A, et al. Is intraoperative pathology needed if 5-aminolevulinic-acid-induced tissue fluorescence is found in stereotactic brain tumor biopsy? *Neurosurgery.* 2020;86(3):366-373.
26. Richter JC, Haj-Hosseini N, Andersson-Engel S, Wårdell K. Fluorescence spectroscopy measurements in ultrasonic navigated resection of malignant brain tumors. *Lasers Surg Med.* 2011;43(1):8-14.
27. Antonsson J, Eriksson O, Lundberg P, Wårdell K. Optical measurements during experimental stereotactic radiofrequency lesioning. *Stereotact Funct Neurosurg.* 2006;84(2-3):118-124.

Acknowledgments

The authors are grateful to the staff at the Department of Neurosurgery and the Department of Pathology at Linköping University Hospital for clinical measurements and tissue preparation.