



Since January 2020 Elsevier has created a COVID-19 resource centre with free information in English and Mandarin on the novel coronavirus COVID-19. The COVID-19 resource centre is hosted on Elsevier Connect, the company's public news and information website.

Elsevier hereby grants permission to make all its COVID-19-related research that is available on the COVID-19 resource centre - including this research content - immediately available in PubMed Central and other publicly funded repositories, such as the WHO COVID database with rights for unrestricted research re-use and analyses in any form or by any means with acknowledgement of the original source. These permissions are granted for free by Elsevier for as long as the COVID-19 resource centre remains active.



Original Articles

COVID-19 with underdiagnosed influenza B and parainfluenza-2 co-infections in Saudi Arabia: Two case reports



Sari T. Alhoufie^{a,*}, Naif H. Alsharif^b, Khalid O. Alfarouk^c, Nadier A. Ibrahim^a, Ali M. Kheyami^d, Alanoud A. Aljifri^d

^a Medical Laboratories Technology Department, College of Applied Medical Sciences, Taibah University, Al-Madinah Al-Munwarah, Saudi Arabia

^b King Salman Medical City, Al-Madinah General Hospital Laboratory Dept, Al-Madinah Al-Munwarah, Saudi Arabia

^c Institute of Endemic Diseases, University of Khartoum, Khartoum, Sudan

^d Al-Madinah Health Cluster, Ministry of Health, Saudi Arabia

ARTICLE INFO

Article history:

Received 7 July 2021

Received in revised form 6 September 2021

Accepted 8 September 2021

Keywords:

COVID-19

Cytokine storm

Co-infection

Virus

ABSTRACT

The emerging of the COVID-19 pandemic is currently challenging for the public health system globally. Beyond SARS-CoV-2 pathogenicity, co-infections with recycling respiratory pathogens, whether bacterial, viral, or fungal, might increase disease symptoms, morbidity, and mortality.

In this study, we reported two COVID-19 cases in the early phase of the virus spread in Saudi Arabia with underdiagnosed respiratory viruses' co-infections, influenza B and Parainfluenza-2, detected retrospectively. Fortunately, both patients recovered and were discharged home.

Underestimation of co-infection among COVID-19 patients might lead to hospital stay prolongation and increases morbidity and mortality. Therefore, it is crucial to consider and screen for co-infecting pathogens among COVID-19 patients and those with risk factors.

© 2021 The Author(s). Published by Elsevier Ltd on behalf of King Saud Bin Abdulaziz University for Health Sciences. This is an open access article under the CC BY-NC-ND license (<http://creativecommons.org/licenses/by-nc-nd/4.0/>).

Introduction

The association of viral respiratory tract infection and the rate of hospitalization, morbidity, and mortality is a significant concern in public health measurements and management. This concern is rising particularly with respiratory co-infection among those patients, which might increase the severity of the illness [1].

Several studies reported respiratory pathogens during the current COVID-19 pandemic, including bacteria, viruses, and fungi, as co-infections among SARS-COV-2 patients [2,3]. Early observation from Yang and his colleagues in China (Wuhan) found some SARS-CoV-2 patients with viral co-infections were in serious condition. Their treatments were more complicated and more prolonged in general [4]. Influenza viruses such as influenza A, B, and Parainfluenza seem to be commonly observed as viral co-infection agents among COVID-19 patients that show the clinical significance and increase the severity of the respiratory infection Acute Respiratory Distress Syndrome (ARDS) [5,6].

The first reported case of COVID-19 infection in Saudi Arabia was on Mar 2, 2021; since then, cases have exceeded 490,464

patients, including 470,328 recovered cases and 7848 deaths as of Jul 3, 2021 [7]. Unfortunately, few studies in Saudi Arabia were conducted to investigate co-infection incidences among COVID-19 patients [8–10].

This work reports two COVID-19 patients with underdiagnosed respiratory co-infecting viruses, which shed light on the importance of considering respiratory viral co-infections among COVID-19 in the current pandemic.

Cases presentation

Two patients were admitted to Al-Madinah General Hospital, King Salman Medical city in Saudi Arabia, in the early phase of the COVID-19 pandemic during May and June 2020. Both patients were COVID-19 positive as their nasopharyngeal swabs were subjected to a reverse-transcription polymerase chain reaction (RT-PCR) at their admission time.

Case 1

A 66-year-old female, diabetic type 2 on insulin, presented to the hospital on Jun 14, 2020, with fever (38 °C), productive cough, chest pain, shortness of breath for six days, and partial pressure Oxygen was 88%. Chest X-ray showed bilateral coarse reticular shadow,

* Corresponding author.

E-mail address: shoufie@taibahu.edu.sa (S.T. Alhoufie).

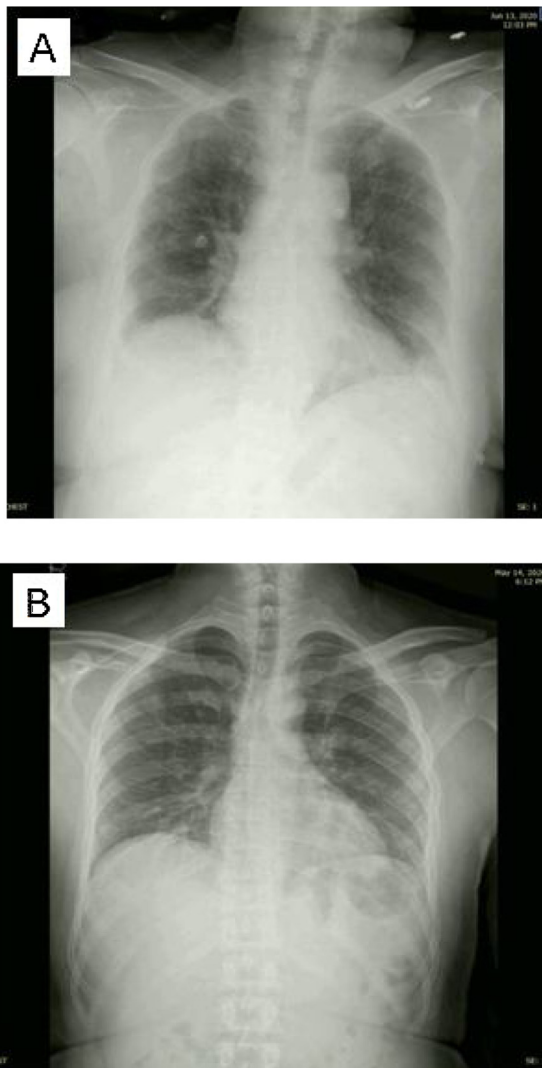


Fig. 1. (A) Case 1, chest X-ray depicting bilateral coarse reticular shadow with no pleural effusion. (B) Case 2, chest x-ray depicting bilateral hilar bronchial wall thickening and no lung opacity.

and no pleural effusion occurred (Fig. 1a). Other laboratory investigations showed positive C-reactive protein (CRP), International Normalized ratio (INR) of 1.04, blood glucose at the time of admission of 201, and Hb1AC was 6.4. Prothrombin time was 13.9s (for other labs Investigations, see Table 1). Treatment included Ceftriaxone 2 gm I.V. every 24 h, Hydroxychloroquine 400 mg tablet oral for one day and then 200 mg orally every 12 h for five days, Methylprednisolone 40 mg/mL for two days, Enoxaparin 40 mg every 12 h, Omeprazole 40 mg iv once per day, Paracetamol 1 gm oral tablet every 8 h, Salbutamol nebulizer 2.5 mg every hour, and of Ipratropium bromide nebulizer 250 mg every 8 h. Fortunately, after 12 days of hospital stays in a non-critical ward, the patient was discharged home.

Case 2

A 44-year-old male patient with no comorbid diseases presented on May 14, 2020, with fever (37.5 °C), productive cough for seven days, shortness of breath, and diarrhea for three days. Chest X-ray showed bilateral hilar bronchial wall thickening and no lung opacity (Fig. 1b), laboratory investigations showed positive C-reactive protein (for other lab investigations, see Table 1). The patient was treated with Amoxicillin/Clavulanic acid 2 gm

Table 1
Shows the clinical chemistry profile of the two patients.

Variables	Influenza B Patient 1	Parainfluenza-2 Patient 2	Referenced Value
Age	66	40	
SARS-CoV-2	Positive	Positive	
C-Reactive protein	Positive	Positive	
INR	1.04	0.83	
Aspartate aminotransferase (AST), serum	20	72	0–31 U/L H
Chloride, serum	102	103	98–106 mmol/L
Glucose, serum	6.4	5.7	LEES THAN 6
Creatinine, serum	89.61	89.83	53–97.2 umol/L
Calcium, serum	2.03	2.22	2.2–2.7 mmol/L
Direct bilirubin, serum	3.23	2.06	3.4–12 umol/L
Blood urea nitrogen	4.8	3.4	2.5–7.1 umol/L
Prothrombin time, plasma	13.9	11.7	11–12.5 s

I.V. every hour for ten days, Azithromycin 500 mg for six days, Hydroxychloroquine, Paracetamol 1 gm, and Omeprazole 40 mg once daily. He was admitted to the isolation ward in the hospital and stayed 24 h, then transferred to the hotel quarantine till his PCR test became negative, which was repeated ten days after infection diagnosis.

Methodology

RT-PCR for SARS-CoV-2 detection

A nasopharyngeal swab from patients was sent to the Regional Lab, Health Affairs in Madinah and subjected to the cobas® 6800 SARS-CoV-2 RT-PCR test (Roche, Pleasanton CA, USA) using the fully automated cobas® 6800 (Roche Molecular Systems, Rotkeruz, Switzerland)). Target-specific primers were used to amplify the structural protein envelope E-gene and open reading frame (ORF) 1a of SARS-CoV-2.

Sero detection for influenza B and parainfluenza 2

Preserved Serum samples of the two patients were used to detect the IgM antibodies for influenza B and parainfluenza 2 in an indirect ELISA using Vircell IgM ELISA kits G/M1008 and G/M1010 respectively, (Vircell, Granada, Spain), according to the manufacturer's instructions. All the patients' data were extracted from the patient's medical records. The Institutional Review Board approves this study of the General Directorate of Health Affairs in Madinah with the number (IRB 9-2021).

Discussion

In this work, two patients infected with the COVID-19 virus in the early phase of the pandemic in Saudi Arabia (May and June 2020) showed retrospectively positive results for influenza B virus antibody IgM (case1) and Parainfluenza-2 antibody IgM (case2), indicating co-infections existence. Fortunately, the co-infection incidences did not lead to ARDS development or other complications, and patients were discharged home after 12 and 2 days of admission, respectively. On the other hand, the prolonged hospital stay is seen in case 1, which is attributed to the co-infection with influenza B and the patient co-morbidity (diabetes) and age (66 years).

The administered medications thoroughly covered most of the morbidity-related factors include:

- Many evidence suggested that thromboembolism becomes a recent cardinal of COVID-19 that worsens the disease prognosis and is associated with COVID-19-related-mortality [11]. Therefore, administration of Enoxaparin would represent a rational approach in reducing the disease related-mortality [12,13].
- Cytokine storm, hyper-inflammation, lies within the core of COVID-19 and induced many factors that increase disease-related mortality [14]. Therefore, pharmacological agents that suppress this cytokine storm will eventually decrease the disease-related mortality, e.g., Acute Respiratory Distress Syndrome (ARDS) [15]. Methylprednisolone fitted to antagonize the cytokine storm, and so early administration of methylprednisolone will reduce the COVID-19-related mortality [16,17].
- Although hydroxychloroquine is approved as an antiprotozoal drug, yet recently, it has been widely used off-label (re-purposing) in the management of rheumatoid arthritis and systemic lupus erythematosus due to its ability to stabilize the lysosomal membrane [18,19]; thus, it prevents and/or decrease the releases of cathepsin enzymes, and so reduces the cytokine storm.
- Azithromycin is an example of macrolides antibiotics widely used to treat bacterial infections, especially atypical bacteria (bacteria that lack cell walls), as macrolides inhibit protein synthesis. However, how does azithromycin affect the COVID-19 where its causation was viral and not a bacterial disease, which is a conundrum? One of the suggested explanations is that macrolides have anti-inflammatory properties, reducing hyper-inflammation [20]. Moreover, developing viral infection mostly leads to developing secondary acute bacterial infection (SABI) [21]. Therefore, additional administration of ceftriaxone to cover the possible typical bacterial infection [22].

Co-infections that occurred in these two cases were not diagnosed during the care time in the hospital. Similar situations of misdiagnosing respiratory infecting pathogens during early (H1N1) pdm09 virus pandemic in Australia 2009 was reported [23]. However, few studies have reported viral co-infection during respiratory infection endemics such as MERS-COV and the current COVID-19 pandemic [2,23,24]. This limitation in reporting is attributed to the underestimation of co-infection agents during the emergence of a novel pathogen of endemic or pandemic potential. Additionally, similar clinical manifestations, transmission route, and season time for COVID-19 and other circulating respiratory pathogens might encourage clinicians to exclude the possibility of co-infection existence [23,25,26].

An experimental study on cells culture and mice in China showed that the influenza virus facilitates SARS-CoV-2 infectivity via increasing the expression level of ACE2, which is the main target for the COVID19 virus to infect host cells [27]. Indeed, co-infection can seriously damage the immune system and accelerate the severity of the illness [4,28,29]. A study in Spain reported influenza A and B as co-infecting agents among SARS-COV-2 patients under mechanical ventilation [30]. A recent study in Saudi Arabia by Bander and colleagues found a positive correlation between co-infecting influenza H1N1 virus and mortality, particularly for ICU patients. Their study also detected several respiratory viruses among non-critical COVID-19 patients, such as influenza B, Parainfluenza-3, Adenovirus, and Metapneumovirus diagnosed via respiratory panel multiplex PCR [9].

Limitations of the current study

As the study is retrospective, some limitations are included. Besides the serological results, there were no available respiratory samples to conduct further confirmatory molecular diagnosis (PCR) for influenza B and Para-influenza viruses' infection. Furthermore, the patient's medical records did not notify if patients had

previously received influenza vaccinations, which might minimize the severity of the current influenza co-infections. In addition, no follow-up been mentioned in patient's records since they have been discharged. However, the study highlighted the importance of considering possible underdiagnosed co-infections among COVID-19 patients and their challenging diagnosis in the clinical, radiographic, and laboratory investigations.

Concluding remarks and recommendations

This report showed two COVID-19 patients with underdiagnosed co-infection respiratory pathogens, influenza B and Parainfluenza-2. Thus, screening for possible co-pathogens among COVID-19 patients, particularly respiratory virus, is essential to handle their effect that might lead to ARDS and other complications during the current COVID-19 pandemic.

Implementation of a wide range of diagnostic tests such as respiratory panel multiplex PCR and simple antibodies detection techniques (ELISA, latex, etc.) for these co-pathogens in hospital and regional labs would minimize the possibility of misdiagnosing the incidences of COVID-19 co-infections. A further prospective cohort study to investigate the prevalence of influenza viruses among COVID-19 patients is in progress.

Funding

This research did not receive any specific grant from funding agencies in the public, commercial, or not-for-profit sectors.

Conflict of interest

The authors declare that they have no known competing financial interests that could have influenced the work reported in this paper.

Ethical approval

Not required.

Acknowledgment

We thank Mr. Khaled Aljabri, and Mr. Adnan Khoumaeys for their help. Our thanks also extended to the Academic Affairs in King Salman Medical City in Madinah for their support.

References

- [1] Denny FW. The clinical impact of human respiratory virus infections. *Am J Respir Crit Care Med* 1995;152:S4–12, <http://dx.doi.org/10.1164/ajrccm/152.4.Pt.2.S4>.
- [2] Zhu X, Ge Y, Wu T, Zhao K, Chen Y, Wu B, et al. Co-infection with respiratory pathogens among COVID-2019 cases. *Virus Res* 2020;285, <http://dx.doi.org/10.1016/j.virusres.2020.198005>.
- [3] Wang M, Wu Q, Xu W, Qiao B, Wang J, Zheng H, et al. Clinical diagnosis of 8274 samples with 2019-novel coronavirus in Wuhan; 2020, <http://dx.doi.org/10.1101/2020.02.12.20022327>.
- [4] Yang X, Yu Y, Xu J, Shu H, Xia J, Liu H, et al. Clinical course and outcomes of critically ill patients with SARS-CoV-2 pneumonia in Wuhan, China: a single-centered, retrospective, observational study. *Lancet Respir Med* 2020;8:475–81, [http://dx.doi.org/10.1016/S2213-2600\(20\)30079-5](http://dx.doi.org/10.1016/S2213-2600(20)30079-5).
- [5] Yue H, Zhang M, Xing L, Wang K, Rao X, Liu H, et al. The epidemiology and clinical characteristics of co-infection of SARS-CoV-2 and influenza viruses in patients during COVID-19 outbreak. *J Med Virol* 2020;92:2870–3, <http://dx.doi.org/10.1002/jmv.26163>.
- [6] Tang X, Du RH, Wang R, Cao TZ, Guan LL, Yang CQ, et al. Comparison of hospitalized patients with ARDS caused by COVID-19 and H1N1. *Chest* 2020;158:195–205, <http://dx.doi.org/10.1016/j.chest.2020.03.032>.
- [7] Saudi Arabia COVID: 490,464 Cases and 7,848 Deaths – Worldometer Available online: <https://www.worldometers.info/coronavirus/country/saudi-arabia/> [Accessed 3 July 2021].

- [8] Faqih F, Alharthy A, Noor AF, Balshi A, Balhamar A, Karakitsos D. COVID-19 in a patient with active tuberculosis: a rare case-report. *Respir Med Case Rep* 2020;31:101146, <http://dx.doi.org/10.1016/j.rmcr.2020.101146>.
- [9] Alosaimi B, Naeem A, Hamed ME, Alkadi HS, Alanazi T, Al Rehily SS, et al. Influenza co-infection associated with severity and mortality in COVID-19 patients, 18; 2021.
- [10] Elhazmi A, Al-Tawfiq JA, Sallam H, Al-Omari A, Alhumaid S, Mady A, et al. Severe acute respiratory syndrome coronavirus 2 (SARS-CoV-2) and Middle East Respiratory Syndrome Coronavirus (MERS-CoV) coinfection: a unique case series. *Travel Med Infect Dis* 2021;41:102026, <http://dx.doi.org/10.1016/j.tmaid.2021.102026>.
- [11] Vaughn VM, Yost M, Abshire C, Flanders SA, Paje D, Grant P, et al. Trends in venous thromboembolism anticoagulation in patients hospitalized with COVID-19. *JAMA Netw Open* 2021;4:e2111788, <http://dx.doi.org/10.1001/jamanetworkopen.2021.11788>.
- [12] Drago F, Gozzo L, Li L, Stella A, Cosmi B. Use of enoxaparin to counteract COVID-19 infection and reduce thromboembolic venous complications: a review of the current evidence. *Front Pharmacol* 2020;11, <http://dx.doi.org/10.3389/fphar.2020.579886>.
- [13] Billett HH, Reyes M, Szymanski J, Ikemura K, Stahl LR, Lo Y, et al. Anticoagulation in COVID-19: effect of enoxaparin, heparin, and apixaban on mortality. *Thromb Haemost* 2020;120:1691–9, <http://dx.doi.org/10.1055/S-0040-1720978>.
- [14] Alfarouk KO, AlHoufie STS, Ahmed SBM, Shabana M, Ahmed A, Alqahtani SS, et al. Pathogenesis and management of COVID-19. *J Xenobiot* 2021;11:77–93, <http://dx.doi.org/10.3390/jox11020006>.
- [15] Kolilekas L, Loverdos K, Giannakaki S, Vlasi L, Levounets A, Zervas E, et al. Can steroids reverse the severe COVID-19 induced “cytokine storm”? *J Med Virol* 2020;92:2866–9, <http://dx.doi.org/10.1002/jmv.26165>.
- [16] Pinzón MA, Ortiz S, Holguín H, Betancur JF, Cardona Arango D, Laniado H, et al. Dexamethasone vs methylprednisolone high dose for Covid-19 pneumonia. *PLoS One* 2021;16:e0252057, <http://dx.doi.org/10.1371/journal.pone.0252057>.
- [17] Sauñe PM, Bryce-Alberti M, Portmann-Baracco AS, Accinelli RA. Methylprednisolone pulse therapy: an alternative management of severe COVID-19. *Respir Med Case Rep* 2020;31:101221, <http://dx.doi.org/10.1016/j.rmcr.2020.101221>.
- [18] Ornstein MH, Sperber K. The antiinflammatory and antiviral effects of hydroxychloroquine in two patients with acquired immunodeficiency syndrome and active inflammatory arthritis. *Arthritis Rheum* 1996;39:157–61, <http://dx.doi.org/10.1002/art.1780390122>.
- [19] Gies V, Bekaddour N, Dieudonné Y, Guffroy A, Frenger Q, Gros F, et al. Beyond anti-viral effects of chloroquine/hydroxychloroquine. *Front Immunol* 2020;11:1409, <http://dx.doi.org/10.3389/fimmu.2020.01409>.
- [20] Banjanac M, Munić Kos V, Nujić K, Vrančić M, Belamarić D, Crnković S, et al. Anti-inflammatory mechanism of action of azithromycin in LPS-stimulated J774A.1 cells. *Pharmacol Res* 2012;66:357–62, <http://dx.doi.org/10.1016/j.phrs.2012.06.011>.
- [21] Manohar P, Loh B, Athira S, Nachimuthu R, Hua X, Welburn SC, et al. Secondary bacterial infections during pulmonary viral disease: phage therapeutics as alternatives to antibiotics? *Front Microbiol* 2020;11:1434, <http://dx.doi.org/10.3389/fmicb.2020.01434>.
- [22] Ruga E, Giaquinto C, Cozzani S, Giacomelli A, Pagliaro A, Mazza A, et al. The use of antibiotics in the treatment and prevention of infection in HIV-infected children. *Acta Paediatr Suppl* 1994;400:70–2, <http://dx.doi.org/10.1111/j.1651-2227.1994.tb13339.x>.
- [23] Ratnamohan VM, Taylor J, Zeng F, McPhie K, Blyth CC, Adamson S, et al. Pandemic clinical case definitions are non-specific: multiple respiratory viruses circulating in the early phases of the 2009 influenza pandemic in New South Wales, Australia. *Virol J* 2014;11:113, <http://dx.doi.org/10.1186/1743-422X-11-113>.
- [24] Alfaraj SH, Al-Tawfiq JA, Alzahrani NA, Altwaijri TA, Memish ZA. The impact of co-infection of influenza A virus on the severity of Middle East Respiratory Syndrome Coronavirus. *J Infect* 2017;74:521–3, <http://dx.doi.org/10.1016/j.jinf.2017.02.001>.
- [25] Azekawa S, Namkoong H, Mitamura K, Kawaoka Y, Saito F. Co-infection with SARS-CoV-2 and influenza A virus. *IDCases* 2020;20:e00775, <http://dx.doi.org/10.1016/j.idcr.2020.e00775>.
- [26] Lai C-C, Wang C-Y, Hsueh P-R. Co-infections among patients with COVID-19: the need for combination therapy with non-anti-SARS-CoV-2 agents? *J Microbiol Immunol Infect* 2020;53:505–12, <http://dx.doi.org/10.1016/j.jmii.2020.05.013>.
- [27] Bai L, Zhao Y, Dong J, Liang S, Guo M, Liu X, et al. Coinfection with influenza A virus enhances SARS-CoV-2 infectivity. *Cell Res* 2021;31:395–403, <http://dx.doi.org/10.1038/s41422-021-00473-1>.
- [28] Tay MZ, Poh CM, Rénia L, MacAry PA, Ng LFP. The trinity of COVID-19: immunity, inflammation and intervention. *Nat Rev Immunol* 2020;20:363–74, <http://dx.doi.org/10.1038/s41577-020-0311-8>.
- [29] Denney L, Ho L-P. The role of respiratory epithelium in host defence against influenza virus infection. *Biomed J* 2018;41:218–33, <http://dx.doi.org/10.1016/j.bj.2018.08.004>.
- [30] Cuadrado-Payán E, Montagud-Marrahi E, Torres-Elorza M, Bodro M, Blasco M, Poch E, et al. SARS-CoV-2 and influenza virus co-infection. *Lancet (London, England)* 2020;395:e84, [http://dx.doi.org/10.1016/S0140-6736\(20\)31052-7](http://dx.doi.org/10.1016/S0140-6736(20)31052-7).