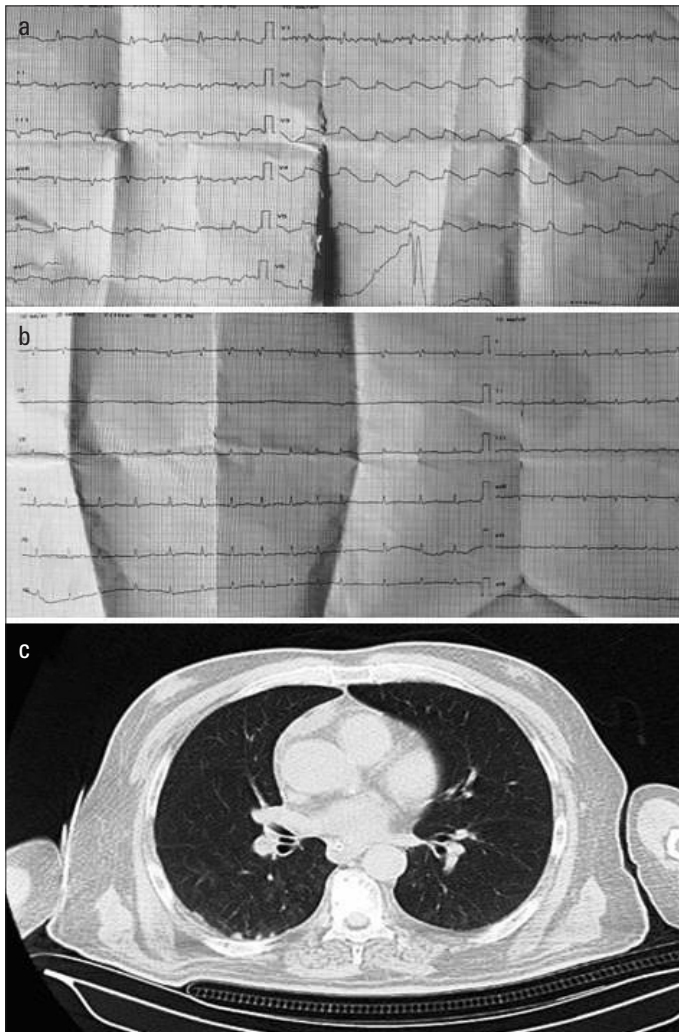
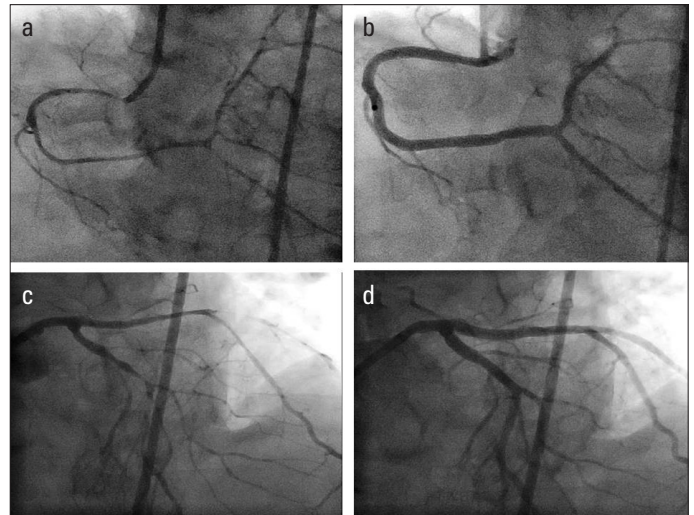


## Spontaneous, severe, and diffuse coronary vasospasm in a patient with COVID-19 🎬

Although respiratory system injury is the dominant feature of acute severe coronavirus disease 2019 (COVID-19), the occurrence of cardiovascular complications has generated considerable concern. During COVID-19, proinflammatory mediators trigger a state called “cytokine storm” that is especially seen in advanced stages and lead to a life-threatening acute systemic inflammatory syndrome characterized by multiple organ dysfunction. The intense inflammatory process may cause coronary vasospasm (CVS). Here, we present a 61-year-old patient with



**Figure 1.** (a) Twelve-lead electrocardiography during the chest pain episode showing elevation of D1-aVL, V2-V6 with specular descent in D2-D3, aVF leads. (b) After intravenous nitroglycerin administration, the patient’s chest pain resolved, and ECG changes reverted to normal. (c) Initial thoracic computed tomography depicting ground-glass opacities and infiltration



**Figure 2.** (a) Right coronary angiogram showing significant, diffuse coronary artery spasm causing subtotal stenosis. (b) Right coronary artery flow revealing normal artery caliber after intracoronary 100 µg nitroglycerin administration. (c) Left coronary angiography revealing nearly occlusive, diffuse coronary vasospasm (CVS) and coronary slow flow, which were thought to be the causes of the inflammatory process of coronavirus disease 2019. (d) CVS completely resolved after nitroglycerin administration

anterior ST-elevation myocardial infarction (Fig. 1a and 1b) because of severe, diffuse, spontaneous CVS (Fig. 2a and 2c, Video 1). It includes almost all the side branches in COVID-19 with the patient being diagnosed with COVID-19 pneumonia owing to typical findings on thoracic computed tomography (Fig. 1c) and highly suspicious clinical and laboratory results.

CVS was revealed to be completely normal without occlusive coronary artery disease after administration of nitroglycerin (Fig. 2b and 2d, Video 2). Notably, acute coronary syndrome was excluded, and the patient was transferred back to the emergency service. Despite intense medical therapy, severe hypoxemia was sustained and clinical findings got worse, and the patient died during emergency service follow-up.

The context of a hyper-inflammatory response during COVID-19 may be a cause of coronary spasm should be considered in patients with COVID-19, especially in severe cases, and nitroglycerin therapy should be considered during clinical evaluation or angiogram lab in the intervention of patients with COVID-19.

**Informed consent:** The informed consent was not obtained. The patient was in acute coronary syndrome and was taken to coronary angiography procedure as an emergency. The patient died shortly after the procedure (coronary angiography).

**Video 1.** Coronary angiogram video demonstrating widespread, nearly occlusive multi-segment coronary vasospasm

**Video 2.** Improvement of the coronary vasospasm with recovery of the normal arterial caliber after intracoronary administration of nitroglycerin

**Mutlu Çağın Sümerkan** , **Arzu Er Kara** , **Güneş Melike Doğan** ,  
**Ömer Alyan** 

**Department of Cardiology, University of Health Sciences, Şişli  
Hamidiye Etfal Training and Research Hospital; İstanbul-Turkey**

**Address for Correspondence:** Dr. Mutlu Çağın Sümerkan,  
Sağlık Bilimleri Üniversitesi, Şişli Hamidiye Etfal Eğitim ve Araştırma Hastanesi,  
Kardiyoloji Kliniği, İstanbul-Türkiye

Phone: +90 212 373 50 00

E-mail: mutlusumerkan@gmail.com

©Copyright 2021 by Turkish Society of Cardiology -

Available online at

[www.anatoljcardiol.com](http://www.anatoljcardiol.com)

DOI:10.5152/AnatolJCardiol.2021.167

