

bimonthly *BCR-ABL1* IS tests indicated a persistent MMR. Continuous monitoring of *BCR-ABL1* was not able to detect the development of the extramedullary blast crisis in our patient. This case demonstrates the need to be mindful of the possibility of extramedullary disease even in patients having achieved MMR following TKI therapy.

The patient has provided informed consent for publication of this case.

Acknowledgements

This case report was funded by a Fujii Investigator Award to HT.

Author contributions

RN and TM wrote the draft and provided patient care. SS, TY, KM and NA contributed to patient care. YO made the pathological diagnosis. NA, JO, NS, and HT revised the manuscript. All the authors reviewed the manuscript and provided final approval.

Conflicts of interest

The authors have no conflicts of interest to disclose.

Rui Nakajima¹

Takuji Matsuo²

Ritsu Sumiyoshi²

Sumiko Saito²

Tadashi Yamamoto²


Kensuke Matsumoto²

Nobu Akiyama²

Jun Ooi² 

Yasunori Ota³

Naoki Shirafuji²

Haruko Tashiro² 

¹Department of Internal Medicine, Teikyo University School of Medicine, ²Department of Hematology/Oncology, Teikyo University School of Medicine and ³Department of Pathology, Research Hospital, The Institute of Medical Science, The University of Tokyo, Tokyo, Japan.

E-mail: haruko-t@med.teikyo-u.ac.jp

Keywords: CML, tyrosine kinase inhibitor, extramedullary, bosutinib, ponatinib

First published online 10 August 2021

doi: 10.1111/bjh.17771

Supporting Information

Additional supporting information may be found online in the Supporting Information section at the end of the article.

Fig S1. Clinical course of the patient. Level of the *BCR-ABL1* transcript on the International Scale (IS) had not been tested before December 2015.

References

- Hochhaus A, Baccarani M, Silver RT, Schiffer C, Apperley JF, Cervantes F, et al. European LeukemiaNet 2020 recommendations for treating chronic myeloid leukemia. *Leukemia*. 2020;**34**(4):966–84.
- Jabbour E, Kantarjian H, O'Brien S, Rios MB, Abruzzo L, Verstovsek S, et al. Sudden blastic transformation in patients with chronic myeloid leukemia treated with imatinib mesylate. *Blood*. 2006;**107**(2):480–2.
- Okada Y, Sato K, Kobayashi S, Nagao S, Takano K, Teramoto M, et al. Sudden blast phase in chronic myeloid leukemia developed during nilotinib therapy after major molecular response was achieved. *Int J Hematol*. 2018;**107**(4):495–7.
- Kim AS, Goldstein SC, Luger S, Van Deerlin VM, Bagg A. Sudden extramedullary T-lymphoblastic blast crisis in chronic myelogenous leukemia: a nonrandom event associated with imatinib? *Am J Clin Pathol*. 2008;**129**(4):639–48.
- Wang H-Y, Tzachanis D. Extramedullary early T-cell precursor acute lymphoblastic lymphoma presenting as blast crisis of CML. *Blood*. 2020;**136**(9):1112.
- Matsuda M, Morita Y, Shimada T, Miyatake J, Hirase C, Tanaka M, et al. Extramedullary blast crisis derived from 2 different clones in the central nervous system and neck during complete cytogenetic remission of chronic myelogenous leukemia treated with imatinib mesylate. *Int J Hematol*. 2005;**81**(4):307–9.
- Shune L, Cayci Z, Rogosheske J, Brunstein C, Ustun C. Extramedullary blastic crisis in abdominal lymph nodes in a patient with chronic myelogenous leukemia on imatinib. *Leuk Res*. 2012;**36**(6):e131–e132.
- Angelopoulou MK, Asimakopoulos JV, Galani Z, Levidou G, Roumelioti M, Vassilakopoulos TP, et al. Extramedullary sudden blast crisis in chronic-phase chronic myeloid leukemia during first-line treatment with nilotinib. *Blood*. 2016;**6**(8):e461.
- Simpson E, O'Brien SG, Reilly JT. Extramedullary blast crises in CML patients in complete hematological remission treated with imatinib mesylate. *Clin Lab Haematol*. 2006;**28**(3):215–6.

Thrombotic thrombocytopenic purpura temporally associated with BNT162b2 vaccination in an adolescent successfully treated with caplacizumab

Thrombotic thrombocytopenic purpura (TTP) is caused by a severe deficiency of plasma protease ADAMTS13 (a disintegrin and metalloproteinase with a thrombospondin type 1

motif, member 13), which is responsible for cleavage of von Willebrand factor (vWF). Immune TTP (iTTP), which accounts for approximately two-thirds of childhood TTP,

occurs secondary to inhibitory autoantibodies against ADAMTS13. These autoantibodies prevent cleavage of vWF resulting in ultralarge multimers of vWF and, in turn, microangiopathic haemolytic anaemia, thrombocytopenia, and organ dysfunction.¹

A 14-year-old female presented to a community hospital with a two-day history of fatigue, headache, confusion, and bruising. She had a long-standing history of anxiety, iron deficiency, and postprandial abdominal pain. She received the first dose of the BNT162b2 vaccine two weeks prior to presentation. Her neurological examination and head computed tomography (CT) were both normal. Her laboratory investigations showed a haemolytic anaemia with a haemoglobin of 63 g/l, platelets $<10 \times 10^{12}/l$, bilirubin 68 $\mu\text{mol}/l$, lactate dehydrogenase (LDH) 626 μ/l , haptoglobin <0.10 g/l, and the occasional red cell fragment noted on blood film. She had a PLASMIC score of 6 and was transferred to our tertiary-care paediatric centre with a suspicion of TTP.

The diagnosis of iTTP was confirmed with urgent ADAMTS13 activity testing showing a level of $<1\%$ and ADAMTS13 IgG of 72 μml . She was started on oral prednisone 2 mg/kg and daily therapeutic plasma exchange (TPE) to replace 1.5 \times her plasma volume using cryosupernatant plasma as the exchange solution. Her platelet count rapidly improved and after two consecutive days of a count greater than $150 \times 10^{12}/l$, TPE was held (Day 5). Rituximab was administered to reduce the risk of long-term relapse. Within 48 h she had an exacerbation as her platelet count dropped precipitously to $28 \times 10^{12}/l$ which resulted in restarting TPE. Twice daily TPE and a pulse of methylprednisolone was started on Day 9 as her platelet count was $15 \times 10^{12}/l$. As a result of her early exacerbation, caplacizumab, a novel anti-vWF nanobody was obtained via the Sanofi compassionate access programme.² Her platelet count increased to $177 \times 10^{12}/l$ within 48 h of starting caplacizumab and

remained in the normal range (Fig 1). TPE was stopped on Day 12 at which point her ADAMTS13 activity was 19% and antibody level had fallen to 7 μml . Steroids were weaned and caplacizumab continued for 30 days post TPE. She did not experience any bleeding during her therapy.

Throughout the course of her treatment, she appeared remarkably well, with no evidence of end-organ damage. She had a normal blood pressure, serum creatinine, and no haematuria nor albuminuria throughout her course. Ophthalmologic examination, head magnetic resonance imaging (MRI), and abdominal ultrasound were normal. There were no clinical features to support underlying autoimmune disease. Her anti-nuclear and double-stranded DNA antibodies were negative. Human immunodeficiency virus (HIV), Epstein-Barr virus (EBV), and cytomegalovirus (CMV) testing were negative. Her SARS-CoV-2 polymerase chain reaction (PCR) and anti-SARS-CoV-2 total assay (nucleocapsid) pre-TPE were both negative. IgA and IgG assays (Spike; S1) were tested following initiation of TPE and were borderline.

Immune thrombotic thrombocytopenic purpura is rare in childhood with an annual incidence of less than one in a million.³ In the Oklahoma TTP registry, only two of 90 patients registered in 23 years were children under 18 years of age.⁴ In adults, autoimmune disorders, pregnancy, drugs, HIV, malignancy, and organ transplantation have also been linked as possible triggers for TTP.¹ Childhood-onset iTTP has a similarly increased association with autoimmune disorders, though most cases are idiopathic.⁴ Vaccine-associated iTTP has been previously noted with the pneumococcal, rabies, and influenza vaccines.^{5,6} De Bruijn *et al.* first reported an adult patient who presented with a new diagnosis of iTTP following the first dose of the BNT162b2 vaccine.⁷ Recently, an Israeli study reported a cluster of four adult cases of iTTP (two new and two relapses) within four weeks of the BNT162b2 vaccine, a rate higher than that

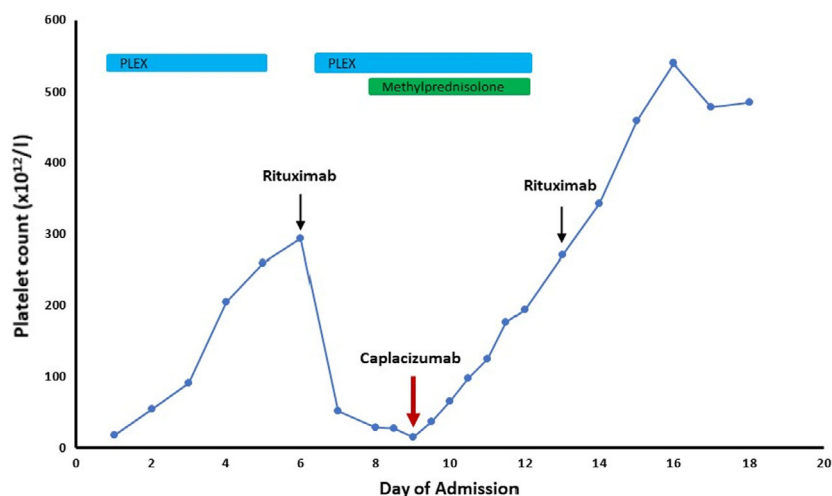


Fig 1. Platelet count over the course of therapy. Oral prednisone and daily therapeutic plasma exchange (TPE) were started upon admission. The patient had an exacerbation within 24 h of holding TPE to administer rituximab. She received a pulse of methylprednisolone and caplacizumab was administered on Day 9.

usually seen.⁸ Three of these cases were after the second dose and one after the first dose of the BNT162b2 vaccine.

Our patient's presentation within two weeks of vaccination together with the lack of other possible causes are suspicious for the BNT162b2 vaccine playing a role, though we cannot assign causality. The presence of antibodies to the spike protein would have potentially supported this hypothesis. However, her presentation soon after the first vaccine dose and analysis being performed after initiation of TPE may have influenced the borderline assay in our patient. There is a family history of maternal immune thrombocytopenia (ITP) and thus it is possible the vaccine may have been the trigger to unmask an underlying vulnerability to autoimmunity.

There are no consensus guidelines for the management of paediatric TTP, with TPE, corticosteroids and rituximab serving as initial therapy options. This is in keeping with adult literature. The use of vincristine, cyclophosphamide, bortezomib, and splenectomy have been reported in refractory cases.⁹

Caplacizumab is a nanobody which recognizes the vWF A1 domain and inhibits platelet binding to vWF. Two pivotal randomized controlled trials in adults demonstrated the use of caplacizumab was associated with a more rapid platelet response, and reduced risk of recurrence or a refractory course.^{2,10} Consequently, the International Society on Thrombosis and Haemostasis (ISTH) guideline for the treatment of TTP suggests the use of caplacizumab in initially treating iTTP.¹¹ As a result of inhibiting vWF function, mucocutaneous bleeding is the most common side-effect. The successful use of caplacizumab in paediatric iTTP has been reported in front-line therapy or for refractory disease.^{12–15} Our patient had an early exacerbation upon stopping TPE which responded very well to caplacizumab, with a rapid platelet response, discontinuation of TPE, and no bleeding.

We report the first paediatric case of *de novo* iTTP possibly associated with the BNT162b2 vaccine and highlight the need to consider TTP in thrombocytopenic children post vaccination. We strongly support the drive to vaccinate children and adults against COVID-19 as the established benefits of the BNT162b2 vaccine in reducing COVID-19 related morbidity and mortality far outweigh the risks of extremely rare side effects such as iTTP. To our knowledge, this is also the first paediatric patient treated with caplacizumab in Canada. Our results support the early consideration of the use of caplacizumab in children with iTTP.

Author contributions

AK and JG collected and analyzed the data and revised the manuscript. KA, SP, APS, SLG, MB, CC, SL, LB, S-HSH and MJK analyzed the data and revised the manuscript. ST collected and analyzed the data, drafted the initial manuscript and revised the manuscript. All authors approve of the final manuscript as submitted.

Conflicts of interest statement

The authors have no conflicts of interest to disclose.

Patient consent statement

The patient provided written consent to publish this case report.

Acknowledgements

We would like to acknowledge the apheresis team and the haemostasis and thrombosis laboratory at London Health Sciences Centre for their support in caring for the patient.

Amrit Kirpalani^{1,2}

Justin Garabon¹

Kiersten Amos¹

Serina Patel^{1,2}

Ajay P Sharma^{1,2}

Saptharishi Lalgudi Ganesan^{1,2}

Michelle Barton^{1,2}


Chantel Cacciotti^{1,2}

Sarah Leppington³

Linda Bakovic^{4,5}

Shih-Han Susan Huang^{2,6}

Michael J Knauer⁷

Soumitra Tole^{1,2} 

¹Department of Pediatrics, Schulich School of Medicine & Dentistry, Western University, ²Department of Pediatrics, London Health Sciences Centre, ³Children's Hospital, London Health Sciences Centre, London, ⁴Department of Pediatrics, Northern Ontario School of Medicine, ⁵Department of Pediatrics, Thunder Bay Regional Health Sciences Centre, Thunder Bay, ⁶Department of Medicine, Schulich School of Medicine & Dentistry, Western University and ⁷Department of Pathology and Laboratory Medicine, Schulich School of Medicine & Dentistry, University of Western Ontario, London, ON, Canada.

E-mail: soumitra.tole@lhsc.on.ca

Keywords: TTP, caplacizumab, vaccine, adolescent, COVID-19

First published online 17 August 2021

doi: 10.1111/bjh.17782

References

1. Joly BS, Coppo P, Veyradier A. Thrombotic thrombocytopenic purpura. *Blood*. 2017;**129**(21):2836–46.
2. Scully M, Cataland SR, Peyvandi F, Coppo P, Knobl P, Kremer Hovinga JA, et al. Caplacizumab treatment for acquired thrombotic thrombocytopenic purpura. *N Engl J Med*. 2019;**380**(4):335–46.
3. Joly BS, Coppo P, Veyradier A. Pediatric thrombotic thrombocytopenic purpura. *Eur J Haematol*. 2018;**101**(4):425–34.
4. Siddiqui A, Journeycake JM, Borogovac A, George JN. Recognizing and managing hereditary and acquired thrombotic thrombocytopenic purpura in infants and children. *Pediatr Blood Cancer*. 2021;**68**(5):e28949.

Correspondence

5. Dias PJ, Gopal S. Refractory thrombotic thrombocytopenic purpura following influenza vaccination. *Anaesthesia*. 2009;**64**(4):444–6.
6. Kojima Y, Ohashi H, Nakamura T, Nakamura H, Yamamoto H, Miyata Y, et al. Acute thrombotic thrombocytopenic purpura after pneumococcal vaccination. *Blood Coagul Fibrinolysis*. 2014;**25**(5):512–4.
7. de Bruijn S, Maes MB, De Waele L, Vanhoorelbeke K, Gadisseur A. First report of a de novo iTTP episode associated with an mRNA-based anti-COVID-19 vaccination. *J Thromb Haemost*. 2021;**19**(8):2014–18.
8. Maayan H, Kirgner I, Gutwein O, Herzog-Tzarfati K, Rahimi-Levene N, Koren-Michowitz M, et al. Acquired thrombotic thrombocytopenic purpura: A rare disease associated with BNT162b2 vaccine. *J Thromb Haemost*. 2021.1–4. <https://doi.org/10.1111/jth.15420>
9. Sayani FA, Abrams CS. How I treat refractory thrombotic thrombocytopenic purpura. *Blood*. 2015;**125**(25):3860–7.
10. Peyvandi F, Scully M, Kremer Hovinga JA, Cataland S, Knobl P, Wu H, et al. Caplacizumab for acquired thrombotic thrombocytopenic purpura. *N Engl J Med*. 2016;**374**(6):511–22.
11. Zheng XL, Vesely SK, Cataland SR, Coppo P, Geldziler B, Iorio A, et al. ISTH guidelines for treatment of thrombotic thrombocytopenic purpura. *J Thromb Haemost*. 2020;**18**(10):2496–502.
12. Bhoopalan SV, Hankins J, George J, Ryder A, Onder AM, Puri L. Use of caplacizumab in a child with refractory thrombotic thrombocytopenic purpura. *Pediatr Blood Cancer*. 2019;**66**(7):e27737.
13. Boudali J, Hallak B, Haeck M, Sellier-Leclerc AL, Ulrich M, Coppo P, et al. Immune-mediated thrombotic thrombocytopenic purpura in childhood treated by caplacizumab, about 3 cases. *J Nephrol*. 2021. <https://doi.org/10.1007/s40620-021-00992-5>
14. Nagel MB, Ryder A, Lobbins M, Bhatt N. Refractory acquired thrombotic thrombocytopenic purpura treated with caplacizumab in a pediatric patient with systemic lupus erythematosus. *Pediatr Blood Cancer*. 2021;**68**(1):e28534.
15. Dutt T, Shaw RJ, Stubbs M, Yong J, Bailiff B, Cranfield T, et al. Real-world experience with caplacizumab in the management of acute TTP. *Blood*. 2021;**137**(13):1731–40.