

Asymmetrical cutaneous vasculitis following COVID-19 vaccination with unusual eosinophil preponderance

doi: 10.1111/ced.14797

Dear Editor,

The COVID-19 pandemic has profoundly impacted people's lives across the globe. Vaccines are perhaps the only silver lining in this dark cloud as they mitigate the severity of the disease. However, as more people are vaccinated, various adverse events (AEs) including cutaneous AEs have been reported. Cutaneous vasculitis is one such rare AE with a few cases reported. We report a case of cutaneous small vessel vasculitis (cSVV) with a strikingly asymmetrical distribution, following COVID-19 vaccination.

A 31-year-old woman presented with a 3-day history of painful purpuric lesions on her legs. She reported no

comorbidities, systemic problems or prior medications. Her medical history was unremarkable apart from receipt of her second dose of inactivated viral vaccine (COVAXIN®; Bharat Biotech, Hyderabad, India) 4 days prior to development of the lesion; she had not developed any similar lesion after the first dose, which had been given 4 weeks before the second dose.

On examination, tender palpable purpura was noted predominantly on the left leg, with pitting oedema (Fig. 1a,b).

Dermoscopy revealed irregularly arranged red blotches with an orange-red background (Fig. 1c).

Histology showed an abundant upper and mid-dermal perivascular infiltrate comprised predominantly of eosinophils and lymphocytes with a few neutrophils, along with erythrocyte extravasation, perivascular fibrin and perivascular oedema (Fig. 2a,b). The patient's financial constraints precluded direct immunofluorescence.

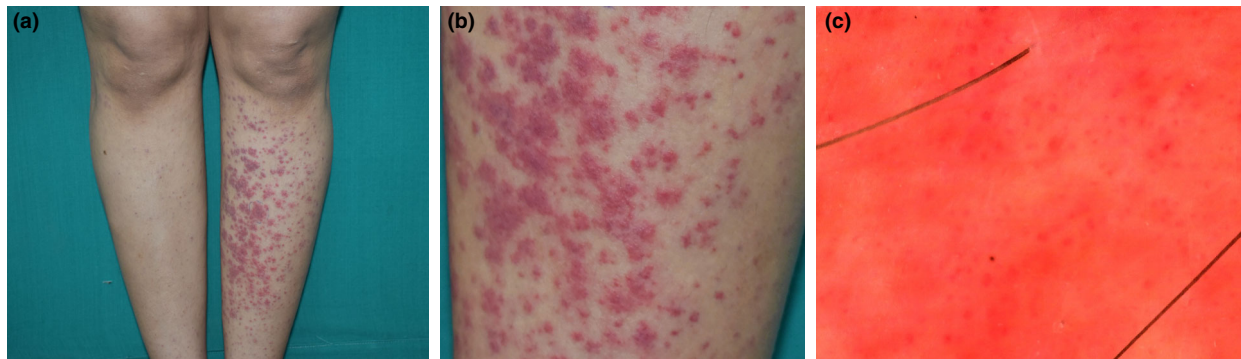


Figure 1 (a) Palpable purpura predominantly involving the left leg; (b) closer view. (c) Dermoscopy (polarized mode) revealing red dots and blotches on a red-orange background.

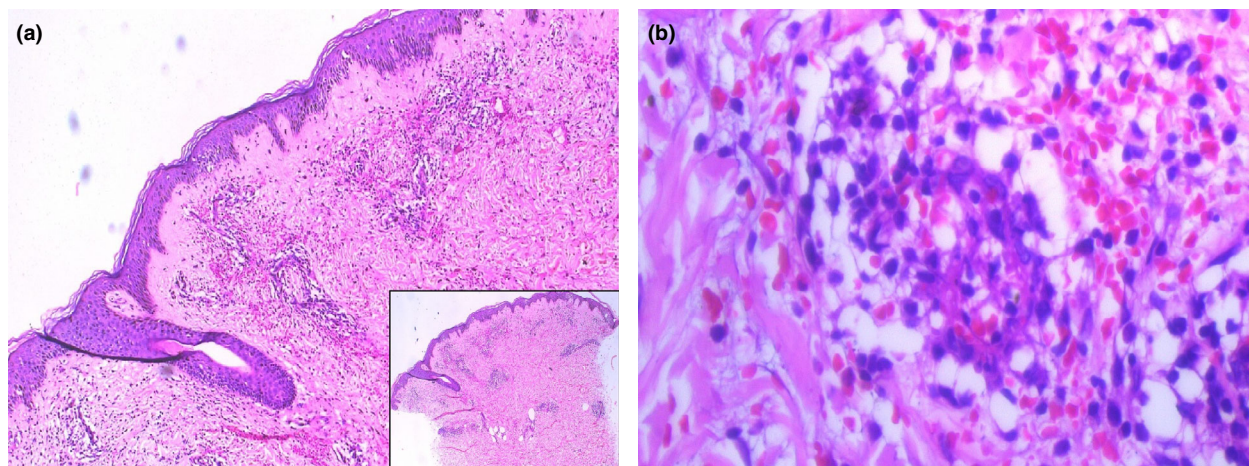


Figure 2 (a) Superficial and mid-dermal perivascular infiltrate with erythrocyte extravasation; (b) fibrin cuffing around dermal blood vessels with eosinophils, lymphocytes and, to a lesser extent, neutrophils. Haematoxylin and eosin, original magnification (a) $\times 100$; inset $\times 25$; (b) $\times 400$.

Routine biochemical and immunological investigations were within normal limits. Reverse transcription (RT)-PCR for COVID-19 and throat swab were negative.

The final diagnosis was cSVV secondary to COVAXIN[®]. The patient was advised rest and leg elevation, and prescribed antihistaminics for a week, after which the lesions resolved with hyperpigmentation. She is being followed up monthly and remains asymptomatic.

Immunological phenomena with vaccines are not unknown, having been noted with hepatitis B, human papillomavirus and influenza vaccines.¹ This could be due to molecular mimicry and immunological crossreactivity due to vaccine antigens.²

With the increase in the number of people receiving COVID-19 vaccines, multiple reports of cutaneous AEs to COVID-19 vaccines have emerged. The largest series of 414 patients described local reactions as the commonest AEs.³ Only three cases of cutaneous vasculitis following COVID-19 vaccination have been reported.³ Another report described a single patient with aggravation of pre-existing vasculitis after mRNA vaccine.² There are multiple reports of COVID-19 manifesting with vasculitis, but the negative COVID-19 PCR test excluded this possibility in our patient.


The obvious asymmetry of the purpura in this case was intriguing. While working, our patient tended to sit with her right leg habitually crossed over the left, thus due to the resultant reduction of gravity and hydrostatic pressure, the purpura were less severe on the right leg. The few previous reports of similar cases also considered the cause to be the dependent position of the affected limb, while the limb which is kept horizontally tends to be spared.^{4,5}

Eosinophil predominance, an unusual histopathological aspect of the present case, has been noted in only a few groups of diseases,⁶ and has not been described previously in vaccine-induced vasculitis.

Awareness and reporting of systemic and cutaneous AEs of vaccines by physicians is important. Further studies are needed to determine the association of vasculitis with vaccine constituents. A wait-and-watch policy in such cases could be adopted before further investigations, as in our patient resolution was noted in 10 days without recurrence.

Acknowledgement

We thank the patient for their written informed consent to publication of the case details.

V. Kharkar,¹ T. Vishwanath,¹  S. Mahajan,¹ R. Joshi² and P. Gole¹

¹Department of Dermatology, Seth G. S. Medical College and K. E. M. Hospital, Mumbai, India and ²Department of Dermatology, P. D. Hinduja National Hospital and Medical Research Centre, Mumbai, India

E-mail: tejasvishwanath.igs@gmail.com

Conflict of interest: the authors declare that they have no conflicts of interest.

Accepted for publication 8 June 2021

References

- Orbach H, Agmon-Levin N, Zandman-Goddard G. Vaccines and autoimmune diseases of the adult. *Discov Med* 2010; **9**: 90–7.
- Cohen SR, Prussick L, Kahn JS *et al*. Leukocytoclastic vasculitis flare following the COVID-19 vaccine. *Int J Dermatol* 2021. <https://doi.org/10.1111/ijd.15623>.
- McMahon DE, Amerson E, Rosenbach M *et al*. Cutaneous reactions reported after Moderna and Pfizer COVID-19 vaccination: a registry-based study of 414 cases. *J Am Acad Dermatol* 2021; **85**: 46–55.
- Tekin B, Salman A, Tuğlular S *et al*. Unilateral cutaneous vasculitis: an uncommon presentation and a possible explanation. *Indian J Dermatol Venereol Leprol* 2015; **81**: 518–19.
- Gershinsky Y, Levi R, Heyman SN. Unilateral purpuric rash in a patient with acute renal failure. *Isr Med Assoc J* 2011; **13**: 515.
- Khoury P, Grayson PC, Klion AD. Eosinophils in vasculitis: characteristics and roles in pathogenesis. *Nat Rev Rheumatol* 2014; **10**: 474–83.

Blood high mobility group box 1 levels are not a suitable biomarker for disease activity or severity in nonsegmental vitiligo

doi: 10.1111/ced.14782

Dear Editor,

High mobility group box (HMGB)1 is one of the molecular patterns associated with intracellular damage. It is released from keratinocytes in response to external stressors and affects neighbouring melanocytes by inducing apoptosis and suppressing melanogenesis.¹ The levels of HMGB1 in the blood and the expression of HMGB1 in skin tissues are increased in psoriasis, alopecia areata, dystrophic epidermolysis bullosa and vitiligo.^{1–4} Serum levels of HMGB1 have a positive correlation with disease severity scores in psoriasis and epidermolysis bullosa.^{2,4} However, the association between blood HMGB1 levels and vitiligo activity or severity has not been studied to date. This study aimed to examine whether blood HMGB1 levels are related to disease activity.

The protocol was approved by the institutional review board of Severance Hospital at Yonsei University College of Medicine (approval numbers 4-2016-0025 and 4-2016-1003). Written informed consent was obtained from all participants.

Active vitiligo was defined as clinical signs (e.g. confetti depigmentation, Koebner phenomenon, inflammatory