



# Urethral self-insertion of a USB cable as sexual experimentation: A case report

Ioannis Loufopoulos, Konstantinos Kapriniotis, Clio Kennedy<sup>\*</sup>, Sabareen Huq, Thomas Reid, Ashwin Sridhar

University College Hospital at Westmoreland Street, London, United Kingdom

## ARTICLE INFO

### Keywords:

Foreign body  
Urethra  
Self-insertion  
Autoerotism

## ABSTRACT

The insertion of a foreign body into the urethra is a delicate matter that may prevent patients from presenting promptly. It can have serious long-term implications. Sexual experimentation and gratification, as well as underlying mental disorders, are considered the main causes of retained foreign bodies in the urethra and bladder. Management varies depending on the shape and size of the object, and the mechanism of insertion. Here we describe the case of a 15-year-old boy who self-inserted a USB wire into his proximal urethra. Manual and endoscopic attempts at removal were unsuccessful. A peno-scrotal urethrostomy was performed.

## 1. Introduction

Intravesical or intraurethral retained foreign bodies represent an important presentation to Emergency Departments. Urgent intervention is of paramount importance, but can be challenging depending on the type, shape, location, and mechanism of insertion. Inappropriate attempts to remove a retained object can lead to more extensive urethral trauma, increasing the risk of long term complications.<sup>1</sup>

We describe the case of a 15-year-old boy who inserted a USB wire into his urethra in the context of autoerotism, requiring urgent tertiary urological assessment and open surgical management.

## 2. Case report

A 15-year-old male patient was transferred to our department from his local hospital following self-insertion of the knotted cable of a USB wire into his urethra in the context of sexual experimentation.

His repeated failed attempts to remove the cable shortly after its insertion resulted in gross haematuria and he presented to the Emergency Department of his local hospital. After urological assessment, he underwent rigid cystoscopy and optical urethrotomy. This was unsuccessful due to the proximal knotting of the cable. A suprapubic catheter was inserted under ultrasound guidance, draining approximately 700mls of haematuric urine. This was performed to prevent any episodes of clot or foreign body induced retention. Following this, the patient was urgently referred and transferred to our department for tertiary

evaluation and management.

On admission, he was haemodynamically stable. The two distal ports of the USB wire were found to be protruding from the external urethral meatus whilst the middle part of the knotted wire remained within the urethra. The patient was an otherwise fit and healthy adolescent with no history of mental health disorders.

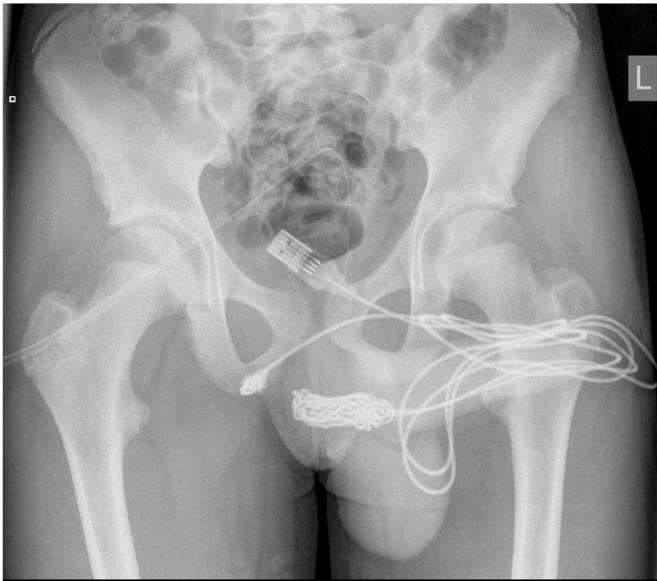
Following his request to be examined without his mother, he confessed that he inserted the cable into his urethra to measure the length of his penis triggered by sexual curiosity. A plain pelvic radiographic imaging (Fig. 1) confirmed the exact position and shape of the formatted knot, and the patient was transferred to the theatre.

A longitudinal peno-scrotal incision over the palpable foreign body was made and careful dissection was undertaken through deeper tissues, splitting the bulbospongiosus muscle. The knotted cable was revealed in the proximal aspect of the penile urethra and cut from the remainder of the cord. Both ends of the wire were pulled out successfully through the external urethral meatus (Fig. 2). The urethra was closed with interrupted sutures and a urethral catheter was inserted. His recovery was uneventful, and he was discharged the following day with simple analgesia, oral antibiotics, and the urethral and suprapubic catheters in situ.

A fluoroscopic urethrogram was arranged two weeks post-procedure to assess the urethral healing before removal of the catheters. No evidence of urine leak or urethral stricture was observed apart from a slight calibre change at the distal bulbar and proximal penile urethra, in the position of the recent urethrostomy (Fig. 3). The catheter was removed successfully, and ongoing follow-up is required to monitor for any long-

<sup>\*</sup> Corresponding author.

E-mail address: [clio.kennedy@nhs.net](mailto:clio.kennedy@nhs.net) (C. Kennedy).



**Fig. 1.** Plain pelvic xray: the knot of the middle part of the electrical wire in the proximal part of the penile urethra.



**Fig. 2.** Post-surgical removal of the cable.

term damage.

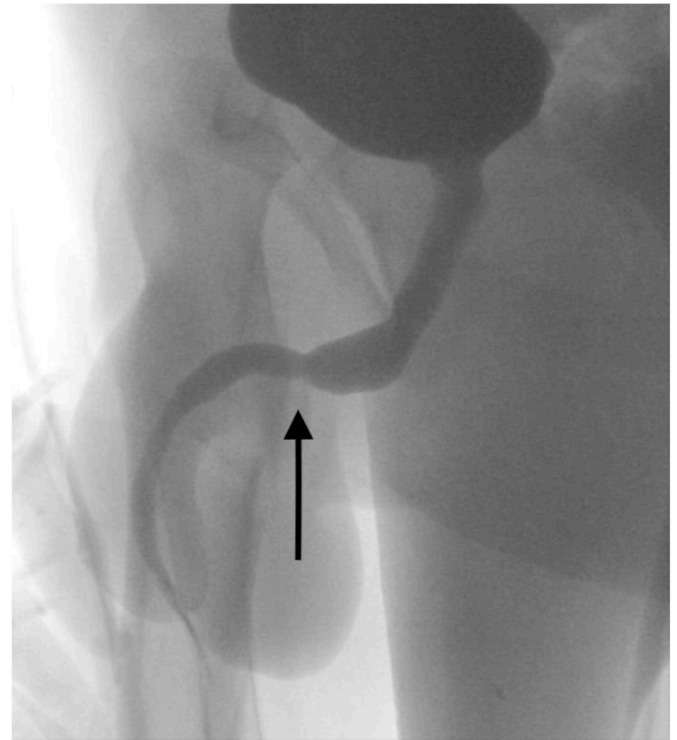
### 3. Discussion

Although retained urethral foreign bodies represent a clinical rarity in the daily urological practice, numerous different cases have been described. The insertion of a wide variety of objects has been documented (needles, pins, iron wires, pistachio shells).<sup>1-4</sup>

The most common causes of foreign body insertion into the lower genitourinary tract include sexual curiosity, sexual practice after intoxication, and mental disorders such as borderline, schizoaffective and bipolar personality disorders<sup>3,4</sup>. More rarely, it could be secondary to migration of deliberately placed medical devices in adjacent organs, such as ureteral stents and intra-uterine devices.<sup>5</sup>

In a minority of cases foreign bodies can be completely asymptomatic. However, in most of the cases they present with lower urinary tract symptoms (LUTS) including dysuria, gross haematuria, painful erection, and even acute urinary retention. Furthermore, depending on the mechanism of insertion, and the size and shape of the object, they can cause delayed complications, mainly recurrent urinary tract infections, urethral strictures or false passages and bladder perforation, which may require major reconstructive procedures to restore the anatomy.<sup>1</sup>

Detailed history including information on the nature of the foreign body and mechanism of insertion are critical to guide further



**Fig. 3.** Fluoroscopic Urethrogram: possible urethral narrowing scarring (arrow) due to urethral injury and subsequent surgical repair.

investigations and this must be obtained in a supportive and non-judgmental manner as patients might feel uncomfortable to disclose all relevant information. Therefore, careful physical examination, radiological evaluation and direct visualization with cystoscopy can help diagnosis and management. Abdominal and pelvic computed tomography or ultrasound scans can provide more detailed information in challenging cases.<sup>1,4</sup>

The management of a urethral foreign body can be particularly challenging and mainly depends on the number, nature, and location of the retained objects, as well as on the presence of significant urethral injury. Simple manual extraction can be effective for smooth, mobile objects protruding from the external urethral meatus.

In more complex cases, endoscopic retrieval is always preferable to open approaches, as it is minimally invasive and associated with less disruption of the urethral anatomy and shorter hospitalisation.<sup>1</sup>

Open approaches, including urethrotomy or cystotomy depending on the location of the object, are reserved for complex cases of abnormally shaped and proximally cited foreign bodies. In our case a urethrotomy was elected due to the shape of the foreign object and the previous unsuccessful cystoscopic attempts. The location of the foreign body (proximal penile urethra) has a rich blood supply and is a relatively forgiving site for urethrotomy. All management techniques should be covered with pre- and post-operative antibiotics for a minimum of seven days. According to Palmer et al. an empirical seven-day-course of antibiotics for patients with negative urine cultures could decrease the rate of a urinary tract infection postoperatively by 20%.<sup>1</sup>

In our case, the patient was an adolescent boy accompanied by his mother and, thus, initially reluctant to provide clear information regarding the circumstances of insertion. No evidence of psychiatric disorder was existing and the “experimentation” in context of autoerotism was noted as the cause of insertion. This constituted another case of sexual curiosity resulting in a challenging urological emergency, managed effectively with open surgery and without any short-term complications.

### Declaration of competing interest

There are no conflicts of interest. The author(s) received no financial support for the research, authorship, and/or publication of this article.

### References

1. Palmer CJ, Houlihan M, Psutka SP, Ellis KA, Vidal P, Hollowell CMP. Urethral foreign bodies: clinical presentation and management. *Urology*. 2016. <https://doi.org/10.1016/j.urology.2016.05.045>.
2. Moon SJ, Kim DH, Chung JH, et al. Unusual foreign bodies in the urinary doi: 10.5213/inj.2010.14.3.186.
3. Van Ophoven A, DeKernion JB. Clinical management of foreign bodies of the genitourinary tract. *J Urol*. 2000. [https://doi.org/10.1016/S0022-5347\(05\)67342-9](https://doi.org/10.1016/S0022-5347(05)67342-9).
4. Kochakarn W, Pummanagura W. Foreign bodies in the female urinary bladder: 20-year experience in ramathibodi hospital. *Asian J Surg*. 2008. [https://doi.org/10.1016/S1015-9584\(08\)60073-1](https://doi.org/10.1016/S1015-9584(08)60073-1).
5. Nouioui MA, Taktak T, Mokadem S, Mediouni H, Khiari R, Ghozzi S. A mislocated intrauterine device migrating to the urinary bladder: an uncommon complication leading to stone formation. *Case Rep Urol*. 2020. <https://doi.org/10.1155/2020/2091915>.