

Samsung, Sanofi, and UCB; and has received research/educational grants from AbbVie, Novartis, and LEO Pharma. **DJ** has served as a board member and or consultant for AbbVie, Almirall, Amgen, Biogen, Celgene, Fresenius Kabi, Janssen-Cilag, LEO Pharma, Eli Lilly, MSD, MEDAC, Novartis, Pfizer, UCB, and Sanofi. He has received payment for development of educational presentations including service on speakers' bureaus from AbbVie, Celgene, Janssen-Cilag, LEO Pharma, Eli Lilly, MEDAC, Novartis, and Pfizer. He had travel/accommodations expenses covered or reimbursed by AbbVie, Amgen, Biogen, Celgene, Fresenius Kabi, Janssen-Cilag, LEO Pharma, Eli Lilly, MSD, MEDAC, Novartis, Pfizer, UCB, and Sanofi. **AE** has received research funding from Pfizer, Eli Lilly, Novartis, Bristol-Myers Squibb, AbbVie, Janssen Pharmaceuticals, the Danish National Psoriasis Foundation, the Simon Spies Foundation, and the Kgl Hofbundtmager Aage Bang Foundation, and honoraria as a consultant and/or speaker from AbbVie, Almirall, LEO Pharma, Galápagos NV, Sun Pharmaceutical, Samsung Bioepis Co., Ltd., Pfizer, Eli Lilly, Novartis, Galderma, Dermavant, UCB, Mylan, Bristol-Myers Squibb, and Janssen Pharmaceuticals. **JMC** has participated as a PI/SI and/or advisor and/or speaker and/or received grants from Almirall, Pfizer, AbbVie, Novartis, Celgene, Amgen, Janssen, Gebro, LEO Pharma, Eli Lilly, MSD, and Mylan. **JJW** is or has been an investigator, consultant, or speaker for AbbVie, Almirall, Amgen, Arcutis, Aristeia Therapeutics, Boehringer Ingelheim, Bristol-Myers Squibb, Dermavant, Dr. Reddy's Laboratories, Eli Lilly, Galderma, Janssen, LEO Pharma, Mindera, Novartis, Regeneron, Sanofi Genzyme, Solius, Sun Pharmaceutical, UCB, Valeant Pharmaceuticals North America LLC, and Zerigo Health. **IP-C** is an employee of Almirall. **PG** has received honoraria as a consultant or received research funding from AbbVie, Almirall, Amgen, Eli Lilly, Novartis, Sanofi, and UCB.

D. Thaçi,^{1,*} D. Jullien,² A. Egeberg,³ J.M. Carrascosa,⁴ J.J. Wu,⁵ I. Pau-Charles,⁶ P. Gisondi⁷

¹Institute and Comprehensive Centre for Inflammation Medicine, University of Lübeck, Lübeck, Germany, ²Department of Dermatology, Edouard Herriot Hospital, Lyon, France, ³Department of Dermatology, Bispebjerg Hospital, Copenhagen, Denmark, ⁴Department of Dermatology, Germans Trias i Pujol University Hospital (HUGTP), Autonomous University of Barcelona (UAB), Badalona, Spain, ⁵Dermatology Research and Education Foundation, Irvine, California, USA, ⁶Almirall R&D, Barcelona, Spain, ⁷Department of Medicine, Section of Dermatology and Venereology, University of Verona, Verona, Italy

*Correspondence: D. Thaçi. E-mail: Diamant.Thaci@uksh.de

References

- 1 Wan MT, Shin DB, Winthrop KL, Gelfand JM. The risk of respiratory tract infections and symptoms in psoriasis patients treated with interleukin 17 pathway-inhibiting biologics: A meta-estimate of pivotal trials relevant to decision making during the COVID-19 pandemic. *J Am Acad Dermatol* 2020; **83**: 677–679.
- 2 Reich K, Papp KA, Blauvelt A *et al*. Tildrakizumab versus placebo or etanercept for chronic plaque psoriasis (reSURFACE 1 and reSURFACE 2): results from two randomised controlled, phase 3 trials. *Lancet* 2017; **390**: 276–288.
- 3 Thaçi D, Piaserico S, Warren RB *et al*. Five-year efficacy and safety of tildrakizumab in patients with moderate to severe psoriasis who respond at week 28: pooled analyses of two randomised phase 3 clinical trials (reSURFACE 1 and reSURFACE 2). *Br J Dermatol* 2021; **185**: 323–334. <https://doi.org/10.1111/bjd.19866>.
- 4 Galanti M, Birger R, Ud-Dean M *et al*. Longitudinal active sampling for respiratory viral infections across age groups. *Influenza Other Respir Viruses* 2019; **13**: 226–232.
- 5 Schett G, Sticherling M, Neurath MF. COVID-19: risk for cytokine targeting in chronic inflammatory diseases?. *Nat Rev Immunol* 2020; **20**: 271–272.
- 6 Syed MN, Shin DB, Wan MT, Winthrop KL, Gelfand JM. The risk of respiratory tract infections in patients with psoriasis treated with interleukin 23 pathway-inhibiting biologics: A meta-estimate of pivotal trials relevant to decision making during the COVID-19 pandemic. *J Am Acad Dermatol* 2020; **83**: 1523–1526.
- 7 Huang C, Wang Y, Li X *et al*. Clinical features of patients infected with 2019 novel coronavirus in Wuhan, China. *Lancet* 2020; **395**: 497–506.
- 8 Wu D, Yang XO. TH17 responses in cytokine storm of COVID-19: An emerging target of JAK2 inhibitor Fedratinib. *J Microbiol Immunol Infect* 2020; **53**: 368–370.
- 9 Talamonti M, Galluzzo M, Chiricozzi A *et al*. Characteristic of chronic plaque psoriasis patients treated with biologics in Italy during the COVID-19 Pandemic: Risk analysis from the PSO-BIO-COVID observational study. *Expert Opin Biol Ther* 2021; **21**: 271–277.
- 10 Mahil SK, Dand N, Mason KJ *et al*. Factors associated with adverse COVID-19 outcomes in patients with psoriasis-insights from a global registry-based study. *J Allergy Clin Immunol* 2021; **147**: 60–71.

DOI: 10.1111/jdv.17427

Delayed cutaneous reaction to ChAdOx1 nCoV-19 vaccine: Is it an 'AstraZeneca arm'?

Dear Editor,

Blumenthal *et al.*¹ reported cases of delayed large local reaction to the mRNA-1273 Moderna COVID-19 vaccine, which was called the 'Moderna arm' for the first time. Intriguingly, this phenomenon was observed primarily in Moderna vaccine but rarely reported in BNT162b2 COVID-19 vaccine by Pfizer-BioNTech.^{2–4} Because the reports were limited to mRNA vaccines, a delayed-type hypersensitivity reaction to the excipient polyethylene glycol (PEG) in both mRNA vaccines was suggested as one potential aetiology.^{4,5}

Unlikely these mRNA vaccines, ChAdOx1 nCoV-19 (AZD1222) is a replication-defective chimpanzee adenovirus-vectored vaccine, and it includes polysorbate 80 as an excipient.⁶ Recently, we have observed delayed cutaneous reactions around the injection site of the ChAdOx1 nCoV-19 vaccine. We report four cases with such reactions that developed at least three days (range, Day 4–17) after the first dose of vaccination (Table 1). All the patients were female

Table 1 Demographic and clinical data of subjects with delayed cutaneous reaction to ChAdOx1 nCoV-19 vaccine*

Patient	Patient 1	Patient 2	Patient 3	Patient 4
Age, years	44	30	58	53
Sex	Female	Female	Female	Female
Past medical history	Allergic rhinitis	No	Dyslipidemia	Vitiligo
Current medication	No	No	Atorvastatin	No
Past history of cutaneous reaction to vaccination	No	No	No	No
Day of skin reaction onset after COVID-19 vaccination	4	5	17	14
Symptoms and signs of cutaneous reaction	Erythema, swelling, pain, tenderness	Erythema, swelling, pain, tenderness, pruritus	Erythema, swelling, pain, tenderness	Erythema, swelling, pruritus
Lesion size, cm	10 × 10	15 × 8	9 × 7.5	18 × 10
Immediate injection site reaction after vaccination	No	No	No	No
Immediate systemic symptoms after vaccination	Fever (38.5°C), chill, myalgia	Fever (38.4°C), chill, fatigue, headache	Fever (38.1°C), chill, fatigue, headache, myalgia	Fatigue, myalgia
Concurrent systemic symptoms with delayed skin reaction	No	No	No	No
Treatment	Oral prednisolone 30 mg for 4 days	Oral antihistamine, topical corticosteroid for 3 days	Oral antihistamine, topical corticosteroid for 4 days	Oral antihistamine, topical corticosteroid for 4 days
Duration of skin reaction, days	4	17	7	6
Treatment response	Complete resolution	Complete resolution	Complete resolution	Complete resolution

*None of the patients had known previous SARS-CoV-2 infection. The clinical data were reported by patients, and symptoms were evaluated by a dermatologist or allergist.

healthcare workers (1 physician, 2 nurses and 1 laboratory technician) at our university hospitals and were ethnically Korean. They did not have a previous history of hypersensitivity reactions to drugs or any vaccine. Only one patient had allergic rhinitis but did not require regular medication. Routine blood tests including complete blood cell counts, C-reactive protein and serum IgE were unremarkable. All patients had a large delayed skin reaction that started with erythematous swelling (Fig. 1a–d), and three developed systemic symptoms including fever, chill and myalgia from the day of vaccination and that resolved before the delayed skin reactions. Thus, at the development of delayed local skin reactions, none of the patients experienced concurrent systemic symptoms. The delayed skin lesions resolved after short-term treatment, such as oral antihistamines or topical or oral corticosteroids, while the duration of skin reaction varied from 4 to 18 days. Skin biopsy from three patients showed superficial perivascular and perifollicular lymphocytic infiltration with sparse eosinophils (Fig. 1e–k). These findings suggest that the delayed local cutaneous reactions are mediated by hypersensitivity mechanisms. However, the exact pathophysiological mechanism remains unclear if they are true hypersensitivity reactions. One reason for this controversy is that the skin tests (patch, prick, and intradermal test) of the patient who was injected BNT162b2 vaccine were all negative.² In the aspect of hypersensitivity reaction, unlike PEG, polysorbate 80 in ChAdOx1 nCoV-19 vaccine has been used in other vaccines before, it is still unclear which antigen in the vaccine caused these reactions.

Our report suggests that the delayed local cutaneous reactions to the COVID-19 vaccines are not vaccine-specific, since both mRNA vaccine and viral-vector vaccine showed such reactions. Before implementing a mass vaccination campaign with various COVID-19 vaccines, clinicians should be aware of the possible ‘COVID-arm’ to avoid unnecessary tests or treatment. While the Centers for Disease Control and Prevention reported that patients who experienced delayed cutaneous reactions to the first dose of COVID-19 vaccine could be safely vaccinated with the second dose,⁷ more data are required to understand and manage the ‘COVID-arm’ to various COVID-19 vaccines.

Conflicts of interest

Jeong Eun Kim, Hyun Lee, Seung Sam Paik, Ji-Yong Moon, Ho Joo Yoon and Sang-Heon Kim declare to have no conflict of interest.

Funding source

None.

IRB approval

Yes (Number HYUH 2021-03-052).

Acknowledgement

The patients in this manuscript have given written informed consent to the publication of their case details. This research was

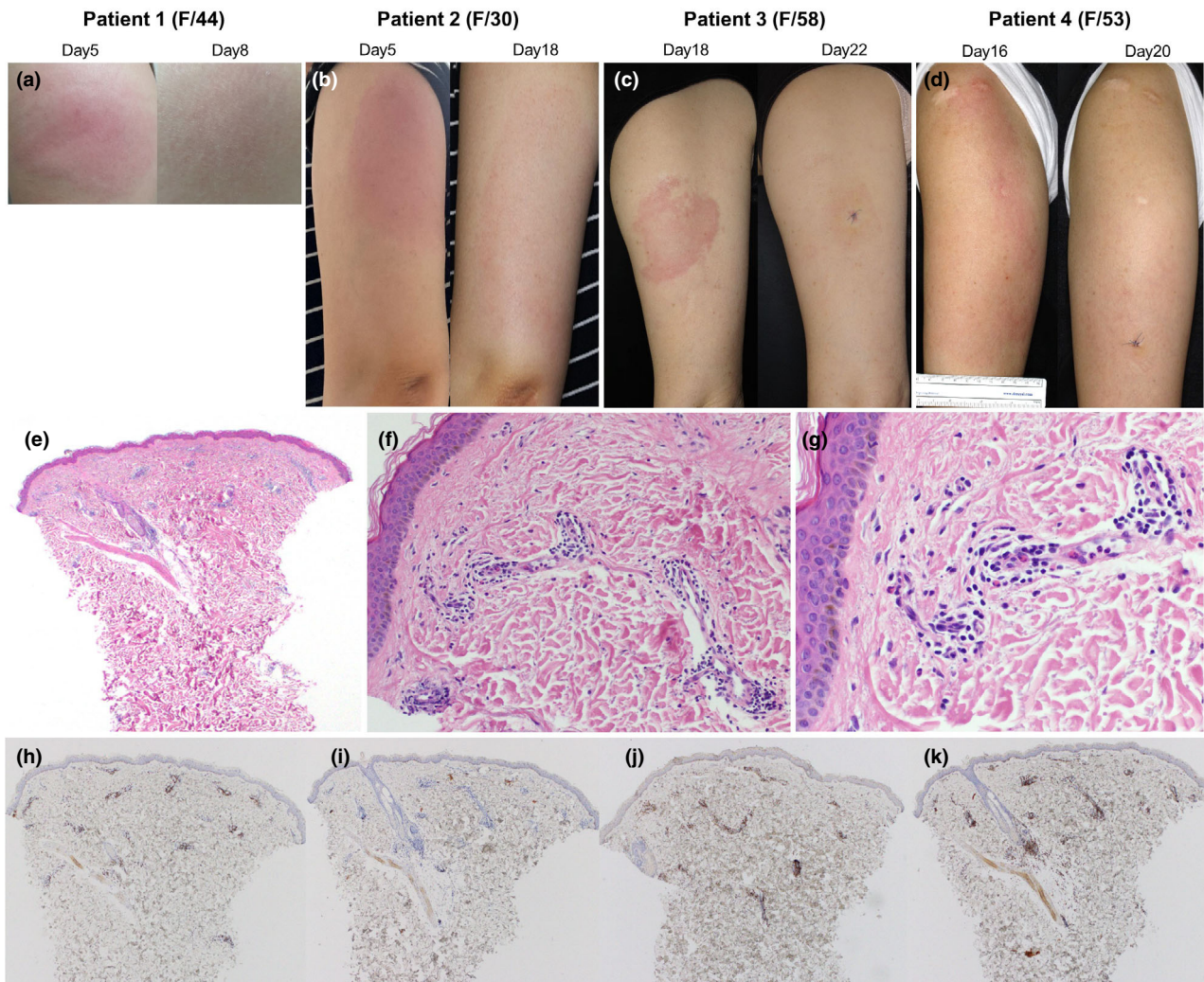



Figure 1 Clinical photographs and the representative histopathologic findings of delayed cutaneous reactions to the ChAdOx1 nCoV-19 vaccine. (a) Patient 1 presented considerable induration with pain and tenderness on Day 5. After 3 days of oral prednisolone 30 mg, the skin lesion resolved. (b) Patient 2 started a painful erythematous swelling on Day 5. Without treatment, the skin lesion became larger (15 × 8 cm), but pain decreased, and pruritus occurred on Day 18. The skin lesion gradually improved after 3 days of oral antihistamine and topical corticosteroid. (c) Patient 3 presented with erythematous tender plaque on day 17. There was no immediate skin reaction after vaccination. On Day 18, the patient underwent skin biopsy and was prescribed oral antihistamine and topical corticosteroid. Four days later (on Day 22), the skin lesion was much improved. (d) Patient 4 suffered from 18 × 10 cm sized itchy erythematous swollen plaque on Day 16. There was no immediate cutaneous symptom after vaccination and no concurrent systemic symptom. (e–g) Skin biopsy specimen from patient 4 shows superficial perivascular and perifollicular lymphocytic infiltration and some eosinophils. Neutrophils are present inside dilated small vessels. Immunohistochemistry reveals mainly CD3⁺ T cells with sparse exocytosis (h) and few CD20⁺ B cells (i). There is a mixed population of CD4⁺ (j) and CD8⁺ (k) cells, but CD4⁺ is predominant. These findings are consistent with a delayed hypersensitivity reaction (e: H&E × 40, f: H&E × 200, g: H&E × 400, h: CD3 × 40, i: CD20 × 40, j: CD4 × 40, k: CD8 × 40).

supported by a grant from the Korean Academy of Asthma, Allergy and Clinical Immunology.

J.E. Kim,¹  H. Lee,² S.S. Paik,³ J.-Y. Moon,² H.J. Yoon,² S.-H. Kim^{2,*}

¹Department of Dermatology, Hanyang University College of Medicine, Seoul, Korea, ²Division of Pulmonary Medicine and Allergy, Department of Internal Medicine, Hanyang University College of Medicine, Seoul, Korea,

³Department of Pathology, Hanyang University College of Medicine, Seoul, Korea

*Correspondence: S.-H. Kim. E-mail: sangheonkim@hanyang.ac.kr

References

- Blumenthal KG, Freeman EE, Saff RR *et al.* Delayed large local reactions to mRNA-1273 vaccine against SARS-CoV-2. *N Engl J Med* 2021; **384**: 1273–1277.
- Baeck M, Marot L, Belkhir L. Delayed large local reactions to mRNA vaccines. *N Engl J Med.* 2021;**384**(24):e98.
- Fernandez-Nieto D, Hammerle J, Fernandez-Escribano M *et al.* Skin manifestations of the BNT162b2 mRNA COVID-19 vaccine in healthcare workers. 'COVID-arm': a clinical and histological characterization. *J Eur Acad Dermatol Venereol.* 2021;**35**(7):e425–e427.
- McMahon DE, Amerson E, Rosenbach M, *et al.* Cutaneous reactions reported after Moderna and Pfizer COVID-19 vaccination: A registry-based study of 414 cases. *J Am Acad Dermatol* 2021; **85**(1): 46–55.
- Farinazzo E, Ponis G, Zelin E *et al.* Cutaneous adverse reactions after mRNA COVID-19 vaccine: early reports from North-East Italy. *J Eur Acad Dermatol Venereol* 2021; **35**: e548–e551.
- Voysey M, Clemens SAC, Madhi SA *et al.* Safety and efficacy of the ChAdOx1 nCoV-19 vaccine (AZD1222) against SARS-CoV-2: an interim analysis of four randomised controlled trials in Brazil, South Africa, and the UK. *Lancet* 2021; **397**: 99–111.
- Centers for Disease Control and Prevention. <https://www.cdc.gov/coronavirus/2019-ncov/vaccines/safety/allergic-reaction.html>. Accessed 29th March 2021.

DOI: 10.1111/jdv.17476

Impact of the COVID-19 pandemic on melanoma diagnosis

Dear Editor,

Many healthcare systems have responded to the COVID-19 pandemic by delaying and/or cancelling elective surgical procedures, particularly during the lockdown.^{1–3} There is a concern that this could have affected the early diagnosis of malignant melanoma (MM) that is critical to improve its prognosis.^{4,5} The objective of this observational study was to investigate whether a reduction in the incidence of new diagnoses of MM

has occurred following the COVID-19 outbreak. All the consecutive histological diagnoses of MM were retrospectively collected in the pathological laboratories of four provinces of the Veneto region in northern Italy, namely Verona, Vicenza, Rovigo and Treviso, between 1 March and 31 October 2020 and the same period of 2019. All cases were stratified into three categories according to Breslow thickness: *in situ*, <1 and ≥1 mm. The date of MM excision was considered for all the time-related analyses. The period March–October 2020 was compared with the same period of 2019. Incidence rates (IR) of MM per 100 000 person-year were computed by considering the overall population of the included provinces in the Veneto region and were presented along with their exact mid-P 95% confidence intervals (CI). Incidence rates ratios (IRR) comparing IR of 2020 vs. 2019 were produced along with their exact mid-P 95% CI and *P*-values. In addition, IRR comparing the number of observed cases in 2020 and the expected number based on the estimated annual per cent change (APC) of MM from the regional cancer registry was calculated.⁶ Univariate logistic regression analysis was used to compare Breslow thickness categories in the same periods of 2020 and 2019. A total of 556 MM cases in the period March–October 2020 vs. 634 MM cases in the same period of 2019 were collected (Table 1). No difference in age, sex and Breslow thickness was observed between the two periods.

The number of MM cases stratified by Breslow thickness category and excision dates in the period March–October 2020 and 2019 with a finer division by 2-month interval is reported in Fig. 1. The number of missed expected cases, based on an estimated 3.4% annual change of MM incidence from Veneto regional data, is shown as well (Fig. 1).

The incidence of MM in the period March–October 2020 vs the same period of 2019 was 28.7 (95% C.I. 26.4–31.2) and 32.8 (95% C.I. 30.2–35.4), respectively; the corresponding IRR was 0.88 (95% C.I. 0.78–0.98, *P* = 0.02). When considering the number of cases observed vs. those expected based on estimated

Table 1 Demographics and clinical characteristics of patients by year in the period March–October 2019 and 2020

		March–October 2019		March–October 2020		<i>P</i> †
		<i>N</i> = 634	%	<i>N</i> = 556	%	
Sex	Female	283	44.6%	242	43.5%	0.70
	Male	351	55.4%	314	56.5%	
Age	Median, IQR	61.0	50.0–72.0	62.5	51.0–73.0	0.69
Breslow	Median, IQR‡	0.5	0.3–1.1	0.5	0.3–1.2	0.57
	<i>In situ</i>	163	25.7%	133	23.9%	0.62
	<1 mm	338	53.3%	295	53.1%	
	1+ mm	133	21.0%	128	23.0%	

IQR, interquartile range.

†Continuous variables were presented as medians with interquartile ranges (IQR), while nominal variables as numbers with percentages. Chi-square test and Mann–Whitney *U* test were used for nominal and continuous variables, respectively. ‡Excluding *in situ* melanoma.