

The necrosis and peripheral purpuric appearance of vulvar ulcers could also recall one of the typical skin patterns described during COVID-19.⁶

The lack of definitive knowledge on the aetiology of UVAL, as well as the limited use of histology in confirming the imputability of a specific infectious agent, does not allow us to affirm with certainty that SARS-CoV-2 is the cause of UVAL in our patient. However, the timing of onset and the unique positive serology for SARS-CoV-2 may suggest an aetiological role of this virus.

During the COVID-19 pandemic, it seems advisable to include SARS-CoV-2 as a possible cause of UVAL and to focus attention on the possible association with UVAL and its rare male counterpart, the juvenile gangrenous vasculitis of the scrotum.

Acknowledgement



The parents of the patient in this manuscript have given written informed consent to the publication of the patient case details.

Conflict of interest

None.

Funding source

None.

M.C. Alberelli,¹ A. Panariello,¹ M. Olivi,² A. Borghi,³ 
P. Zedde,^{3,*}  M. Corazza³

¹O.U. of Pediatrics, Marche Nord Hospital, Pesaro, Italy, ²O.U. of Obstetrics and Gynecology, Marche Nord Hospital, Pesaro, Italy,

³Department of Medical Sciences, Section of Dermatology and Infectious Diseases, University of Ferrara, Ferrara, Italy

*Correspondence: P. Zedde. E-mail: zddpnt@unife.it

References

- Huppert JS. Lipschutz ulcers: evaluation and management of acute genital ulcers in women. *Dermatol Ther* 2010; **23**: 533–540.
- Sadoghi B, Sary G, Wolf P, Komericki P. Ulcus vulvae acutum Lipschütz: a systematic literature review and a diagnostic and therapeutic algorithm. *J Eur Acad Dermatol Venereol* 2020; **34**: 1432–1439.
- Sárdy M, Wollenberg A, Niedermeier A, Flaig MJ. Genital ulcers associated with Epstein-Barr virus infection (ulcus vulvae acutum). *Acta Derm Venereol* 2011; **91**: 55–59.
- Rekhtman S, Tannenbaum R, Strunk A *et al*. Eruptions and related clinical course among 296 hospitalized adults with confirmed COVID-19. *J Am Acad Dermatol* 2021; **84**: 946–952.
- Magro C, Mulvey JJ, Berlin D *et al*. Complement associated microvascular injury and thrombosis in the pathogenesis of severe COVID-19 infection: a report of five cases. *Transl Res* 2020; **220**: 1–13.
- Catalá Gonzalo A, Galván Casas C. COVID-19 and the Skin. *Actas Dermosifiliograficas* 2020; **111**: 447–449. <https://doi.org/10.1016/j.ad.2020.04.007>

DOI: 10.1111/jdv.17463

Development of severe pemphigus vulgaris following SARS-CoV-2 vaccination with BNT162b2

Dear Editor,

Pemphigus vulgaris (PV) is a rare and severe autoimmune disorder of skin and mucosa. In PV, the production of autoantibodies against desmosomal proteins of the skin, namely desmoglein (Dsg) 1 and Dsg3, leads to a clinical phenotype characterized by blistering and severe erosions. Several factors including genetic susceptibility, certain drugs and malignant disorders have been reported to trigger or exacerbate PV.¹ Here, we report the first case of a patient, who developed PV following COVID-19 vaccination with the mRNA vaccine BNT162b2 (Comirnaty®, Biontech/Pfizer).

A 40-year-old female patient of Asian ethnicity was referred to our department following the outbreak of painful, non-healing erosions of the oral mucosa, the trunk and the back (Fig. 1a–c). The patient's history revealed that first oral lesions occurred mid-January 5 days after the first administration of BNT162b2. Three days after the patient received the second vaccine dose, oral lesions worsened heavily; in addition, blisters and erosions occurred on the upper part of the body. Prior to vaccination, the patient was otherwise healthy, without any history of skin disease and without any medication. Due to the clinical presentation suspicious for pemphigus disease, we performed skin and blood sampling. The histology of lesional skin showed acantholysis within the lower epidermal layers, and the presence of a dense lymphocytic dermal infiltrate, accompanied by a rich presence of plasma cells (Fig. 1d). Direct immunofluorescence from perilesional skin revealed a prominent deposition of IgG in a honeycomb-like intercellular epidermal pattern (Fig. 1e). Finally, we detected high titres of autoantibodies against Dsg3 and Dsg1 in the patient's sera (974 and 124 RE/mL, respectively) (Euroimmun, Lübeck, Germany). With these findings, we confirmed the clinically suspected diagnosis of PV and initiated an immunosuppressive treatment with oral prednisone (1mg per kg body weight, eventually tapered) and azathioprine (100mg/day).² This approach ceased blistering and diminished autoantibody production. The patient is currently under regular clinical follow-ups in our clinic.

Single cases of manifestation of PV following vaccination have been reported after administration of vaccines against rabies, influenza, hepatitis B, diphtheria, typhoid, tetanus and anthrax (Table 1). The BNT162b2 vaccine is a lipid nanoparticle-formulated nucleoside-modified RNA (modRNA) encoding the SARS-CoV-2 full-length spike protein in its perfusion conformation. Following injection, common side effects like local redness,

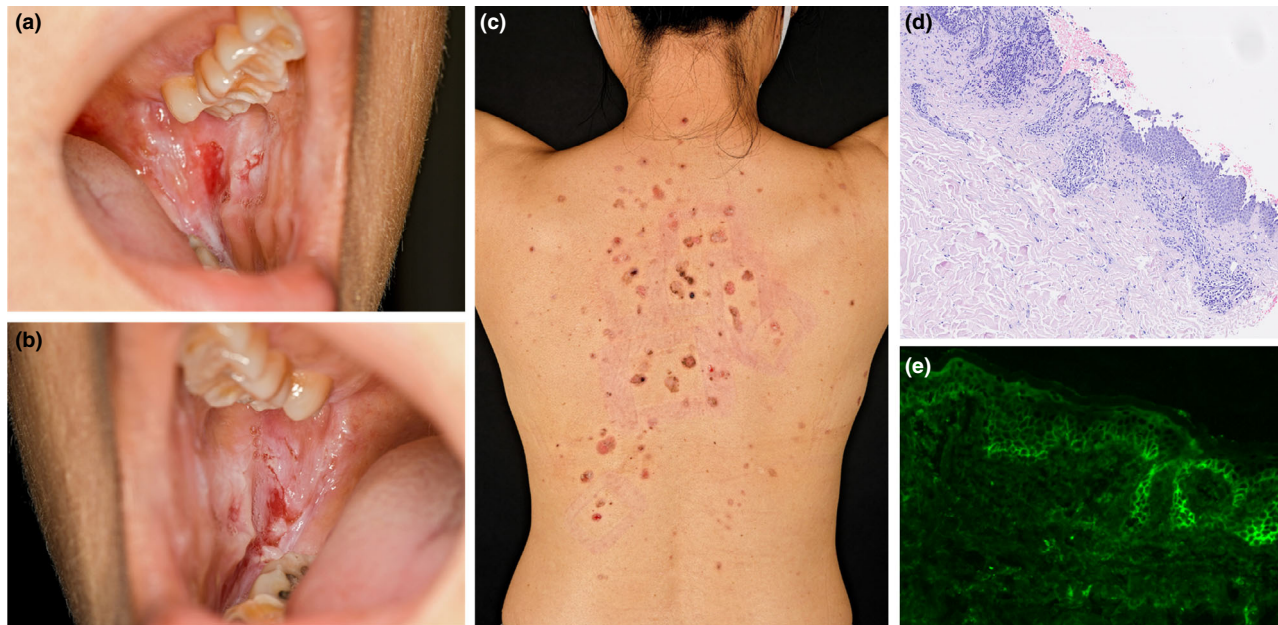


Figure 1 Clinical appearance and immunohistology of pemphigus in a patient vaccinated against SARS-CoV-2. (a and b) Extensive painful erosions of the oral mucosa; (c) erosive annular red-brownish lesions on the upper back; (d) histology of lesional skin, with pronounced acanthosis and strong dermal infiltration; (e) direct immunofluorescence from perilesional skin presenting intercellular epidermal IgG deposition in a honeycomb-like pattern.

Table 1 Reported cases of pemphigus triggered or exacerbated following vaccination

Vaccine against	Type	Disease type	Reference
Rabies	Human diploid cell vaccine	PV—new onset	Yalçın B, <i>J Dermatol</i> , 2007
Influenza	N/a	PV—exacerbation	De Simone C, <i>Clin Exp Dermatol</i> , 2008
	N/a	PV—new onset	Mignogna M, <i>Int J Dermatol</i> , 2000
Hepatitis B	Recombinant (Engerix-B)	PV—new onset	Berkun Y, <i>Autoimmunity</i> , 2005
Typhoid	Typhim Vi	PV—new onset	Bellaney G, <i>Clin Exp Dermatol</i> , 1996
Tetanus	N/a	PF—exacerbation	Korang K, <i>Acta Derm Venereol</i> , 2002
Anthrax	Anthrax vaccine absorbed (AVA)	PV—new onset	Muellerhoff M, <i>J Am Acad Dermatol</i> , 2004
Sars-CoV2	Modified mRNA	PV—new onset	Solimani F, <i>J Eur Acad Dermatol Venereol</i> , 2021

N/a, not available; PV, Pemphigus vulgaris; PF, Pemphigus foliaceus.

swelling, pain or systemic effects like fever, headaches, joint pain or diarrhoea are commonly described.³ The clinical appearance of autoimmune disorders after antiviral vaccinations is rare.⁴ Different processes such as molecular mimicry, inflammatory dysregulation in genetically susceptible persons, epitope

spreading or bystander activation seem to be involved in the onset of autoimmunity following vaccinations.⁴ BNT162b2 injection provokes a potent T and B cell activation. After inoculation, there is a profound CD4⁺ and CD8⁺ expansion, with production of IFN- γ , IL-2 and skewing of T cells towards a Th1 profile.³ Similarly, vaccination boosts B cell activity, with a rapid increase in the numbers of plasma cells, memory B cells and level of antibodies.³ Single individuals develop a strong IL-4 production following vaccination with BNT162b1.³ Although data regarding IL-17 and IL-21 production following BNT162b2 inoculation are still missing, the production of IL-17 and IL-21 seems to play an important role in vaccine-induced immunological protection.^{5,6} Of note, cytokines like IL-4, IL-17 and IL-21 are linked to germinal centre activation and critically implicated in autoimmune disorders like pemphigus, especially in its initial phase.⁷ However, a strong antibody response following vaccination usually requires more than 5 days. In patients vaccinated with BNT162b1, specific antibodies appear 14–21 days later.³ It is very likely that in our patient the vaccination with BNT162b2 boosted her T/B cell response that resulted in the unwanted onset of pemphigus. Genetic susceptibility may promote such a side effect.

Even if we cannot identify a direct pathological link between the BNT162b2 and the onset of PV lesions, there is a clear temporal relation between these two events. This report does not intend to create public concern regarding the safety of this vaccine, yet occurrence of vaccine-related events warrants documentation and



may help to define risk profiles for patients in the future, especially in those with subclinical autoantibody titres.

Acknowledgements

The patients in this manuscript have given written informed consent to the publication of their case details. This work was supported by the Deutsche Forschungsgemeinschaft (DFG) FOR 2497/TP02 (GH133/2-2 to Kamran Ghoreschi).

Conflict of interest

The authors declare no conflict of interests.

F. Solimani,^{1,*}  Y. Mansour,¹ D. Didona,² A. Dilling,¹ K. Ghoreschi,¹ K. Meier¹ 

¹Department of Dermatology, Venereology and Allergology, Charité-Universitätsmedizin Berlin, Corporate Member of Freie Universität Berlin, Humboldt-Universität zu Berlin, Berlin Institute of Health, Berlin, Germany,

²Department of Dermatology and Allergology, Philipps University, Marburg, Germany

*Correspondence: F. Solimani. E-mail: farzan.solimani@charite.de

References

- 1 Kasperkiewicz M, Ellebrecht CT, Takahashi H *et al*. Pemphigus. *Nat Rev Dis Primers* 2017; **3**: 17026.
- 2 Amber KT, Maglie R, Solimani F, Eming R, Hertl M. Targeted therapies for autoimmune bullous diseases: current status. *Drugs* 2018; **78**: 1527–1548.
- 3 Sahin U, Muik A, Derhovanessian E *et al*. COVID-19 vaccine BNT162b1 elicits human antibody and TH1 T cell responses. *Nature* 2020; **586**: 594–599.
- 4 Segal Y, Shoenfeld Y. Vaccine-induced autoimmunity: the role of molecular mimicry and immune crossreaction. *Cell Mol Immunol* 2018; **15**: 586–594.
- 5 Priebe GP, Walsh RL, Cederroth TA *et al*. IL-17 is a critical component of vaccine-induced protection against lung infection by lipopolysaccharide-heterologous strains of *Pseudomonas aeruginosa*. *J Immunol* 2008; **181**: 4965–4975.
- 6 Spensieri F, Borgogni E, Zedda L *et al*. Human circulating influenza-CD4+ICOS1+IL-21+ T cells expand after vaccination, exert helper function, and predict antibody responses. *Proc Natl Acad Sci USA* 2013; **110**: 14330–14335.
- 7 Holstein J, Solimani F, Baum C *et al*. Immunophenotyping in pemphigus reveals a TH17/TFH17 cell-dominated immune response promoting desmoglein1/3-specific autoantibody production. *J Allergy Clin Immunol* 2021; **147**: 2358–2369

DOI: 10.1111/jdv.17480

LETTERS TO THE EDITOR

Atopic dermatitis, dupilumab and cancers: a case series

Dear Editor,

Data regarding the association between atopic dermatitis (AD) and specific tumours are still controversial.^{1–3} Conflicting data have also been reported about the involvement of Interleukin (IL)-4 and IL-13 in carcinogenesis.⁴

We report our experience relating to both the use of dupilumab in patients with a previous history of cancer and the onset of tumour in patients receiving dupilumab. In our centre, 280 patients suffering from moderate-to-severe AD and treated with dupilumab have been prospectively collected from January 2019 to October 2020.⁵ Out of them, a previous history of cancer was found in seven patients.

We treated with dupilumab:

- 1 A 25-year-old female patient who started dupilumab therapy 15 months after autologous stem cell transplantation for relapsed stage IIb Hodgkin's lymphoma.
- 2 A 56-year-old woman with a pT1c-pN0 infiltrating ductal breast carcinoma diagnosed 3 years before starting dupilumab.
- 3 A 64-year-old woman who received diagnosis of lobular carcinoma in situ and of pT2pN0 infiltrating lobular carcinoma of the breast 13 and 11 years before starting dupilumab, respectively.
- 4 A 77-year-old man for whom dupilumab was started 11 years after diagnosis of adenocarcinoma of the large intestine (pT1N0) and 1 year after prostatectomy for T2cN0 adenocarcinoma.
- 5 A 40-year-old man diagnosed with papillary thyroid carcinoma (pT1bN0) 3 years before.
- 6 A 60-year-old man with history of papillary urothelial bladder carcinoma (G3pT1) diagnosed 3 years before.
- 7 A 53-year-old patient with stage IV lung adenocarcinoma previously treated with pembrolizumab.

Globally, <5 years have passed between cancer diagnoses and the starting of dupilumab for six out of seven patients with a cancer history; four of them already have a significant follow-up time beyond 1 year (for patients no. 1, 3, 5 and 6). In most cases, these tumours were in early stages and, therefore, with a good prognosis. Most of the patients had long-lasting skin disease, and two patients had undergone cyclosporine treatment prior to cancer diagnosis. To date, no cancer recurrence has been observed after a mean follow-up of 54 weeks.

Out of 273 patients without a history of cancer, three patients developed a tumour during dupilumab treatment:

- 1 A 46-year-old man developed a low-grade papillary urothelial carcinoma of the bladder (pTa) after 5 months of dupilumab therapy. The treatment was temporarily suspended and the patient underwent cancer therapy with intravesical epirubicin; dupilumab was then resumed effectively.⁶
- 2 Two patients were diagnosed with testicular neoplasm: A 32-year-old man developed pT2 seminoma, and a 23-year-old was diagnosed with embryonic carcinoma. After multidisciplinary discussion with the oncologists, in the first case treatment with dupilumab was suspended at the time of a single administration of carboplatin and resumed 4 weeks later, while for the second patient a longer duration standard chemotherapy was required (cisplatin, etoposide and