

Myocarditis following COVID-19 vaccination

Risheek Kaul^{a,*}, Jayakumar Sreenivasan^a, Akshay Goel^a, Aaqib Malik^a,
Dhrubajyoti Bandyopadhyay^a, Chengyue Jin^b, Mala Sharma^a, Avi Levine^a, Stephen Pan^a,
Anthon Fuisz^a, Howard A. Cooper^a, Julio A. Panza^a

^a Department of Cardiology, Westchester Medical Center and New York Medical College, Valhalla, NY, United States

^b Department of Medicine, Westchester Medical Center and New York Medical College, Valhalla, NY, United States

The messenger ribonucleic acid (mRNA) - based BNT162b2 (Pfizer, Inc) and mRNA-1273 vaccines (Moderna, Inc) were demonstrated in large randomized clinical trials to be highly effective in preventing severe illness from COVID-19 and to have acceptable safety profiles [1,2]. Given the short timeline between development and widespread utilization of this novel vaccine technology, however, careful investigation of possible unexpected adverse effects during real-world use is essential. In this report, we describe 2 cases of myocardial inflammation temporally associated with receipt of a COVID-19 mRNA vaccine in patients without evidence of concurrent or prior COVID-19 infection.

We describe 2 patients with acute myocarditis occurring within 72 h after the administration of mRNA-based COVID-19 vaccine. Clinical presentations, in-hospital events, treatments, and outcomes are presented in the Table 1. Cardiac magnetic resonance imaging findings and electrocardiograms of both patients with myocarditis are shown in Fig. 1. Both patients were young males without significant medical history, and presented 2–3 days after receiving the second vaccine dose. No patient had a history of prior or current COVID-19 infection, and all had negative RT-PCR nasopharyngeal swab testing for COVID-19 during their hospital course. With prompt recognition and treatment, all patients recovered quickly and were discharged from the hospital. The second patient followed up at 3 months after discharge and was completely asymptomatic without any other side effects.

This case series contributes to a limited body of literature describing acute myocardial and/or pericardial inflammatory illness occurring in close temporal association with the receipt of a mRNA COVID-19 vaccine. The possibility of a connection between COVID-19 vaccination and cardiac inflammatory illness was first suggested by a preliminary report from the the Israeli Health Ministry [3] which described a small number of cases of myopericarditis among young adults after receiving the BNT162b2 vaccine. Subsequently, 3 other case reports [4–6] and 3 case

series [7–9] reporting myocarditis following COVID-19 vaccination have been published. Consistent with those recent reports, in our series all affected patients were males, and their illness was characterized by an uncomplicated hospital course and uneventful recovery with conventional treatment for myopericarditis.

In the published randomized clinical trials of these two COVID-19 mRNA vaccines, cardiovascular adverse events were exceedingly rare. Those that were reported included paroxysmal ventricular arrhythmias, arteriosclerosis and cardiac arrest, but there were no occurrences of myocarditis or pericarditis [1,2]. Myopericarditis has been reported in association with other vaccines, and the temporal relationship between the onset of symptoms and administration of the vaccine in our patients would suggest a possible causal association. Although mechanisms such as molecular mimicry between the viral spike protein and a cardiac protein or alternatively aberrant activation of the innate and acquired immune system leading to a non-specific inflammatory response have been suggested these potential mechanisms remain speculative.

It is important to consider these case reports within the broader context of the COVID-19 pandemic and the worldwide vaccination effort. COVID-19 has caused tremendous morbidity and mortality throughout the world, and the rapid development of safe and effective vaccines has provided hope that the pandemic can eventually be brought under control. Out of the more than 142 million Americans that have been vaccinated, fewer than 1000 cases of potential vaccine-associated myocarditis or pericarditis have been reported to Vaccine Adverse Event Reporting System (VAERS). An investigation by the US Centers for Disease Control (CDC) and their Advisory Committee on Immunization Practices (ACIP) is ongoing [10]. Even if a causal relationship between mRNA COVID-19 vaccination and myopericarditis is established, the incidence appears to be extremely low, the outcomes seem to be favorable, and the benefit of vaccination far outweighs any potential

* Corresponding author at: Department of Cardiology, Westchester Medical Center and New York Medical College, 100 Woods Road, Macy Pavilion, Room 100, Valhalla, NY 10595, United States.

E-mail address: Risheek.Kaul@WMCHHealth.org (R. Kaul).

<https://doi.org/10.1016/j.ijcha.2021.100872>

Received 16 August 2021; Received in revised form 6 September 2021; Accepted 8 September 2021

Available online 20 September 2021

2352-9067/© 2021 Published by Elsevier B.V. This is an open access article under the CC BY-NC-ND license (<http://creativecommons.org/licenses/by-nc-nd/4.0/>).

Table 1
Patient clinical characteristics, in-hospital events and outcomes.

	Patient 1	Patient 2
Age (years)	28	21
Sex	Male	Male
Ethnicity	Caucasian	Caucasian
Vaccine/Dose	mRNA-1273 (Moderna, Inc)/2nd dose	BNT162b2 (Pfizer, Inc)/2nd dose
Time from vaccine administration to hospital presentation	3 days	2 days
Presenting complaint	Chest pain	Substernal chest pain
Other symptoms	Fever, headache, neck pain, myalgia	Fever, chills, headache
Medical history	None	None
Vitals on presentation	T: 98.6F HR: 75 beats/min BP:118/60 mmHg O2 sat: 98% on room air	T: 98.9F HR: 83 beats/min BP: 131/83 mmHg O2 sat: 96% on room air
Physical examination	Unremarkable	Unremarkable
Electrocardiogram	Infero-lateral ST elevation with no reciprocal changes	Diffuse ST elevation
Peak troponin I (ng/mL)	7.75	17.0
Other pertinent labs	ESR: 15 mm/hr CRP: 6 mg/dL	ESR: 20 mm/hr CRP: 3.8 mg/dL D-dimer: 509 ng/mL RF: <10 ANA: 1:80
Coronary angiogram	Normal	Not performed
Initial echocardiogram	LVEF 55%, mid inferolateral wall hypokinesis, normal RV systolic function, no pericardial effusion	LVEF 25%, mildly dilated RV and reduced systolic function, moderate mitral regurgitation, no pericardial effusion
Repeat echocardiogram	LVEF 55–60%, normal wall motion, normal RV systolic function, no pericardial effusion	LVEF 50–55%, normal wall motion. RV mildly dilated with mildly reduced function, mild mitral regurgitation
Cardiac MRI Performed	Yes	Yes
SARS-CoV-2 RT PCR	Negative	Negative
SARS-CoV-2 IgG antibody	Negative	Not performed
Other tests	Respiratory multiplex negative, Coxsackie virus serology negative	Respiratory multiplex negative
Other clinical events	None	Brief episode of supraventricular tachycardia
Treatment	Conservative care	Solunomedrol 1000 mg once daily for 3 days, colchicine 0.6 mg twice daily, losartan 25 mg daily and metoprolol succinate 25 mg daily
Length of stay	3 days	3 days
Clinical condition at the time of discharge	Asymptomatic	Asymptomatic

Abbreviations: ANA: anti-nuclear antibody, CRP: C-reactive protein, ESR: erythrocyte sedimentation rate, LVEF: Left ventricular ejection fraction, MRI: magnetic resonance imaging, RF – rheumatoid factor, RV: right ventricle, RT-PCR: reverse transcriptase-polymerase chain reaction.

Normal laboratory range: BUN - < 20 mg/dL; CRP - <1.0 mg/dL; D-dimer - < 500 ng/mL; ESR - 0–15 mm/hr; Troponin - < 0.03 ng/mL.

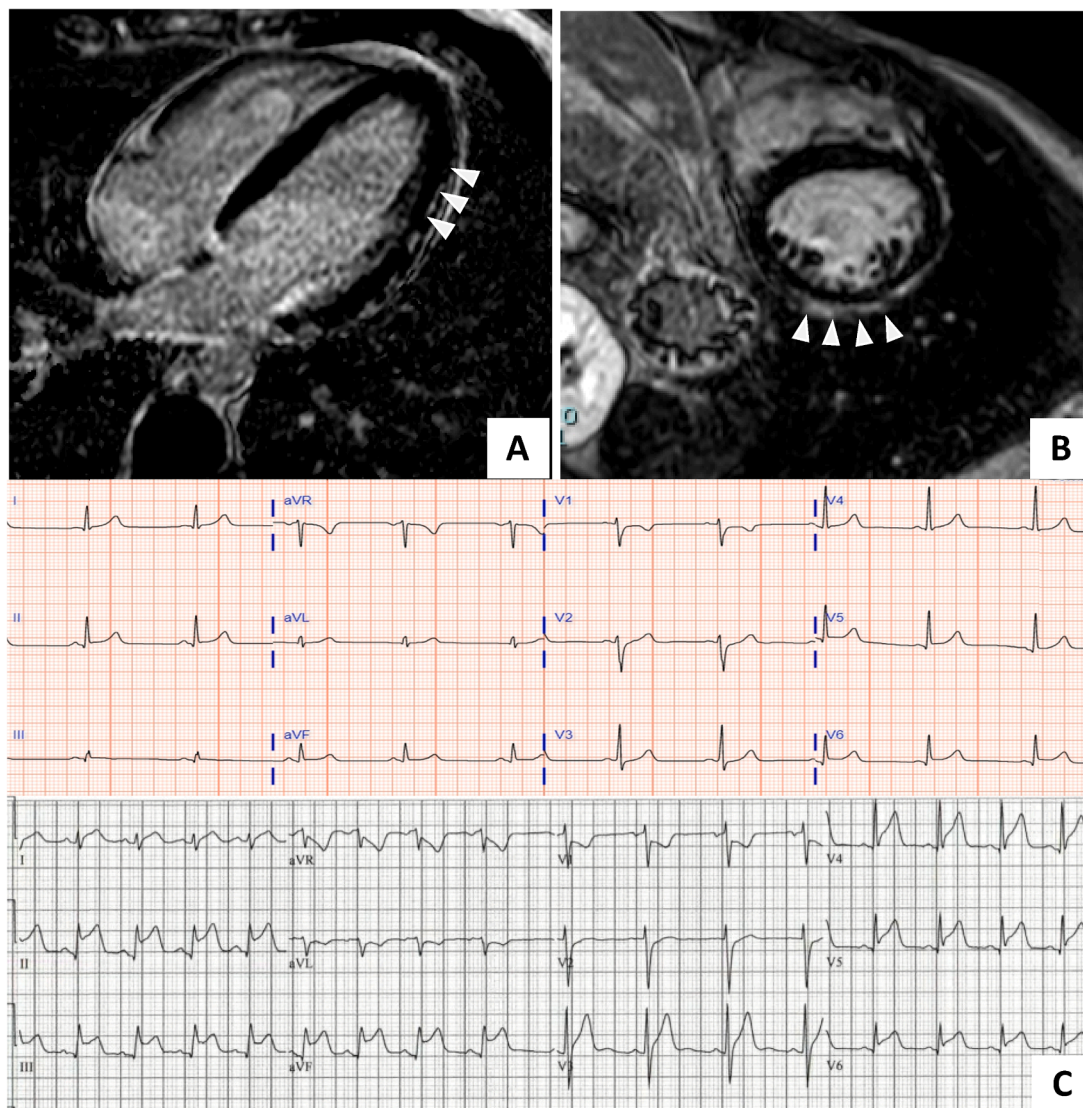


Fig. 1. Cardiac magnetic resonance (CMR) images and electrocardiograms at the time of diagnosis. *Panel A and B:* CMR image from Patient 1 and 2 respectively showing delayed hyperenhancement in the lateral epicardium (A, arrowheads) and in the pericardium and epicardial surface of the anterior and lateral wall (B, arrowheads) consistent with myocarditis by the Lake Louise criteria. *Panel C* shows electrocardiogram from patient 1 (top) showing diffuse ST segment elevation and patient 2 (bottom) showing sinus rhythm with marked sinus arrhythmia and diffuse ST segment elevation (II, III, aVF, V5 and V6) and ST segment depressions in aVR and V1. CMR – cardiac magnetic resonance imaging.

risk.

We report 2 cases of myocarditis occurring in close temporal relation to receipt of an mRNA COVID-19 vaccine. Clinicians should be alert to the possibility of myocarditis in patients presenting with compatible symptoms after vaccination, and appropriate diagnostic and therapeutic steps should be undertaken. Further basic and epidemiologic research is required to determine if a causal relationship exists and, if so, to elucidate the immunological basis of this aberrant inflammatory response.

Declaration of Competing Interest

The authors declare that they have no known competing financial interests or personal relationships that could have appeared to influence the work reported in this paper.

Acknowledgements

None.

References

- [1] F.P. Polack, S.J. Thomas, N. Kitchin, J. Absalon, A. Gurtman, S. Lockhart, J. L. Perez, G. Pérez Marc, E.D. Moreira, C. Zerbini, R. Bailey, K.A. Swanson, S. Roychoudhury, K. Koury, P. Li, W.V. Kalina, D. Cooper, R.W. Frenck, L. L. Hammitt, Ö. Türeci, H. Nell, A. Schaefer, S. Ünal, D.B. Tresnan, S. Mather, P. R. Dormitzer, U. Şahin, K.U. Jansen, W.C. Gruber, Safety and Efficacy of the BNT162b2 mRNA Covid-19 Vaccine, *N. Engl. J. Med.* 383 (27) (2020) 2603–2615, <https://doi.org/10.1056/NEJMoa2034577>.
- [2] L.R. Baden, H.M. El Sahly, B. Essink, K. Kotloff, S. Frey, R. Novak, D. Diemert, S. A. Spector, N. Rouphael, C.B. Creech, J. McGittigan, S. Khetan, N. Segall, J. Solis, A. Broz, C. Fierro, H. Schwartz, K. Neuzil, L. Corey, P. Gilbert, H. Janes, D. Follmann, M. Marovich, J. Mascola, L. Polakowski, J. Ledgerwood, B.S. Graham, H. Bennett, R. Pajon, C. Knightly, B. Leav, W. Deng, H. Zhou, S. Han, M. Ivarsson, J. Miller, T. Zaks, Efficacy and Safety of the mRNA-1273 SARS-CoV-2 Vaccine, *N. Engl. J. Med.* 384 (5) (2021) 403–416, <https://doi.org/10.1056/NEJMoa2035389>.
- [3] Israel examining heart inflammation cases in people who received Pfizer COVID shot | Reuters, n.d. <https://www.reuters.com/world/middle-east/israel-examining-heart-inflammation-cases-people-who-received-pfizer-covid-shot-2021-04-25/> (accessed May 26, 2021).
- [4] J. Bautista García, P. Peña Ortega, J.A. Bonilla Fernández, A. Cárdenes León, L. Ramírez Burgos, E. Caballero Dorta, Miocarditis aguda tras administración de vacuna BNT162b2 contra la COVID-19, *Rev. Española Cardiol.* 74 (9) (2021) 812–814, <https://doi.org/10.1016/j.recesp.2021.03.009>.

- [5] A. Muthukumar, M. Narasimhan, Q.-Z. Li, L. Mahimainathan, I. Hitto, F. Fuda, K. Batra, X. Jiang, C. Zhu, J. Schoggins, J.B. Cutrell, C.L. Croft, A. Khera, M. H. Drazner, J.L. Grodin, B.M. Greenberg, P.P.A. Mammen, S.J. Morrison, J.A. de Lemos, In Depth Evaluation of a Case of Presumed Myocarditis Following the Second Dose of COVID-19 mRNA Vaccine, *Circulation*. (2021), <https://doi.org/10.1161/CIRCULATIONAHA.121.056038>.
- [6] E. Albert, G. Aurigemma, J. Saucedo, D.S. Gerson, Myocarditis following COVID-19 vaccination, *Radiol. Case Rep.* 16 (8) (2021) 2142–2145, <https://doi.org/10.1016/j.radcr.2021.05.033>.
- [7] K.F. Larson, E. Ammirati, E.D. Adler, L.T. Cooper, K.N. Hong, G. Saponara, D. Couri, A. Cereda, A. Procopio, C. Cavalotti, F. Oliva, T. Sanna, V.A. Ciconte, G. Onyango, D.R. Holmes, D.D. Borgeson, Myocarditis after BNT162b2 and mRNA-1273 Vaccination, *Circulation*. 144 (6) (2021) 506–508, <https://doi.org/10.1161/CIRCULATIONAHA.121.055913>.
- [8] C.M. Rosner, L. Genovese, B.N. Tehrani, M. Atkins, H. Bakhshi, S. Chaudhri, A. A. Damluji, J.A. de Lemos, S.S. Desai, A. Emaminia, M.C. Flanagan, A. Khera, A. Maghsoudi, G. Mekonnen, A. Muthukumar, I.M. Saeed, M.W. Sherwood, S. S. Sinha, C.M. O'Connor, C.R. deFilippi, Myocarditis Temporally Associated with COVID-19 Vaccination, *Circulation*. 144 (6) (2021) 502–505, <https://doi.org/10.1161/CIRCULATIONAHA.121.055891>.
- [9] E. Ammirati, C. Cavalotti, A. Milazzo, P. Pedrotti, F. Soriano, J.W. Schroeder, N. Morici, C. Giannattasio, M. Frigerio, M. Metra, P.G. Camici, F. Oliva, Temporal relation between second dose BNT162b2 mRNA Covid-19 vaccine and cardiac involvement in a patient with previous SARS-COV-2 infection, *Int. J. Cardiol. Heart Vasc.* 34 (2021) 100774, <https://doi.org/10.1016/j.ijcha.2021.100774>.
- [10] CDC investigating rare myocarditis in teens, young adults; COVID-19 vaccine still advised for all who are eligible | American Heart Association, n.d. <https://newsroom.heart.org/news/cdc-investigating-rare-myocarditis-in-teens-young-adults-covid-19-vaccine-still-advised-for-all-who-are-eligible> (accessed June 18, 2021).