



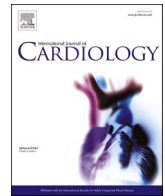
Since January 2020 Elsevier has created a COVID-19 resource centre with free information in English and Mandarin on the novel coronavirus COVID-19. The COVID-19 resource centre is hosted on Elsevier Connect, the company's public news and information website.

Elsevier hereby grants permission to make all its COVID-19-related research that is available on the COVID-19 resource centre - including this research content - immediately available in PubMed Central and other publicly funded repositories, such as the WHO COVID database with rights for unrestricted research re-use and analyses in any form or by any means with acknowledgement of the original source. These permissions are granted for free by Elsevier for as long as the COVID-19 resource centre remains active.



Contents lists available at ScienceDirect

International Journal of Cardiology

journal homepage: www.elsevier.com/locate/ijcard

Editorial

Severe COVID-19 vaccine associated myocarditis: Zebra or unicorn?



Despite having multiple widely availability, efficacious, and safe coronavirus disease 2019 (COVID-19) vaccines, vaccination campaigns have been challenged by unanticipated, rare adverse events. Beyond the common peri-inoculation fatigue, fevers, and myalgias observed in the clinical trials, vaccine associated myocarditis has emerged as an exceedingly rare adverse event appreciated during post-marketing surveillance through the Centers for Disease Control (CDC) [1–4]. Several COVID-19 vaccines, including the BNT162b2 mRNA, mRNA-1273, and Ad26.COV2-S vaccines, have utilized the SARS-CoV-2 spike protein to induce antigen-specific CD8+ and Th1-type CD4+ T-cell responses to create robust adaptive immunity [1–3]. The SARS-CoV-2 spike (S) proteins bind to angiotensin-converting enzyme 2 (ACE2) expressed on host cells and in combination with host transmembrane serine protease 2 (TMPRSS2) may lead to cell entry and viral infection [5]. The utilization of the SARS-CoV-2 spike protein to produce immunity led to concern about the potential to induce vaccine-associated myocarditis as cardiomyocytes express ACE2. Despite the clear safety and efficacy of the COVID-19 vaccines approved for use within the United States, it remained possible that exceptionally rare adverse events may be appreciated within the United States Vaccine Adverse Event Reporting System (VAERS) after inoculation to tens of millions of individuals [1–3].

Although VAERS is subject to bias, a clear signal for vaccine associated myocarditis has emerged with nearly 1300 cases reported from more than 350 million doses in the United States [4]. Thus far, most cases have been reported in young men (median age 24 years), and nearly 2/3 of cases were reported after the second dose with a median onset of symptoms approximately three days after vaccination [4]. For 18–24 year-old males, this translates to an expected prevalence of vaccine associated myocarditis that is approximately 3 cases per 100,000 doses (0.003%) based on VAERS data [4]. Further observational data has replicated these findings with an overall prevalence of COVID-19 vaccine associated myocarditis at ~3 per 100,000 patients (0.003%) versus ~11 per 100,000 patients (0.01%) for acute COVID-19 myocarditis [6]. Despite very low rates, the prevalence exceeded the expected background rate of myocarditis resulting in the United States Food and Drug Administration adding a warning label to both the BNT162b2, and mRNA-1273 about the potential risk for myocarditis [4]. Fortunately, most case reports describing COVID-19 vaccine associated myocarditis have described a mild-to-moderate severity illness treated with supportive care, steroids, and/or non-steroidal anti-inflammatory drugs [4]. The reported prognosis for these patients appears to be good despite isolated cases with left ventricular systolic dysfunction [4].

The two cases reported herein reported in this issue of IJC illustrate the remote possibility that COVID-19 vaccination may also be associated

with a more fulminant post-vaccination myocarditis than previously reported [7]. Notably, the cases do not provide a clear cause and effect relationship, but these cases are important to consider for a several key reasons. First, both cases are presumed to be fulminant myocarditis as they did not meet contemporary diagnosis either by endomyocardial biopsy or cardiac MRI findings. However, the clinical descriptions are consistent with myocarditis and illustrate the challenge of a securing a formal diagnosis with a rapidly progressive fulminant presentation. Second, both cases are markedly different from the majority of peer-reviewed vaccine associated cases of myocarditis which typically follow a relatively benign clinical course. In fact, both cases share striking similarities with the Multisystem Inflammatory Syndrome in Adults (MIS-A) that is often described as an acute fulminant presentations of COVID-19 defined by myocarditis with immune dysregulation [8]. Although the extent of cytokine dysregulation is confounded by acute liver failure in both patients, immune dysregulation remained a key component. This raises the question if these two cases represent a different disease process, as opposed to an unusually severe outcome that differs substantially from what has been described to be a generally self-limited adverse event.

Similar to Multisystem Inflammatory Syndrome in Children (MIS-C), the authors elected to treat with a combination of high dose steroids and IVIG [5]. Currently there is limited high-quality evidence available to guide treatment therapies in MIS-A; however, observational data from MIS-C has supported the use of intravenous steroids and intravenous immunoglobulin (IVIG) [9]. Due to elevated inflammatory markers the authors elected to use tocilizumab (an interleukin-6 receptor blocker), which has been used in a few case reports and small case series for patients with refractory viral and immune check-point inhibitor myocarditis, but higher quality data in myocarditis is lacking. For patients hospitalized with severe COVID-19 use of tocilizumab is controversial. A randomized trial comparing tocilizumab to placebo did not improve clinical status or mortality at 28 days; however, other trials has suggested modest benefits [10]. Therefore, the clinical benefits or harm of tocilizumab or various interleukin antagonists in acute COVID-19 myocarditis or vaccine associated myocarditis is uncertain.

Lastly, the pathogenesis of COVID-19 vaccine associated myocarditis is poorly understood and further research is needed. Endomyocardial biopsies obtained in patients with clinical COVID-19 myocarditis have observed a lymphocytic infiltrate consistent with lymphocytic myocarditis. Due to the generally mild-to-moderate clinical disease with COVID-19 vaccine associated myocarditis, endomyocardial biopsies have rarely been undertaken. If COVID-19 vaccine associated myocarditis results in a lymphocytic myocarditis (typical of acute viral myocarditis) or a hypersensitivity myocarditis, is unknown. Future

<https://doi.org/10.1016/j.ijcard.2021.09.036>

Received 2 September 2021; Accepted 17 September 2021

Available online 21 September 2021

0167-5273/© 2021 Elsevier B.V. All rights reserved.

investigations into myocarditis and vaccine associated myocarditis will require leveraging more detailed phenotyping with systematic genetics, proteomics, cardiac imaging, and biomarkers to advance our understanding of the pathology this syndrome. Although clinically rare, multicenter clinical trials for fulminant lymphocytic myocarditis will need to be established to further advance efficacious therapies. Without further structured investigation, we will continue to haphazardly apply anecdotal therapies to patients without an adequate understanding of therapeutic efficacy.

In conclusion, although they lack evidence for causality, both cases may represent the most severe spectrum of an exceptionally rare adverse event associated with vaccination. Although these two unusually severe cases deviate from reported estimates of self-limited vaccine associated myocarditis, they do serve as a reminder of continued vigilance for exceedingly rare events that may associated with any novel therapy. Importantly, these reports should not dampen the enthusiasm for safe and highly efficacious COVID-19 vaccines which provide the best pathway to mitigating morbidity and mortality from SARS-CoV-2 infection.

Funding

JLG reports research funding from the Texas Health Resources Clinical Scholarship.

Disclosures

NSH and SC report no relevant conflicts of interest or disclosures. JLG reports consulting fees from Pfizer, Eidos, and Alnylam.

Acknowledgements

None.

Appendix A. Supplementary data

Supplementary data to this article can be found online at <https://doi.org/10.1016/j.ijcard.2021.09.036>.

[org/10.1016/j.ijcard.2021.09.036](https://doi.org/10.1016/j.ijcard.2021.09.036).

References

- [1] F.P. Polack, S.J. Thomas, N. Kitchin, J. Absalon, A. Gurtman, S. Lockhart, et al., Safety and efficacy of the BNT162b2 mRNA Covid-19 vaccine, *N. Engl. J. Med.* 383 (27) (2020) 2603–2615.
- [2] L.R. Baden, H.M. El Sahly, B. Essink, K. Kotloff, S. Frey, R. Novak, et al., Efficacy and safety of the mRNA-1273 SARS-CoV-2 vaccine, *N. Engl. J. Med.* 384 (5) (2021) 403–416.
- [3] J. Sadoff, G. Gray, A. Vandebosch, V. Cardenas, G. Shukarev, B. Grinsztejn, et al., Safety and efficacy of single-dose Ad26.COV2.S vaccine against Covid-19, *N. Engl. J. Med.* 384 (23) (2021) 2187–2201.
- [4] B. Bozkurt, I. Kamat, P.J. Hotez, Myocarditis with COVID-19 mRNA vaccines, *Circulation.* 144 (6) (2021) 471–484.
- [5] N.S. Hendren, M.H. Drazner, B. Bozkurt, L.T. Cooper Jr., Description and proposed management of the acute COVID-19 cardiovascular syndrome, *Circulation.* 141 (23) (2020) 1903–1914.
- [6] N. Dagan, N. Barda, E. Kepten, O. Miron, S. Perchik, M.A. Katz, et al., BNT162b2 mRNA Covid-19 vaccine in a nationwide mass vaccination setting, *N. Engl. J. Med.* 384 (15) (2021) 1412–1423.
- [7] Antonio Abbate, Nima Madanchi, Christin Kim, Pranav R. Shah, Katherine Klein, Julie Boatman, Charlotte Roberts, Seema Patel Stamatina Danielides, Fulminant myocarditis and systemic hyperinflammation temporally associated with BNT162b2 mRNA COVID-19 vaccination in two patients, *Int. J. Cardiol.* (2021).
- [8] Z.M. Most, N. Hendren, M.H. Drazner, T.M. Perl, The striking similarities of multisystem inflammatory syndrome in children and a myocarditis-like syndrome in adults: overlapping manifestations of COVID-19, *Circulation.* 143 (2021) 4–6.
- [9] M.B.F. Son, N. Murray, K. Friedman, C.C. Young, M.M. Newhams, L.R. Feldstein, et al., Multisystem inflammatory syndrome in children - initial therapy and outcomes, *N. Engl. J. Med.* 385 (1) (2021) 23–34.
- [10] I.O. Rosas, N. Brau, M. Waters, R.C. Go, B.D. Hunter, S. Bhagani, et al., Tocilizumab in hospitalized patients with severe Covid-19 pneumonia, *N. Engl. J. Med.* 384 (16) (2021) 1503–1516.

Nicholas S. Hendren^{a,b}, Spencer Carter^{a,b}, Justin L. Grodin^{a,b,*}

^a Division of Cardiology, Department of Internal Medicine, University of Texas Southwestern Medical Center, Dallas, TX, USA

^b Parkland Health and Hospital System, Dallas, TX, USA

* Corresponding author at: 5323 Harry Hines Blvd. Ste. E5.310F, Dallas, TX 75390–8830, USA.

E-mail address: Justin.Grodin@utsouthwestern.edu (J.L. Grodin).