



CLINICAL REPORT

Variants of *ATPIA3* in residue 756 cause a separate phenotype of relapsing encephalopathy with cerebellar ataxia (RECA)—Report of two cases and literature review

Mateusz Biela¹  | Malgorzata Rydzanicz²  | Krystyna Szymanska³ |
Karolina Pieniawska-Smiech⁴ | Aleksandra Lewandowicz-Uszynska⁵ |
Joanna Chruszcz⁶ | Lucyna Benben⁷ | Malgorzata Kuzior-Plawiak⁷ | Pawel Szyld⁸ |
Aleksandra Jakubiak¹ | Leszek Szenborn⁶  | Rafal Ploski²  | Robert Smigiel¹ 

¹Department of Pediatrics, Division Pediatric Propedeutics and Rare Disorders, Wrocław Medical University, Wrocław, Poland

²Department of Medical Genetics, Medical University of Warsaw, Warsaw, Poland

³Department of Experimental and Clinical Neuropathology, Mossakowski Medical Research Centre, Polish Academy of Sciences, Warsaw, Poland

⁴Department of Clinical Immunology, Wrocław Medical University, Wrocław, Poland

⁵Third Department and Clinic of Pediatrics, Immunology and Rheumatology of Developmental Age, Wrocław Medical University, Wrocław, Poland

⁶Department of Paediatrics and Infectious Diseases, Wrocław Medical University, Wrocław, Poland

⁷Department of Paediatric Neurology, J. Gromkowski Regional Specialist Hospital, Wrocław, Poland

⁸Cancer Genetics Unit Cancer Prevention Department, The Maria Skłodowska-Curie National Research Institute of Oncology, Warsaw, Poland

Correspondence

Mateusz Biela and Robert Smigiel,
Department of Pediatrics, Division
Pediatric Propedeutics and Rare
Disorders, Wrocław Medical University,
Wybrzeże L. Pasteura 1, 50-367 Wrocław,
Poland.
Email: mateuszbiela14@gmail.com (M.
B.) and robert.smigiel@umed.wroc.pl
(R. S.)

Funding information

Ministerstwo Nauki i Szkolnictwa
Wyższego, Grant/Award Number: 016/
RID/2018/19

Abstract

Background: Variants in *ATPIA3* cause well-known phenotypes—alternating hemiplegia of childhood (AHC), rapid-onset dystonia-parkinsonism (RDP), cerebellar ataxia, areflexia, pes cavus, optic atrophy, sensorineural hearing loss (CAPOS), and severe early infantile epileptic encephalopathy. Recently, there has been growing evidence for genotype–phenotype correlations in the *ATPIA3* variants, and a separate phenotype associated with variants in residue 756—two acronyms are proposed for the moment—FIPWE (fever-induced paroxysmal weakness and encephalopathy) and RECA (relapsing encephalopathy with cerebellar ataxia).

Materials and Methods: Herein, we are describing two new pediatric cases with a p.Arg756His change in the *ATPIA3* gene. Both patients have had more than one episode of a neurological decompensation triggered by fever with severe hypotonia and followed by ataxia. Thirty-three cases from literature were analyzed to define and strengthen the genotype–phenotype correlation of variants located in residue 756 (p.Arg756His, p.Arg756Cys, p.Arg756Leu).

Conclusions: Patients with a *ATPIA3* variant in residue 756 are characterized by recurrent paroxysmal episodes of neurological decompensations triggered by fever,

Mateusz Biela and Malgorzata Rydzanicz have equal contribution.

This is an open access article under the terms of the Creative Commons Attribution-NonCommercial License, which permits use, distribution and reproduction in any medium, provided the original work is properly cited and is not used for commercial purposes.

© 2021 The Authors. *Molecular Genetics & Genomic Medicine* published by Wiley Periodicals LLC.

with severe hypotonia, ataxia, dysarthria, symptoms from the orofacial area (dysphagia, drooling) as well as with altered consciousness. Recovery is slow and usually not full with the persistent symptoms of cerebellar ataxia, dysarthria, dystonic and choreiform movements.

KEYWORDS

ATPIA3, cerebellar ataxia, hypotonia, relapsing encephalopathy, whole-exome sequencing

1 | INTRODUCTION

The alpha-3-subunit of the Na⁺/K⁺-ATPase pump which is responsible for the transport of three molecules of Na⁺ out and two molecules of K⁺ into the cell is encoded by *ATPIA3* (OMIM: *182350). The localization of ATP1a3 is restricted to neurons, especially to GABAergic neurons in all nuclei of the basal ganglia (striatum, globus pallidus, subthalamic nucleus, and substantia nigra), which is a key circuitry in the fine movement control (Böttger et al., 2011).

Heterozygous variants in the *ATPIA3* gene cause well-known phenotypes: alternating hemiplegia of childhood (AHC, OMIM: #614820), rapid-onset dystonia-parkinsonism (RDP, OMIM: #128235), cerebellar ataxia, areflexia, pes cavus, optic atrophy, sensorineural hearing loss (CAPOS, OMIM: #601338), and severe early infantile epileptic encephalopathy (Paciorkowski et al., 2015; Sweney et al., 2015).

Aside from the phenotypes mentioned above, in literature there has appeared evidence for overlap phenotypes, reported as “atypical AHS” or “atypical RDP”. Recently, there has been growing evidence for genotype–phenotype correlations between *ATPIA3* variants in residue 756 and a separate phenotype(s)—two acronyms are proposed for the moment—FIPWE (fever-induced paroxysmal weakness and encephalopathy) and RECA (relapsing encephalopathy with cerebellar ataxia) (Dard et al., 2015; Sabouraud et al., 2019; Yano et al., 2017).

In this paper, we are reporting two unrelated individuals with de novo c.2267G>A (p. Arg756His) change in *ATPIA3* and we are summarizing cases available in literature with *ATPIA3* variants in residue 756.

2 | MATERIAL AND METHODS

2.1 | Ethical compliance

This study was approved by Wroclaw Medical University Ethics Committee. The parents gave written informed consent for sampling, genetic testing, and clinical examination.

2.2 | Patient 1

The proband is a 3-year and 6-month-old boy, the only child of healthy non-consanguineous parents. He was born at 40 weeks of gestation, weighing 3360 g. From birth, mild hypotonia was observed, gross motor development was slightly delayed. At 19 months of age after 2 weeks of a viral infection with subtly elevated body's temperature (38°C), the acute neurological symptoms developed such as lethargy, diminished contact, and severe hypotonia. During hospitalization, brain MRI and cerebrospinal fluid analysis were performed showing no abnormalities. The patient maintained recumbent position, hyperaphia, generalized hypotonia, and lack of visual contact were observed, as well as convergent strabismus, nuchal rigidity, constricted pupils with weak response to brightness. Viral encephalitis was suspected. In the course of hospitalization, oseltamivir was initiated due to a positive test for AH1N1. After recovery generalized hypotonia, mild axial ataxia, and joint hypermobility were observed without other neurological abnormalities. The child presented very good cognitive development.

Seven months from the first episode, at 2 years 2 months of age he had experienced a second acute neurological decompensation after 1 day of a febrile infection (38.7°C)—severe hypotonia with areflexia, dysarthria, ataxia, involuntary movements of facial muscles in the lower part of the face, and convergent strabismus. He was admitted to a neurological department. Changes of consciousness were not detected. CT of the brain did not reveal abnormalities, and cerebrospinal fluid analysis was normal. MRI demonstrated maxillary sinusitis only. Electromyography did not reveal explanation of depressed deep tendon reflexes. Metabolic investigations were normal (plasma ammonia, plasma and CSF lactate and pyruvate). Inflammatory neuropathy was originally suspected, but intravenous immunoglobulin therapy was not beneficial. After the acute episode the child was not able to sit unassisted and walk. Generalized hypotonia with weak head stabilization, generalized ataxia, scanning speech, and periodic esotropia were observed. After 3 months of rehabilitation, the boy started to walk again.

At the last follow-up at age of 3 years, alternating convergent strabismus, general ataxia (distinct axial ataxia), and hypotonia were observed. Deep tendon reflexes, in upper

extremities were significantly weak, in lower absent, plantar reflex both side present. Ophthalmological and audiological examination were normal. Mental development was compatible with age.

2.3 | Patient 2

A 4-year-old girl, the second child of healthy non-consanguineous parents was born at term by normal delivery with good condition and weight 3030 g. Psychomotor development was normal. At 15 months of age during a viral pneumonia (39°C), the acute neurological symptoms developed with lethargy, loss of consciousness, stereotypic movements of mouth, and hypotonia. The child was admitted to a neurology ward with suspicion of meningitis. Brain MRI and CSF analysis as well as metabolic screening tests were normal. The child was treated with antibiotics, acyclovir and dexamethasone.

After the episode the girl did not fully recover. There were two more similar episodes at the of age 19 months and of 3 years with lethargy, hypotonia, dysphagia, and dysarthria. Both were caused by a febrile infection (viral bronchitis and urinary tract infection) with high fever (to 40°C). Brain MRI each time was normal.

At the age of 4 years hypotonia, ataxia, with unstable gait, and dysarthria were observed. Deep tendon reflexes in upper extremities were significantly weak, in lower absent, plantar reflex both side present. Cognitive development was normal.

2.4 | Molecular study

Whole exome sequencing (WES) was performed in both probands using *Nextera Flex for Enrichment* sample preparation kit (Illumina) for Patient 1, and Human Core Exome Kit (Twist Bioscience) for Patient 2. Enriched libraries were paired-end sequenced (2 × 100 bp) on HiSeq 1500 (Illumina), and analyzed as previously described (Śmigiel et al., 2020). In brief, variants passing a default quality were further filtered to include only those with <1% minor allele frequency in all tested databases (including gnomAD, Bravo, and in-house database of >4000 Polish exomes), and to exclude deep intronic variants and synonymous variants. The final list of variants were screened against known pathogenic mutations listed in ClinVar and HGMD databases, and then searched for biallelic mutations consistent with autosomal recessive inheritance and monoallelic variants potentially causative of an autosomal dominant. All prioritized variants were manually inspected with Integrative Genomics Viewer.

Family study was performed by amplicon deep sequencing (ADS) using Nextera XT Kit (Illumina) for Patient 1 and by direct Sanger sequencing for Patient 2.

In both probands, known pathogenic heterozygous variant in the *ATPIA3* gene was detected (hg38, chr19:g.41970539-C>T, NM_152296.5:c.2267G>A, NP_001243143.1:p.Arg769His). The p.Arg756His was absent in probands' parents and Patient 2 older sister suggesting de novo event (Figure 1).

2.5 | Methods of data collection from literature

PubMed was used for literature search, first were used keywords "ATPIA3 AND Fever OR Encephalopathy," followed by the single term "ATPIA3," to identify all cases of patients with a *ATPIA3* mutation in residue 756 (mandatory inclusion criterion). A publication year filter was applied: 2012–2021, because the mutation was discovered for the first time in 2012 (Brashear et al., 2012). If the abstracts mentioned patients with encephalopathy, atypical RDP/AHC, fever as a trigger or mentioned about *ATPIA3* mutations in p.Arg756 the full texts were analyzed. Only cases with a full description of symptoms in English were included in the genotype-phenotype analysis (Figure A1).

3 | DISCUSSION

To date, 57 cases with changes at residue 756 in the *ATPIA3* gene have been reported, including 34 cases with c.2267G>A (p.Arg756His), 20 cases with c.2266C>T (p.Arg756Cys), and 3 cases with c.2267G>T (p.Arg756Leu) (Brashear et al., 2012; Dard et al., 2015; Fornarino et al., 2014; de Gusmao et al., 2016; Hully et al., 2017; Jaffer et al., 2017; Kanemasa et al., 2016; Nakamura et al., 2018; Sabouraud et al., 2019; Schirinzi et al., 2018; Sival et al., 2018; Sousa et al., 2017; Stagnaro et al., 2018; Tan et al., 2014; Yano et al., 2017). Some cases were described as intermediate or atypical phenotypes (Brashear et al., 2012; Hully et al., 2017). RECA and FIPWE were suggested as acronyms of the phenotype associated with variants at p.Arg756 (Dard et al., 2015; Sabouraud et al., 2019; Yano et al., 2017). Based on the study of our cases and the 33 cases discussed in literature (inclusion and exclusion criteria shown in appendices 1), we have described and defined the phenotype which is distinct from the AHC, RDP, and CAPOS phenotypes (Table 1) (Brashear et al., 2012; Dard et al., 2015; Fornarino et al., 2014; de Gusmao et al., 2016; Hully et al., 2017; Jaffer et al., 2017; Kanemasa et al., 2016; Nakamura et al., 2018; Sabouraud et al., 2019; Schirinzi et al., 2018; Sival et al., 2018; Sousa et al., 2017; Stagnaro et al., 2018; Sweney et al., 2015; Tan et al., 2014; Yano et al., 2017).

In presented patient 1 and nine cases described in literature psychomotor delay of varying intensity and neurological

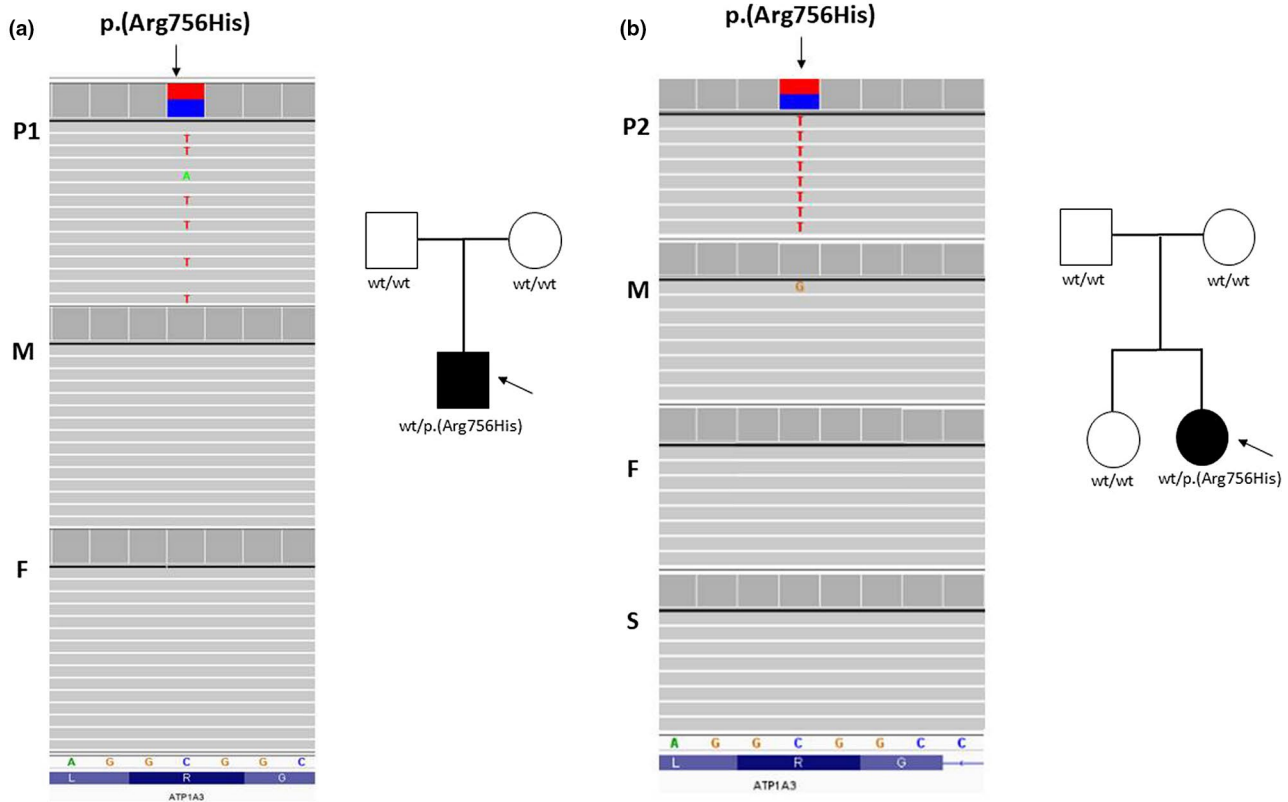


FIGURE 1 Results of molecular examination. Amplicon deep sequencing family study of *ATP1A3* p.Arg756His variant. A – Patient 1 (P1), B – Patient 2 (P2). IGV screen shot is given on the left hand side, while pedigree with genotype-phenotype information is given on right: circle represents female, square indicates male, filled symbol - affected individual. Proband is marked with black arrow. P -patient, M – mother, F – father, S – sister, wt – wild type genotype

abnormalities were present before the first decompensation (Nakamura et al., 2018; Sabouraud et al., 2019; Sival et al., 2018; Sousa et al., 2017; Stagnaro et al., 2018). The data may be inaccurate as some of the patients are adults and the assessment of their infant development is subjective.

In the analyzed group, fever was the main triggering factor of these paroxysmal episodes. One patient after two episodes of fever-triggered paroxysmal episodes as an infant has now (as a teenager) rare paroxysmal episodes, mostly triggered by tiredness (Stagnaro et al., 2018).

The age range of the first acute episodes was between 8 months and 10 years (3 cases)—the upper range is almost two times higher than previously noted by Sabouraud et al. (de Gusmao et al., 2016; Sabouraud et al., 2019; Sousa et al., 2017; Tan et al., 2014). In 19 of cases, the first episode occurred before age of 2 years. The median number of episodes was two.

The course of these episodes was comparable and included severe hypotonia (30/35), ataxia (28/35), dysarthria (26/35), dystonic movements (21/35), dysphagia, and drooling (18/35). Altered consciousness was present in 22 cases. Choreiform movements and oculomotor symptoms were present approximately in ¼ of the patients. The recovery was slow in most cases and the patients presented the following

long-term conditions: ataxia (28/35), dysarthria (19/35), hypotonia, and dystonic movements were present in more than 50%. Dysphagia has subsided in most cases. After the acute period choreiform movements occur in 15 patients which is a new finding.

In Table 1 we have summarized the clinical features of the 33 reported cases and our two cases with variants at residue 756 to compare the genotype-phenotype correlations. The paroxysmal episodes of patients with p. Arg756His and p. Arg756Cys had a significant difference in the number of cases with altered consciousness (47.4% vs. 76.9%), other symptoms are similar in prevalence (hypotonia, ataxia, dystonia, choreiform, and oculomotor symptoms). Cognitive delay symptoms after acute episodes have higher frequency in cases with p.Arg756Cys. It should be emphasized that in this group the number of patients with psychomotor delay prior to onset is lower than in patients with p.Arg756His. We suggest that this change can predispose to a worse prognosis in development.

Two patients with p.Arg756Cys (sisters) had mild atrophies, one of the vermis, and the other of the cerebellar. In the p.Arg756His group, one patient had cerebellar atrophy and one patient had hypoplasia of the anterior commissure and corpus callosum. There are only two patients (twins) with the

TABLE 1 Clinical characteristics of the current and reported in literature patients with mutations in *ATP1A3* gene (NM_152296.5 / NP_001243143.1)

	Patient 1		Patient 2		ATP1A3 mutation at residue 756			TOTAL
	p.Arg756His	p.Arg756His	p.Arg756His	p.Arg756Cys	p.Arg756Leu	2 (twins)	35	
Number of patients	20 (including current cases)		13			2 (twins)	35	
Age at onset of paroxysms - year	1.7	1.3	0.8–10.0 (2.6)	0.8–5.6 (1.6)	1.9	0.8–10.0 (1.9)	≤1.6	4.0–55.0
month (median)								0.6–5.0
Psychomotor delay (prior to onset)	1	Normal	7 (35.0%)	3 (23.1%)	0 (0.0%)	10 (28.6%)	Normal	Normal
Trigger of onset	Fever	Fever	Fever	Fever	Fever	Variable	Variable	Fever
Recurrence (median of episodes)	2	3	+ (2)	+ (2)	2	+ (2)	±	+
Paroxysmal episodes								
Altered consciousness	+	+	10 (50.0%)	10 (76.9%)	2 (100%)	22 (62.9%)	±	+
Oculomotor symptoms	+	-	5 (25.0%)	2 (15.4%)	1 (50.0%)	8 (22.9%)	±	±
Dysarthria	+	+	15 (75.0%)	11 (84.6%)	0 (0.0%)	26 (74.3%)		
Dysphagia, drooling	+	+	10 (50.0%)	6 (46.2%)	2 (100%)	18 (51.4%)	+	±
Hypotonia, weakness	+	+	17 (85.0%)	12 (92.3%)	2 (100%)	30 (85.7%)	-	+
Ataxia	+	+	16 (80.0%)	10 (76.9%)	2 (100%)	28 (80.0%)	±	+
Dystonia	-	-	12 (60.0%)	9 (69.2%)	0 (0.0%)	21 (60.0%)	±	±±
Choreiform movements	-	-	5 (25.0%)	4 (30.8%)	0 (0.0%)	9 (25.7%)	-	-
Recovery (duration)	Slow (> 1 month)		-	-			Variable (< 1 h to days)	
Long-term conditions								
Cognitive delay	-	-	6 (30.0%)	6 (46.2%)	2 (100%)	14 (40.0%)	±	±
Oculomotor symptoms	+	-	3 (15.0%)	3 (23.1%)	0 (0.0%)	6 (17.1%)	±	±
Dysarthria	+	+	10 (50.0%)	9 (69.2%)	0 (0.0%)	19 (54.3%)		
Dysphagia, drooling	-	+	3 (15.0%)	0 (0.0%)	0 (0.0%)	3 (8.6%)	+	-
Hypotonia/weakness	+	+	10 (50.0%)	6 (42.6%)	2 (100%)	18 (51.4%)	-	+
Ataxia	+	+	15 (75.0%)	11 (84.6%)	2 (100%)	28 (80.0%)	±	±

(Continues)

TABLE 1 (Continued)

Number of patients	Patient 1		Patient 2		ATPIA3 mutation at residue 756			TOTAL
	p.Arg756His	p.Arg756His	p.Arg756His	p.Arg756His	p.Arg756Cys	p.Arg756Leu	2 (twins)	
Dystonia	–	–	–	–	13	2	35	35
Choreiform movements	–	–	–	–	10 (76.9%)	0 (0.0%)	18 (51.4%)	+
Neuroimaging findings	Normal	Normal	Normal	Normal	6 (46.2%)	2 (100%)	15 (42.9%)	+
					2 cases of mild atrophies— case hypoplasia of the anterior commissure and corpus callosum (16 patients had MRI)	0 (0.0%)	4 (11.4%)	rare
Anthropometric measurements at last follow-up with centiles (weight, height, head circumference)	11.5 kg (3–10 c.), 86 cm (<3 c.), 48 cm (25 c.)	13.5 kg (3–10 c.), 100 cm (10–25 c.), 49 cm (25–50 c.)						

Abbreviations: AHC, alternating hemiplegia of childhood; CA, cerebellar atrophy; CAPOS, cerebellar ataxia, areflexia, pes cavus, optic atrophy, sensorineural hearing loss; RDP, rapid-onset dystonia-parkinsonism.

p.Arg756Leu change what we found unrepresentative and for this reason we did not analyze them separately, their symptoms are shown in Table 1.

Analyzing the information about the patients' parents in literature (not included in Table 1, see exclusion criteria, appendices 1) and the symptoms of patients described by Yano et al. the long-term course of the symptoms are mostly stable without further severe progression (Sabouraud et al., 2019; Yano et al., 2017). The main symptoms reported were cerebellar signs, ataxia, and dysarthria. Jaffer et al. and Dard et al. reported cases of patients with progressing symptoms (Dard et al., 2015; Jaffer et al., 2017). None of the mentioned patients presented symptoms typical of CAPOS such as hearing loss, optic atrophy, or pes cavus.

Dard et al. proposed the term of relapsing encephalopathy with cerebellar ataxia pointing out that the symptoms (severe hypotonia, mutism, dysarthria, nystagmus, and swallowing problems) are likely to have a cerebellar involvement. In literature, there is lack of information about the types of dysarthria in patients with *ATPIA3* variants. Our patients presented scanning speech, generalized hypotonia and ataxia—typical of cerebellar dysfunction. Abnormal movements may be due to the involvement of the basal ganglia and brain stem. Hyporeflexia and hypotonia can be caused by impairment of motoneuron activity.

In our opinion, the term RECA is more corresponding to the general phenotype presented by cases with a *ATPIA3* change at residue 756—it includes the paroxysmal episodes symptoms (recurrent encephalopathy) as well as the long-term conditions (cerebellar ataxia).

4 | CONCLUSIONS

ATPIA3 variants in residue 756 (p.Arg756His, p.Arg756Cys, p.Arg756Leu) cause a separate phenotypic entity characterized by recurrent paroxysmal episodes of neurological decompensations triggered by fever, with severe hypotonia, ataxia, dysarthria, symptoms from the orofacial area (dysphagia, drooling) as well as with altered consciousness. Recovery is slow and usually not full with the persistent symptoms of cerebellar ataxia, dysarthria, dystonic, and choreiform movements. The neurological sequels worsen after every decompression episode. Oculomotor symptoms may be present but are not so frequent as the symptoms mentioned above. There are no specific laboratory and neuroimaging findings—further brain MRI follow-ups should be considered in these patients, as cerebellar atrophy may be a late finding. No preventive treatment is available to avoid the paroxysmal episodes and exacerbation of the neurological outcome. After childhood, the disease usually does not progress.

ACKNOWLEDGMENTS

The publication was prepared under the project financed from the funds granted by the Ministry of Science and Higher Education in the Regional Initiative of Excellence program for the years 2019–2022, project number 016/RID/2018/19, the amount of funding 11,998,121.30 PLN.

CONFLICT OF INTEREST

The authors declare no conflict of interest.

AUTHOR CONTRIBUTIONS


The manuscript was designed and edited by: Mateusz Biela, Małgorzata Rydzanicz, and Robert Smigiel. The patients were analyzed and described by: Mateusz Biela, Robert Smigiel, Krystyna Szymanska, Karolina Pieniawska-Śmiech, Aleksandra Lewandowicz-Uszynska, Joanna Chruszcz, and Leszek Szenborn. The genetic analysis was done by: Małgorzata Rydzanicz, Rafał Płoski. Literature review and data analysis were done by: Mateusz Biela, Karolina Pieniawska-Śmiech, and Aleksandra Jakubiak. Content-related supervision was exercised by: Małgorzata Rydzanicz, Krystyna Szymanska, Leszek Szenborn, Rafał Płoski, and Robert Smigiel.

DATA AVAILABILITY STATEMENT

Data sharing not applicable to this article as no datasets were generated or analysed during the current study.

ORCID

Mateusz Biela  <https://orcid.org/0000-0002-3461-193X>

Małgorzata Rydzanicz  <https://orcid.org/0000-0002-6969-0535>

Leszek Szenborn  <https://orcid.org/0000-0001-6574-8229>

Rafał Płoski  <https://orcid.org/0000-0001-6286-5526>

Robert Smigiel  <https://orcid.org/0000-0003-2930-9549>

REFERENCES

- Böttger, P., Tracz, Z., Heuck, A., Nissen, P., Romero-Ramos, M., & Lykke-Hartmann, K. (2011). Distribution of Na/K-ATPase alpha 3 isoform, a sodium-potassium P-type pump associated with rapid-onset of dystonia parkinsonism (RDP) in the adult mouse brain. *The Journal of Comparative Neurology*, 519(2), 376–404. <https://doi.org/10.1002/cne.22524>
- Brashear, A., Mink, J. W., Hill, D. F., Boggs, N., McCall, W. V., Stacy, M. A., Snively, B., Light, L. S., Sweadner, K. J., Ozelius, L. J., & Morrison, L. (2012). *ATPIA3* mutations in infants: A new rapid-onset dystonia-Parkinsonism phenotype characterized by motor delay and ataxia: Case report. *Developmental Medicine & Child Neurology*, 54(11), 1065–1067. <https://doi.org/10.1111/j.1469-8749.2012.04421.x>
- Dard, R., Mignot, C., Durr, A., Lesca, G., Sanlaville, D., Roze, E., & Mochel, F. (2015). Relapsing encephalopathy with cerebellar ataxia related to an *ATPIA3* mutation. *Developmental Medicine*

- & *Child Neurology*, 57(12), 1183–1186. <https://doi.org/10.1111/dmcn.12927>
- de Gusmao, C. M., Dy, M., & Sharma, N. (2016). Beyond dystonia-parkinsonism: Chorea and ataxia with ATP1A3 mutations. *Movement Disorders Clinical Practice*, 3(4), 402–404. <https://doi.org/10.1002/mdc3.12317>
- Fornarino, S., Stagnaro, M., Rinelli, M., Tiziano, D., Mancardi, M. M., Traverso, M., Veneselli, E., & De Grandis, E. (2014). Paroxysmal features responding to flunarizine in a child with rapid-onset dystonia-parkinsonism. *Neurology*, 82(22), 2037–2038. <https://doi.org/10.1212/WNL.0000000000000473>
- Hully, M., Ropars, J., Hubert, L., Boddaert, N., Rio, M., Bernardelli, M., Desguerre, I., Cormier-Daire, V., Munnich, A., de Lonlay, P., Reilly, L., Besmond, C., & Bahi-Buisson, N. (2017). Mosaicism in ATP1A3-related disorders: Not just a theoretical risk. *Neurogenetics*, 18(1), 23–28. <https://doi.org/10.1007/s10048-016-0498-9>
- Jaffer, F., Fawcett, K., Sims, D., Heger, A., Houlden, H., Hanna, M. G., Kingston, H., & Sisodiya, S. M. (2017). Familial childhood-onset progressive cerebellar syndrome associated with the ATP1A3 mutation. *Neurology: Genetics*, 3(2), e145. <https://doi.org/10.1212/NXG.0000000000000145>
- Kanemasa, H., Fukai, R., Sakai, Y., Torio, M., Miyake, N., Lee, S., Ono, H., Akamine, S., Nishiyama, K., Sanefuji, M., Ishizaki, Y., Torisu, H., Saito, H., Matsumoto, N., & Hara, T. (2016). De novo p.Arg-756Cys mutation of ATP1A3 causes an atypical form of alternating hemiplegia of childhood with prolonged paralysis and choreo-athetosis. *BMC Neurology*, 16(1), 174. <https://doi.org/10.1186/s12883-016-0680-6>
- Nakamura, Y., Hattori, A., Nakashima, M., Ieda, D., Hori, I., Negishi, Y., Ando, N., Matsumoto, N., & Saitoh, S. (2018). A de novo p.Arg-756Cys mutation in ATP1A3 causes a distinct phenotype with prolonged weakness and encephalopathy triggered by fever. *Brain and Development*, 40(3), 222–225. <https://doi.org/10.1016/j.braindev.2017.09.010>
- Paciorkowski, A. R., McDaniel, S. S., Jansen, L. A., Tully, H., Tuttle, E., Ghoneim, D. H., Tupal, S., Gunter, S. A., Vasta, V., Zhang, Q., Tran, T., Liu, Y. B., Ozelius, L. J., Brashear, A., Sweadner, K. J., Dobyns, W. B., & Hahn, S. (2015). Novel mutations in ATP1A3 associated with catastrophic early life epilepsy, episodic prolonged apnea, and postnatal microcephaly. *Epilepsia*, 56(3), 422–430. <https://doi.org/10.1111/epi.12914>
- Sabouraud, P., Riquet, A., Spitz, M.-A., Deiva, K., Nevsimalova, S., Mignot, C., Lesca, G., Bednarek, N., Doummar, D., Pietrement, C., & Laugel, V. (2019). Relapsing encephalopathy with cerebellar ataxia are caused by variants involving p.Arg756 in ATP1A3. *European Journal of Paediatric Neurology*, 23(3), 448–455. <https://doi.org/10.1016/j.ejpn.2019.02.004>
- Schirinzi, T., Graziola, F., Nicita, F., Travaglini, L., Stregapede, F., Valeriani, M., Curatolo, P., Bertini, E., Vigeveno, F., & Capuano, A. (2018). Childhood rapid-onset ataxia: Expanding the phenotypic spectrum of ATP1A3 mutations. *Cerebellum (London, England)*, 17(4), 489–493. <https://doi.org/10.1007/s12311-018-0920-y>
- Sival, D. A., Vansenne, F., Van der Hout, A. H., Tijssen, M. A. J., & de Koning, T. J. (2018). Fever-induced paroxysmal weakness and encephalopathy (FIPWE)—Part of a phenotypic continuum in patients with ATP1A3 mutations? *Pediatric Neurology*, 81, 57–58. <https://doi.org/10.1016/j.pediatrneurol.2017.12.009>
- Śmigiel, R., Biela, M., Szmyd, K., Błoch, M., Szmida, E., Skiba, P., Walczak, A., Gasperowicz, P., Kosińska, J., Rydzanicz, M., Stawiński, P., Biernacka, A., Zielińska, M., Gołębiowski, W., Jalowska, A., Ohia, G., Głowska, B., Walas, W., Królak-Olejnik, B., ... Płoski, R. (2020). Rapid whole-exome sequencing as a diagnostic tool in a neonatal/pediatric intensive care unit. *Journal of Clinical Medicine*, 9(7), 2220. <https://doi.org/10.3390/jcm9072220>
- Sousa, A. L., Alonso, I., & Magalhães, M. (2017). A Portuguese rapid-onset dystonia-parkinsonism case with atypical features. *Neurological Sciences*, 38(9), 1713–1714. <https://doi.org/10.1007/s10072-017-2996-4>
- Stagnaro, M., Pisciotto, L., Gherzi, M., Di Rocco, M., Gurrieri, F., Parrini, E., Prato, G., Veneselli, E., & De Grandis, E. (2018). ATP1A3 spectrum disorders: A video-documented history of 7 genetically confirmed early onset cases. *European Journal of Paediatric Neurology*, 22(2), 264–271. <https://doi.org/10.1016/j.ejpn.2018.01.010>
- Sweney, M. T., Newcomb, T. M., & Swoboda, K. J. (2015). The expanding spectrum of neurological phenotypes in children with ATP1A3 mutations, alternating hemiplegia of childhood, rapid-onset dystonia-parkinsonism, CAPOS and beyond. *Pediatric Neurology*, 52(1), 56–64. <https://doi.org/10.1016/j.pediatrneurol.2014.09.015>
- Tan, A. H., Ozelius, L. J., Brashear, A., Lang, A. E., Ahmad-Annuar, A., Tan, C. T., & Lim, S. (2014). Rapid-onset dystonia-parkinsonism in a Chinese girl with a De Novo ATP1A3 c.2267G>A (p. R756H) genetic mutation. *Movement Disorders Clinical Practice*, 2(1), 74–75. <https://doi.org/10.1002/mdc3.12122>
- Yano, S. T., Silver, K., Young, R., DeBrosse, S. D., Ebel, R. S., Swoboda, K. J., & Acsadi, G. (2017). Fever-induced paroxysmal weakness and encephalopathy, a new phenotype of ATP1A3 mutation. *Pediatric Neurology*, 73, 101–105. <https://doi.org/10.1016/j.pediatrneurol.2017.04.022>

How to cite this article: Biela, M., Rydzanicz, M., Szymanska, K., Pieniawska-Smiech, K., Lewandowicz-Uszynska, A., Chruszcz, J., Benben, L., Kuzior-Plawiak, M., Szyld, P., Jakubiak, A., Szenborn, L., Ploski, R., & Smigiel, R. (2021). Variants of *ATP1A3* in residue 756 cause a separate phenotype of relapsing encephalopathy with cerebellar ataxia (RECA)—Report of two cases and literature review. *Molecular Genetics & Genomic Medicine*, 9, e1772. <https://doi.org/10.1002/mgg3.1772>

APPENDIX A

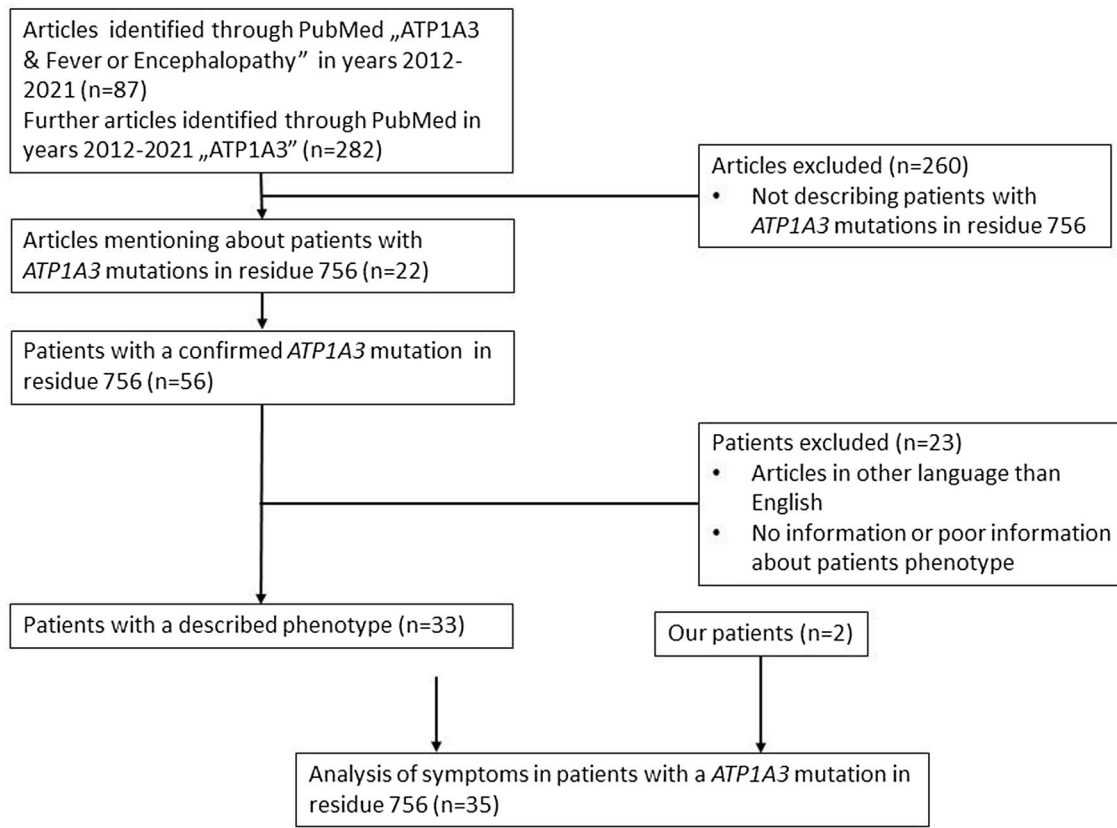


FIGURE A1 Inclusion and exclusion criteria for review of patients with p.Arg756 *ATP1A3* mutation