

## Ghost Aneurysm in Atraumatic Acute Subdural Hematoma: A Sign of Caution or a Mere Finding – A Case Report

### Abstract

Atraumatic subdural bleed often presents with diagnostic and management dilemma. This is a case of a 36-year male who presented with acute onset headache while at rest without any focal neurodeficit. Computed Tomographic Scan of brain revealed subdural hematoma. Cerebral Digital Subtraction Angiography showed a same sided focal dye extravasation which corresponded exactly to the inner margin of the subdural bleed. Though the patient opted out for surgical management this imaging and DSA finding correlated with the “Ghost Aneurysm” concept in acute atraumatic subdural bleeds and its early recognition is an important imaging marker for caution for hematoma expansion.

**Keywords:** *Atraumatic, ghost aneurysm, subdural hematoma*

**Apratim Chatterjee,  
Gaurav Goel,  
Piyush Ojha,  
Anshu Mahajan,  
Anirban Deep  
Bannerjee**

*Department of Neurointervention  
Surgery, Medanta, Medicity,  
Gurgaon, Haryana, India*

### Introduction

Isolated atraumatic subdural hematoma often has illusive etiologies. Rarely, cortical aneurysms<sup>[1]</sup> are associated with such findings. As in intraparenchymal bleed, subdural bleed sometimes gives a sign of a further increase in bleed. The following case report describes an image finding which helps to identify early on about the chance of further bleed in such scenario and hence is of immense importance for management.

### Case Report

The following is a case of a 36-year-male presenting with sudden-onset severe headache. The headache was suddenly occurred while lying on the couch and was present mainly in the anterior and the right part of the head. It was excruciating and occurred “out of blue.” There was no history of trauma or any preexisting comorbidity. After evaluation, no gross neurodeficit was found. Computed tomography (CT) scan of the brain showed the presence of right frontoparietal acute subdural hematoma. As the patient was neurologically intact, a neurosurgical intervention was withheld for the time being with critical observation for any deterioration. A cerebral digital subtraction angiography (DSA) was planned

which showed a focal extravasation of dye in the M3 segment of the parietal branch of the right middle cerebral artery (MCA). The location of the focal extravasation was corresponding to the inner margin of the subdural hematoma. The presence of focal globular dye extravasation in such a location corresponding to the inner margin of subdural hematoma pointed toward the presence of “Ghost aneurysm” formation and urged for immediate treatment [Figure 1]. Attendants were counseled regarding endovascular management and risk of infarct after closure of the branch. Surgical management was denied by patients’ relative. However, the patient took leaving against medical advice (LAMA) and was lost to follow-up.

Isolated atraumatic subdural hematoma due to aneurysm rupture is rare but has been reported previously.<sup>[1]</sup> It has also been reported due to spontaneous rupture of a cortical artery,<sup>[2]</sup> neoplasm<sup>[3]</sup> or hematological abnormality.<sup>[4]</sup> In our case, the patient had no history of trauma neither was in any exertional activity during the event of headache. There was a spontaneous severe bursting headache in lying posture while resting. Such clinical history points toward a possible spontaneous dissection of cortical vessel. The focal globular dye extravasation as seen in DSA near the

This is an open access journal, and articles are distributed under the terms of the Creative Commons Attribution-NonCommercial-ShareAlike 4.0 License, which allows others to remix, tweak, and build upon the work non-commercially, as long as appropriate credit is given and the new creations are licensed under the identical terms.

For reprints contact: WKHLRPMedknow\_reprints@wolterskluwer.com

**How to cite this article:** Chatterjee A, Goel G, Ojha P, Mahajan A, Bannerjee AD. Ghost aneurysm in atraumatic acute subdural hematoma: A sign of caution or a mere finding – A case report. *Asian J Neurosurg* 2021;16:587-8.

**Submitted:** 01-Feb-2021

**Revised:** 04-May-2021

**Accepted:** 19-May-2021

**Published:** 14-Sep-2021

### Address for correspondence:

*Dr. Anshu Mahajan,  
Medanta, Medicity,  
Gurgaon, Haryana, India.  
E-mail: anshunph@gmail.com*

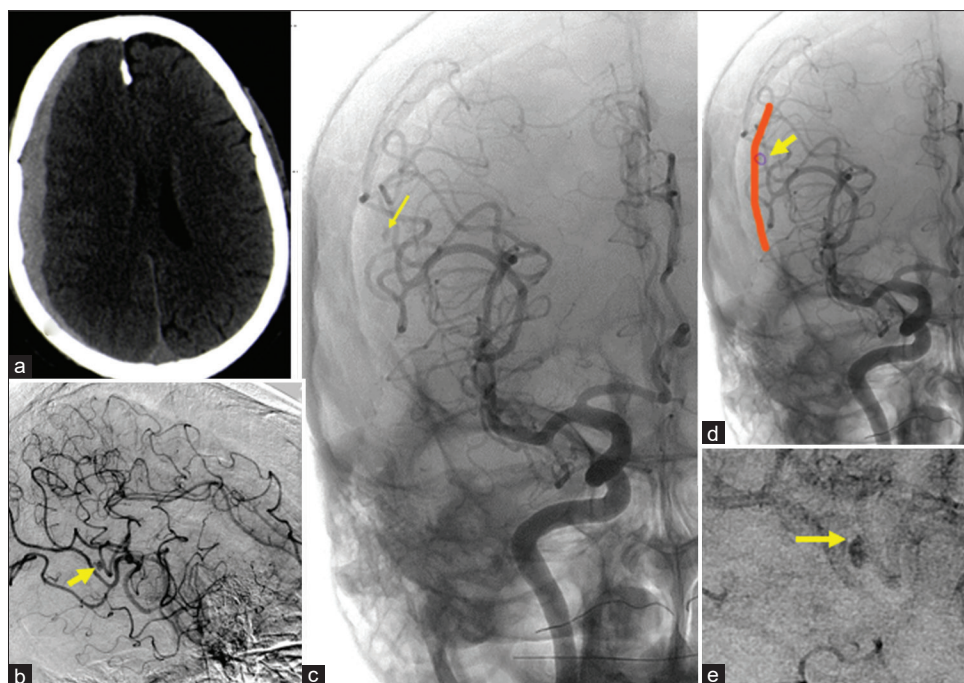
### Access this article online

**Website:** [www.asianjns.org](http://www.asianjns.org)

**DOI:** 10.4103/ajns.AJNS\_560\_20

### Quick Response Code:





**Figure 1:** (a) Acute subdural hematoma in right frontoparietal cortex. (b) Arrow pointing to “Ghost aneurysm” adjacent to m3 segment of the parietal branch of the middle cerebral artery in Lateral view of digital subtraction angiography. (c) Arrow pointing to “Ghost aneurysm” in AP view of digital subtraction angiography. (d) Schematic representation to show “Ghost Aneurysm (yellow arrow) in the inner margin of subdural hematoma (as shown by red line). (e) Arrow pointing to stasis in the “ghost aneurysm” in a venous phase of digital subtraction angiography

M3 segment of MCA vessel pointed toward a possible rupture in that vessel with thrombus formation due to blood extravasation which formed the wall of the so-called “ghost aneurysm” and the dye extravasation within the wall of thrombus led to appearance of an aneurysm. In regard to above, two similar cases have been reported previously causing isolated atraumatic subdural hemorrhage (SDH).<sup>[5]</sup> In our case, however, due to the patient taking LAMA and not opting for treatment, further microcatheter imaging of the area or even craniotomy and subsequent findings could not be documented. In cases where ghost aneurysms have been reported, no such aneurysms were actually found after craniotomy, and hence, such angiographic abnormality has been correlated to “swirl sign” in CT and “spot sign” in CTA implying ongoing bleed in intraparenchymal hemorrhages.<sup>[5]</sup> We contemplate our case to be another evidence of “Ghost aneurysm” based on the angiographic findings and presence of such findings in an SDH should caution for ongoing bleed and increase of SDH and thus prompts urgent management.

## Conclusion

Presence of “Ghost aneurysm” should be identified as an early sign of ongoing bleed and hematoma expansion in a subdural bleed. Hence, this sign needs to be recognized for better management of such patients.

## Declaration of patient consent

The authors certify that they have been obtained in all appropriate forms. In the consent, the patient

and attendants have agreed for images and clinical information to be published for academic purposes. In no way, the identity of the patient has been revealed in this letter.

## Financial support and sponsorship

Nil.

## Conflicts of interest

There are no conflicts of interest.

## References

1. Kondziolka D, Bernstein M, ter Brugge K, Schutz H. Acute subdural hematoma from ruptured posterior communicating artery aneurysm. *Neurosurgery* 1988;22:151-4.
2. McDermott M, Fleming JF, Vanderlinden RG, Tucker WS. Spontaneous arterial subdural hematoma. *Neurosurgery* 1984;14:13-8.
3. Nery B, Costa RAF, Pereira LCT, Quaggio E, Coronatto LH, Tirapelli DPDC, et al. Spontaneous subdural hematoma associated with microcystic meningioma: First case report in the literature. *Br J Neurosurg* 2019;33:428-31.
4. Entezami P, Raval MP, Sanders LN, Adepoju A, Yamamoto J. Spontaneous subdural hematoma in patient with polycythemia vera. *World Neurosurg* 2019;125:354-6.
5. Abecassis ZA, Nistal DA, Abecassis IJ, Sen RD, Levitt MR. Ghost aneurysms in acute subdural hematomas: A report of two cases. *World Neurosurg* 2020;139:e159-65.