

Endoscopy Management of Complete Gastric Outlet Obstruction Secondary to Elipse™ Intra-gastric Balloon

Giulio Ciprian¹, Jessica Khoury¹, Leandro Ramirez¹, John Miskovsky²

1. Internal Medicine, Roger Williams Medical Center, Providence, USA 2. Department of Medicine, Roger Williams Medical Center, Providence, USA

Corresponding author: Giulio Ciprian, giulioqiprian@yahoo.com

Abstract

The Allurion Elipse™ device is a swallowable balloon in the form of a capsule placed without endoscopy that serves the same purpose as an intra-gastric balloon (IGB) used for weight loss. We report a case of a 43-year-old female who presented with a complete gastric outlet obstruction confirmed by computed tomography (CT) scan. The patient initially failed conservative management; therefore, the IGB was later removed endoscopically. This is a rare complication and one of the first cases described in the literature; therefore, further studies are needed before its widescale implementation.

Categories: Internal Medicine, Gastroenterology, Nutrition

Keywords: weight loss, intra-gastric balloon, endoscopy, stomach, gastric outlet obstruction

Introduction

The Allurion Elipse™ device is a swallowable balloon in the form of a capsule that is placed without endoscopy. The scope is to function as a bariatric balloon for weight loss that gradually degrades over time so that four months after placement, it deflates and then is expelled safely through the gastrointestinal tract. The balloon is usually filled with 550 mL of saline solution through a thin catheter after being swallowed [1]. Although extremely rare, this device can lead to partial or complete gastric outlet obstruction [2]. If this is the case, the device can be removed similarly to the Orbera® balloon endoscopically. However, conservative management with intravenous fluids and diet advancement is first tried before any invasive procedure is attempted [3].

Case Presentation

A forty-three-year-old female with no significant medical history but status post abdominoplasty and breast enhancement surgery presents to the hospital with ongoing abdominal pain for three weeks. The patient reported to have had a bariatric surgical procedure in the Dominican Republic consisting of an Allurion Elipse™ balloon placed into her stomach (Figure 1). The device was confirmed to be positioned correctly by abdominal X-ray without signs of hyperinflation. From day one post-surgery, she endorsed nausea, abdominal discomfort, and vomiting and was not able to tolerate p.o. solid and minimal p.o. liquids. She reported the emesis to be non-bilious in nature, with very scanty blood secretions at the end of the vomitus. Moreover, she reported occasional diarrhea described as clear-green in nature without any foul smell associated with it. Since the placement of the device, the patient reports losing about 25 pounds. On admission, the patient was normotensive and afebrile without respiratory distress. Her abdominal pain was managed with morphine and proton pump inhibitors, nausea with Zofran™. An abdominal computer tomography (CT) performed on arrival revealed a distended stomach with complete obstruction of the gastric outlet (Figures 2-3). Furthermore, a gastric bariatric balloon measuring up to 11.6 cm in size was visualized with overall gastric distension measuring up to 11 cm (Figure 4). The patient was initially placed n.p.o. and electrolytes were repleted intravenously; however, the patient did not tolerate the advancement of the diet to clear liquids. The gastroenterology team and the inventor of the device were consulted, both of which initially recommended symptomatic and conservative management and to observe for any improvement. However, on the fifth day of hospitalization, a decision to remove the balloon endoscopically was made since no significant improvements could be observed. During endoscopy, an intra-gastric balloon compatible with the Elipse™ was noticed with no signs of hyperinflation and fully intact in a proper position. Copious fluid was suctioned with some solid debris just underneath the fluid. Using the Orbera® removal system, the balloon was punctured, and approximately 700cc of clear fluid was aspirated. Thereafter, the balloon was retrieved successfully with rat-tooth forceps and found completely intact upon inspection (Figure 5). An esophagogastroduodenoscopy (EGD) was then performed to ensure no injury in the esophagus or cardia sphincter was present, both of which appeared normal. Pylorus and duodenum also appeared normal. After the procedure, the patient felt better and was able to tolerate diet advancement. Repeat CT scan showed complete resolution of the obstruction (Figure 6). The patient was discharged home without any complications.

Review began 08/21/2021

Review ended 08/24/2021

Published 08/29/2021

© Copyright 2021

Ciprian et al. This is an open access article distributed under the terms of the Creative Commons Attribution License CC-BY 4.0., which permits unrestricted use, distribution, and reproduction in any medium, provided the original author and source are credited.

How to cite this article

Ciprian G, Khoury J, Ramirez L, et al. (August 29, 2021) Endoscopy Management of Complete Gastric Outlet Obstruction Secondary to Elipse™ Intra-gastric Balloon. Cureus 13(8): e17542. DOI 10.7759/cureus.17542



FIGURE 1: Allurion Elipse™ balloon with catheter for inflation

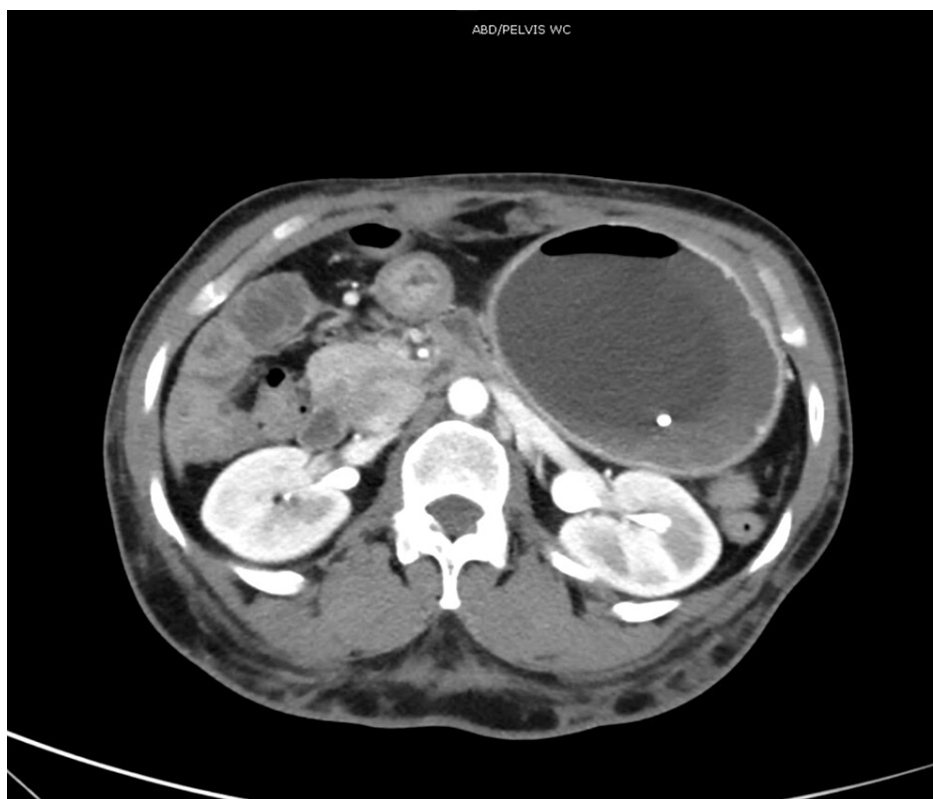

FIGURE 2: Computer tomography of abdomen showing the balloon marker

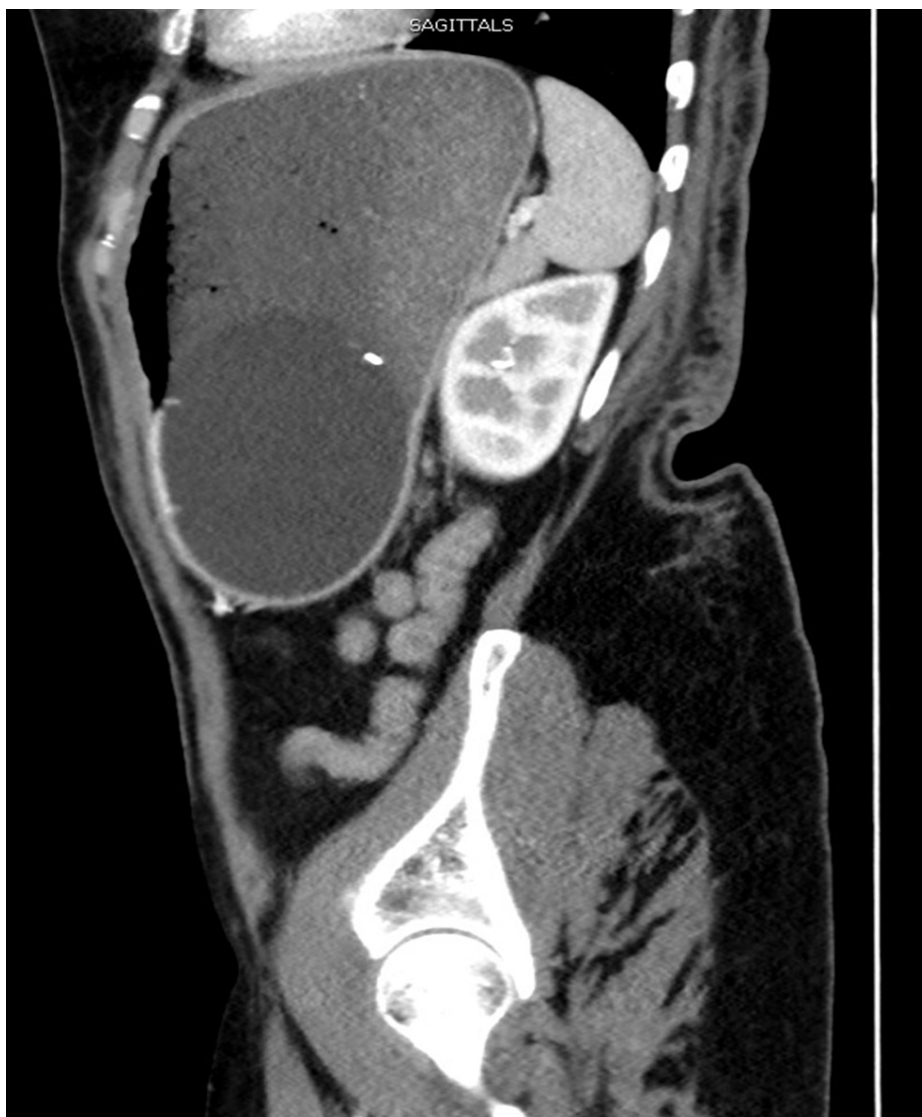

FIGURE 3: Sagittal view of the Elipse™ intragastric balloon obstructing the gastric outlet

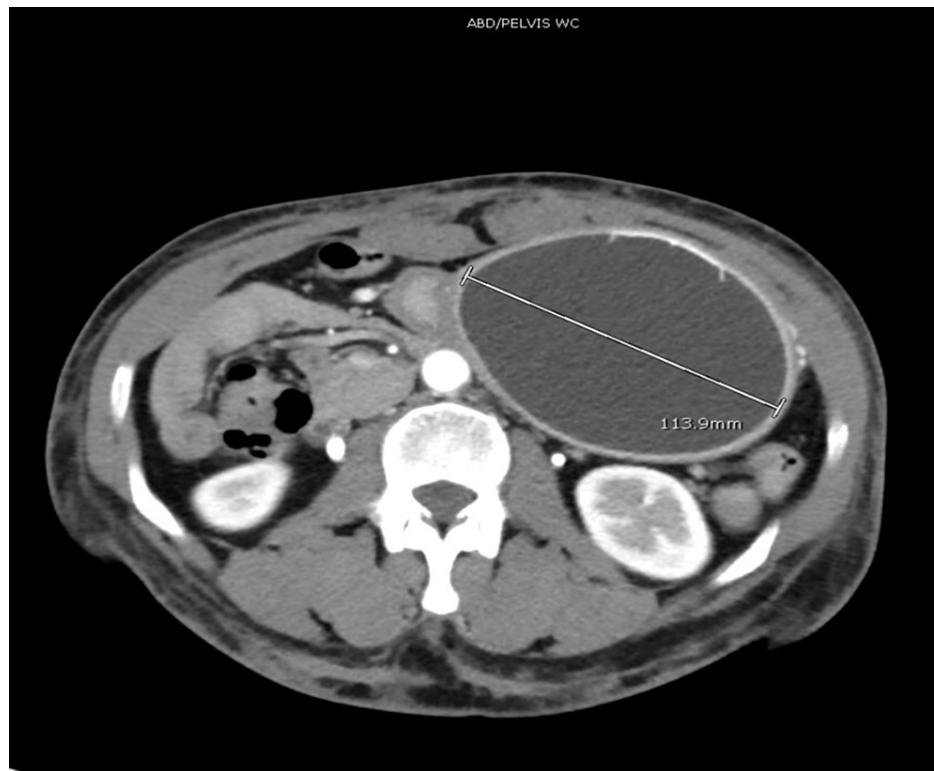

FIGURE 4: Computer tomography of abdomen showing balloon placed in the stomach and its diameter

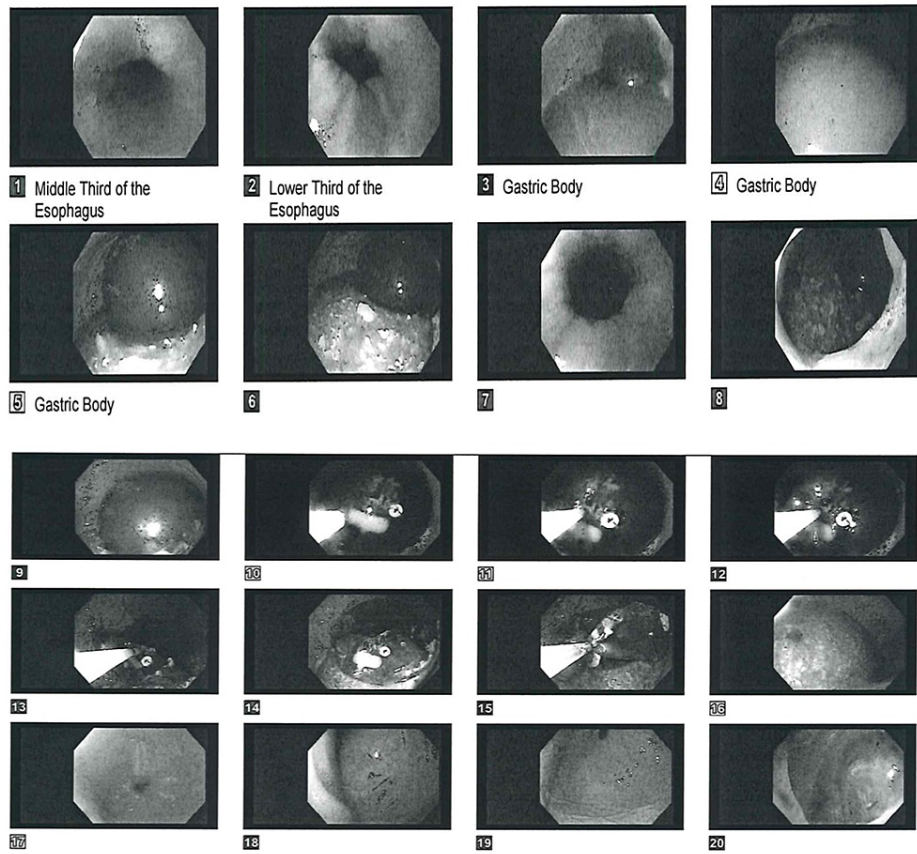


FIGURE 5: Endoscopy showing retrieval of the Elipse™ balloon and esophagogastroduodenoscopy after its removal

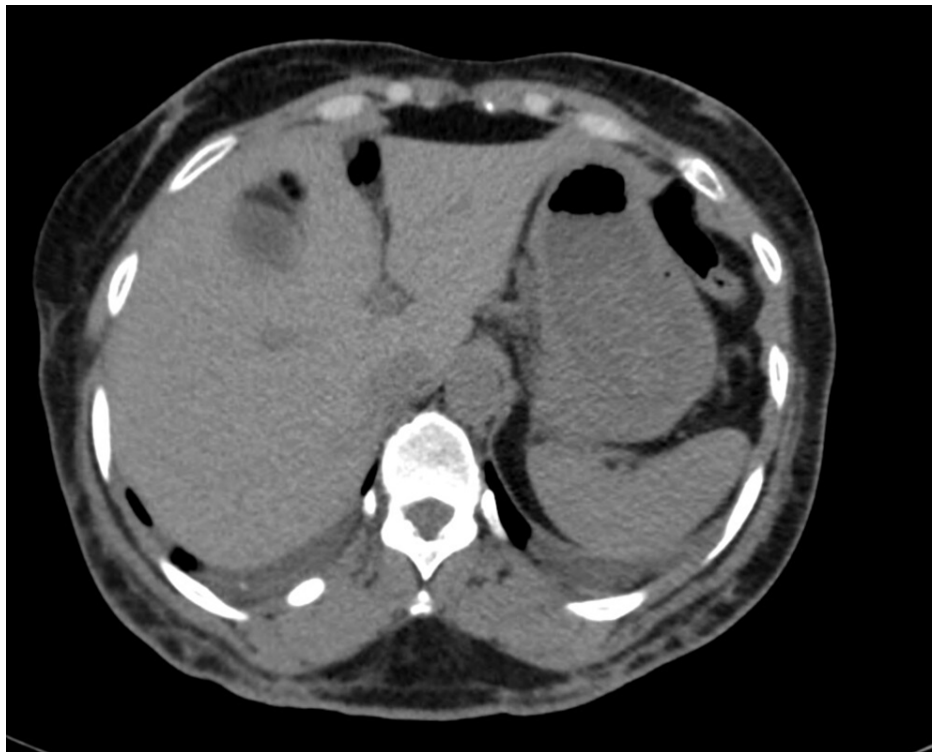

FIGURE 6: Computer tomography of abdomen showing resolution of the obstruction after endoscopic retrieval of the balloon

Discussion

At the moment, the device Allurion Elipse™ is not yet FDA approved for use in the United States. While some health authorities outside of the US have a more liberal approach, it is paramount that more studies and research are performed on this device before its introduction into the North American market. While its way of being deployed and extracted without undergoing anesthesia or endoscopy seems appealing for many patients and providers, more studies are needed for definitive recommendations on the potential carcinogenic risk deriving from the device being in direct contact with the digestive tract lining even after deflation [4-6]. Furthermore, its risks associated with hyperinflation causing complete gastric obstruction in a similar way to pyloric stenosis raise the need for more in-depth trials and safety protocols. Moreover, there has been a case of distal gastric migration, which can raise concerns for rupture and complications derived from it, such as compression of nearby anatomical structures, pancreatitis, and small bowel obstruction [7].

Conclusions

Although initial data showed that the Elipse™ intragastric balloon to be safe overall, serious complications can still occur. As medical providers, we are not able to release definitive recommendations on the safety of the Allurion Elipse™ balloon until further studies and trials are available in the literature.

Additional Information

Disclosures

Human subjects: Consent was obtained or waived by all participants in this study. **Conflicts of interest:** In compliance with the ICMJE uniform disclosure form, all authors declare the following: **Payment/services info:** All authors have declared that no financial support was received from any organization for the submitted work. **Financial relationships:** All authors have declared that they have no financial relationships at present or within the previous three years with any organizations that might have an interest in the submitted work. **Other relationships:** All authors have declared that there are no other relationships or activities that could appear to have influenced the submitted work.

References

1. Machytka E, Chuttani R, Bojkova M, et al.: Elipse™, a procedureless gastric balloon for weight loss: a proof-of-concept pilot study. *Obes Surg.* 2016, 26:512-6. [10.1007/s11695-015-1783-7](https://doi.org/10.1007/s11695-015-1783-7)
2. Ienca R, Al Jarallah M, Caballero A, et al.: The procedureless elipse gastric balloon program: multicenter experience in 1770 consecutive patients. *Obes Surg.* 2020, 30:3354-62. [10.1007/s11695-020-04539-8](https://doi.org/10.1007/s11695-020-04539-8)

3. Salmi A, Greco F, Belleri E: Ultrasound-guided insertion of the elipse® gastric balloon: technical details, learning curve, and perioperative outcome in 36 cases. *J Ultrasound*. 2020, 23:593-7. [10.1007/s40477-020-00499-y](https://doi.org/10.1007/s40477-020-00499-y)
4. Taha O, Abdelaal M, Askiany A, et al.: Outcomes of a swallowable intragastric balloon (elipse™) on 96 overweight and obese patients. *Obes Surg*. 2021, 31:965-9. [10.1007/s11695-020-05086-y](https://doi.org/10.1007/s11695-020-05086-y)
5. Genco A, Ernesti I, Ienca R, et al.: Safety and efficacy of a new swallowable intragastric balloon not needing endoscopy: early Italian experience. *Obes Surg*. 2018, 28:405-9. [10.1007/s11695-017-2877-1](https://doi.org/10.1007/s11695-017-2877-1)
6. Al-Subaie S, Khalifa S, Buhaimed W, Al-Rashidi S: A prospective pilot study of the efficacy and safety of Elipse intragastric balloon: A single-center, single-surgeon experience. *Int J Surg*. 2017, 48:16-22. [10.1016/j.ijso.2017.10.001](https://doi.org/10.1016/j.ijso.2017.10.001)
7. Al-Subaie S, Al-Barjas H, Al-Sabah S, Al-Helal S, Alfakharani A, Termos S: Laparoscopic management of a small bowel obstruction secondary to Elipse intragastric balloon migration: a case report. *Int J Surg Case Rep*. 2017, 41:287-91. [10.1016/j.ijscr.2017.10.050](https://doi.org/10.1016/j.ijscr.2017.10.050)