



# Black fungus immunosuppressive epidemic with Covid-19 associated mucormycosis (zygomycosis): a clinical and diagnostic perspective from India

Kuljeet Singh<sup>1</sup> · Sachin Kumar<sup>1</sup> · Sourabh Shastri<sup>1</sup> · Amrit Sudershan<sup>2</sup> · Vibhakar Mansotra<sup>1</sup>

Received: 5 July 2021 / Accepted: 10 August 2021 / Published online: 1 October 2021  
© The Author(s), under exclusive licence to Springer-Verlag GmbH Germany, part of Springer Nature 2021

## Abstract

The catastrophic phase of Covid-19 turns the table over with the spread of its disastrous transmission network throughout the world. Covid-19 associated with mucormycosis fungal infection accompanied by opportunistic comorbidities have emerged the myriad of complications and manifestations. We searched the electronic databases of Google Scholar, PubMed, Springer, and Elsevier until June 05, 2021, using keywords. We retrieved the details of confirmed and suspected mucormycosis patients associated with Covid-19. We analyzed the case reports, treatment given for Covid-19, steroids used, associated comorbidities, mucormycosis site involved, and patients survived or dead. Overall, 102 patients of mucormycosis associated with Covid-19 have been reported from India. Mucormycosis was predominant in males (69.6%) rather than females (19.6%), and most of the patients were active Covid-19 cases (70.5%). Steroids were mostly used (68.6%) for the treatment of Covid-19 followed by remdesivir (10.7%). Patients were suffering from diabetes mellitus (88.2%) and severe diabetic ketoacidosis (11.7%). Mucormycosis affects the sino-nasal (72.5%), orbit (24.5%), central nervous system (18.6%), and maxillary necrosis (13.7%) of the patients. The Mortality rate was recorded as 23.5%, and recovery rate was 2.9%. Diabetes mellitus cases are highest in India as compared to other countries, and prevalent use of steroids with the background of Covid-19 becomes an opportunistic environment for mucormycosis fungal infection to survive.

**Keywords** Black fungus · Mucormycosis · Covid-19 · Diabetes mellitus · Corticosteroids

## Introduction

The catastrophic phase of Covid-19 (Coronavirus disease 2019) ravages the world by its disastrous ability of transmission from human to human, and it still continues since December 2019 (Shastri et al. 2020). Severe acute respiratory syndrome coronavirus 2 (SARS-CoV-2) yields Covid-19, and now it became more devastating by associating with wide range of fungal and bacterial infections (Shastri et al. 2021a). The main pathogens like aspergillus and candida are mainly involved in the co-infection in patients with some Covid-19 history. The patients with associated comorbidities

(diabetes mellitus, lung infection, pulmonary disease) and immunocompromised conditions (due to over-use of steroids, prolonged mechanical ventilation, long duration of hospital stay) are the prime targets of mucormycosis associated with Covid-19 along with many opportunistic fungal infections. With the development of bacterial or fungal infection in patients, many severe opportunistic co-infections may arise such as bloodstream candida infections, oropharyngeal candidiasis, pulmonary aspergillosis, and pneumocystis jiroveci pneumonia (Sarkar et al. 2021). Paltauf, A. (Paltauf 1885), in 1885 first coined and described the term phycomycosis or zygomycosis, and later in 1957 Baker, RD. (Baker 1957), coined the term mucormycosis for a violent fungal infection caused by rhizopus. Mucormycosis belongs to the class zygomycetes with cunninghamella of order mucorales and is caused by the fungi of the genus rhizomucor. Mucormycosis target the patients with Covid-19 history by taking advantage of their immunocompromised condition, which is a very opportunistic environment for mucormycosis (black fungus) to survive and expand on human body parts. The

✉ Kuljeet Singh  
kuljeetshan94@gmail.com

<sup>1</sup> Department of Computer Science & IT, University of Jammu, Jammu & Kashmir 180006, Jammu, India

<sup>2</sup> Institute of Human Genetics, University of Jammu, Jammu & Kashmir 180006, Jammu, India

global impact of mucormycosis ranges from 0.005 to 1.7, and comparatively, its impact in India is much higher (80%) than its global impact (Chander et al. 2018). The main reason behind this is that the percentage of diabetes mellitus patients is highest in India as compared to other countries, which in turn is a suitable and opportunistic environment for mucormycosis fungal infection to survive (Singh et al. 2021). In recent time, various increasing cases of mucormycosis associated with Covid-19 have been reported globally and particularly in India.

In this paper, we have presented the clinical and diagnostic perspective of mucormycosis (black fungus) fungal infection surge in India. We have gone through a very critical review of 102 patients and their medical contingencies that are published in the last 2 to 3 months. Various factors over mucormycosis are seen as commonest and overlapping among the patients, which are discussed and summarized in following sections.

The rest of the paper is organized as follows: “**Literature review**” represents the critical review of recent scholarly research works that are related to the present study. “**Materials and methods**” describes the research materials and methods that are used in this study to find mucormycosis associated Covid-19 patients. “**Case presentation**” represents the case presentation of 102 patients from India that are infected/suspected with mucormycosis associated Covid-19. “**Results and discussion**” explains the result of mucormycosis affected patients and states of India. “**Discussion**” contains the discussion of various mucormycosis parameters. “**Conclusion**” illustrates the conclusion of the study.

## Literature review

Rhino-cerebral mucormycosis associated with Covid-19 pneumonia and comorbidities like type 1 diabetes mellitus of a patient were discussed and a case report was also presented. RT-PCR was used to diagnose the Covid-19, and the patient was treated with steroids and hydroxychloroquine. Intravenous (IV) fluids and insulin drip were used for treating diabetic ketoacidosis, and patient was discharged after mucormycosis was cured (Alekseyev et al. 2021).

The active case of Covid-19 with mucormycosis and orbital compartment syndrome was diagnosed. Patient was affected with proptosis, diabetic ketoacidosis (DKA), and unbalanced mental health. Intravenous fluids and sodium bicarbonate were given to the patient for treatment of DKA. Left middle turbinate of the patient was getting black with mucormycosis fungal infection, and Amphotericin-B was given to the patient for fungal recovery, but unfortunately, on the 26th day of the treatment, patient died in the hospital (Werthman-Ehrenreich 2020).

The patient was confirmed with Covid-19 after getting a fever, shortness of breath, and cold. Patient was treated with extensive use of antibiotics, interleukin antagonists, and high-dose glucocorticoids for the treatment of Covid-19 but due to immunocompromised conditions patient succumbed to mucormycosis fungal infection (Placik et al. 2020).

The Covid-19 infected patient with arterial hypertension has been succumbed to the opacification of maxillary left sinus and identified with the Rhizopus. The patient died after 62 days with liver failure and refractory shock (Pasero et al. 2020).

Patient with Covid-19 disease confirmation and hospitalization got remdesivir, corticosteroid, and interferon-alpha for the treatment of Covid-19. After 1 week of hospital discharge, patient was facing hemifacial pain, nasal congestion, and rhinorrhea. Having immunosuppressant problems, patient was infected with mucormycosis and later ophthalmic treatment revealed that patient has complete loss of vision and right-side proptosis (Karimi-Galougahi et al. 2019).

Two Covid-19 patients with lung injuries were undergone corticosteroid therapy and were affected with visual loss, ophthalmoplegia, and orbital inflammation. Histopathologic and radiologic findings were confirmed that both patients had affected with mucormycosis fungal infection. Amphotericin-B is used with endoscopic sinus debridement for the treatment but one patient died due to intracranial space involvement (Veisi et al. 2021).

Anxiety disorder patient with respiratory distress and fatigue had Covid-19 positive report on hospitalization. Patient was identified with comorbidities like metabolic acidosis, hyperglycemia, and hypoxia and was underwent corticosteroid treatment. After a week in intensive care unit, patient was caught with proptosis, ophthalmoplegia, and restricted eye moment followed by mucormycosis fungal confirmation patient succumbed to death (Sargin et al. 2021).

A case report of a patient with Covid-19 and severe rhino-orbital mucormycosis fungal infection has been reported. Patient has succumbed to severe diabetic ketoacidosis, severe metabolic acidosis, and diabetes mellitus which became opportunistic for mucormycosis to gear up fungal infection (Waizel-Haiat et al. 2021).

Patient suffering from acute myeloid leukemia infected with Covid-19 has been reported as mucormycosis confirmed fungal infection. Patient was treated with multiple comorbidities in the hospital and was diagnosed with pulmonary mucormycosis (Zurl et al. 2021).

Poorly controlled diabetic patient with confirmed Covid-19 disease has infected with comorbidities such as malaise, unilateral facial swelling, partial dyspnoea, earache, and myalgia. The otolaryngologist has been

consulted for endoscopic sinus surgery which confirms the mucosal thickening in sinusitis (Ahmadikia et al. 2021).

## Materials and methods

A structured review of literature was searched in the electronic databases of Google Scholar, PubMed, Springer, and Elsevier until June 2021 using keywords “Mucormycosis,” “Covid-19,” “Zygomycosis,” “SARS CoV-2,” “Mucor,” “Phycomycosis,” and “Rhizopus.” The veracity of data has been checked independently by the corresponding authors. We retrieved the details of confirmed and suspected mucormycosis associated with Covid-19 patients (Table 1). The case studies of patients from various medical institutes from India with mucormycosis and Covid-19 have been thoroughly studied, and the characteristics of each patient were collected and analyzed through various endpoints and results (Table 2).

## Results

The mucormycosis surge associated with Covid-19 in India is at its peak. There are more than 28 K active cases of mucormycosis in different Indian states. Most of the Indian states and union territories declared the mucormycosis as “black fungus epidemic.” The white fungus and yellow fungus cases were also seen in some states but the count of affected patients are limited. Although mucormycosis has been spread in 28 states/union territories (UTs), Table 3 describes some Indian states with higher mucormycosis associated Covid-19 confirmed and death cases. A total of 86% of the mucormycosis patients in India have Covid-19 history, and 62.3% of the patients are having a history of diabetes. To control the mucormycosis effect, the central government has sent about 2,70,060 vials of Amphotericin B to different states/UTs as of May 30, 2021.

A total of 102 cases of mucormycosis (black fungus) from India are considered in this study. Out of which 96/102 (94.1%) are confirmed and 6/102 (5.8%) are suspected of mucormycosis associated with Covid-19. A total of 72/102 (70.5%) of the cases are confirmed with Covid-19, and 30/102 (29.4%) are recovered cases prior to the inception of mucormycosis in patient’s bodies (Table 1). This study reveals that mucormycosis predominantly spreads more in males (69.6%) rather than females (19.6%). For the treatment of Covid-19, patients are being diagnosed with different medicines. Steroids have been given to 68.6% of patients

followed by Remdesivir to 10.7% of patients, Tocilizumab to 2.9% of patients, and long-term antimicrobials have been given to 9.8% Covid-19 affected patients. Diabetes mellitus is the most viral risk factor that prevailed in the majority of the cases (88.2%) having patients that are affected with mucormycosis associated with Covid-19. Corticosteroids and different comorbidities associated with the Covid-19 patients lead them to viral mucormycosis fungal infection (Fig. 1). Severe diabetic ketoacidosis was present in 11.7% of patients with Covid-19 and mucormycosis. Chronic kidney disease, hypertension, and cancer were also present in some of the cases (1.9%) infected with mucormycosis and Covid-19. Severe metabolic acidosis (0.9%), coronary artery disease (0.9%), chronic granulomatous disease (0.9%), and leukemia (0.9%) are the multifactorial diseases prerequisite to patients affected with Covid-19 and mucormycosis that increases the disease severity rate of the patients. Most of the cases (94.1%) are confirmed with the black fungus disease (mucormycosis), and around 5.8% of the patients are suspected with mucormycosis viral infection along with Covid-19. Among all the patients, the common organs that are involved in mucormycosis fungal infection are Sino-nasal (72.5%) followed by orbit (24.5%) and some more organs that are common among the patients are the central nervous system (18.6%), maxillary necrosis (13.7%), intracranial extension (8.8%), pulmonary (6.8%), right maxilla and zygoma (1.9%), and lung infection (0.9%). Mucormycosis survival status is about 52.9% of the patients that are still alive and are under treatment in the hospitals. A total of 23.5% of the patients are dead because of the mucormycosis associated with Covid-19, and almost 12.7% of patients are improved in their health. The severity of the disease depends on the factors like age, comorbidities associated with Covid-19 (confirmed/recovered) patient, treatment received for Covid-19, and site involved for the mucormycosis. The old aged patients with compromised immunology are more susceptible to mucormycosis. The corticosteroids used for the treatment of the Covid-19 are main the reason behind the immunosuppressant severity among the patients. Also, the site involved for the mucormycosis is a key factor behind the severity of fungus that infected the patients. For example, if the nervous system is affected with the mucormycosis, it is more severe than the other infected body parts involved. The recovery rate (2.9%) of the patients that are infected with mucormycosis and Covid-19 is very less. Table 2 summarizes the characteristics of the 102 patients from India that are exposed to black fungus (mucormycosis).

## Case presentation

**Table 1** Mucormycosis associated with Covid-19 for 102 cases reported in India till June 2021

Author	N, Male (M)/ Female (F)	Age of patients (range in years)	COVID-19 Confirmed (active(A)/ recovered(R))	Treatment received for COVID-19	Comorbidities	Confirmed/suspected mucormycosis	Site involved	Survival status
Paul et al. (2021)	16: 13(M), 3(F)	24–75	Confirmed, A: 14, R: 2	Steroids, long-term anti- microbials	DM: 12, CAD: 1, CKD: 2, CGD: 1	Confirmed	Sino-nasal, Pulmonary	Alive: 10 Death: 6
Moorthy et al. (2021)	18: 15(M), 3(F)	35–73	Confirmed, A	Steroids	DM: 16, Cancer	Confirmed	Maxillary necrosis, Intracranial extension	Alive: 12 Death: 6
Krishna et al. (2021)	2, M	34–50	Confirmed, R	NR	DM, Hypertension	Confirmed: 1 Suspected: 1	Right maxilla and zygoma	Recovered
Sahoo et al. (2021)	1, F	25	Confirmed, R	Steroids	DM	Confirmed	Orbit, Sino-nasal, CNS	Death
Revannavar et al. (2021)	1, F	40	Confirmed, A	NR	DM, SMA	Confirmed	Sino-nasal, CNS, Orbit	Improved
Sarkar et al. (2020)	10: M(8), F(2)	27–67	Confirmed, A	Steroids, Remdesivir	DM, SDK	Confirmed: 6 Suspected: 4	Sino-nasal, CNS	Alive: 6 Death: 4
Mishra et al. (2021)	10: 9(M), 1(F)	37–78	Confirmed, A	Steroid, Tocilizumab, Remdesivir	DM	Confirmed	Sino-nasal, CNS, Orbit	Alive: 5 Death: 4 NR: 1
Garg et al. (2021)	1, M	55	Confirmed, A	Steroids	DM	Confirmed	Lung Infection	Improved
Saldanha (2021)	1, F	32	Confirmed, A	NR	DM	Confirmed	Sino-nasal, Orbit	Improved
Sharma et al. (2021)	23: M(15), F(8)	NR	Confirmed, A: 4, R: 19	Steroids	DM, SDK	Confirmed	Sino-nasal, CNS	Alive: 21 NR: 2
Maiti et al. (2021)	1, M	38	Confirmed, R	Remdesivir, Steroids	NR	Confirmed	Lung Infection	Recovered
Sen et al. (2021)	6, M	47–74	Confirmed, A: 1, R: 5	Steroids	DM	Confirmed: 5 Suspected: 1	Sino-nasal, Orbit, CNS	Improved
Mehta et al. (2020)	1, M	60	Confirmed, A	Tocilizumab, Steroids	DM	Confirmed	Sino-nasal, Orbit	Death
Satish et al. (2021)	11: M(NR), F(NR)	30–74	Confirmed, A	NR	DM, Leukemia	Confirmed	Sino-nasal, Orbit, CNS	Improved: 4 Death: 2 LAMA: 5

N total number of patients, NR not reported, DM diabetes mellitus, SMA severe metabolic acidosis, SDK severe diabetic ketoacidosis, CAD coronary artery disease, CKD chronic kidney disease, CGD chronic granulomatous disease, CNS central nervous system, LAMA left against medical advice.

**Table 2** Characteristics of 102 patients from India exposed to mucormycosis with Covid-19

Parameters	Value	Affected ratio (in %)	Remarks/Outcome
Age	Range 24–78	-	
Sex	Male	71/102 (69.6)	Most prevalent in 30–50 age group Males are more targeted by mucormycosis
	Female	20/102 (19.6)	
	NR	11/102 (10.7)	
Covid-19 Status	Active	72/102 (70.5)	More active cases leads to its epidemic surge in India
	Recovered	30/102 (29.4)	
	Steroids	70/102 (68.6)	
Treatment for Covid-19	Remdesivir	11/102 (10.7)	Steroids are most frequently used among the patients
	Tocilizumab	3/102 (2.9)	
	Long-term antimicrobials	10/102 (9.8)	
Patients suffering from	NR	8/102 (7.8)	Diabetes mellitus with severe diabetic ketoacidosis always increases the contamination ratio of patients being affected with mucormycosis. Diabetes mellitus is frequently found among the patients that are infected with the Covid-19 The multifactorial diseases prerequisite to patients affected with Covid-19 and mucormycosis that increases the disease severity rate of the patients
	Diabetes mellitus	90/102 (88.2)	
	Severe metabolic acidosis	1/102 (0.9)	
	Severe diabetic ketoacidosis	12/102 (11.7)	
	Coronary artery disease	1/102 (0.9)	
	Chronic kidney disease	2/102 (1.9)	
	Cancer	2/102 (1.9)	
	Chronic granulomatous disease	1/102 (0.9)	
	Hypertension	2/102 (1.9)	
	Leukemia	1/102 (0.9)	
NR	1/102 (0.9)		
Mucormycosis	Confirmed	96/102 (94.1)	Patients are under microbiological diagnosis
	Suspected	6/102 (5.8)	
Mucormycosis affects on	Sino-nasal	74/102 (72.5)	Sino-nasal infection is most commonly targeted by mucormycosis associated with Covid-19
	Orbit	25/102 (24.5)	
	Maxillary necrosis	14/102 (13.7)	
	Intracranial extension	9/102 (8.8)	
	Pulmonary	7/102 (6.8)	
	Central nervous system	19/102 (18.6)	
	Right maxilla and zygoma	2/102 (1.9)	
	Lung infection	1/102 (0.9)	
	Alive	54/102 (52.9)	
	Dead	24/102 (23.5)	
Survival Status	Improved	13/102 (12.7)	Although the patient's death rate is less than alive rate but we cannot predict the final survival status of the patients. Treatment is still under process for most of the patients
	Recovered	3/102 (2.9)	
	Left against medical advice	5/102 (4.9)	
	NR	3/102 (2.9)	

NR not reported

**Table 3** Confirmed and death cases of mucormycosis in Indian states (as on July 31, 2021) (Ministry of Health Family Welfare. MoHFW Home. Ministry of Health Family Welfare 2020)

State/union territory	Confirmed cases	Death cases	Notifiable disease/epidemic declared
Maharashtra	7998	476	Yes
Gujarat	5486	250	Yes
Rajasthan	1524	74	Yes
Andhra Pradesh	1179	14	Yes
Delhi	1044	89	Yes
Tamil Nadu	1000	409	Yes
Madhya Pradesh	987	31	Yes
Telangana	744	2	Yes
Uttar Pradesh	500	19	Yes
Karnataka	446	12	Yes
<b>Total</b>	<b>20,908</b>	<b>1376</b>	

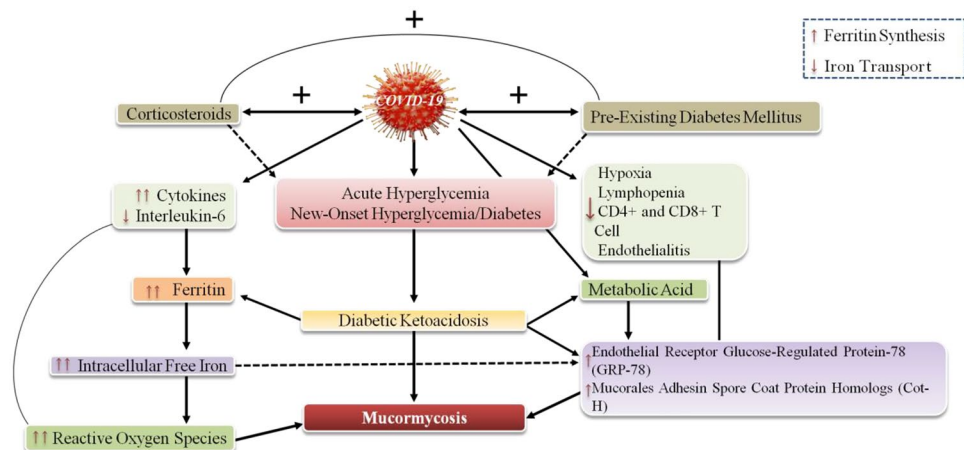
## Discussion

### Why mucormycosis (black fungus)

The immunocompromised patients are under great threat of very rare fungal infection known as mucormycosis or zygomycosis or black fungus. The Covid-19 active or recovered patients with low immunity level are the primary targets of mucormycosis. People are infected when they came into contact with the fungal spores in the environment or when the fungus entered human body through some means of skin trauma. The Covid-19 patients are suffered from the immunocompromised conditions by ingesting the drugs like dexamethasone, tocilizumab, itolizumab, and extensive use of steroids for Covid-19 treatment which in turn suppresses the immune system of the human body. Mucormycosis or black fungus is caused by the set of micro organisms called as mucormycetes that are also present in the environment naturally in soil,

decaying organic matter, or compost. The diabetic or low immunity patients having Covid-19 history needs to be taken care of it because mucormycetes organisms could take advantage of low immunity along with co-morbidities and surpass the health mechanism of the patients (Shastri et al. 2021b). The mask used regularly without change or wash of it could also be dangerous for health and sufficient for mucormycosis inception in the body. The moisture exposure of unchanged mask or oxygen therapy of Covid-19 patients in hospitals could be prone to fungal infection like mucormycosis. Indian Council of Medical Research issued an advisory explaining causes and conditions for Covid-19 patients susceptible to mucormycosis infection. Uncontrolled diabetes, immunocompromised patients due to use of steroids, prolonged stay in hospital or ICU, co-morbidities like cancer, and voriconazole therapy are major causes for mucormycosis or black fungus infection (Ministry of Health Family Welfare. MoHFW Home. Ministry of Health Family Welfare 2020).

**Fig. 1** Patients with mucormycosis associated with Covid-19, diabetes, and corticosteroid





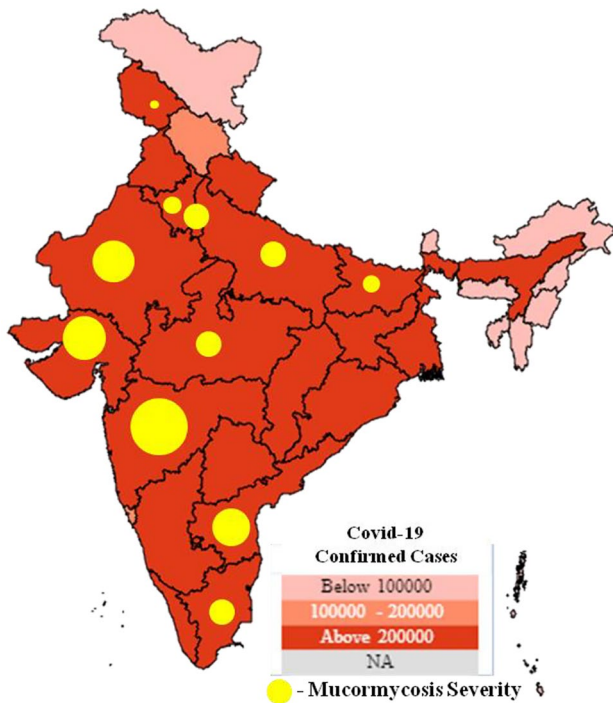


Fig. 2 Covid-19 and mucormycosis (black fungus) severity in India

### Vaccines for mucormycosis and Covid-19

Amphotericin-B, posaconazole, and isavuconazole are the antifungal medicines used for the treatment of mucormycosis

or black fungus. These medicines are given to the patients directly through vein or in some cases through mouth also. In most of the cases, it is seen that the dead or infected tissues with the mucormycosis required surgery. Liposomal amphotericin-B ( $\geq 5$  mg/kg) is used as the first line therapy for the mucormycosis along with the surgery. The mortality rate of the mucormycosis is quite high (up to 70%) despite of proper treatment (Brunet and Rammaert 2020). One immunocompromised patient with rhino-orbital-cerebral mucormycosis having acute invasive fungal sinusitis was treated with the retrobulbar injections of amphotericin-B deoxycholate along with the intravenous antifungals and endoscopic sinus debridement (Hirabayashi et al. 2017). More than 3 million vials of Amphotericin-B have been allocated to states and UTs of India to combat mucormycosis. More than 240 million vaccine doses have been administered by Indian states and UTs. Covaxin, Covishield, and Sputnik-V are the active vaccines that are being administered throughout India at large scale. By the end of 2021, half a dozen vaccines will be available to minimize the gap between demand and supply of vaccines.

### India under great threat of pandemic series

India is battling with the second wave of Covid-19, and total cases are more than 28 million with 1.7 million active cases, 3,37,989 deaths, and about 26 million recovered cases as of June 3, 2021. Fighting with the current pandemic situation, a new epidemic surge has been notified by the Indian states

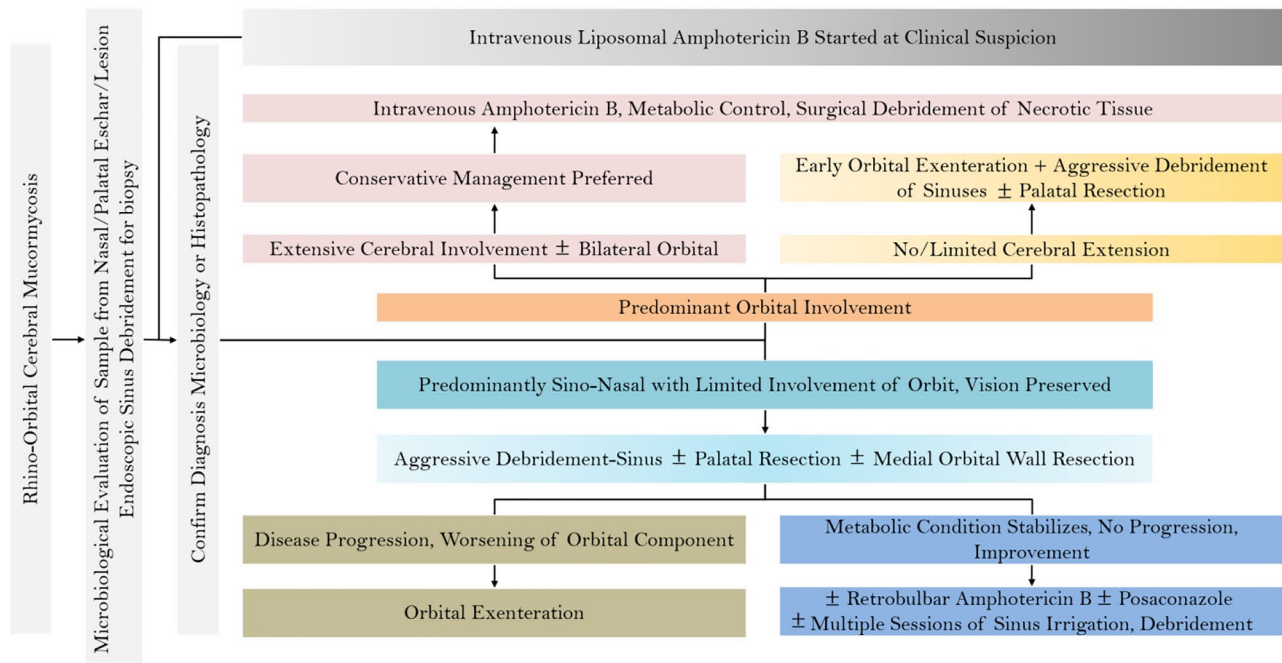


Fig. 3 Prescriptions for predominant orbital involvement and surgical debridement in mucormycosis cases

and UTs known as mucormycosis or black fungus (Kumar et al. 2020). The cases of black fungus are also increasing in almost all the states/UTs at a rapid rate like Covid-19 was at its initial stages (Fig. 2). Therefore, it is a matter of great concern for the whole world as the new variants of Covid-19 associated mucormycosis have been notified. Along with the black fungus cases at a large scale, few cases of white fungus and yellow fungus were also seen in different parts of the country. While the third wave of Covid-19 is expected in the country, there is a sudden hike in the cases of multi-system inflammatory syndrome among children (MIS-C) and that became the matter of great concern for many paediatricians. According to the Indian academy of pediatrics, there were more than 2000 cases of multi-system inflammatory syndrome since the first wave of Covid-19 (Academy and of Pediatrics (IAP) | COVID-19. 2021).

### Mucormycosis in other countries

Mucormycosis is expanding its disastrous net not only in India but in many other countries also. The USA, Brazil, France, Italy, Turkey, Iran, Austria, and Mexico along with many other countries are also experiencing cases of mucormycosis associated with Covid-19. Immunocompromised patients are direct targets of this fatal fungal infection; otherwise, if immune system is strong, mucormycosis (black fungus) can be fled away without taking much medication and hospitalization. Singh et al. (2021) has reported 19 cases of mucormycosis associated with Covid-19 from 8 different countries other than India. All the patients have Covid-19 history of active or recovered cases and having diabetes mellitus, cancer, or any other comorbidities associated with them. Some of the patients have used steroids, tocilizumab, and remdesivir for their treatment of Covid-19 which may cause their immunocompromised condition. A total of 12/19 patients (63.1%) are dead because of their suppressed immune system and were under attack of mucormycosis associated with Covid-19. Patients are supervised to learn the correct and credible use of steroids when needed and be aware of the user generated content over the internet that may lead to misinformation about the same (Jain et al. 2021).

### Symptoms and precautionary measures for mucormycosis

There are vital symptoms that show inception of mucormycosis (black fungus) fungal infection in the human body. Mucormycosis can affect different parts of the body, and mainly, it affects the nasal sinuses, skin, orbit, central nervous system, lungs, oral cavity, and gastrointestinal. Rhinocerebral and rhino-orbital mucormycosis are the commonest seen affected parts throughout the literature survey. Black lesion, ptosis, one-sided facial swelling, and ophthalmoplegia are the symptoms that are seen among the mucormycosis

associated with Covid-19 patients. Gastrointestinal bleeding, stroke, swelling of gums, and hemiplegia are also seen in few cases. In order to detect the mucormycosis at the early stages the symptoms must be known to the patients who recovered or having some Covid-19 history. The precautionary measures must be followed by the suspected patients in order to avoid any black fungus infection scenario. Depending upon the predominant orbital involvement different precautions and results are given (Fig. 3). Patients depending on immunosuppressant's (or steroids) need to take prescribed precautions and curb the diabetes mellitus, high blood sugar levels, and use immune suppressed drugs only when prescribed by the doctors. Mucormycosis involvement in the otorhinolaryngology can cause hazardous conditions; therefore, patients must wear clean mask, wash hands regularly, and use facial protection. Moreover, as immunity is so much involved, patients should not be compromised with healthy food and keep themselves hydrated with exercise and yoga practices intact (Ministry of Ayush | Covid-19 2021).

### Conclusion

The catastrophic phase of Covid-19 and associated mucormycosis (black fungus) raised the calamitous situation around the world and specifically in India. The diabetes mellitus is the utmost biological threat to the people of India. Mucormycosis associated with Covid-19 is spreading at a high pace because of the immunocompromised patients. Extensive use of steroids and other drugs given in the name of Covid-19 treatment are the main causes for the immunosuppressant patients. Comorbidities such as diabetes mellitus and severe diabetic ketoacidosis are the opportunistic conditions for the mucormycosis to survive into the patient's body. This study reveals that mucormycosis is predominant in males (69.6%) rather than females (19.6%), and most of the patients are active Covid-19 cases (70.5%). Patients are suffering from diabetes mellitus (88.2%) and severe diabetic ketoacidosis (11.7%). Steroids are mostly used (68.6%) for the treatment of Covid-19 followed by remdesivir (10.7%). Mucormycosis affects the sino-nasal (72.5%), orbit (24.5%), central nervous system (18.6%), and maxillary necrosis (13.7%) of the patients. The mortality rate was recorded as 23.5%, and the recovery rate was 2.9%.

**Acknowledgements** This research work is dedicated to Covid-19 front-line workers.

### Declarations

**Informed consent** Not applicable.

**Conflict of interest** The authors declare no competing interests.



## References

- Ahmadikia K, Hashemi SJ, Khodavaisy S et al (2021) The double-edged sword of systemic corticosteroid therapy in viral pneumonia: a case report and comparative review of influenza-associated mucormycosis versus COVID-19 associated mucormycosis. *Mycoses*. (February):1–11. <https://doi.org/10.1111/myc.13256>
- Alekseyev K, Didenko L (2021) Chaudhry B. Rhinocerebral mucormycosis and COVID-19 pneumonia. *J Med Cases*. 12(3):85–89. <https://doi.org/10.14740/jmc3637>
- Baker RD (1957) Mucormycosis; a new disease. *J Am Med Assoc* 163(10):805–808. <https://doi.org/10.1001/jama.1957.02970450007003>
- Brunet K, Rammaert B (2020) Mucormycosis treatment: recommendations, latest advances, and perspectives. *J Mycol Med* 30(3):101007. <https://doi.org/10.1016/j.mycmed.2020.101007>
- Chander J, Kaur M, Singla N et al (2018) Mucormycosis: battle with the deadly enemy over a five-year period in India. *J fungi* (Basel, Switzerland). 4(2). <https://doi.org/10.3390/jof4020046>
- Garg D, Muthu V, Singh I, Raja S (2021) Coronavirus disease (Covid-19) associated mucormycosis (CAM): case report and systematic review of literature. *Mycopathologia* 186(2):289–298. <https://doi.org/10.1007/s11046-021-00528-2>
- Hirabayashi KE, Kalin-Hajdu E, Brodie FL, Kersten RC, Russell MS, Reza VM (2017) Retrobulbar Injection of Amphotericin B for Orbital mucormycosis. *Ophthal Plast Reconstr Surg* 33(4):e94–e97. <https://doi.org/10.1097/IOP.0000000000000806>
- Indian Academy of Pediatrics (IAP) | COVID-19. Published 2021. Accessed June 6, 2021. <https://iapindia.org/get-latest-guidance-on-COVID-19/>
- Jain PK, Pamula R, Ansari S (2021) A supervised machine learning approach for the credibility assessment of user-generated content. *Wireless Pers Commun* 118:2469–2485. <https://doi.org/10.1007/s11277-021-08136-5>
- Karimi-Galougahi M, Arastou S, Haseli S (2021) Fulminant mucormycosis complicating coronavirus disease 2019 (COVID-19). *Int Forum Allergy Rhinol*. 1029–1030. <https://doi.org/10.1002/alr.22785>
- Krishna DS (2021) Maxillofacial infections in Covid-19 Era — actuality or the unforeseen: 2 Case reports. *Indian J Otolaryngol Head Neck Surg* 2:2–5. <https://doi.org/10.1007/s12070-021-02618-5>
- Kumar M, Gupta S, Kumar K, Sachdeva M (2020) Spreading of Covid-19 in India, Italy, Japan, Spain, UK, US: a prediction using ARIMA and LSTM model. *Digit Gov: Res Pract* 1, 4. <https://doi.org/10.1145/3411760>
- Maini A, Tomar G, Khanna D, Kini Y, Mehta H, Bhagyasree V (2021) Sino-orbital mucormycosis in a COVID-19 patient: a case report. *Int J Surg Case Rep* 82(April):105957. <https://doi.org/10.1016/j.ijscr.2021.105957>
- Mehta S, Pandey A (2020) Rhino-orbital mucormycosis associated with Covid-19. *Cureus* 12(9):10–14. <https://doi.org/10.7759/cureus.10726>
- Ministry of Ayush | Covid-19. Accessed June 6, 2021. <https://www.ayush.gov.in/>
- Ministry of Health & Family Welfare. MoHFW Home (2021) Ministry of Health & Family Welfare, Government of India. 2020. Accessed June 5, 2021. <https://www.mohfw.gov.in/>
- Mishra N, Sai V, Mutya S, et al (2021) A case series of invasive mucormycosis in patients with COVID-19 infection. *Int J Otorhinolaryngol Head Neck Surg*. 7(5):867–870. <https://doi.org/10.18203/issn.2454-5929.ijohns20211583>
- Moorthy A, Gaikwad R, Krishna S, Hegde R (2021) SARS-CoV-2, Uncontrolled diabetes and corticosteroids — an unholy trinity in invasive fungal infections of the maxillofacial region? A retrospective, multi-centric analysis. *J Maxillofac Oral Surg*. 2. <https://doi.org/10.1007/s12663-021-01532-1>
- Paltauf A (1885) Mycosis mucorina. *Arch Für Pathol Anat Und Physiol Und Für Klin Med* 102(3):543–564. <https://doi.org/10.1007/BF01932420>
- Pasero D, Sanna S, Liperi C, Piredda D, Branca G Pietro (2020) A challenging complication following SARS-CoV-2 infection: a case of pulmonary mucormycosis. *Infection*. <https://doi.org/10.1007/s15010-020-01561-x>
- Paul SS, Kumar R, Meena VP et al (2021) Clinical characteristics and outcomes of 16 cases with COVID19 and mucormycosis: experience from a tertiary care center in India and review of literature. <https://doi.org/10.21203/rs.3.rs-533347/v1>
- Placik DA, Taylor WL, Wnuk NM (2020) Bronchopleural fistula development in the setting of novel therapies for acute respiratory distress syndrome in SARS-CoV-2 pneumonia. *Radiol Case Reports* 15(11):2378–2381. <https://doi.org/10.1016/j.radcr.2020.09.026>
- Revannavar SM, Supriya P, Samaga L, Vineeth K (2021) COVID-19 triggering mucormycosis in a susceptible patient: a new phenomenon in the developing world. *BMJ Case Rep*. 14(4). <https://doi.org/10.1136/bcr-2021-241663>
- Sahoo JP, Mishra AP, Pradhan P, Samal KC (2021) Misfortune never comes alone—the new “black fungus” accompanying COVID-19 wave. 2021;3(5):318–320. <https://doi.org/10.13140/RG.2.2.36157.59361>
- Saldanha M, Reddy R, Vincent MJ (2021) Title of the article: Paranasal mucormycosis in COVID-19 patient. *Indian J Otolaryngol Head Neck Surg*. 2021:1–4. <https://doi.org/10.1007/s12070-021-02574-0>
- Sargin F, Akbulut M, Karaduman S, Sungurtekin H (2021) Severe rhinocerebral mucormycosis case developed after COVID-19. *J Bacteriol Parasitol* 12(1):1000386. Online available at <https://www.longdom.org>.
- Sarkar S, Gokhale T, Choudhury, Sana S, Deb, Kumar A (2021) COVID-19 and orbital mucormycosis. *Indian J Ophthalmol*. 69(4):1002–1004. <https://doi.org/10.4103/ijo.IJO>
- Sarkar S, Gokhale T, DA Sushmita Choudhury S (2020) COVID-19 and orbital mucormycosis. *Indian J Ophthalmol* 69(4):1002–1004. <https://doi.org/10.4103/ijo.IJO>
- Satish D, Joy D, Ross AB (2021) Mucormycosis coinfection associated with global COVID-19: a case series from India. *Int J Otorhinolaryngol Head Neck Surg*. 7(5):815. <https://doi.org/10.18203/issn.2454-5929.ijohns20211574>
- Sen M, Lahane S, Lahane TP, Parekh R, Honavar SG (2021) Mucor in a viral land : a tale of two pathogens. *Indian J Ophthalmol* (2). <https://doi.org/10.4103/ijo.IJO>
- Sharma S, Grover M, Bhargava S, Samdani S, Kataria T (2021) Post coronavirus disease mucormycosis : a deadly addition to the pandemic spectrum. *J Laryngol Otol*. 1–6. <https://doi.org/10.1017/S0022215121000992>
- Shastri S, Singh K, Deswal M, Kumar S, Mansotra V (2021b) CoBiD-Net: a tailored deep learning ensemble model for time series forecasting of Covid-19. *Spat Inf Res*. <https://doi.org/10.1007/s41324-021-00408-3>
- Shastri S, Singh K, Kumar S, Kour P, Mansotra V (2020) Time series forecasting of Covid-19 using deep learning models: India-USA comparative case study. *Chaos, Solitons Fractals* 140:110227. <https://doi.org/10.1016/j.chaos.2020.110227>
- Shastri S, Singh K, Kumar S, Kour P, Mansotra V (2021a) Deep-LSTM ensemble framework to forecast Covid-19: an insight to the global pandemic. *Int J Inf Technol*. <https://doi.org/10.1007/s41870-020-00571-0>
- Singh AK, Singh R, Joshi SR, Misra A (2021) Mucormycosis in COVID-19: a systematic review of cases reported worldwide and in India. *Diabetes Metab Syndr Clin Res Rev*. Published online May 21, 2021:1–7. <https://doi.org/10.1016/j.dsx.2021.05.019>

- Veisi A, Bagheri A, Eshaghi M, Rikhtehgar MH, Rezaei Kanavi M, Farjad R (2021) Rhino-orbital mucormycosis during steroid therapy in COVID-19 patients: A case report. *Eur J Ophthalmol*. 1–6. <https://doi.org/10.1177/11206721211009450>
- Waizel-Haiat S, Guerrero-Paz JA, Sanchez-Hurtado L, Calleja-Alarcon S, Romero-Gutierrez L (2021) A Case of fatal rhino-orbital mucormycosis associated with new onset diabetic ketoacidosis and COVID-19. *Cureus* 13(2):1–8. <https://doi.org/10.7759/cureus.13163>
- Werthman-Ehrenreich A (2020) Mucormycosis with orbital compartment syndrome in a patient with COVID-19. *Am J Emerg Med* 42:264.e5–264.e8. <https://doi.org/10.1016/j.ajem.2020.09.032>
- Zurl C, Hoenigl M, Schulz E et al (2021) Autopsy proven pulmonary mucormycosis due to *Rhizopus microsporus* in a critically ill COVID-19 patient with underlying hematological malignancy *J Fungi* 7:88–3. <https://doi.org/10.3390/jof7020088>

**Publisher's Note** Springer Nature remains neutral with regard to jurisdictional claims in published maps and institutional affiliations.