

Successful Liver Transplantation From a Deceased Donor With Vaccine-Induced Thrombotic Thrombocytopenia Causing Cerebral Venous Sinus and Hepatic Veins Thrombosis After ChAdOx1 nCov-19 Vaccination

Leonardo Centonze, MD,¹ Andrea Lauterio, MD, FEBS,¹ Riccardo De Carlis, MD,¹ Fabio Ferla, MD,¹ and Luciano De Carlis, MD, FEBS^{1,2}

Dear Editors,

ChAdOx1 nCov-19 vaccine has been associated with the development of a rare coagulation disorder, vaccine-induced thrombotic thrombocytopenia (VITT), that caused some fatalities due to cerebral venous sinus thrombosis (CVST).¹

On April 4, we were offered a liver graft from a donation after brain death (DBD) donor with CVST and hepatic veins thrombosis occurred after ChAdOx1 nCov-19 vaccination.

The 32-y-old female received the first dose 11 d before hospitalization. Computed tomography (CT) highlighted CVST and hepatic vein thrombosis (Figure 1). The donor presented thrombocytopenia with 35 000/mm³ platelets, 1.39 international normalized ratio, partial thromboplastin time of 36 s, elevated D-dimer of 120 800.0 µg/dL and hypofibrinogenemia with a value of 0.80 g/L, while liver function tests (LFTs) were normal.

SARS-CoV-2 reverse transcription-polymerase chain reaction assays of nasopharyngeal swab and bronchoalveolar lavage were negative; donor risk index (DRI)² and euro-transplant DRI (ET-DRI)³ were 1.37 and 1.46, respectively.

Considering the normal LFTs, the DRI/ET-DRI scores and the young donor age, we decided to evaluate the liver

graft; explicit informed consent to receive this graft was obtained from the recipient at the time of organ offer.

Liver procurement followed the standard technique: the liver presented sharp margins without congestion; no biopsy was performed due to the excellent macroscopic aspect of the liver graft.

The recipient was a 69-y-old female with multifocal hepatocellular carcinoma and HCV-cirrhosis with model for end-stage liver disease score of 8.

LT followed the piggyback technique; survival outcomes following liver transplantation⁴ and balance of risk⁵ scores were 6 and 3, respectively.

Immunosuppression included induction by basiliximab, tapered steroids, and tacrolimus.

Postoperative course was uneventful with rapid graft recovery. With the aim to resolve or at least prevent any evolution of the hepatic venous thrombosis, a prophylactic dosage of 4000 IU/d low molecular weight heparin (LMWH) was started after surgery. A CT scan on POD10 showed complete thrombus resolution in the right and left hepatic vein tributaries (Figure 1), and LMWH was therefore continued until discharge.

The recipient was discharged on POD15 and is under follow-up in outpatient setting with weekly LFTs, full blood count, and coagulative profile monitoring until POD30 and every 14 d until POD60. LMWH and steroids were discontinued on POD30 after ultrasonographic assessment of the hepatic veins/portal flows; latest LFTs (alanine aminotransferase: 23 U/L, bilirubin: 0.78 mg/dL, gamma-glutamyl transpeptidase: 18 U/L), platelet count (2 15 000/mm³), coagulation (INR: 1.01), and fibrinogen (3.2 g/L) performed 2 mo from LT are normal.

Institutional Review Board deemed that formal approval for publication was not required, considering the anonymous nature of this report.

This is the first report of successful LT from a DBD donor with CVST and hepatic veins thrombosis after ChAdOx1 nCov-19 vaccination.

The most interesting issues concerning this case were the possibility of clotting disorder transmission to the recipient and postoperative outcome of a liver graft affected by venous thrombosis that led to graft refusal from 4 transplant centers. It should be pointed out that this case was

Received 7 June 2021. Revision received 15 June 2021.

Accepted 17 June 2021.

¹ Department of General Surgery and Transplantation, Niguarda Ca' Granda Hospital, Milan, Italy.

² School of Medicine and Surgery, University of Milan-Bicocca, Milan, Italy.

The authors declare no funding or conflicts of interest.

L.C. and A.L. did transplant surgery, patient care, data collection, article drafting, and final revision. R.D.C. did patient care, data collection, article drafting, and final revision. F.F. did procurement surgery, patient care, data collection, article drafting, and final revision. L.D.C. participated in patient care and article final revision.

Correspondence: Leonardo Centonze, MD, Department of General Surgery and Transplantation, Niguarda Ca' Granda Hospital, Piazza dell'Ospedale Maggiore, 3, 20162 Milan, Italy. (leonardo.centonze@ospedaleniguarda.it).

Copyright © 2021 Wolters Kluwer Health, Inc. All rights reserved.

ISSN: 0041-1337/21/10510-e144

DOI: 10.1097/TP.0000000000003875

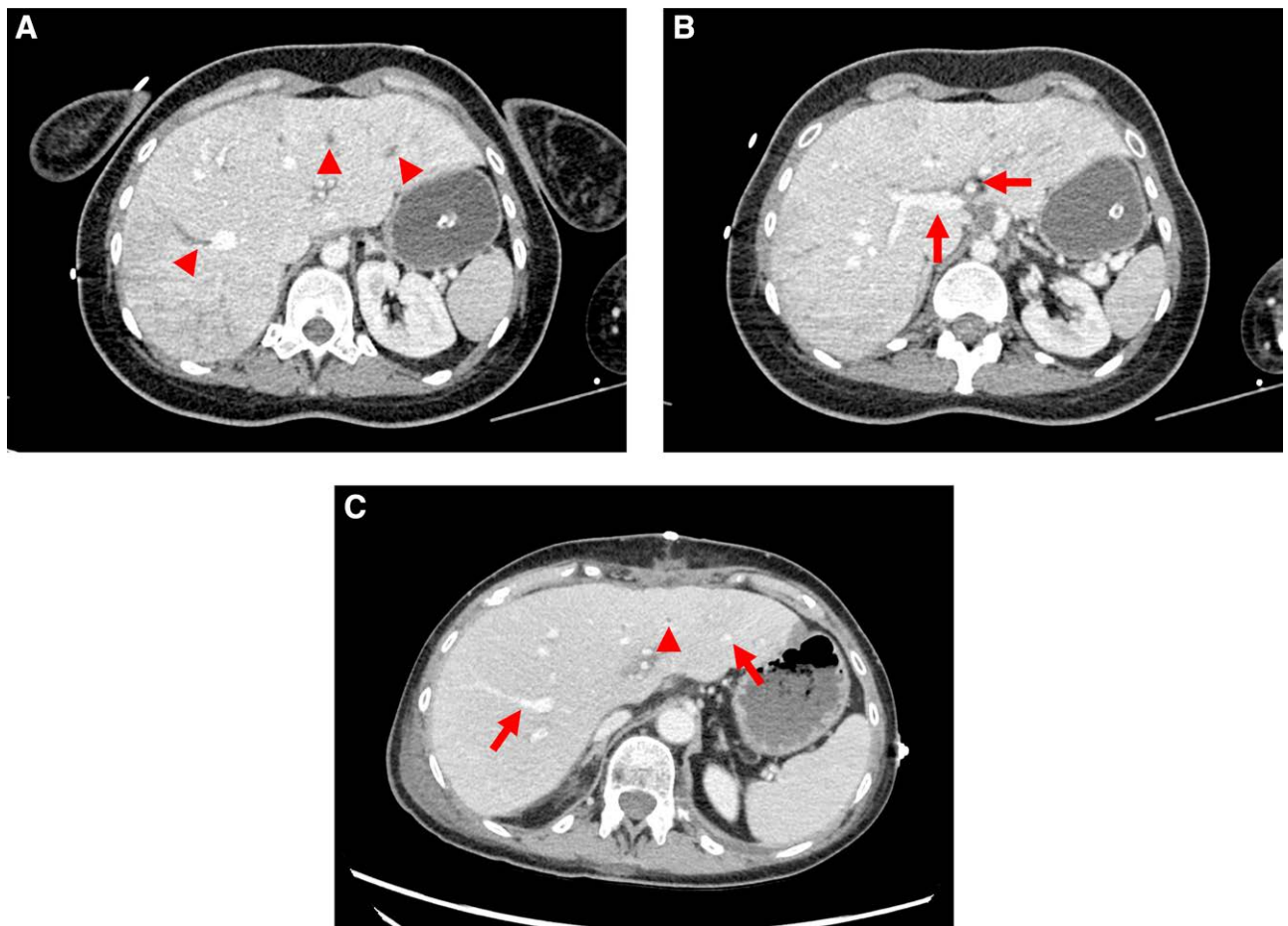


FIGURE 1. Donor and Recipient computed tomography. (A, B) Preoperative donor computed tomography showing thrombosis of peripheral tributaries of the right, middle, and left hepatic veins (arrowheads) and patent portal vein and hepatic artery (arrows). (C) Postoperative recipient computed tomography highlighting resolution of peripheral thrombosis in right and left hepatic vein tributaries (arrows), with persistence of a thrombus in a scissural branch of the middle hepatic vein (arrowhead).

managed before the publication of first studies that suggested the pathophysiology of VITT. Considering the lack of any literature, perioperative management did not differ from those of other DBDs: in particular, the donor did not receive intravenous immunoglobulin nor anticoagulants before procurement.

VITT has been defined as an autoimmune coagulative disorder causing platelet activation and clotting that may result in splanchnic/cerebral thrombosis.¹ Considering its immunological origin, VITT transmission after solid organ transplantation seems unlikely, as confirmed by our recipient's postoperative course. Despite hepatic venous thrombosis and previous refusal from other centers, the young donor age and the significantly low DRI/ET-DRI strongly influenced our decision to evaluate the graft: such attitude was reinforced during procurement considering the excellent macroscopic aspect of the liver.

Notably, CT scan performed after 10 d of LMWH therapy highlighted hepatic vein thrombosis resolution, supporting anticoagulation in this particular scenario.

Recent understanding of VITT pathophysiology and rising attention to early signs of splanchnic/cerebral

thrombosis will hopefully reduce other vaccine-related fatalities. On the other hand, the transplant community should be aware that LT from DBD donors after VITT-induced CVST has shown encouraging results, although further cases are needed to draw definitive conclusions.

REFERENCES

1. Greinacher A, Thiele T, Warkentin TE, et al. Thrombotic thrombocytopenia after ChAdOx1 nCov-19 vaccination. *N Engl J Med.* 2021;384:2092–2101.
2. Feng S, Goodrich NP, Bragg-Gresham JL, et al. Characteristics associated with liver graft failure: the concept of a donor risk index. *Am J Transplant.* 2006;6:783–790.
3. Braat AE, Blok JJ, Putter H, et al; European Liver and Intestine Transplant Association (ELITA) and Eurotransplant Liver Intestine Advisory Committee (ELIAC). The Eurotransplant donor risk index in liver transplantation: ET-DRI. *Am J Transplant.* 2012;12:2789–2796.
4. Rana A, Hardy MA, Halazun KJ, et al. Survival outcomes following liver transplantation (SOFT) score: a novel method to predict patient survival following liver transplantation. *Am J Transplant.* 2008;8:2537–2546.
5. Dutkowski P, Oberkofler CE, Slankamenac K, et al. Are there better guidelines for allocation in liver transplantation? A novel score targeting justice and utility in the model for end-stage liver disease era. *Ann Surg.* 2011;254:745–753.