



## Case Report

# Fatal recurrent ischemic stroke caused by vertebral artery stump syndrome

Akinari Yamano<sup>1</sup>, Yasunobu Nakai<sup>2</sup>, Kazuki Akutagawa<sup>1</sup>, Haruki Igarashi<sup>2</sup>, Kazuaki Tsukada<sup>1</sup>, Toshitsugu Terakado<sup>1</sup>, Kazuya Uemura<sup>2</sup>, Eiichi Ishikawa<sup>1</sup>

<sup>1</sup>Department of Neurosurgery, University of Tsukuba, <sup>2</sup>Department of Neurosurgery, Tsukuba Medical Center Hospital, Tsukuba, Ibaraki, Japan.

E-mail: Akinari Yamano - yamano.neurosurgery@gmail.com; Yasunobu Nakai - y-nakai@fg7.so-net.ne.jp; Kazuki Akutagawa - akutagawa-ymn@umin.ac.jp; Haruki Igarashi - i-haruki@dokkomed.ac.jp; Kazuaki Tsukada - kazuaki.t.1220@hotmail.co.jp; Toshitsugu Terakado - toshi\_0211jp@yahoo.co.jp; Kazuya Uemura - uemura@tmch.or.jp; \*Eiichi Ishikawa - e-ishikawa@md.tsukuba.ac.jp

### \*Corresponding author:

Eiichi Ishikawa,  
Department of Neurosurgery,  
University of Tsukuba, Tsukuba,  
Ibaraki, Japan.

[e-ishikawa@md.tsukuba.ac.jp](mailto:e-ishikawa@md.tsukuba.ac.jp)

Received : 19 April 2021  
Accepted : 20 July 2021  
Published : 06 September 2021

DOI  
10.25259/SNI\_384\_2021

### Quick Response Code:



## ABSTRACT

**Background:** Vertebral artery stump syndrome (VASS) develops into recurrent posterior circulation ischemic stroke after ipsilateral vertebral artery (VA) occlusion at its origin.

**Case Description:** The patient was a 46-year-old man with the right posterior cerebral artery occlusion. We used a recombinant tissue plasminogen activator (rt-PA) and then performed mechanical thrombectomy using a stent retriever. Angiography revealed left VA occlusion and stagnant flow to the left VA from the right deep cervical artery; therefore, we diagnosed VASS. Within 24 h of the rt-PA injection, the symptoms had dramatically improved, and so we avoided additional antithrombotic agents. Only 13 h later, the patient developed a basilar artery occlusion and died in spite of a repeated mechanical thrombectomy.

**Conclusion:** Vigilance against early (and sometimes fatal) recurrent stroke induced by VASS is required.

**Keywords:** Endovascular treatment, Ischemic stroke, Stroke, Vertebral artery stump syndrome

## INTRODUCTION

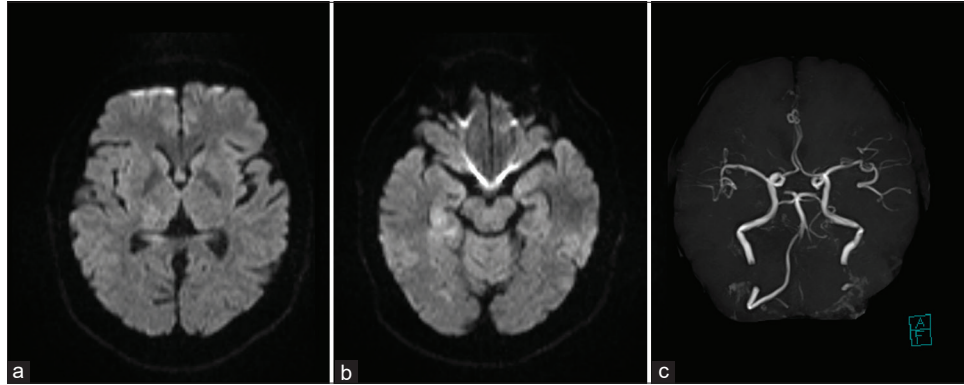
Vertebral artery stump syndrome (VASS) presents with recurrent posterior circulation (PC) stroke after ipsilateral vertebral artery (VA) occlusion at its origin.<sup>[1]</sup> Its pathophysiology is thought to derive from a stagnant thrombus distal to the VA occlusion caused by antegrade flow from the collaterals but effective treatment remains unestablished. Here, we report a case of basilar artery occlusion (BAO) that occurred only 13 h after intravenous recombinant tissue plasminogen activator (IV rt-PA) therapy.

## CASE DESCRIPTION

A 46-year-old man arrived at our emergency room with sudden, disturbed consciousness, left homonymous hemianopsia, left hemiplegia, and left hypoesthesia. The National Institutes of Health Stroke Scale (NIHSS) score was 10. Magnetic resonance (MR) diffusion-weighted imaging revealed slightly high-intensity signals in the right occipital lobe, right thalamus, and right hippocampus [Figure 1a and b] while MR-angiography showed the right posterior cerebral

This is an open-access article distributed under the terms of the Creative Commons Attribution-Non Commercial-Share Alike 4.0 License, which allows others to remix, tweak, and build upon the work non-commercially, as long as the author is credited and the new creations are licensed under the identical terms.

©2021 Published by Scientific Scholar on behalf of Surgical Neurology International

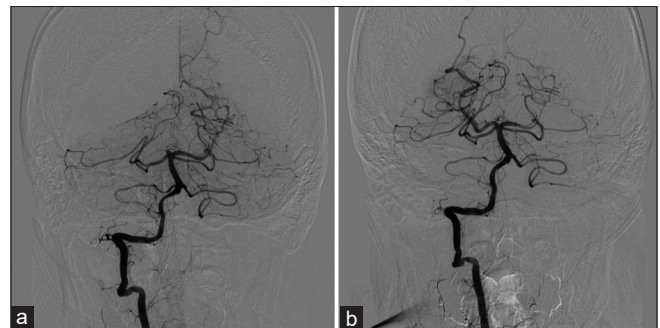


**Figure 1:** Diffusion-weighted imaging showing a slightly high-intensity area in the right occipital lobe, right thalamus, and right hippocampus (a and b). MR angiography showing right posterior cerebral artery occlusion at the P1 segment (c).

artery occlusion at the P1 segment and unclear blood flow in the left VA [Figure 1c]. We immediately started IV rt-PA and performed cerebral angiography, revealing a right P1 occlusion [Figure 2a]. We pursued mechanical thrombectomy with a stent retriever against the right P1 thrombus through the right VA. Complete first-pass perfusion was achieved and the thrombolysis in cerebral infarction (TICI) score was Grade 3 [Figure 2b]. Angiography also revealed a left VA occlusion from its origin [Figure 3a], with the left deep cervical artery anastomosed to the left VA and forming an antegrade stagnant flow to the proximal end of the left VA [Figure 3b and c]. After thrombectomy, the patient dramatically improved (NIHSS score of 1) and complained only of mild left-sided paresthesia. We assumed that the VASS had an embolic source but, given the 24-h window since rt-PA use, avoided additional anticoagulation therapy at that point. Thirteen hours after the thrombectomy, the patient developed generalized seizures then a decerebrate posture. CT showed a high-density thrombus in the BA while angiography further revealed BA occlusion, necessitating a repeat mechanical thrombectomy with a stent retriever [Figure 4a]. This thrombus was retrieved but new thrombi appeared repeatedly during the procedure. After 7 passes, we achieved TICI grade 2A partial reperfusion but blood flow to the cerebellum was absent [Figure 4b] and the left VA was still occluded from its origin. The patient died 3 h after the procedure.

## DISCUSSION

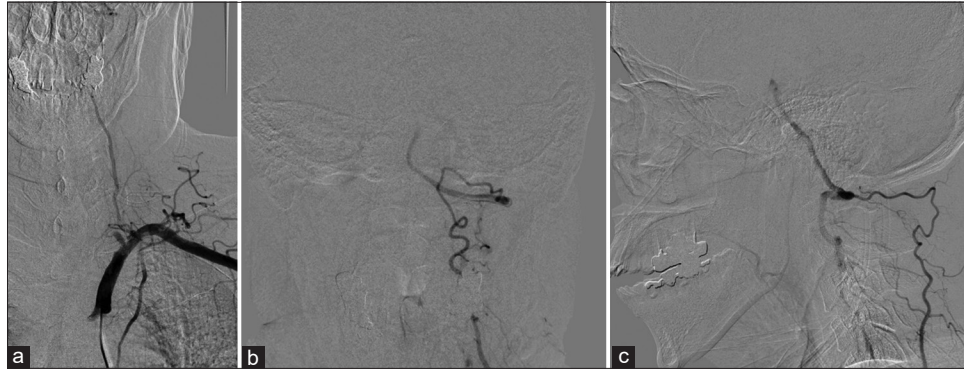
In 2008, Nguyen *et al.* reported two cases of recurrent PC stroke due to VA origin occlusion, calling it “VASS” because of the clinical similarities to carotid stump syndrome.<sup>[11]</sup> They hypothesized that the pathophysiology of this stroke was the embolism from the stagnant thrombus distal to the occlusion whereas the stagnant flow in the VA was caused by collaterals from the deep and ascending cervical arteries or



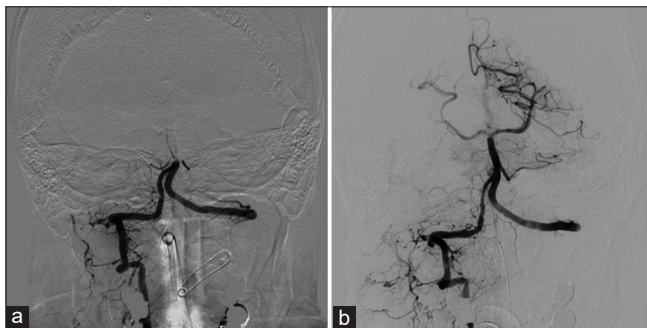**Figure 2:** Angiography before mechanical thrombectomy. The right posterior cerebral artery was occluded at the P1 segment (a). Angiography after thrombectomy. Thrombolysis in cerebral infarction 3 complete reperfusion was achieved (b).

the occipital artery. This anastomosis caused antegrade flow in the proximal side of the VA whose origin was occluded although the detailed fatal mechanism was unclear.<sup>[14,15]</sup> From this hypothesis, anticoagulation therapy may be effective for the prevention of recurrent ischemic events in VASS<sup>[9]</sup> as seen in a report of 12 such cases.<sup>[8]</sup> In that report, 1.2% of PC strokes were VASS-related, indicating that VASS is not a rare cause of PC stroke, but, since it is not recognized as causative for PC stroke, scarce reports exist. Given the lack of accumulated data, effective medical treatments for VASS remain controversial.

Intravenous rt-PA is known as an effective treatment for acute ischemic stroke<sup>[6]</sup> and mechanical thrombectomy is also effective for those cases where rt-PA is ineffective. In our case, mechanical thrombectomy was effective against VASS on the first attempt. Since VASS is believed to derive from embolism, thrombectomy may be efficacious but its efficacy and safety with regard to the PC has yet to be proven<sup>[5]</sup> since it cannot prevent recurrent ischemic strokes. After rt-PA use, additional antithrombotic treatment after rt-PA carries risks of hemorrhagic complications within the first 24 h,



**Figure 3:** Angiography of the left subclavian artery. The left VA was occluded from its origin (a). Anterior-posterior view (b) and lateral view (c) of angiography of the left subclavian artery. The left deep cervical artery was anastomosed to the left VA and its antegrade flow in the VA was stagnant. VA: Vertebral artery.



**Figure 4:** Angiography before the second thrombectomy. Basilar artery occlusion was revealed (a). Angiography after thrombectomy. Blood flow to the cerebellum other than the left posterior inferior cerebellar artery was absent (b).

as seen in<sup>[17]</sup> current AHA/ASA recommendations,<sup>[13]</sup> but some reports maintain that early antithrombotic therapy is safe.<sup>[1,7,16]</sup> Since our patient developed recurrent stroke within 24 h of rt-PA and symptoms dramatically improved, we avoided additional antithrombotic therapy after thrombectomy. We still believe that immediate intravenous rt-PA and mechanical thrombectomy for the distal thrombus using a stent retriever were also a candidate strategy for the “artery-to-artery” thrombus originating from VA occlusion in the present case. However, retrospectively, the early introduction of additional antithrombotic therapy might have prevented the recurrent stroke.

Endovascular treatment is reported to permanently prevent recurrent stroke, as seen when Nguyen *et al.* reported two cases of VASS treated with coil embolization to exclude the embolic source at the VA.<sup>[11]</sup> The coils were placed at the distal end of the VA thrombus, slightly proximal to the collateral flow to the VA while microcatheters were inserted from the contralateral VA or the collateral artery to the VA. After coil embolism, the stagnant flow at the VA disappeared and the two patients had no recurrent strokes during follow-up. On the other hand, Chen *et al.* reported 23 cases of VASS treated

with endovascular revascularization<sup>[2]</sup> in which a stent was placed in the proximal VA after balloon percutaneous transluminal angioplasty under the use of a distal protection device. The rate of successful technical revascularization was 91.3% and the rate of complication was 4.3%, results that held over a 3-month follow-up. Although these reports suggested the efficiency and safety of either embolization and revascularization treatment against non-acute VASS, small sample sizes reflect the need for further research and treatment against acute VASS was not reported.

There are several reports of endovascular treatment for BAO due to VASS.<sup>[3,4,10-12]</sup> Revascularization treatment (either angioplasty or stenting) is done during acute BAO, and Ecker *et al.* showed 100% (6 out of 6 patients) recanalization of the occluded VA prior to the acute BAO treatment.<sup>[4]</sup> In [Table 1], we summarize the data of patients who underwent endovascular treatment for VASS. In a previous report, patients with minor stroke, especially recurrent strokes, were treated electively while patients with major strokes, such as BAO, were treated radically, including revascularization of the occluded VA. In our case, the patient demonstrated right P1 occlusion, and mechanical thrombectomy was effective for the lesion. At that time, dramatic symptom improvement made us hesitate on additional acute phase treatment but the thrombus occluding the P1 segment could have been large enough for urgent VA embolization or revascularization. These treatments have some technical limitations. Coil embolization to exclude the embolic source needs access to the distal part of the occluded VA through collateral arteries or the contralateral VA.<sup>[11]</sup> The difficulty of the procedure depends on individual anatomical features and severe arteriosclerotic changes are expected in VASS patients. Revascularization of the occluded VA is also not simple since, unlike an acute artery occlusion, inability to traverse a lesion, dissection of the VA, and stroke due to distal embolization may complicate repairs. Preparation of appropriate guiding catheter support and distal protection devices is suggested,

**Table 1:** Summary of patients with endovascular treatment for VASS.

Reference	Cases	Type of stroke	Treatment	Timing	Recurrence	mRS						
						0	1	2	3	4	5	6
Nguyen, <i>et al.</i> (2008) <sup>[11]</sup>	2	Minor stroke	Embolization of VA	Nonacute	None	ND	ND	ND	ND	ND	ND	ND
Nii, <i>et al.</i> (2013) <sup>[12]</sup>	1	Minor stroke	VA angioplasty+stenting	Nonacute	None	ND	ND	ND	ND	ND	ND	ND
Ecker, <i>et al.</i> (2014) <sup>[4]</sup>	6	BAO	BA thrombectomy+VA stenting	Acute	None	0	2	1	1	0	0	2
Cohen, <i>et al.</i> (2016) <sup>[3]</sup>	7	BAO	BA thrombectomy+VA stenting	Acute	None	0	0	2	2	1	0	2
Maeoka, <i>et al.</i> (2020) <sup>[10]</sup>	1	BAO	BA thrombectomy+VA angioplasty	Acute	None	0	1	0	0	0	0	0
Chen, <i>et al.</i> (2020) <sup>[2]</sup>	23	Minor stroke	VA angioplasty+stenting	Nonacute	None	0	15	8	0	0	0	0
Our	1	P1 occlusion at the first event	P1 thrombectomy for the first event	Acute	Yes	0	0	0	0	0	0	1

VASS: Vertebral artery stump syndrome, mRS: Modified Rankin scale, BAO: Basilar artery occlusion, BA: Basilar artery, VA: Vertebral artery

but, as there are no best practice guidelines for this issue,<sup>[2,4]</sup> we hesitated to enact urgent radical treatment in the acute phase to avoid complications.

In our case, the stagnant flow at the VA continued to produce new thrombi despite IV rt-PA use. Because the volume from the VA origin to the anastomosis with the collaterals was relatively large, the stagnant flow had enough space to produce a large thrombus, which had the potential to occlude the BA. The possibility of recurrent stroke, including fatal BA occlusion, must be considered, especially in the acute phase, if antithrombotic therapy is withheld. Even though VASS is not a rare cause of PC stroke, only a few cases have been reported. The concept of VASS must be spread for the sake of accurate diagnosis and to accumulate case numbers sufficient for evaluating the efficacy and safety of early use of antithrombotic and/or radical endovascular treatment.

## CONCLUSION

In patients with PC ischemic stroke featuring VA occlusion, VASS, as a dangerous syndrome involving the risk of fatal recurrent stroke, must be considered as its embolic source. In the present case, fatal BA occlusion developed within 24 h of rt-PA use but administration of rt-PA restricted the early introduction of antithrombotic therapy. Vigilance against such fatal, recurrent strokes must therefore be maintained, particularly when antithrombotic therapy is restricted.

## Declaration of patient consent

The authors certify that they have obtained all appropriate patient consent.

## Financial support and sponsorship

Nil.

## Conflicts of interest

There are no conflicts of interest.

## REFERENCES

- Barreto AD, Alexandrov AV, Lyden P, Lee J, Martin-Schild S, Shen L, *et al.* The argatroban and tissue-type plasminogen activator stroke study: final results of a pilot safety study. *Stroke* 2012;43:770-5.
- Chen L, Jiang Y, Hu F, He L, Zheng H. Endovascular revascularization of nonacute symptomatic proximal extracranial vertebral artery occlusion. *World Neurosurg* 2020;134:39-44.
- Cohen JE, Leker RR, Gomori JM, Eichel R, Rajz G, Moscovici S, *et al.* Emergent revascularization of acute tandem vertebrobasilar occlusions: Endovascular approaches and technical considerations-Confirming the role of vertebral artery ostium stenosis as a cause of vertebrobasilar stroke. *J Clin Neurosci* 2016;34:70-6.
- Ecker RD, Tsujiura CA, Baker CB, Cushing D. Endovascular reconstruction of vertebral artery occlusion prior to basilar thrombectomy in a series of six patients presenting with acute symptomatic basilar thrombosis. *J Neurointerv Surg* 2014;6:379-383.
- Gory B, Eldesouky I, Sivan-Hoffmann R, Rabilloud M, Ong E, Riva R, *et al.* Outcomes of stent retriever thrombectomy in basilar artery occlusion: An observational study and systematic review. *J Neurol Neurosurg Psychiatry* 2016;87:520-5.
- Hacke W, Kaste M, Bluhmki E, Brozman M, Dávalos A, Guidetti D, *et al.* Thrombolysis with alteplase 3 to 4.5 hours after acute ischemic stroke. *N Engl J Med* 2008;359:1317-29.
- Jeong HG, Kim BJ, Yang MH, Han MK, Bae HJ, Lee SH. *Stroke*

- outcomes with use of antithrombotics within 24 hours after recanalization treatment. *Neurology* 2016;87:996-1002.
8. Kawano H, Inatomi Y, Hirano T, Yonehara T. Vertebral artery stump syndrome in acute ischemic stroke. *J Neurol Sci* 2013;324:74-9.
  9. Kawano H, Inatomi Y, Hirano T, Yonehara T, Uchino M. Anticoagulation therapy for vertebral artery stump syndrome. *J Neurol Sci* 2010;295:125-7.
  10. Maeoka R, Nakagawa I, Ohnishi H, Kuga Y, Nakase H, Ohnishi H. A thread of hope for successful revascularization for acute embolic basilar artery occlusion due to miserable vertebral artery stump syndrome. A technical report. *J Clin Neurosci* 2020;73:299-303.
  11. Nguyen TN, Raymond J, Mahmoud M, Weill A, Roy D, Guilbert F. Vertebral artery stump syndrome. *J Neurol Neurosurg Psychiatry* 2008;79:91-2.
  12. Nii K, Abe G, Iko M, Nomoto Y, Iwae Y, Sakamoto K, *et al.* Endovascular angioplasty for extracranial vertebral artery occlusion without visualization of the stump of the artery ostium technical note. *Neurol Med Chir (Tokyo)* 2013;53:422-6.
  13. Powers WJ, Rabinstein AA, Ackerson T, Adeoye OM, Bambakidis NC, Becker K, *et al.* 2018 Guidelines for the early management of patients with acute ischemic stroke: A guideline for healthcare professionals from the American heart association/American stroke association. *Stroke* 2018;49:e46-110.
  14. Suzuki M, Dembo T, Hara W, Tajima T, Yamashita M, Oji S, *et al.* Vertebral artery stump syndrome. *Intern Med* 2018;57:733-6.
  15. Tempaku A. Cerebral angiography directly visualizes to-and-fro stream of vertebral artery stump syndrome. *J Gen Fam Med* 2017;18:462-3.
  16. Von Kummer R, Hache W. Safety and efficacy of intravenous tissue plasminogen activator and heparin in acute middle cerebral artery stroke. *Stroke* 1992;23:646-52.
  17. Zinkstok SM, Roos YB; ARTIS Investigators. Early administration of aspirin in patients treated with alteplase for acute ischaemic stroke: A randomised controlled trial. *Lancet* 2012;380:731-7.

**How to cite this article:** Yamano A, Nakai Y, Akutagawa K, Igarashi H, Tsukada K, Terakado T, *et al.* Fatal recurrent ischemic stroke caused by vertebral artery stump syndrome. *Surg Neurol Int* 2021;12:445.