

## CASE REPORT

# Refractory pneumothorax secondary to COVID-19 treated by autologous blood patch pleurodesis

Y. Mitsuyama<sup>1\*</sup>, S. Tanaka<sup>2</sup>, A. Ike<sup>3</sup>, J. Tanaka<sup>1</sup> and S. Fujimi<sup>1</sup>

<sup>1</sup>From the Division of Trauma and Surgical Critical Care, Osaka General Medical Center, 3-1-56 Bandai-Higashi, Sumiyoshi-ku, Osaka 558-8558, Japan, <sup>2</sup>Department of Respiratory Medicine, Osaka General Medical Center, 3-1-56 Bandai-Higashi, Sumiyoshi-ku, Osaka 558-8558, Japan and <sup>3</sup>Department of Thoracic Surgery, Osaka General Medical Center, 3-1-56 Bandai-Higashi, Sumiyoshi-ku, Osaka 558-8558, Japan

\*Address correspondence to Y. Mitsuyama, MD, Division of Trauma and Surgical Critical Care, Osaka General Medical Center, 3-1-56 Bandai-Higashi, Sumiyoshi-ku, Osaka 558-8558, Japan. email: goto8940@gmail.com

## Learning points for clinicians

- Treatment strategies for refractory pneumothorax secondary to interstitial pneumonia after coronavirus disease 2019 (COVID-19) are challenging.
- Autologous blood patch pleurodesis for refractory pneumothorax secondary to COVID-19 is one of the treatment options.

Pneumothorax secondary to coronavirus disease 2019 (COVID-19) is not uncommon.<sup>1</sup> However, there is no well-established treatment strategy for refractory pneumothorax secondary to COVID-19 with persistent air leak. We report a case of refractory pneumothorax secondary to COVID-19 that was successfully treated by autologous blood patch pleurodesis.

## Case presentation

A 59-year-old man with no previous history of stopping smoking was admitted with moderate COVID-19, and oxygen and dexamethasone were administered (Figure 1A). Sixteen days after admission, he suffered a spontaneous left pneumothorax and drain management was begun. The drain was removed 24 days after admission. On hospital day (HD) 26, his respiratory condition deteriorated, and a computed tomography

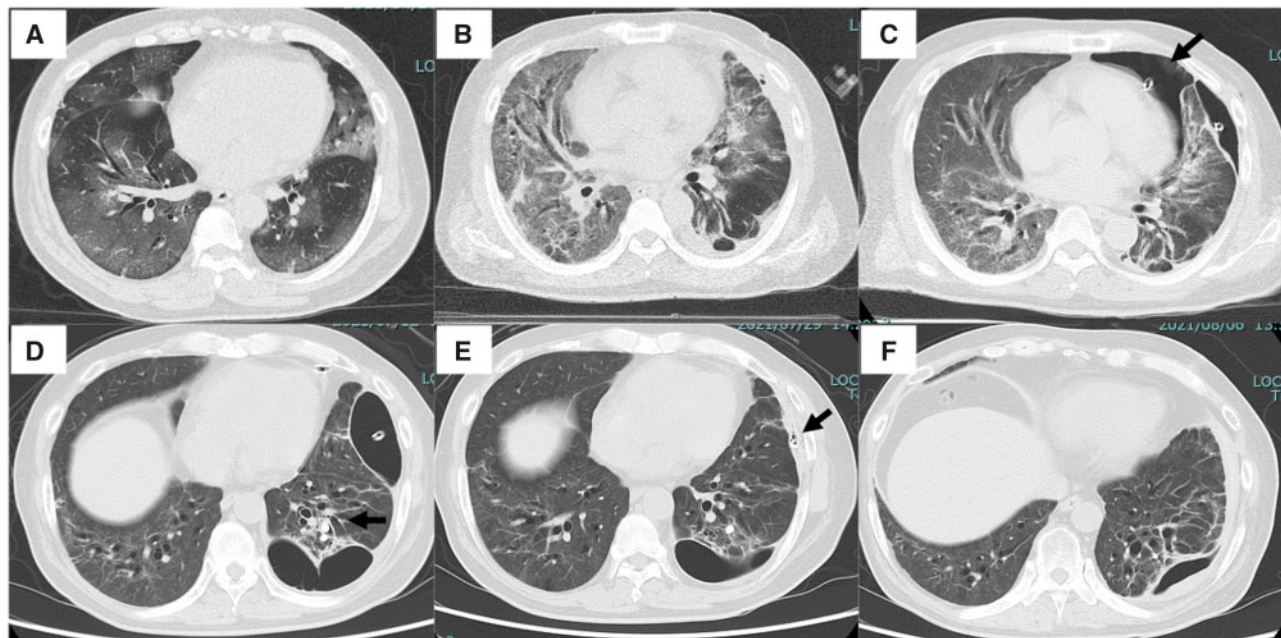
scan showed bilateral ground-glass opacities (Figure 1B). As there was no evidence of secondary bacterial infection, we diagnosed exacerbation of interstitial pneumonia after viral infection and started administration of steroids (prednisolone 1 mg/kg). On HD 36, the left pneumothorax recurred, and a chest drain was inserted. Because the patient was not fully decompressed, an additional drain was placed in the ventral pneumothorax cavity (Figure 1C). The patient underwent pleurodesis seven times with minocycline 200 mg and OK-432 5KE, but the air leak persisted. We performed endobronchial occlusion on branches of the left lower lobe three times. First, the left B10b was occluded using 7- and 5-mm endobronchial Watanabe spi-gots (EWS), followed by the left B10a using 5- and 6-mm EWS, and finally, by the left B10a using 5- and 6-mm EWS (Figure 1D). Nevertheless, the leak persisted, so four more pleurodesis procedures were performed with 200 ml of 5% glucose. The air leak decreased but remained, so 50 ml of the patient's own blood was injected into the pleural cavity via the drain on HD 90 and 96. The air leak finally ceased, and the drain was removed on HD 98 (Figure 1E). Thereafter, there was no recurrence of pneumothorax, and the patient was discharged home with induction of home oxygen therapy on HD 104.

## Discussion

There have been several reports of spontaneous pneumothorax in non-mechanically ventilated COVID-19 patients.<sup>1</sup> As in the case of a general spontaneous pneumothorax, the treatment of pneumothorax secondary to COVID-19 is by drainage

Submitted: 21 September 2021

© The Author(s) 2021. Published by Oxford University Press on behalf of the Association of Physicians. All rights reserved. For permissions, please email: journals.permissions@oup.com



**Figure 1.** Computed tomography (CT) images during the course of hospitalization. (A) CT image at hospitalization shows the presence of bilateral ground-glass opacities. (B) CT image on hospital day (HD) 25. The ground-glass opacities in the bilateral lung fields had expanded, indicating exacerbation of interstitial pneumonia. (C) CT image on HD 35. One additional drain was placed in the ventral pneumothorax cavity (arrow) because the single drain placed dorsally was insufficient for degassing. (D) CT image on HD 77. The air leak did not disappear despite endobronchial occlusion of branches of the left lower lobe (arrow). (E) CT image on HD 92. Autologous blood patch pleurodesis resulted in disappearance of the ventral pneumothorax cavity (arrow). (F) CT image on HD 100. The air leak from the dorsal drain had stopped, and the drain was removed.

management. Surgery is the standard treatment for pneumothorax with a recurrent or persistent air leak, but medical chemical pleurodesis may be an option when the underlying pulmonary disease is so severe that surgical intervention is not appropriate.<sup>2</sup> In the present case, the patient had secondary interstitial pneumonia caused by COVID-19 and was taking steroids and therefore was intolerant to surgery. Although pleurodesis was performed using various drugs, and bronchial embolization was performed in the middle of the process, it was difficult to achieve complete embolization due to bronchiectasis caused by the interstitial pneumonia. Importantly, autologous blood patch pleurodesis was effective in treating this pneumothorax with persistent air leak secondary to COVID-19. Persistent air leak can complicate the course of secondary spontaneous pneumothorax and can be a particularly difficult problem in patients who are deemed unfit for any surgical intervention.<sup>3</sup> Aihara et al.<sup>4</sup> reported that autologous blood patch pleurodesis is an effective and safe treatment for spontaneous pneumothorax due to pre-existing lung disease in patients who are not candidates for surgery. Autologous blood patch pleurodesis may be a treatment option for recurrent and refractory pneumothorax secondary to COVID-19.

## Informed consent

The patient described in this study provided informed consent for the publication of this study and for the use of his medical data.

*Conflict of interest.* None declared.

## References

- Martinelli AW, Ingle T, Newman J, Nadeem I, Jackson K, Lane ND, et al. COVID-19 and pneumothorax: a multicentre retrospective case series. *Eur Respir J* 2020; **56**:2002697.
- MacDuff A, Arnold A, Harvey J; BTS Pleural Disease Guideline Group. Management of spontaneous pneumothorax: British Thoracic Society Pleural Disease Guideline 2010. *Thorax* 2010; **65**(Suppl. 2):ii18–31.
- Dugan KC, Laxmanan B, Murgu S, Hogarth DK. Management of persistent air leaks. *Chest* 2017; **152**:417–23.
- Aihara K, Handa T, Nagai S, Tanizawa K, Watanabe K, Harada Y, et al. Efficacy of blood-patch pleurodesis for secondary spontaneous pneumothorax in interstitial lung disease. *Intern Med* 2011; **50**:1157–62.