


# The Use of Bone Grafts, Bone Graft Substitutes, and Orthobiologics for Osseous Healing in Foot and Ankle Surgery

Jonathan R. Peterson, MD<sup>1</sup> , Fangyu Chen, BS<sup>1</sup>,  
 Eugene Nwankwo, BS<sup>1</sup>, Travis J. Dekker, MD<sup>1</sup>,  
 and Samuel B. Adams, MD<sup>1</sup>

## Abstract

Achieving fusion in osseous procedures about the foot and ankle presents unique challenges to the surgeon. Many patients have comorbidities that reduce osseous healing rates, and the limited space and high weightbearing demand placed on fusion sites makes the choice of bone graft, bone graft substitute, or orthobiologic agent of utmost importance. In this review, we discuss the essential characteristics of grafts, including their osteoconductive, osteoinductive, osteogenic, and angiogenic properties. Autologous bone graft remains the gold standard and contains all these properties. However, the convenience and lack of donor site morbidity of synthetic bone grafts, allografts, and orthobiologics, including growth factors and allogenic stem cells, has led to these being used commonly as augments.

**Level of Evidence:** Level V, expert opinion.

**Keywords:** autograft, allograft, stem cells, bone marrow aspirate, PDGF, BMP, orthobiologics

Arthrodesis procedures remain the gold-standard treatment for end-stage arthritis and avascular necrosis of the foot and ankle. However, achieving fusion is not guaranteed, and nonunion results in clinically significant poorer functional outcomes compared to union. There are many factors associated with nonunion, including smoking, alcohol use, diabetes, peripheral neuropathy, infection, avascular necrosis, history of open fracture, and revision surgery.<sup>9,20,38,40,41</sup> Unfortunately, many of these comorbidities plague foot and ankle surgery patients requiring arthrodesis procedures, and the nonunion rate in these patients can be as high as 40%.<sup>1,9,20,38,40,41</sup> Moreover, in foot and ankle surgery, the purpose and importance of bone grafts is enhanced compared to other sites of fusion throughout the body due to high mechanical loads placed across fusion sites with weightbearing and limited space for grafts.

Therefore, it is not enough to just “fill a void,” but rather the graft itself needs to support an osseous healing response with the goal of forming union. Traditionally, autologous bone graft (ABG) from the iliac crest, tibia, or calcaneus has been considered the gold-standard bone graft because of its osteoconductive, osteoinductive, and osteogenic properties. However, ABG has limitations with regard to quantity, quality, donor site

morbidity, infection, and pain.<sup>3,4,10,28</sup> To this end, many bone graft substitutes, orthobiologics, and augments have been developed. Unfortunately, there is minimal level 1 evidence to support the use of many of the bone graft substitutes and orthobiologics available. Therefore, it is imperative that the treating surgeon know and understand the properties of these products. The purpose of this review is to summarize the current state-of-the-art on bone grafts and bone graft substitutes used in arthrodesis procedures about the foot and ankle.

## Bone Graft Properties

The 3 historical essential properties to successful osseous healing include osteoconduction, osteoinduction, and osteogenesis. However, 1 common theme among the previously

<sup>1</sup> Department of Orthopaedic Surgery, Duke University Medical Center, Durham, NC, USA

### Corresponding Author:

Samuel B. Adams, MD, Department of Orthopaedic Surgery, Duke University Medical Center, 4709 Creekstone Drive, Durham, NC 27703, USA.

Email: [samuel.adams@duke.edu](mailto:samuel.adams@duke.edu)



mentioned risk factors for nonunion is impaired vascularity. Therefore, we consider angiogenesis a fourth essential property of osseous healing. Here, we will briefly discuss these properties as it is important to understand them and realize that most bone graft substitutes or orthobiologics do not possess them all.

Osteoconduction is the ability to serve as a scaffold for the formation of new bone. Because bone is a structural soft tissue, a certain degree of stability is needed for new bone formation, especially when it comes to filling a gap between bone edges, such as at an arthrodesis site. Osteoprogenitor cells need a framework on which to attach to form new bone.

Osteoinduction is the property of encouraging new bone formation. Osteoinductive bone grafts are those in which pro-osteogenic factors are released into the host environment to actively induce mesenchymal stem cells and osteoprogenitor cells to become osteoblasts. There is a wide array of known pro-osteogenic cytokines and signaling molecules, including bone morphogenetic proteins (BMPs, specifically BMP-2, BMP-7, and BMP-12), platelet-derived growth factors (PDGFs), and other members of the transforming growth factor  $\beta$  (TGF- $\beta$ ) family.

Osteogenesis is the ability to form new bone. Osteogenic bone grafts are those in which actual cellular elements within the bone graft are capable of producing bone. There is debate about which cell population this includes. For example, mesenchymal stem/stromal cells could produce new bone but only after being induced (osteoinduction) down the osteoblast lineage. Therefore, strictly speaking, we consider osteogenic bone grafts to include cells that have already differentiated down the osteoblast lineage.

Another important characteristic of bone grafts is angiogenesis. Angiogenesis is the ability to form new blood vessels at the site of healing. Since the idea of angiogenesis regarding bone grafts is a modern one, we are unaware of a strict definition. For the purposes of this article, we will consider an angiogenic bone graft or substitute as one that contains cells or growth factors known to contribute to new blood vessel formation. There is some overlap in the osteoinductive cytokines mentioned above and those found in angiogenic materials.<sup>19,21</sup> The timing of angiogenesis to achieve bony union may be the most important in the initial few weeks.<sup>45</sup> Grafts that have angiogenic effects can be critical in developing the microenvironment that will be required to achieve bony fusion.

## Autologous Bone Graft

Autologous bone graft (ABG, autograft) can be cancellous bone, cortical bone, or a combined cortical-cancellous graft obtained most commonly from the iliac crest, tibia, or calcaneus. Cancellous bone carries many benefits, including high surface area with many osteogenic cells that allows for rapid incorporation. Cortical-cancellous grafts offer the same biologic benefits while also adding structural stability. ABG provides all 4 key aspects of bone grafts. It is

osteogenic and angiogenic with actual bone- and vessel-forming cells included in the graft. It is also osteoinductive, containing native osteogenic growth factors. Furthermore, it can be osteoconductive, providing a scaffold for bone cells and creeping substitution.<sup>36</sup>

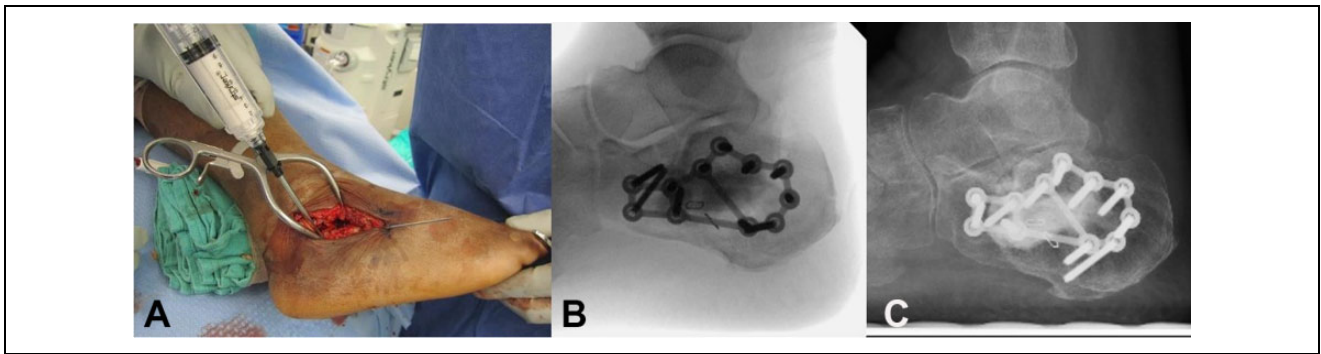
The donor location for ABG is an important consideration as bone harvested from different sites on the body can have markedly different potential for augmenting fusion. The amount of osteoblasts and osteoprogenitors in hematopoietic marrow varies among graft donor sites. For example, autograft from the tibia has been shown to contain fewer osteoblasts and a more fatty marrow than iliac crest bone graft, which is more osteogenic and angiogenic.<sup>10</sup> The calcaneus, another common source of autograft, has also been shown to be inferior with regard to osteogenic and angiogenic cells to iliac crest bone graft.<sup>28</sup> In general, it is easier to harvest ABG as you get farther from the axial skeleton, but the quality of ABG declines as the sources move from the axial to the appendicular skeleton.<sup>34</sup>

Beyond the location of the donor graft, many host factors affect ABG quality. Increasing age, female sex, and medical comorbidities all decrease the number and/or quality of the cellular component of ABGs.<sup>50,51</sup> Interestingly, the local vascularity of the tissues from which the autograft is taken can affect the ultimate efficacy of the autograft; the more well vascularized the donor site, the better.<sup>8</sup> The ultimate autologous graft is the free vascularized bone flap. The transfer of living osteocytes in structural bone with already intact vascularity can promote the potential for healing in the most difficult situations. Free fibula, free iliac, and medial femoral condyle free flaps have been used in the foot and ankle. A review of these different flaps is beyond the scope of this review, but they have been successfully used for the treatment of avascular necrosis, large bony defects, and persistent nonunions.<sup>23</sup>

There are drawbacks common to all autograft harvest procedures. Combined major and minor complications and donor site morbidity have been reported to occur in 15% to 49% of cases.<sup>3,4</sup> Complications of harvesting bone from the iliac crest can include infection, lateral femoral cutaneous nerve injury, bowel injury, hernia, prolonged pain, and hematoma. The amount of autograft able to be obtained is also an important consideration when using ABGs. Large grafts of 3 to 4 cm in length and width can be obtained only from the iliac crest. Expense due to equipment cost (eg, with use of the Reamer Irrigator Aspirator [RIA] device), added operative time, and surgeon costs also have been cited as drawbacks to autograft when compared to synthetic or osteobiologic alternatives.<sup>15,43</sup>

## Synthetic Bone Grafts

Synthetic bone grafts typically only have the property of osteoconduction. Their synthetic nature allows for low cost, ready availability, and multiple physical forms, which include pellets, powder, putty, and as coatings on implants. However, they are not as potent or reliable at ensuring a



**Figure 1.** (A) Intraoperative photograph and (B) fluoroscopic image of the use of a calcium phosphate product to fill a void in the calcaneus after open reduction and internal fixation. (C) The calcium phosphate can still be seen after 6 months.

successful arthrodesis due to the lack of any osteogenic, osteoinductive, or angiogenic properties. They instead rely wholly on the ability of the patient to generate adequate bone at the fusion site.

Calcium sulfate is a widely used synthetic bone graft that is available in multiple forms, including liquid and malleable putty that solidifies after implantation. This allows for sculpting of complex shapes and even percutaneous injection into bone voids. This can be a major advantage in foot and ankle surgery, in which any reduction in the size and extent of incisions is welcome and may help avoid wound complications. One major drawback is the rapidity at which the graft is resorbed, which can be on the order of 1 to 3 months. This is often faster than new bone can be formed to replace it and may result in seromas or dead space and serous wound drainage.<sup>24</sup>

Calcium phosphate is another calcium salt derivative that comprises a family of synthetic bone grafts used in fusion surgery. Like calcium sulfate, mono- and dicalcium phosphate are available in a wide variety of forms. Resorption is much slower compared to calcium sulfate, taking at least 6 months and up to 10 years in some instances (Figure 1). One major advantage is their impressive compression strength, which is higher than that of cancellous bone. Tricalcium phosphate more approximates the compressive characteristics of cancellous bone and is notable for its superior ability to allow for bony ingrowth. It does not come in a putty form and is known to be particularly brittle.<sup>49</sup>

Coralline hydroxyapatite is another available graft similar to calcium phosphate. Hydroxyapatite itself is a major component of native bone, making up nearly 50% of its weight. In graft form, it is available as solid blocks or granules. It is also known to be brittle but does have compressive strength that approximates cancellous bone. There are ceramicized and nonceramic hydroxyapatite grafts that affect its resorption rate with the ceramic form being much slower to resorb (can be >10 years) than the nonceramic form.<sup>49</sup>

Bioactive glass grafts are synthetic, silica (SiO<sub>2</sub>)-based substances that form chemical bonds to bone and the surrounding soft tissue. They release ions, including Si<sup>+</sup>, Na<sup>+</sup>, and Ca<sup>2++</sup>, that react with interstitial fluid to enhance the

deposition of calcium phosphate on the bone surface. It is the subsequent deposition of the calcium phosphate that enhances the attachment of osteoblasts to the site. Bioactive glass is available in solid and particulate forms that have varying rates of bioactivity, due largely in part to the proportion of SiO<sub>2</sub> they contain, which helps osteoblasts attach to bone surface.<sup>53</sup>

## Demineralized Bone Matrix

Demineralized bone matrix (DBM) is an allograft bone product. Human bone sources are processed with acid extraction to remove cells and soft tissues and gamma irradiated to remove virus, bacteria, and fungus matter. What is left are the calcium-containing solids, inorganic phosphates, cell debris, and the proteinaceous components of bone.<sup>22</sup> The bulk of the solid matter that has been acellularized is the osteoconductive portion of bone. It exists in a myriad of forms, including structured blocks, flexible sheets, putty, paste, and gel. In addition to the abundant volume available without concern for donor site morbidity, the diversity of material form lends itself well to use in the limited-space environment of foot and ankle arthrodesis.

Another beneficial aspect of DBM is the protein component of the graft that may have some osteoinductive properties. Osteoinductive proteins, including osteocalcin, osteopontin, BMPs, insulin-like growth factors (IGFs), and other members of the TGF- $\beta$  family, have been isolated from DBM. There are no current industry standards for measuring the amounts of these osteoinductive compounds in any given lot or product. Most studies of these grafts *in vivo* have been done in animal models. From these studies, it seems that the degree of osteoinductivity in a graft is dependent on the health of the donor. The osteoinductive properties of DBM have been shown to correlate inversely with donor age in several *in vivo* studies.<sup>32,56</sup> Conflicting reports exist on the actual content of BMPs in DBM, with some showing no significant correlation between age and actual BMP content and others showing a significant difference in some BMPs.<sup>27,42</sup> Significant differences have also been reported

with regard to the sex of the donor, with DBM from female sources having a higher concentration of BMP.<sup>42</sup>

However, the naturally occurring levels of BMP-2 in cortical bone are in the nanogram per gram level and may have a negligible effect on the overall efficacy of the graft. These differences in donor attributes, no standardized intracorporate standards for demineralization processing, or assays for efficacy of processed lots must be taken into consideration when selecting an appropriate graft for use in foot and ankle surgery. Some of the earliest reports of their use in arthrodesis about the foot and ankle have included ankle and triple arthrodesis, segmental lengthening, and revision of nonunions.<sup>31,35,55</sup>

## Orthobiologics

While autograft and the synthetic bone grafts described above have been in use for many years, recent research has focused on understanding the specific biochemical pathways that lead to new bone formation. Osteobiologics represent the group of substances that aim to take advantage of the body's endogenous osteosynthetic capacity. Thus, most of the available osteobiologic additives are local growth factors that are typically involved in bony repair. These compounds are osteoinductive in that they initiate and/or enhance the natural bone-forming process. Examples include BMPs, PDGF, vascular endothelial growth factor (VEGF), and TGF- $\beta$ . Given that these products are newer, reportedly more purified, and potent, as well as the focus of a significant amount of ongoing research, they are also often relatively expensive and sometimes controversial.<sup>39</sup>

Bone morphogenetic proteins are members of the TGF- $\beta$  superfamily and have been the subject of extensive orthopedic research for the past 50 years. There are over 20 identified types, most having osteogenic properties, with BMP-2, BMP-4, and BMP-7 being the most well studied. BMP-2 and BMP-7 are the only subtypes currently available commercially for application in orthopedic surgery. From these products, a multibillion-dollar market has arisen.<sup>39</sup> The net effect of BMPs is to cause mesenchymal stem cells to differentiate into osteoblasts.

Currently, BMP-2 is approved by the US Food and Drug Administration (FDA) for 2 purposes: for anterior lumbar interbody fusion (ALIF) with BMP-2 inserted into titanium cages and for acute, open tibial shaft fractures.<sup>47</sup> BMP-7 is used for nonunions of long bones and failure of spinal fusions as a Humanitarian Device Exemption through the FDA. Off-label uses of these powerful and potent recombinant molecules are common in orthopedic fields, including foot and ankle surgery.

There have been several studies regarding the efficacy and safety of BMP use in fusions about the foot and ankle. One report retrospectively chronicled ankle or hind foot arthrodesis in 69 patients who were classified as "high risk" based on comorbid factors, including diabetes, chronic infection, smoking, alcohol, high-energy injuries or multiple

trauma, collagen disorders, and multiple medical comorbidities.<sup>7</sup> Recombinant human BMP-2 (rhBMP-2) was included in the fusion surgery in all patients; some also received autograft. The fusion rate at 112 arthrodesis sites in the 69 patients was 96%, with a mean fusion time of 11 weeks postoperatively by computed tomography (CT) scan. One hundred percent of ankle arthrodesis sites were fused with the addition of BMP-2. Interestingly, there were no differences between groups that received autograft in addition to BMP and those that did not. This fusion rate was compared to a prior study of subtalar fusion rates in 15 patients without high-risk characteristics and included the use of proximal tibia cancellous autograft, which showed only 48% fusion in these patients at 12 weeks postoperatively.<sup>12</sup> The authors also noted no significant increase in complication rates with the use of rhBMP-2.

In a similar study of high-risk patients,<sup>44</sup> 51 fusion sites treated with rhBMP-2 in 48 patients, including several with prior fracture nonunion, were retrospectively reviewed. These patients also received a mix of autograft and allograft. A similar overall fusion rate of 95% was observed with the use of rhBMP-2. Interestingly, all nonunions occurred in patients who had prior nonunions. A low complication rate was observed with rhBMP-2, including a 2% infection rate and delayed wound healing in 8% of patients.<sup>44</sup>

One controversial feature of BMP use that has been heavily debated and studied is the risk of cancer. In addition to the known osteogenic activities of BMPs, they are also trophic growth factors, and several members of the BMP family have neoplastic properties, including BMP-2, which has been shown to stimulate growth in prostate cancer. Both BMP-2 and BMP-7 have been shown to induce metastasis.<sup>5</sup> Conversely, these same BMP family members have also been shown to have anticancer activities and inhibit metastasis, growth, and proliferation.<sup>52</sup> While the number of studies using BMP specifically in foot and ankle surgery is still few, there has not been any reported evidence of cancer after BMP use in fusion surgery. Another potential drawback to BMP use is the possibility of excess bone formation. Most documented adverse effects relating to ectopic bone are found in the literature relating to spine surgery, in which robust bone formation can cause radiculitis due to nerve root compression with an incidence as high as 14%.<sup>29,48</sup> Similar complications from excessive bone formation have not been widely documented in foot and ankle surgery. While there have not been any randomized controlled trials, BMP appears to be effective in the promotion of fusion in high-risk arthrodesis about the foot and ankle.

PDGF is a potent modulator of inflammation and tissue repair. As its name indicates, PDGF is made and stored in platelets and released during platelet degranulation in the acute phase of the inflammatory response. Its effect is important throughout the initial bone-healing process. The primary influence of PDGF is felt in the early phase of bone healing as it promotes chemotaxis of inflammatory cells,

mitogenesis of mesenchymal stem cells, and angiogenesis. These key factors are critical in the formation of soft callus and setting the stage for complete bony fusion.<sup>19</sup> PDGF does not have any nascent osteoconductive properties, so it is commercially available packed with  $\beta$ -tricalcium phosphate to act as a scaffold for bone formation.

In foot and ankle surgery, the safety and efficacy of PDGF have been demonstrated in several studies. In a randomized control trial of 20 patients comparing recombinant human PDGF (rhPDGF) with a  $\beta$ -tricalcium phosphate carrier to autograft in ankle or hindfoot fusions, there was radiographic evidence of union in 50% of patients with autologous bone graft and 77% of patients with PDGF after 9 months.<sup>18</sup> A similar study with 63 patients randomized to receive PDGF compared to a control group consisting of 12 patients prospectively randomized to receive autograft, combined with 142 patients from another study with similar protocol, showed fusion rates of 84% in the PDGF group and 65% in the autograft group. The primary end factor again was radiographic evidence of fusion. This study also assessed clinical outcomes based on visual analog scale (VAS) score and lack of need for any secondary procedure after 1 year and demonstrated 91% of patients with PDGF fusions achieving clinical success compared to 78% of those treated with autograft.<sup>14</sup>

In another prospective randomized controlled trial (RCT) from the North American Orthopedic Foot and Ankle Study Group, 434 patients were randomized (2:1) to rhPDGF or autograft-augmented fusion of the ankle or hindfoot. In the cohort that received rhPDGF, the fusion rate, as determined by CT scan at 6 months, was 62.0% (159/260 patients). The fusion rate for the autograft cohort at this time point was similar at 62.6% (85/137 patients). Efficacy rates between groups were comparable, with clinical healing status of 87.7% for those receiving PDGF and 88.3% for those receiving autograft. The main clinically relevant difference in outcomes between these groups was the lack of donor site pain and morbidity in the group that did not have autologous graft harvest. In terms of complications, there was no significant difference between the groups in any of the studied parameters, including serious/emergent events, wound complications, or device-related complications.<sup>19</sup>

Similar to the use of rhBMP as discussed above, there has been concern about the potential for cancer risk with the use of rhPDGF. These concerns are founded on the potent mitogenic and angiogenic effect of this bioactive molecule. In a 2013 RCT study, the occurrence of cancer was not significantly different with the use of PDGF vs autograft (1.1% in the PDGF group and 1.4% in the autograft group). While this represents only 1 year of follow-up in a limited sample size, it is the largest RCT studying rhPDGF in arthrodesis.<sup>19</sup> The authors also note that there has been concern about the cancer risk of a topical application of PDGF (becaplermin) that is used for nonhealing diabetic foot ulcers. However, in a large matched cohort study of 1622 patients, there was no increase in incidence of cancer in the 6-year follow-up

period.<sup>57</sup> There was a subgroup that used a large amount of the topical preparation (3 tubes), and in this group, there was a significant difference in mortality from preexisting malignancies.<sup>46</sup> Due to this finding, the FDA did issue a warning regarding the excessive use of becaplermin. No such findings or warnings have been issued regarding the use of rhPDGF in arthrodesis.

Concentrated bone marrow aspirate (CBMA) theoretically contains cells with osteogenic and angiogenic potential. The mesenchymal stem cells in bone marrow have nascent osteogenic potential and are also osteoinductive. Endothelial progenitors in bone marrow aspirate are angiogenic. Platelets are also contained in the aspirate, which contains the growth factors described above that may be beneficial in arthrodesis. A myriad of growth factors in CBMA have powerful osteogenic and angiogenic effects, including BMP, PDGF, TGF- $\beta$ , and VEGF.<sup>33</sup> However, CBMA alone does not have osteoconductive properties and must be mixed with another graft to have all 4 properties.

One critical step in the processing of CBMA that sets it apart from autologous bone grafting is the concentration phase, which is key for its successful application. In 1 study, CBMA was harvested from the anterior iliac crest and implemented at a tibial nonunion site in 60 patients. On average, about 300 mL of aspirate was collected in total from bilateral iliac crests. Concentration by centrifugation reduced the volume to an average progenitor-containing buffy coat of 50 mL. An average of 20 mL of this CBMA was injected into the tibial nonunion site. Prior to concentration, there was an average of 612 progenitor cells in each milliliter of aspirate. After concentration, the CBMA contained an average of 2579 progenitor cells. There was a strong association between the concentration of progenitor cells and success of the union.<sup>26</sup>

Another important factor in the efficacy of CBMA is the location of the harvest. In general, the concentration of osteoprogenitors in a bone marrow aspirate increases the closer the harvest site is to the axial skeleton. Vertebral bodies have been shown to have the highest concentration, but harvest from the vertebral bodies is not feasible for routine use.<sup>34</sup> While iliac crest has been well studied, other locations are convenient targets during foot and ankle surgery. In 1 study, bone marrow aspirate was obtained from the iliac crest, distal tibial metaphysis, and calcaneal body in 40 patients. These samples were concentrated by centrifugation and then grown in culture. Alkaline phosphatase stain identified osteoblastic progenitors, which were quantified by harvest site. The concentration of osteoprogenitor cells was significantly higher than other sites at 898 cells/mL from the iliac crest, 32 cells/mL from the tibia, and 7 cells/mL from the calcaneus.<sup>28</sup> The difference between the calcaneus and distal tibia was not significant, but the trend of decreasing concentration of osteoprogenitors in CBMA as you move distally from the axial skeleton is a common theme in all these studies.

CBMA has been shown to be an effective augment in obtaining union in several procedures about the foot and ankle. Certain fractures of the fifth metatarsal are known to have increased risk of nonunion, including zone 2 (Jones) fractures, which occur in a vascular watershed area. In 1 study comparing zone 2 and zone 3 fractures, the authors note that zone 3 fractures treated nonoperatively also carry a high nonunion rate up to 25%.<sup>13</sup> In their case series of 26 athletes, they employed screw fixation with application of CBMA harvested from ipsilateral iliac crest. Their overall union rate was 96% complete bony union at 8 weeks.<sup>37</sup> The authors do not compare union rates with CBMA against screw fixation alone, but a mean healing time of 5 weeks in high-demand patients is compelling. However, there was no control group.

There also have been reports of CBMA efficacy in nonunions about the foot and ankle. One report demonstrated success with the application of CBMA through a cannulated screw into a stress fracture nonunion site. CBMA was harvested from the ipsilateral iliac crest and injected through a cannulated screw during operative fixation of a medial cuneiform nonunion.<sup>2</sup> Union of the fracture was confirmed by CT scan at 10 weeks postoperatively.

In another case-control study, 86 patients with diabetes and ankle fracture nonunions treated with CBMA augmentation were matched to 86 historical patients with diabetic ankle nonunions treated with autograft. They found a higher rate of union (82% vs 62%) with the use of CBMA. They also looked at major and minor complications after surgery and found a lower rate of minor complications (2% vs 10%) and major complications, including amputations, osteonecrosis, and wound infection (0% vs 12%).<sup>25</sup>

Platelet-rich plasma (PRP) has been studied in a wide array of orthopedic problems. Platelets are known to play an integral role in the normal acute healing response. After injury, platelets are critical in clot formation. They also contain a multitude of growth factors, contained in  $\alpha$ -granules, including PDGF, TGF- $\beta$ , IGF, and VEGF. These factors are important in osseous healing and induce chemotaxis, mitogenesis, vasculogenesis, and angiogenesis.<sup>21</sup> These factors are all critical in the acute phase of bone healing; their roles in chronic healing are less well defined. PRP is formed by centrifugation of venous blood. Collection is simple, and there is typically a large enough intravascular reserve to obtain adequate sample volume. There is a large variation in processing techniques between centrifugation protocols and commercially available kits, which can result in variations in concentration of platelets and leukocytes. There is no current standard to normalize the bioactivity of PRP isolate.

In foot and ankle surgery, PRP has been studied most extensively in osteochondral lesions of the talus, Achilles tendinopathy, and plantar fasciitis. While there have not been many studies focusing specifically on arthrodesis, there are several studies looking at osseous healing in the foot and ankle with PRP augmentation. One study looked at 62

patients undergoing elective osseous foot and ankle procedures (mostly fusions) who had risk factors for nonunion. All patients received PRP, which was either used alone or in combination with autograft or allograft bone if there was an osseous defect to fill. The overall union rate was 94%, and no difference in time to fusion was seen between the use of PRP alone or when used in combination with bone graft.<sup>6</sup>

PRP has been reported to augment syndesmosis fusions in patients receiving total ankle replacements. The authors of this study cite a nonunion rate of up to 38% with standard treatment. They compared a group of 66 patients who received PRP augmentation of the syndesmosis fusion to a group of 114 who underwent standard syndesmosis fusion. The standard fusion group had a nonunion rate of 15% while the nonunion rate in the group that received PRP was significantly lower at 3%.<sup>11</sup>

In another study, PRP was used to augment allograft bone graft in displaced, articular calcaneus fractures. All patients with type III calcaneus fractures over a 7-year period were randomized to either receive autograft (101 patients), allograft + PRP (85 patients), or allograft alone (90 patients). All fractures had healed within 12 months. The authors continued follow-up and compared American Orthopaedic Foot & Ankle Society (AOFAS) outcome scores at 2 and 6 years postoperatively. Allograft alone compared to autograft showed significantly worse outcomes at these time points. However, the group that received allograft with PRP augmentation showed comparable results to the autograft cohort.<sup>54</sup>

## Allograft/allogenic Stem Cell Products

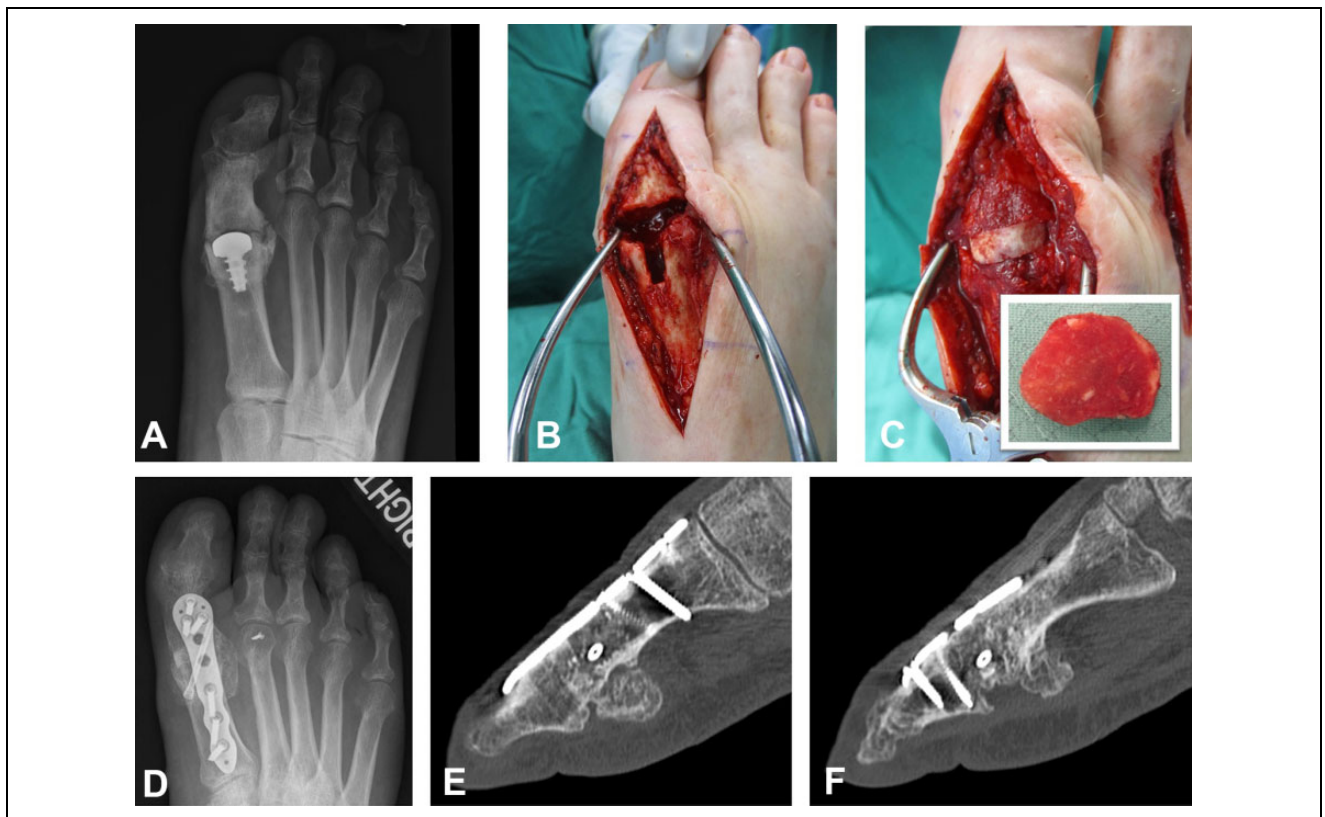
Bone autograft remains the gold standard to which other fusion adjuncts are measured. None of the other orthobiologics exhibit all the factors that contribute to improved fusion rates—namely, being osteoconductive, osteoinductive, osteogenic, and angiogenic (Table 1). Allogenic stem cell products contain multipotent adult progenitor cells that have osteogenic and varying claims of angiogenic properties. The cells are also active in producing osteoinductive factors. The grafts can also retain the cancellous and/or cortical bone from the harvest source and act as an osteoconductive scaffold. The adult stem cell portion is obtained immediately postmortem and cryogenically preserved (Figure 2).

A prospective trial of 92 patients without stratification by risk factors or comorbidities was completed in which all patients received arthrodesis by standard surgical procedure with inclusion of allogenic mesenchymal stem cell graft. The primary end point was fusion at 6 months as demonstrated on CT and radiographs. At 6 months, the fusion rate was 68.5% of all patients (81.1% of all joints). Within the cohort, there were no differences in fusion rates between high-risk patients and patients without high-risk characteristics, except for smoking, in which there was a statistically significant risk of nonunion, despite the use of allogenic stem cell graft.<sup>30</sup>

**Table 1.** Essential Osseous Healing Properties of Bone Grafts, Bone Graft Substitutes, and Orthobiologics.

Graft	Osteoconduction	Osteoinduction	Osteogenesis	Vasculogenesis	Total No. of Properties <sup>a</sup>
Synthetics (calciums, bioactive glass)	+				1
Bone morphogenic protein		+			1
Platelet-rich plasma		+		+	2
Demineralized bone matrix	+	+			2
Cancellous allograft chips	+	+			2
Platelet-derived growth factor		+		+	2
Concentrated bone marrow aspirate		+	+	+	3
Stem cell allografts	+	+	+	+	4
Cancellous/cortical cancellous autograft	+	+	+	+	4

<sup>a</sup>For single graft, combining grafts can increase number of properties.



**Figure 2.** (A) An example of the use of a stem cell allograft. The patient is 49-year-old man with a failed first metatarsophalangeal (MTP) joint arthroplasty. A first MTP joint arthrodesis was performed. (B) There was a 5-mm gap that was (C) filled with an iliac crest allograft (C) from which (insert) the cancellous center was removed and packed with a stem cell allograft product. Arthrodesis was achieved by 4 months after surgery, as can be seen on (D) an anteroposterior radiograph and (E, F) computed tomography scan imaging.

In a retrospective series of 23 patients undergoing arthrodesis surgery with allogenic stem cell graft, 74% of these patients had at least 1 high-risk factor. The overall fusion rate in this cohort was 82.6%, as determined by review of radiographs and CT scans.<sup>16</sup> Another study by the same group looked at 40 fusions or nonunion revisions in 36 patients with high-risk features. A similar fusion rate was observed with the use of allogenic stem cell graft with 83% of fusion sites obtaining radiographic fusion. The presence of diabetes and female sex were independent risk factors that showed independent significance for nonunion.<sup>17</sup>

## Summary

Arthrodesis about the foot and ankle presents unique challenges to the orthopedic surgeon. Well-documented risk factors are common in patients requiring joint fusion that portend nonunions and wound complications. The need for effective augments in fusions about the foot and ankle is compounded by the limited-space environment and high demand that full-body weightbearing puts on fusion. The characteristics of bone graft and orthobiologics that are important to successful fusion include being osteoconductive, osteoinductive, osteogenic,

and angiogenic (Table 1). While angiogenesis has not traditionally been included in the classification scheme of bone graft options, its importance in achieving fusion has become more salient as new graft materials are available. Many of the risk factors that portend nonunion are also associated with poor vascularity (eg, smoking, diabetes, vascular disease, avascular necrosis). Promoting angiogenesis at fusion sites should be taken into consideration when operating about the foot and ankle. Autograft contains all the important bone graft aspects and is the historical gold standard. The benefits of orthobiologics include avoiding donor site morbidity and increased operative time associated with autograft harvest. While there is encouraging evidence for many new orthobiologics, including BMP, PDGF, PRP, CBMA, and allogenic stem cell grafts, there are few randomized control trials, and further investigation is warranted.

### Declaration of Conflicting Interests

The author(s) declared the following potential conflicts of interest with respect to the research, authorship, and/or publication of this article: Samuel B. Adams, MD, reports other from Stryker, other from Orthofix, other from Exactech, other from Extremity Medical, outside the submitted work. ICMJE forms for all authors are available online.

### Funding

The author(s) received no financial support for the research, authorship, and/or publication of this article.

### ORCID iD

Jonathan R. Peterson, MD,  <https://orcid.org/0000-0003-4534-7334>

### References

- Abidi NA, Gruen GS, Conti SF. Ankle arthrodesis: indications and techniques. *J Am Acad Orthop Surg.* 2000;8(3):200-209.
- Adams SB, Lewis JS Jr, Gupta AK, et al. Cannulated screw delivery of bone marrow aspirate concentrate to a stress fracture nonunion: technique tip. *Foot Ankle Int.* 2013;34(5):740-744.
- Arrington ED, Smith WJ, Chambers HG, Bucknell AL, Davino NA. Complications of iliac crest bone graft harvesting. *Clin Orthop Relat Res.* 1996;329:300-309.
- Banwart JC, Asher MA, Hassanein RS. Iliac crest bone graft harvest donor site morbidity: a statistical evaluation. *Spine (Phila Pa 1976).* 1995;20(9):1055-1060.
- Bentley H, Hamdy FC, Hart KA, et al. Expression of bone morphogenetic proteins in human prostatic adenocarcinoma and benign prostatic hyperplasia. *Br J Cancer.* 1992;66(6):1159-1163.
- Bibbo C, Bono CM, Lin SS. Union rates using autologous platelet concentrate alone and with bone graft in high-risk foot and ankle surgery patients. *J Surg Orthop Adv.* 2005;14(1):17-22.
- Bibbo C, Patel DV, Haskell MD. Recombinant bone morphogenetic protein-2 (rhBMP-2) in high-risk ankle and hindfoot fusions. *Foot Ankle Int.* 2009;30(7):597-603.
- Caplan AI. All MSCs are pericytes? *Cell Stem Cell.* 2008;3(3):229-230.
- Charnley J. Compression arthrodesis of the ankle and shoulder. *J Bone Joint Surg Br.* 1951;33(2):180-191.
- Chiodo CP, Hahne J, Wilson MG, Glowacki J. Histological differences in iliac and tibial bone graft. *Foot Ankle Int.* 2010;31(5):418-422.
- Coetzee JC, Pomeroy GC, Watts JD, Barrow C. The use of autologous concentrated growth factors to promote syndesmosis fusion in the Agility total ankle replacement: a preliminary study. *Foot Ankle Int.* 2005;26(10):840-846.
- Coughlin MJ, Grimes JS, Traughber PD, Jones CP. Comparison of radiographs and CT scans in the prospective evaluation of the fusion of hindfoot arthrodesis. *Foot Ankle Int.* 2006;27(10):780-787.
- Dameron TB Jr. Fractures of the proximal fifth metatarsal: selecting the best treatment option. *J Am Acad Orthop Surg.* 1995;3(2):110-114.
- Daniels TR, Younger AS, Penner MJ, et al. Prospective randomized controlled trial of hindfoot and ankle fusions treated with rhPDGF-BB in combination with a beta-TCP-collagen matrix. *Foot Ankle Int.* 2015;36(7):739-748.
- Dawson J, Kiner D, Gardner W II, Swafford R, Nowotarski PJ. The reamer-irrigator-aspirator as a device for harvesting bone graft compared with iliac crest bone graft: union rates and complications. *J Orthop Trauma.* 2014;28(10):584-590.
- Dekker TJ, White P, Adams SB. Efficacy of a cellular allogeneic bone graft in foot and ankle arthrodesis procedures. *Foot Ankle Clin.* 2016;21(4):855-861.
- Dekker TJ, White P, Adams SB. Efficacy of a cellular bone allograft for foot and ankle arthrodesis and revision nonunion procedures. *Foot Ankle Int.* 2017;38(3):277-282.
- DiGiovanni CW, Baumhauer J, Lin SS, et al. Prospective, randomized, multi-center feasibility trial of rhPDGF-BB versus autologous bone graft in a foot and ankle fusion model. *Foot Ankle Int.* 2011;32(4):344-354.
- DiGiovanni CW, Lin SS, Baumhauer JF, et al. Recombinant human platelet-derived growth factor-BB and beta-tricalcium phosphate (rhPDGF-BB/beta-TCP): an alternative to autogenous bone graft. *J Bone Joint Surg Am.* 2013;95(13):1184-1192.
- Frey C, Halikus NM, Vu-Rose T, Ebramzadeh E. A review of ankle arthrodesis: predisposing factors to nonunion. *Foot Ankle Int.* 1994;15(11):581-584.
- Gandhi A, Bibbo C, Pinzur M, Lin SS. The role of platelet-rich plasma in foot and ankle surgery. *Foot Ankle Clin.* 2005;10(4):621-637, viii.
- Gruskin E, Doll BA, Futrell FW, Schmitz JP, Hollinger JO. Demineralized bone matrix in bone repair: history and use. *Adv Drug Deliv Rev.* 2012;64(12):1063-1077.
- Haddock NT, Wapner K, Levin LS. Vascular bone transfer options in the foot and ankle: a retrospective review and update on strategies. *Plast Reconstr Surg.* 2013;132(3):685-693.
- Hak DJ. The use of osteoconductive bone graft substitutes in orthopaedic trauma. *J Am Acad Orthop Surg.* 2007;15(9):525-536.



25. Hernigou P, Guissou I, Homma Y, et al. Percutaneous injection of bone marrow mesenchymal stem cells for ankle non-unions decreases complications in patients with diabetes. *Int Orthop*. 2015;39(8):1639-1643.
26. Hernigou P, Pognard A, Beaujean F, Rouard H. Percutaneous autologous bone-marrow grafting for nonunions: influence of the number and concentration of progenitor cells. *J Bone Joint Surg Am*. 2005;87(7):1430-1437.
27. Honsawek S, Dhitiseth D. Content of bone morphogenetic protein-4 in human demineralized bone: relationship to donor age and ability to induce new bone formation. *J Med Assoc Thai*. 2005;88(suppl 4):S260-S265.
28. Hyer CF, Berlet GC, Bussewitz BW, et al. Quantitative assessment of the yield of osteoblastic connective tissue progenitors in bone marrow aspirate from the iliac crest, tibia, and calcaneus. *J Bone Joint Surg Am*. 2013;95(14):1312-1316.
29. James AW, LaChaud G, Shen J, et al. A review of the clinical side effects of bone morphogenetic protein-2. *Tissue Eng Part B Rev*. 2016;22(4):284-297.
30. Jones CP, Loveland J, Atkinson BL, et al. Prospective, multi-center evaluation of allogeneic bone matrix containing viable osteogenic cells in foot and/or ankle arthrodesis. *Foot Ankle Int*. 2015;36(10):1129-1137.
31. Kado KE, Gambetta LA, Perlman MD. Uses of Grafton for reconstructive foot and ankle surgery. *J Foot Ankle Surg*. 1996; 35(1):59-66.
32. Lohmann CH, Andreacchio D, Koster G, et al. Tissue response and osteoinduction of human bone grafts in vivo. *Arch Orthop Trauma Surg*. 2001;121(10):583-590.
33. McCarrel T, Fortier L. Temporal growth factor release from platelet-rich plasma, trehalose lyophilized platelets, and bone marrow aspirate and their effect on tendon and ligament gene expression. *J Orthop Res*. 2009;27(8):1033-1042.
34. McLain RF, Fleming JE, Boehm CA, Muschler GF. Aspiration of osteoprogenitor cells for augmenting spinal fusion: comparison of progenitor cell concentrations from the vertebral body and iliac crest. *J Bone Joint Surg Am*. 2005;87(12):2655-2661.
35. Michelson JD, Curl LA. Use of demineralized bone matrix in hindfoot arthrodesis. *Clin Orthop Relat Res*. 1996;325: 203-208.
36. Miller CP, Chiodo CP. Autologous bone graft in foot and ankle surgery. *Foot Ankle Clin*. 2016;21(4):825-837.
37. Murawski CD, Kennedy JG. Percutaneous internal fixation of proximal fifth metatarsal jones fractures (zones II and III) with Charlotte Carolina screw and bone marrow aspirate concentrate: an outcome study in athletes. *Am J Sports Med*. 2011;39(6):1295-1301.
38. Myers TG, Lowery NJ, Frykberg RG, Wukich DK. Ankle and hindfoot fusions: comparison of outcomes in patients with and without diabetes. *Foot Ankle Int*. 2012;33(1):20-28.
39. Obremskey WT, Marotta JS, Yaszemski MJ, et al. Symposium. The introduction of biologics in orthopaedics: issues of cost, commercialism, and ethics. *J Bone Joint Surg Am*. 2007;89(7): 1641-1649.
40. O'Connor KM, Johnson JE, McCormick JJ, Klein SE. Clinical and operative factors related to successful revision arthrodesis in the foot and ankle. *Foot Ankle Int*. 2016;37(8):809-815.
41. Perlman MH, Thordarson DB. Ankle fusion in a high risk population: an assessment of nonunion risk factors. *Foot Ankle Int*. 1999;20(8):491-496.
42. Pietrzak WS, Woodell-May J, McDonald N. Assay of bone morphogenetic protein-2, -4, and -7 in human demineralized bone matrix. *J Craniofac Surg*. 2006;17(1):84-90.
43. Polly DW Jr, Ackerman SJ, Shaffrey CI, et al. A cost analysis of bone morphogenetic protein versus autogenous iliac crest bone graft in single-level anterior lumbar fusion. *Orthopedics*. 2003;26(10):1027-1037.
44. Rearick T, Charlton TP, Thordarson D. Effectiveness and complications associated with recombinant human bone morphogenetic protein-2 augmentation of foot and ankle fusions and fracture nonunions. *Foot Ankle Int*. 2014;35(8):783-788.
45. Reed AA, Joyner CJ, Isefuku S, Brownlow HC, Simpson AH. Vascularity in a new model of atrophic nonunion. *J Bone Joint Surg Br*. 2003;85(4):604-610.
46. Regranex. Regranex Gel 0.01% (becaplermin) [product information]. *Raritan, NJ: Ortho-McNeil*; 2008.
47. Rihn JA, Gates C, Glassman SD, et al. The use of bone morphogenetic protein in lumbar spine surgery. *J Bone Joint Surg Am*. 2008;90(9):2014-2025.
48. Rihn JA, Patel R, Makda J, et al. Complications associated with single-level transforaminal lumbar interbody fusion. *Spine J*. 2009;9(8):623-629.
49. Roberts TT, Rosenbaum AJ. Bone grafts, bone substitutes and orthobiologics: the bridge between basic science and clinical advancements in fracture healing. *Organogenesis*. 2012;8(4): 114-124.
50. Seebach C, Henrich D, Tewksbury R, Wilhelm K, Marzi I. Number and proliferative capacity of human mesenchymal stem cells are modulated positively in multiple trauma patients and negatively in atrophic nonunions. *Calcif Tissue Int*. 2007; 80(4):294-300.
51. Sethe S, Scutt A, Stolzing A. Aging of mesenchymal stem cells. *Ageing Res Rev*. 2006;5(1):91-116.
52. Singh A, Morris RJ. The yin and yang of bone morphogenetic proteins in cancer. *Cytokine Growth Factor Rev*. 2010;21(4): 299-313.
53. Valimaki VV, Aro HT. Molecular basis for action of bioactive glasses as bone graft substitute. *Scand J Surg*. 2006;95(2): 95-102.
54. Wei LC, Lei GH, Sheng PY, et al. Efficacy of platelet-rich plasma combined with allograft bone in the management of displaced intra-articular calcaneal fractures: a prospective cohort study. *J Orthop Res*. 2012;30(10):1570-1576.
55. Weinraub GM, Cheung C. Efficacy of allogenic bone implants in a series of consecutive elective foot procedures. *J Foot Ankle Surg*. 2003;42(2):86-89.
56. Zhang M, Powers RM Jr, Wolfenbarger L Jr. Effect(s) of the demineralization process on the osteoinductivity of demineralized bone matrix. *J Periodontol*. 1997;68(11):1085-1092.
57. Ziyadeh N, Fife D, Walker AM, Wilkinson GS, Seeger JD. A matched cohort study of the risk of cancer in users of becaplermin. *Adv Skin Wound Care*. 2011;24(1):31-39.