



Successfully combined therapy of Coca-Cola and endoscopic treatment for a giant diospyrobezoar in the duodenum using the electrosurgical endo-knife and ileus tube

Tadateru Maehata, MD, PhD,¹ Hirofumi Kiyokawa, MD, PhD,¹ Kazunari Nakahara, MD, PhD,¹ Shinjiro Kobayashi, MD, PhD,² Fumio Itoh, MD, PhD¹

A 71-year-old woman was admitted to our surgical department with the chief symptom of abdominal pain and vomiting. She had undergone a distal gastrectomy with Billroth 1 for early gastric cancer 20 years ago. CT showed 8-cm defects and duodenal dilation in the more proximal defect (Fig. 1A). The patient's history and CT findings led us to suspect that a diospyrobezoar may have caused the obstruction.

Endoscopic findings revealed multiple giant diospyrobezoars in the remnant stomach and the third portion of the duodenum (Fig. 2A). We attempted to remove the diospyrobezoar with a snare; however, this was unsuccessful owing to technical difficulties associated with the large size of the bezoar (Video 1, available online at www.giejournal.org).

The patient then consumed Coca-Cola (1 L/day) for 3 days as an alternative treatment. However, CT showed that the diospyrobezoar had remained unchanged in size. We deduced that Coca-Cola had not dissolved the diospyrobezoar because the surface of the diospyrobezoar was too hard. Therefore, we cut the hard surface of the diospyrobezoar and pierced a hole through its center with a flush knife BT 2.0 mm (Fujifilm Co, Tokyo, Japan) (Fig. 2B).

We performed this procedure using a pediatric colonoscope (PCF-H290T; Olympus, Tokyo, Japan) with a short small-caliber tip transparent hood (DH-28GR; Fujifilm). The small-caliber tip transparent hood is an essential

component of the pocket-creation method; it was used in this treatment because of its tapered tip design, which allows for quick and easy pocketing. We used a high-frequency generator (ICC 200; ERBE Elektromedizin GmbH, Tübingen, Germany), and the high-frequency settings were set to ENDO CUT Effect 3 120W.

We directly visualized the distal duodenal lumen and confirmed penetration through the diospyrobezoar using contrast medium. After penetrating only the center of the diospyrobezoar, we inserted the ileus tube through the pierced hole, which was not to be obstructed by the remaining diospyrobezoar. After the insertion of the ileus tube, we cut the diospyrobezoar using a 16- to 18-mm balloon catheter (GIGA balloon, Century Medical, Inc, Tokyo, Japan) (Fig. 2C). Coca-Cola (1 L/day) was added to dissolve the diospyrobezoar for 3 days again, and CT showed that the diospyrobezoar in the duodenum had disappeared (Fig. 2D).

Follow-up gastroscopy revealed no diospyrobezoar in the duodenum and that slight duodenal mucosal injury had been incurred (Fig. 2E and F). The patient had an uneventful postoperative course without any adverse events. She began eating the day we confirmed that the diospyrobezoar in the duodenum had disappeared, and she was discharged 4 days later.

Diospyrobezoars are caused by excessive ingestion of persimmons.^{1,2} Bezoar can be treated by drinking Coca-

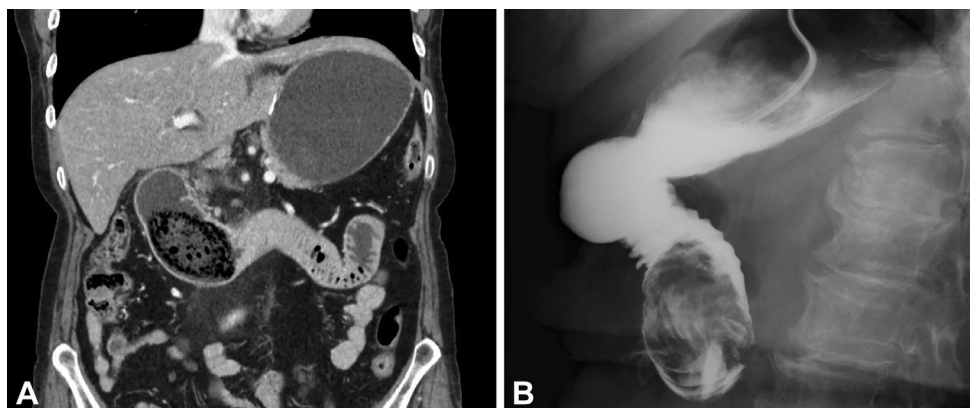


Figure 1. A, CT showed 8-cm defects and duodenal dilation in the more proximal defect. B, Upper GI series shows a giant mass consisting of foreign matter. The mass prevents the contrast medium from flowing beyond it.

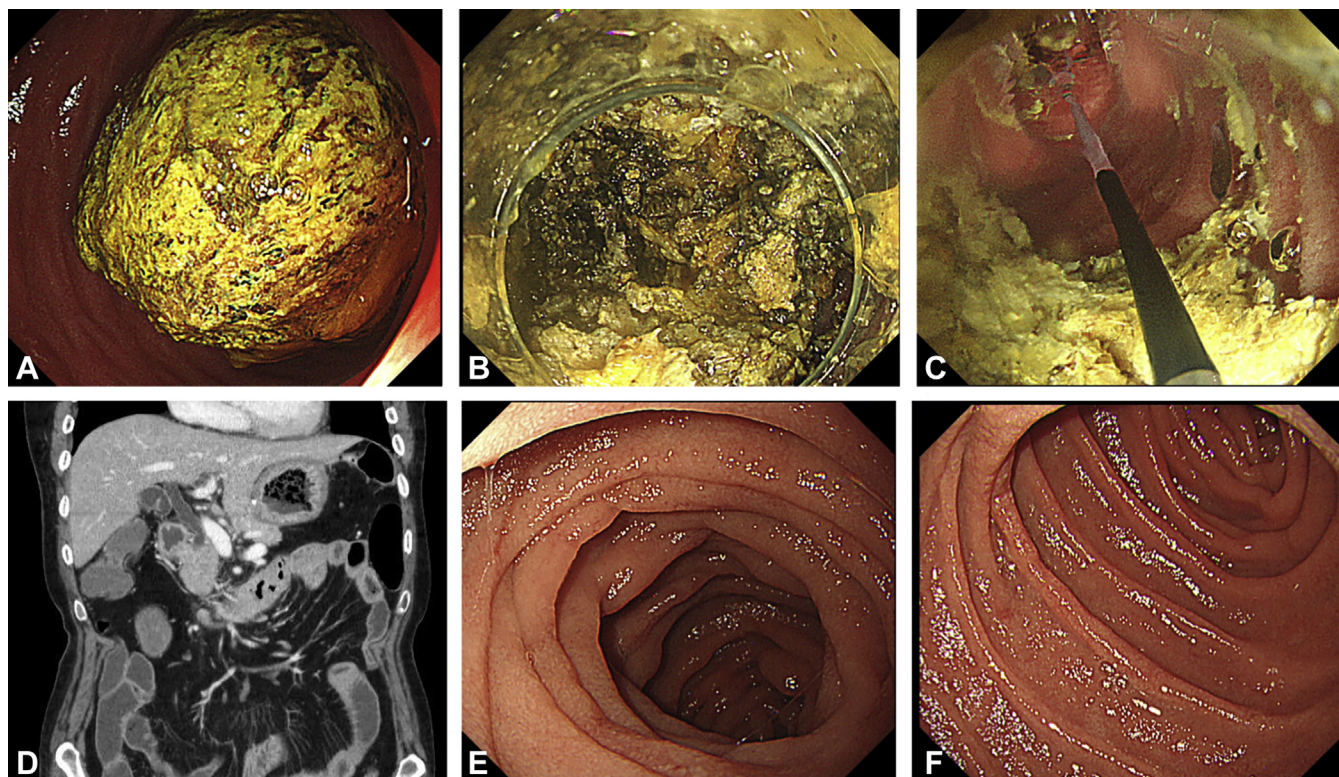


Figure 2. **A**, A giant diospyrobezoar occupying the third portion of the duodenum. **B**, A hole is pierced through the center of the diospyrobezoar with a flush knife BT 2.0 mm. **C**, The diospyrobezoar is broken down using a balloon catheter. **D**, The diospyrobezoar has disappeared from the duodenum. **E** and **F**, The absence of remnant bezoars is confirmed.

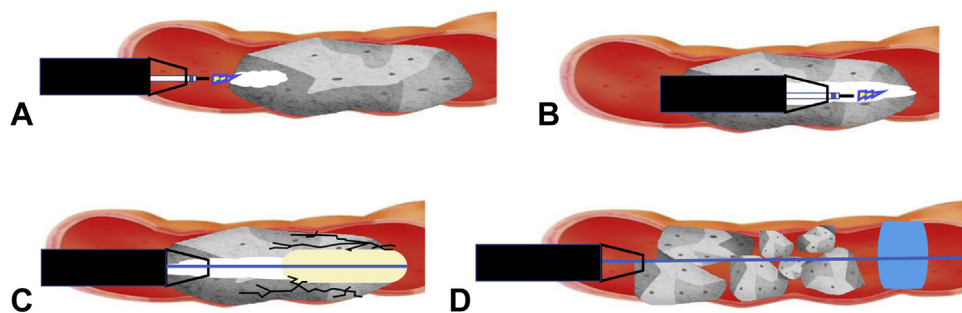


Figure 3. Diagram of the procedure. **A and B**, A hole is pierced through the center of the diospyrobezoar with a flush knife BT 2.0 mm. **C**, The diospyrobezoar is broken down using a balloon catheter. **D**, The ileus tube was inserted through the pierced hole, which was not obstructed by the remaining diospyrobezoar.

Cola and by endoscopic or surgical treatment.¹⁻⁵ It has been reported that dissolution with Coca-Cola or carbonated drinks may be useful for treating bezoars. However, the mechanism of bezoar dissolution by Coca-Cola has not been thoroughly explained. According to previous studies, the mechanism of action of Coca-Cola in the dissolution of bezoars has been hypothesized as follows: (1) Carbon dioxide bubbles penetrate the surface of gastric calculus, (2) Coca-Cola has an acidity of pH 2.6, which is close to the pH (~1-2) of gastric acid, (3) NaHCO_3 's mucolytic effect and CO_2 bubbles enhance the dissolving mechanism, and (4) the effect of unknown ingredients in Coca-

Cola. We believe that the Coca-Cola was able to dissolve the diospyrobezoar because it could penetrate more easily owing to crushing of the hard surface and increased contact area. However, diospyrobezoars are considered resistant to endoscopic treatment because of their hard consistency, and this is especially true of a giant diospyrobezoar. Surgical treatment therefore tends to be viewed as the treatment of choice.

To our knowledge, this is the first case report on the combined therapy of Coca-Cola and endoscopic treatment of a giant diospyrobezoars in the duodenum using the electro-surgical endo-knife and ileus tube (Fig. 3). Thus,

this method should be considered an option for treatment before surgical management of large diospyrobezoars.

DISCLOSURE

All authors disclosed no financial relationships.

REFERENCES

1. Iwamuro M, Okada H, Matsueda K, et al. Review of the diagnosis and management of gastrointestinal bezoars. *World J Gastrointest Endosc* 2015;7:336-45.
2. de Toledo AP, Rodrigues FH, Rodrigues MR, et al. Diospyrobezoar as a cause of small bowel obstruction. *Case Rep Gastroenterol* 2012;6:596-603.
3. Ladas SD, Triantafyllou K, Tzathas C, et al. Gastric phytobezoars may be treated by nasogastric Coca-Cola lavage. *Eur J Gastroenterol Hepatol* 2002;14:801-3.
4. Ladas SD, Kamberoglou D, Karamanolis G, et al. Systematic review: Coca-Cola can effectively dissolve gastric phytobezoars as a first-line treatment. *Aliment Pharmacol Ther* 2013;37:169-73.
5. Tao Z, Yu Y, Zhou X. New application of dual knife: easier removal of a giant gastric bezoar. *Dig Endosc* 2019;31:e62-3.

Division of Gastroenterology and Hepatology, Department of Internal Medicine, St. Marianna University School of Medicine, Kawasaki, Japan (1), Department of Gastroenterological and General Surgery, St. Marianna University School of Medicine, Kawasaki, Japan (2).

If you would like to chat with an author of this article, you may contact Dr Maehata at t2maehata@marianna-u.ac.jp.

Copyright © 2021 American Society for Gastrointestinal Endoscopy. Published by Elsevier Inc. This is an open access article under the CC BY-NC-ND license (<http://creativecommons.org/licenses/by-nc-nd/4.0/>).

<https://doi.org/10.1016/j.vgje.2021.06.008>

Endoscopy

Endoscopy has a new look! Check out the redesign of the official blog of *GIE* and *VideoGIE*. Keep up with the latest news and article discussions and post your comments or questions to *VideoGIE* authors. Visit us at www.endoscopy.com.