

Available online at [www.sciencedirect.com](http://www.sciencedirect.com)

journal homepage: [www.elsevier.com/locate/radcr](http://www.elsevier.com/locate/radcr)

## Case Report

# Post COVID-19 vaccination neuromyelitis optica spectrum disorder: Case report & MRI findings <sup>☆</sup>

Noor Badrawi, MD<sup>\*</sup>, Navin Kumar, MD, Usama Albastaki, MD

Department of Radiology, Rashid Hospital, Dubai Health Authority, PO Box 4545, Dubai, United Arab Emirates

### ARTICLE INFO

#### Article history:

Received 12 September 2021

Accepted 15 September 2021

#### Keywords:

Neuromyelitis optica spectrum disorder  
 NMOSD  
 Novel Corona Virus  
 Covid-19  
 SARS-CoV-2  
 Vaccination

### ABSTRACT

There are rising concerns among the medical community and the public regarding the side effects of different vaccines developed throughout the world and their short and long-term effects, particularly COVID19 vaccines. Most notably, post-vaccination demyelinating diseases such as acute disseminated encephalomyelitis, transverse myelitis, and multiple sclerosis relapses have been reported. We present a case of a 32-year-old male who presented with a 2 weeks history of acute confusional state and imbalance 1 week after receiving the second dose of COVID19 vaccination. MRI findings showed typical distribution of neuromyelitis optica spectrum disorder and the patient was positive for AQP4 IgG. The pathogenesis behind developing neuromyelitis optica and vaccines is still unknown. Few case reports have been reported of post-vaccination neuromyelitis optica spectrum disorder but to our knowledge, this would be the first case published of neuromyelitis optica following exposure to COVID19 vaccine.

© 2021 The Authors. Published by Elsevier Inc. on behalf of University of Washington.

This is an open access article under the CC BY-NC-ND license

(<http://creativecommons.org/licenses/by-nc-nd/4.0/>)

## Introduction

While the most common demyelinating disease that occurs post-vaccination is acute disseminated encephalomyelitis, there have been a number of cases reported of neuromyelitis optica spectrum disorder (NMOSD) in literature associated with exposure to various vaccines [1]. It is suggested that infections and vaccines may be triggers for the autoimmune response that occurs in NMOSD. NMOSD is radiologically characterized by bilateral optic neuritis and/or long-segment transverse myelitis, as well as characteristic distribution of areas of abnormal signal on brain MRI.

## Case report

A 34-year-old male, previously healthy, presented to the emergency department with a history of acute confusional state and imbalance for the past 2 weeks. He also complained of headache and dizziness. No history of fever, loss of consciousness, seizures, sensory loss. He denied any history of trauma or a previous similar episode. There was no significant past medical or surgical history. Family history was negative for any neurologic disorders. He gave a history of receiving 2 doses of COVID19 vaccine (Sputnik V COVID-19 vaccine) with the last dose taken 3 weeks before presentation.

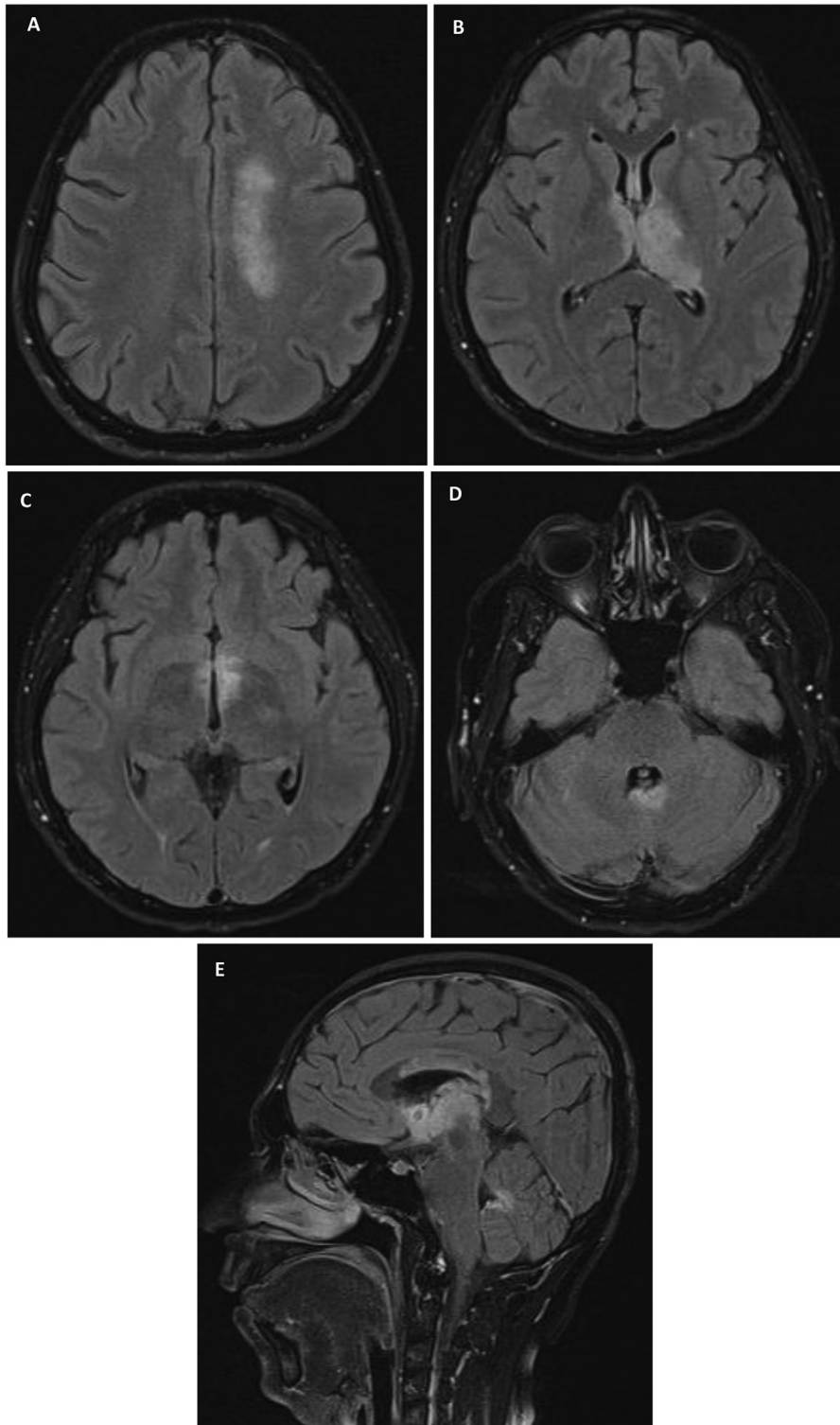
<sup>☆</sup> Competing Interests: The Authors declare that there are no competing interests.

<sup>\*</sup> Corresponding author.

E-mail address: [nabadrawi@dha.gov.ae](mailto:nabadrawi@dha.gov.ae) (N. Badrawi).

<https://doi.org/10.1016/j.radcr.2021.09.033>

1930-0433/© 2021 The Authors. Published by Elsevier Inc. on behalf of University of Washington. This is an open access article under the CC BY-NC-ND license (<http://creativecommons.org/licenses/by-nc-nd/4.0/>)



**Fig. 1 – MRI of the brain. Serial axial images (A-D) & sagittal (E) of the brain in FLAIR sequence showed patchy, hyperintense signal along the ependymal surface of the lateral, third and fourth ventricles, thalamus, corpus callosum and optic chiasma.**

On physical examination, the patient was vitally stable and afebrile. He was confused and not oriented to person or place, obeyed one step command, and sometimes gave irrelevant answers to questions. There were no signs of skin or joint involvement. Neurologic examination showed proptosis of both

eyes, otherwise, intact cranial nerves examination, intact sensory, and muscle power and tone in 4 limbs. There was an ataxic gait and overall imbalance upon examination.

Basic laboratory hematological findings were within normal limits. Viral PCR screening including COVID19, aden-

ovirus, Herpes Simplex virus (type I & II), Epstein Barr virus, Cytomegalovirus, and Human Immunodeficiency virus gave negative results. Lumbar puncture results showed lymphocytosis and mildly raised protein. CSF analysis were negative for bacterial culture, cytology, oligoclonal bands, antibodies to herpes simplex virus, syphilis antigens, cryptococcal antigen, and varicella zoster virus (VZV).

Autoimmune immunologic screening was negative (including thyroid antibodies profile, anti-neutrophil cytoplasmic antibodies, rheumatoid factor, and anti-cardiolipin were all negative. No significant vitamin deficiency was present. Patient had positive SARS-CoV-2 IgG indicating active immunity.

The patient was admitted under the care of the neurology team as a suspected case of acute disseminated encephalomyelitis in view of the history of recent vaccination. An MRI of the brain was performed and revealed extensive periventricular and/or peri-ependymal signal changes around the ventricles, including lateral, third and fourth ventricles along with periaqueductal gray matter. Signal changes were also in the optic chiasma, thalamus, and corpus callosum. (Fig. 1) MRI of the cervical spine was normal with no significant similar abnormality.

The MRI findings were suggestive of neuromyelitis optica and aquaporin-4 serum autoantibody was ordered accordingly and showed positive IgG titer of 1:40. NMOSD-typical MRI lesions, seropositive AQP4-IgG status, and the exclusion of other differential diagnoses confirmed the diagnosis of neuromyelitis optica.

Throughout the patient's stay in the hospital, he received multiple sessions of plasmapheresis receiving 5 sessions in total, and the initial symptoms have gradually improved.

---

## Discussion

Neuromyelitis optica (NMO) is an autoimmune demyelinating disease that is characterized by optic neuritis, long segment extensive transverse myelitis (>3 vertebral segments) and abnormal signals on brain MRI involving the white matter. An antibody known as aquaporin-4 (AQP4) immunoglobulin G (IgG) is a recognized specific antibody seen in patients with NMO which specifically binds to AQP4 water channels that are highly expressed in specific areas in the brain including ependymal surfaces of the ventricles, corpus callosum, corticospinal tract, and periaqueductal region [2].

On imaging, brain MRI classically shows abnormal high signal intensity on T2 weighted images particularly at optic chiasm and/or optic nerves, ependymal surfaces of the lateral, third and fourth ventricles as well as the corpus callosum, brainstem, thalamus and hypothalamus [3]. In the spinal cord, there will be features of transverse myelitis with bright central T2 hyperintensity typically with longitudinal involvement at 3 or more contiguous vertebral segments and involve more than 50% of the diameter of the spinal cord [2].

There are many differential diagnoses that should be included in the setting of predominantly white matter disease and history of recent vaccination in particular acute disseminated encephalomyelitis (ADEM), multiple sclerosis (MS), Guillain-Barré syndrome, neuro-Behçet disease [2]. Dif-

ferentiating between the different entities may be tricky since they mimic NMO on imaging. Therefore, correlation with clinical, and laboratory investigations is crucial in reaching the diagnosis.

The relationship between vaccination and demyelination diseases and in particular NMO is rare and not fully understood. However, it is generally attributed to an exaggerated auto-immune reaction of the body to the vaccine antigen. Previous case reports have emphasized that the most common demyelinating disease to occur preceding vaccination is ADEM and most seen in children [4]. A recent review of literature for the past 10 years revealed that the most commonly reported vaccinations associated with demyelinating diseases included influenza, human papilloma virus (HPV), hepatitis A or B, diphtheria, tetanus, and pertussis (DTAP). Many of the reported cases (44%) were diagnosed with ADEM and 9% were diagnosed with NMOSD [1]. Nevertheless, the overall risk of development of demyelinating disease post-vaccination is considerably low [4].

With recent development of various COVID19 vaccines, there has been increased concern of their effect on different organs. Most common side effects reported have been localized pain at injection site, low grade fever, fatigue, myalgia, chills, and joint pain, and rarely anaphylactic shock [5,6]. Upon literature review, the case presented here is the first case of NMO that proceed COVID19 vaccine. Further studies may be needed to clarify the possible connection between COVID19 vaccination and development of NMOSD. It would positively contribute to better development of safe vaccination.

---

## Conclusion

Neuromyelitis optica is an autoimmune demyelinating condition that is radiologically characterized by bilateral optic neuritis, long-segment transverse myelitis, with characteristic distribution of areas hyperintensity on T2 weighted images in brain MRI. Correlation between COVID19 vaccine and development NMO has never been reported before and this case may indicate that COVID19 vaccine can have similar effect on the immune system as other viral infections vaccines. Further research may be required to establish correlation of vaccine administration as possible trigger for NMO.

---

## Patient consent

A written consent was obtained from the patient for publication of this case and any accompanying images.

---

## REFERENCES

- [1] Kumar Neha, Graven Kelsey, Joseph Nancy I, Johnson John, Fulton Scott, Hostoffer Robert. Case report: postvaccination anti-myelin oligodendrocyte glycoprotein neuromyelitis optica spectrum disorder. *Int J MS Care* 2020;22(2):85–90. doi:10.7224/1537-2073.2018-104.

- 
- [2] Dutra Bruna Garbugio, Rocha Antônio José da, Nunes Renato Hoffmann, Júnior Antônio Carlos Martins Maia. Neuromyelitis optica spectrum disorders: spectrum of mr imaging findings and their differential diagnosis. *RadioGraphics* 2018;38(1):169–93. doi:[10.1148/rg.2018170141](https://doi.org/10.1148/rg.2018170141).
- [3] Flanagan Eoin P, Weinshenker Brian G. Neuromyelitis optica spectrum disorders. *Curr Neurol Neurosci Rep* 2014;14(9):483. doi:[10.1007/s11910-014-0483-3](https://doi.org/10.1007/s11910-014-0483-3).
- [4] Karussis Dimitrios, Panayioti P. The spectrum of post-vaccination inflammatory CNS demyelinating syndromes. *Autoimmun Rev* 2014;13(3):215–24. doi:[10.1016/j.autrev.2013.10.003](https://doi.org/10.1016/j.autrev.2013.10.003).
- [5] Haidere MF, Ratan ZA, Nowroz S, Zaman Sojib Bin, Jung You-Jung, Hosseinzadeh Hassan. COVID-19 vaccine: critical questions with complicated answers. *Biomol Ther (Seoul)* 2021;29(1):1–10. doi:[10.4062/biomolther.2020.178](https://doi.org/10.4062/biomolther.2020.178).
- [6] Kaur RJ, Dutta S, Bhardwaj P, Charan Jaykaran, Dhingra Sameer, Mitra Prasenjit, et al. Adverse events reported from COVID-19 vaccine trials: a systematic review. *Indian J Clin Biochem* 2021:1–13. doi:[10.1007/s12291-021-00968-z](https://doi.org/10.1007/s12291-021-00968-z).