

Case Report

Corticosteroid Management of Coronavirus 2019 (COVID-19) in Patients with Bilateral Adrenalectomy

William Lim¹ and Frederick Lim²

¹Department of Internal Medicine, Richmond University Medical Center, Staten Island, NY, USA

²Department of Endocrinology/Internal Medicine, Prisma Health, Columbia, SC, USA

Correspondence should be addressed to William Lim; wlim@rumcsi.org

Received 1 August 2021; Accepted 6 October 2021; Published 13 October 2021

Academic Editor: Mohd Adnan

Copyright © 2021 William Lim and Frederick Lim. This is an open access article distributed under the Creative Commons Attribution License, which permits unrestricted use, distribution, and reproduction in any medium, provided the original work is properly cited.

Since the World Health Organization (WHO) announced coronavirus 2019 (COVID-19) as a pandemic in March 2020, it has been wreaking havoc across countries, affecting people's lives. Corticosteroids have proven to provide a mortality benefit in patients with COVID-19. Although dexamethasone is the most commonly used glucocorticoid and have shown to have mortality benefit in COVID-19 patients, it cannot be used in patients with adrenal insufficiency due to its lack of mineralocorticoid activity. Herein, we discuss a case of challenging corticosteroid management in a patient with COVID-19 complicated by her medical history of bilateral adrenalectomy.

1. Introduction

Since the end of 2019, coronavirus disease 2019 (COVID-19) has rapidly spread across the whole world, resulting in a pandemic. With over 100 million cases and 3 million deaths, COVID-19 is wreaking havoc across the globe. Dexamethasone is the most commonly used glucocorticoid that has shown a mortality benefit in patients with COVID-19 [1–3]. We herein report a case of steroid management in a patient with a medical history of bilateral adrenalectomy presenting to the emergency room with COVID-19. To the best of our knowledge, there has been no report of COVID-19 associated with the medical history of bilateral adrenalectomy.

2. Case Presentation

A 58-year-old female with past medical history of multiple endocrine neoplasia type 2 (MEN2) status after thyroidectomy and bilateral adrenalectomy and right breast lobectomy, carpal tunnel syndrome, anxiety, depression, and asthma presented to the emergency department (ED) after testing positive for COVID-19. The patient stated that she

was in her usual state of health until 3 days prior to admission when she started having fever, persistent cough with whitish phlegm, mild shortness of breath, and watery diarrhea together with generalized body aches, headache, and excessive sweating.

She decided to take a COVID-19 test which came back positive which prompted her to come to the ED. Her home medications included hydrocortisone 20 mg in the morning, 10 mg in the afternoon, and 5 mg at night, levothyroxine 112 mcg two tablets in the morning, and fludrocortisone 0.1 mg tab daily. Her vital signs were as follows: temperature, 98.7°F; blood pressure, 100/48 mmHg; heart rate, 98/min; and O₂ saturation, 95% on 2 litres of nasal cannula and 88% on room air. Random blood glucose level is 136 mg/dl. Chest X-ray (Figure 1) showed bilateral infiltrates. Remdesivir 200 mg one time and 100 mg for 4 more days was started intravenously (IV) for acute hypoxic respiratory failure. Hydrocortisone 100 mg IV every 8 hours for 2 doses was given while awaiting the endocrinologist to see the patient, and the patient's home medication fludrocortisone was held.

Since the patient received another 100 mg of hydrocortisone apart from bolus dose, a decision was made to continue hydrocortisone 50 mg IV for 2 more doses: a total of 200 mg for

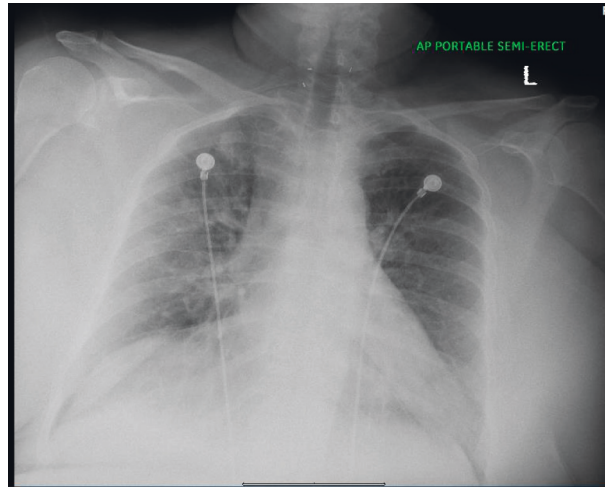


FIGURE 1: Chest X-ray showing bilateral infiltrates.

the first 24 hours. The patient's condition improved the next day, and hydrocortisone was switched to oral hydrocortisone at the strength of double her home dose: 40 mg in the morning, 20 mg in the afternoon, and 5 mg at night. After 3 more days of double strength of hydrocortisone, patient condition improved, and repeat CXR (Figure 2) showed an improvement. The patient was discharged with his regular home dose of hydrocortisone and fludrocortisone.

3. Discussion

Severe acute respiratory syndrome coronavirus is an enveloped single-stranded positive-stranded RNA virus that enters the human cells by binding to its cellular receptor, angiotensin-converting enzyme 2 (ACE2) [4, 5]. Direct person-to-person transmission is the primary means of transmission. It is thought to occur mainly through close-range contact via respiratory particles [6]. The incubation period for COVID-19 is generally within 14 days following exposure [7–9]. Most of the patients present with nonspecific flu-like symptoms or hypoxic respiratory failure with severe pneumonia [9–12].

Dexamethasone is the most commonly used glucocorticoid for COVID-19 pneumonia and shown to have a mortality benefit for severely ill COVID-19 patients who are on supplemental oxygen or ventilatory support [1–3]. However, it cannot be used in patients with adrenal insufficiency due to its lack of mineralocorticoid activity. There are only limited data on the efficacy of other glucocorticoids in treatment of COVID-19 patients because these trials were stopped early [13, 14].

Hydrocortisone is the glucocorticoid with mineralocorticoid activity and preferred glucocorticoid in patients with adrenal insufficiency [15]. Hydrocortisone 100 mg IV bolus followed by 50 mg IV every 6 hours is the recommended dose for patients with adrenal crisis [16]. In the abovementioned case, the patient who is taking hydrocortisone and fludrocortisone as a maintenance home dose presented to the ED with acute hypoxic respiratory failure due to COVID-19. We used a similar regimen that was used

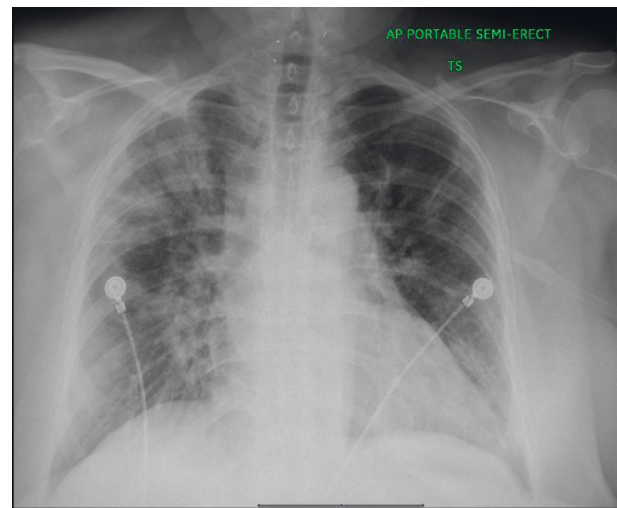


FIGURE 2: Chest X-ray showing an improvement in bilateral infiltrates.

in adrenal crisis (100 mg IV bolus and 200 mg IV in the 24 hours) and saw an improvement in patient condition.

During minor illnesses, increasing the dose of glucocorticoid to two to three times the usual daily dose for three days is recommended and known as the 3 × 3 rule [17].

Since our patient's clinical condition improved, IV hydrocortisone was switched to oral dose at a double strength. Fludrocortisone was held while the patient was receiving double strength of usual hydrocortisone dose since hydrocortisone 20 mg has an equivalent mineralocorticoid effect of fludrocortisone of 0.1 mg [15].

4. Conclusions

The study discussed a challenging case of corticosteroid management in a patient with COVID-19 which was complicated by her medical history of bilateral adrenalectomy. This case adds to a growing body of literature of the effectiveness of alternative glucocorticoids other than

dexamethasone use in COVID-19 patients with hypoxic respiratory failure and highlights the importance of understanding doses and effects of different glucocorticoids.

Abbreviations

mg: Milligram
 mcg: Microgram
 F: Fahrenheit
 mmHg: Millimeter of mercury
 min: Minute.

Data Availability

No data were used to support this study.

Consent

No written consent has been obtained from the patients as there are no patient identifiable data included in this case report.

Conflicts of Interest

None of the authors have any conflicts of interest.

References

- [1] WHO Rapid Evidence Appraisal for COVID-19 Therapies (REACT) Working Group, J. A. C. Sterne, J. A. C. Sterne et al., "Association between administration of systemic corticosteroids and mortality among critically ill patients with COVID-19: a meta-analysis," *Journal of the American Medical Association*, vol. 324, no. 13, pp. 1330–1341, 2020.
- [2] R. A. Siemieniuk, J. J. Bartoszko, L. Ge et al., "Drug treatments for covid-19: living systematic review and network meta-analysis," *BMJ*, vol. 370, p. m2980, 2020.
- [3] P. Horby, W. S. Lim, J. R. Emberson et al., "Dexamethasone in hospitalized patients with covid-19," *New England Journal of Medicine*, vol. 384, no. 8, pp. 693–704, 2021.
- [4] M. A. Shereen, S. Khan, A. Kazmi, N. Bashir, and R. Siddique, "COVID-19 infection: emergence, transmission, and characteristics of human coronaviruses," *Journal of Advanced Research*, vol. 24, pp. 91–98, 2020.
- [5] P. Zhou, X.-L. Yang, X.-G. Wang et al., "A pneumonia outbreak associated with a new coronavirus of probable bat origin," *Nature*, vol. 579, no. 7798, pp. 270–273, 2020.
- [6] E. A. Meyerowitz, A. Richterman, R. T. Gandhi, and P. E. Sax, "Transmission of SARS-CoV-2: a review of viral, host, and environmental factors," *Annals of Internal Medicine*, vol. 174, no. 1, pp. 69–79, 2021.
- [7] Q. Li, X. Guan, P. Wu et al., "Early transmission dynamics in Wuhan, China, of novel coronavirus-infected pneumonia," *New England Journal of Medicine*, vol. 382, no. 13, pp. 1199–1207, 2020.
- [8] J. F.-W. Chan, S. Yuan, K.-H. Kok et al., "A familial cluster of pneumonia associated with the 2019 novel coronavirus indicating person-to-person transmission: a study of a family cluster," *The Lancet*, vol. 395, no. 10223, pp. 514–523, 2020.
- [9] W.-J. Guan, Z.-Y. Ni, Y. Hu et al., "Clinical characteristics of coronavirus disease 2019 in China," *New England Journal of Medicine*, vol. 382, no. 18, pp. 1708–1720, 2020.
- [10] C. Huang, Y. Wang, X. Li et al., "Clinical features of patients infected with 2019 novel coronavirus in Wuhan, China," *The Lancet*, vol. 395, no. 10223, pp. 497–506, 2020.
- [11] N. Chen, M. Zhou, X. Dong et al., "Epidemiological and clinical characteristics of 99 cases of 2019 novel coronavirus pneumonia in Wuhan, China: a descriptive study," *The Lancet*, vol. 395, no. 10223, pp. 507–513, 2020.
- [12] D. Wang, B. Hu, C. Hu et al., "Clinical characteristics of 138 hospitalized patients with 2019 novel coronavirus-infected pneumonia in Wuhan, China," *Journal of the American Medical Association*, vol. 323, no. 11, pp. 1061–1069, 2020.
- [13] P.-F. Dequin, N. Heming, F. Meziani et al., "Effect of hydrocortisone on 21-day mortality or respiratory support among critically ill patients with COVID-19: a randomized clinical trial," *Journal of the American Medical Association*, vol. 324, no. 13, pp. 1298–1306, 2020.
- [14] D. C. Angus, D. C. Angus, L. Derde et al., "Effect of hydrocortisone on mortality and organ support in patients with severe COVID-19: the REMAP-CAP COVID-19 corticosteroid domain randomized clinical trial," *Journal of the American Medical Association*, vol. 324, no. 13, pp. 1317–1329, 2020.
- [15] D. Liu, A. Ahmet, L. Ward et al., "A practical guide to the monitoring and management of the complications of systemic corticosteroid therapy," *Allergy, Asthma & Clinical Immunology*, vol. 9, no. 1, p. 30, 2013.
- [16] R. L. Taylor, S. K. Grebe, and R. J. Singh, "Quantitative, highly sensitive liquid chromatography-tandem mass spectrometry method for detection of synthetic corticosteroids," *Clinical Chemistry*, vol. 50, no. 12, pp. 2345–2352, 2004.
- [17] L. K. Nieman, A. Lacroix, and K. A. Martin, *Treatment of Adrenal Insufficiency in Adults*, UpToDate, Waltham, MA, USA, 2020.