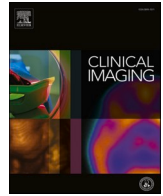



Since January 2020 Elsevier has created a COVID-19 resource centre with free information in English and Mandarin on the novel coronavirus COVID-19. The COVID-19 resource centre is hosted on Elsevier Connect, the company's public news and information website.

Elsevier hereby grants permission to make all its COVID-19-related research that is available on the COVID-19 resource centre - including this research content - immediately available in PubMed Central and other publicly funded repositories, such as the WHO COVID database with rights for unrestricted research re-use and analyses in any form or by any means with acknowledgement of the original source. These permissions are granted for free by Elsevier for as long as the COVID-19 resource centre remains active.



## Neuroradiology

## Brain MRI findings in COVID-19 patients with PRES: A systematic review

Rubaya Yeahia<sup>a</sup>, Javin Schefflein<sup>b</sup>, Patrick Chiarolanzio<sup>c</sup>, Anna Rozenstein<sup>d</sup>, William Gomes<sup>b</sup>, Sana Ali<sup>b</sup>, Hasit Mehta<sup>b</sup>, Fawaz Al-Mufti<sup>e</sup>, Andrew McClelland<sup>f</sup>, Edwin Gulko<sup>b,\*</sup>

<sup>a</sup> New York Medical College, Valhalla, New York, United States of America

<sup>b</sup> Division of Neuroradiology, Department of Radiology, Westchester Medical Center, Valhalla, New York, United States of America

<sup>c</sup> Department of Radiology, New York Medical College, Valhalla, New York, United States of America

<sup>d</sup> Division of Cardiothoracic Radiology, Department of Radiology, Westchester Medical Center, Valhalla, New York, United States of America

<sup>e</sup> Department of Neurology, Westchester Medical Center, Valhalla, New York, United States of America

<sup>f</sup> Division of Neuroradiology, Department of Radiology, Montefiore Medical Center, Bronx, New York, United States of America

## ARTICLE INFO

**Keywords:**  
COVID-19  
PRES  
MRI brain

## ABSTRACT

**Background:** Numerous case reports and case series have described brain Magnetic Resonance Imaging (MRI) findings in Coronavirus disease 2019 (COVID-19) patients with concurrent posterior reversible encephalopathy syndrome (PRES).

**Purpose:** We aim to compile and analyze brain MRI findings in patients with COVID-19 disease and PRES.

**Methods:** PubMed and Embase were searched on April 5th, 2021 using the terms “COVID-19”, “PRES”, “SARS-CoV-2” for peer-reviewed publications describing brain MRI findings in patients 21 years of age or older with evidence of severe acute respiratory syndrome coronavirus 2 (SARS-CoV-2) infection and PRES.

**Results:** Twenty manuscripts were included in the analysis, which included descriptions of 30 patients. The average age was 57 years old. Twenty-four patients (80%) required mechanical ventilation. On brain MRI examinations, 15 (50%) and 7 (23%) of patients exhibited superimposed foci of hemorrhage and restricted diffusion respectively.

**Conclusions:** PRES is a potential neurological complication of COVID-19 related disease. COVID-19 patients with PRES may exhibit similar to mildly greater rates of superimposed hemorrhage compared to non-COVID-19 PRES patients.

## 1. Introduction

The novel Coronavirus disease 2019 (COVID-19) caused by the severe acute respiratory syndrome coronavirus (SARS-CoV-2) can affect multiple organ systems in addition to its primary effect on the respiratory system.<sup>1</sup> Several central nervous system (CNS) complications have been described, including intracranial hemorrhage, acute infarction, cerebral vein thrombosis, and CNS inflammatory disorders.<sup>2–4</sup> Recently, posterior reversible encephalopathy syndrome (PRES) has also been described in association with COVID-19 infections, with more cases emerging as the pandemic progresses. The clinical presentation of PRES varies from headache, altered mental status, seizures, and visual loss, while MRI demonstrates white matter edema predominating in the posterior parietal and occipital cerebrum.<sup>5</sup> Currently, the brain MRI

findings of PRES in the setting of COVID-19 infection is limited to case reports and case series. Utilizing the Preferred Reporting Items for Systematic Reviews and Meta-Analyses (PRISMA) guidelines,<sup>6</sup> we performed a systematic review in order to collect and evaluate the brain MRI findings in COVID-19 associated PRES.

## 2. Methods

## 2.1. Data sources and searches

A systematic search of the PubMed and Embase databases was performed to identify published manuscripts that described brain MRI findings in patients with COVID-19 disease and PRES. Search terms included: “COVID”, “PRES”, and “SARS-CoV-2”. Literature searches

**Abbreviations:** COVID-19, Coronavirus disease 2019; SARS-CoV-2, severe acute respiratory syndrome coronavirus; PRES, posterior reversible encephalopathy syndrome; PRISMA, Preferred Reporting Items for Systematic Reviews and Meta-Analyses; MRI, magnetic resonance imaging; SWI, susceptibility-weighted imaging.

\* Corresponding author at: Division of Neuroradiology, Department of Radiology, Westchester Medical Center, 100 Woods Rd, Valhalla, New York 10595, United States of America.

E-mail address: [Edwin.Gulko@wmchealth.org](mailto:Edwin.Gulko@wmchealth.org) (E. Gulko).

<https://doi.org/10.1016/j.clinimag.2021.10.003>

Received 1 June 2021; Received in revised form 21 September 2021; Accepted 5 October 2021

Available online 16 October 2021

0899-7071/© 2021 Elsevier Inc. All rights reserved.

**Table 3**  
Manuscripts describing Brain MRI findings in COVID-19 patients with PRES.

Patient no./sex/age(y)	First author	Clinical presentation				Clinical intervention		MRI brain findings			Clinical Outcome
		Blood pressure	Visual changes	Altered mental status	Seizures	Highest level O <sub>2</sub> therapy	Immunotherapy status	Findings	Hemorrhage	Diffusion restriction	
P1/M/64	Doo FX et al. <sup>28</sup>	NR	NR	Present	Present	Mechanical ventilation	Tocilizumab	Parietooccipital edema with small foci of hemorrhage.	Present	NR	NR
P2/F/64	Princiotta et al., and Colombo et al. <sup>7,8</sup>	Hypertensive	Present	Present	Absent	Mechanical ventilation	NR	MRI brain consistent with PRES	Present	NR	Discharged
P3/M/58	Kishfy L et al. <sup>29</sup>	Hypertensive	Absent	Present	NR	Mechanical ventilation	Tocilizumab	T2 FLAIR hyperintensity involving subcortical occipital and temporal white matter. Convexity subarachnoid hemorrhage. No abnormal contrast enhancement.	Present	Absent	Discharged
P4/F/67	Kishfy L et al. <sup>29</sup>	Hypertensive	Absent	Present	NR	Mechanical ventilation	NR	T2 FLAIR hyperintense foci in right occipital subcortical white matter and left cerebellum. SWI with petechial hemorrhage. No abnormal contrast enhancement.	Present	Absent	Discharged
P5/F/63	Conte G et al. <sup>30</sup>	Hypertensive	Present	NR	Present	Mechanical ventilation	Anakinra	Partially confluent, tumefactive white matter lesions, with posterior predominance. Left precentral subarachnoid blood products. Perivascular contrast enhancement within white matter.	Present	Present	Discharged
P6/M/59	Rogg J et al. <sup>12</sup>	Hypertensive	NR	Present	NR	Mechanical ventilation	NR	Extensive FLAIR hyperintensity within subcortical greater than deep white matter, internal and external capsules, and cerebellar white matter. No contrast enhancement.	NR	Absent	Death
P7/NR/NR	Dias DA et al. <sup>31</sup>	NR	NR	Present	NR	Mechanical ventilation	NR	Bilateral parieto-occipital vasogenic edema with superimposed blood products. Foci of restricted diffusion attributed to blood products.	Present	Absent	NR
P8/M/64	Parauda SC et al. <sup>32</sup>	Hypertensive	Present	Present	Present	Mechanical ventilation	NR	T2 FLAIR hyperintensities occipital white matter, and within left thalamus and internal capsule.	Absent	Absent	Discharged
P9/M/73	Parauda SC et al. <sup>32</sup>	Hypertensive	NR	Present	Present	Mechanical ventilation	NR	Confluent T2 hyperintensity bilateral parietooccipital white matter.	Absent	Absent	Discharged
P10/F/65	Parauda SC et al. <sup>32</sup>	Hypertensive	NR	Present	Absent	Mechanical ventilation	NR	Non enhancing bilateral occipital subcortical white matter T2 hyperintensities.	NR	Absent	Discharged
P11/F/74	Parauda SC et al. <sup>32</sup>	Hypertensive	NR	Present	Absent	Mechanical ventilation	Tocilizumab	T2 hyperintensities in bilateral parietooccipital lobes with restricted diffusion and SWI hypointense foci.	Present	Present	Discharged
P12/F/27	Agarwal A et al. <sup>33</sup>	NR	NR	Present	NR	Mechanical ventilation	NR	Subcortical vasogenic edema in occipital subcortical white matter.	NR	Absent	Death
P13/F/24*	López Pérez V et al. <sup>34</sup>	Hypertensive	NR	Present	Present	Mechanical ventilation	Tocilizumab	FLAIR hyperintensity in bilateral parietal and parasagittal frontal regions.	NR	NR	Discharged
P14/F/64	D'Amore F et al. <sup>35</sup>	NR	Present	Present	NR	NR	NR	Vasogenic edema and occipital hemorrhages.	Present	NR	NR
P15/F/33	Ghosh R et al. <sup>36</sup>	Normotensive	Present	Absent	NR	NR	NR	FLAIR hyperintensity bilateral occipital subcortical white matter.	Absent	Absent	Discharged
P16/F/25*	Sripadma PV et al. <sup>37</sup>	Hypertensive	NR	NR	Present	Mechanical ventilation	NR	Bilateral parietal-occipital T2 hyperintensities with bilateral small hemorrhages.	Present	Absent	Discharged
P17/F/61	Anand P et al. <sup>38</sup>	Hypertensive	NR	Present	Present	Mechanical ventilation	Anakinra	T2 hyperintensities in bilateral parietooccipital lobes. Susceptibility in right frontal lobe.	Present	Absent	Discharged

(continued on next page)

Table 3 (continued)

Patient no./sex/age(y)	First author	Clinical presentation				Clinical intervention		MRI brain findings			Clinical Outcome
		Blood pressure	Visual changes	Altered mental status	Seizures	Highest level O <sub>2</sub> therapy	Immunotherapy status	Findings	Hemorrhage	Diffusion restriction	
P18/F/52	Anand P et al. <sup>38</sup>	Hypertensive	Absent	Present	Present	Mechanical ventilation	NR	T2 hyperintensities within bilateral parietal, occipital, frontal, temporal white matter. Punctate hemorrhages in temporal and occipital lobes.	Present	Absent	Discharged
P19/M/48	Franceschi AM et al. <sup>11</sup>	Hypertensive	NR	Present	NR	Mechanical ventilation	NR	Vasogenic edema in the posterior parieto-occipital regions with subacute blood products. SWI with petechial hemorrhages diffusely throughout the corpus callosum.	Present	Present	NR
P20/F/67	Franceschi AM et al. <sup>11</sup>	Hypertensive	NR	Present	NR	NR	NR	Multiple areas of restricted diffusion and edema, greatest within the parietooccipital regions, and within the right frontal lobe, basal ganglia, and cerebellar hemispheres. Extensive superimposed hemorrhages in the parietooccipital region with abnormal contrast enhancement.	Present	Present	Discharged
P21/M/46	Ordoñez-Boschetti L et al. <sup>39</sup>	Normotensive	Absent	Present	NR	Mechanical ventilation	NR	T2 FLAIR hyperintensities in frontal and occipital white matter.	NR	Absent	Discharged
P22/M/74	Gómez-Enjuto S et al. <sup>40</sup>	Hypertensive	Present	Present	Present	NR	Carfilzomib	T2 FLAIR hyperintensities frontoparietal and occipital subcortical areas.	NR	NR	Discharged
P23/M/54	Colombo A et al. <sup>5</sup>	Hypertensive	Present	Absent	Present	Mechanical ventilation	NR	MRI brain consistent with PRES	NR	NR	Discharged
P24/F/63	Colombo A et al. <sup>5</sup>	Hypertensive	Present	Present	Present	Mechanical ventilation	IL-1 antagonist	MRI brain consistent with PRES	NR	NR	Discharged
P25/M/64	Colombo A et al. <sup>5</sup>	Normotensive	Present	Present	Present	Mechanical ventilation	NR	Symmetric white matter alterations, mainly occipital lobes. No enhancement.	Present	NR	Discharged
P26/M/68	Colombo A et al. <sup>5</sup>	Hypertensive	Present	Present	Absent	Mechanical ventilation	NR	MRI brain consistent with PRES	NR	NR	Discharged
P27/F/57	Colombo A et al. <sup>5</sup>	Hypertensive	Present	Absent	Present	Non-invasive ventilation	NR	MRI brain consistent with PRES	NR	NR	Discharged
P28/F/43	Santos de Lima F et al. <sup>41</sup>	Normotensive	Absent	Present	Present	Mechanical ventilation	NR	1st MRI-Area of hyperintensity in the splenium. 2nd MRI-extensive T2/FLAIR hyperintensity in bilateral cerebral hemispheres with mild sulcal enhancement, and gyroform restricted diffusion in right temporooccipitoparietal region. Lesion in the splenium resolved. 3rd MRI-progression of white signal abnormality.	NR	Present	Discharged
P29/M/55	Wijeratne T et al. <sup>42</sup>	Hypertensive	Absent	Present	Absent	NR	NR	Bilateral parietal-occipital T2 FLAIR hyperintensities. Diffuse petechial hemorrhages in basal ganglia and deep white matter. Small foci of restricted diffusion in deep white matter.	Present	Present	Discharged
P30/M/70	Talluri K et al. <sup>43</sup>	Hypertensive	Absent	Present	Absent	Mechanical ventilation	Tocilizumab	Cortical and subcortical FLAIR signal in bilateral occipital lobes and paramedian frontal and parietal lobes. Restricted diffusion bilateral occipital lobes, posterior thalami and left temporal lobe.	NR	Present	Death

NR = Not recorded. Patient #2 was described in two separate manuscripts. \* = Patients were pregnant.

were performed on April 5th, 2021.

2.2. Study selection and data extraction

We included articles published in peer-reviewed journals if they described brain MRI findings in patients older than 21 years of age with SARS-CoV-2 infection and a provided diagnosis of PRES. Duplicate manuscripts from literature search results were removed prior to the screening process. Three reviewers (E.G., J.S., R.Y.) examined titles and abstracts from the literature searches to identify potential manuscripts for inclusion. Articles included after initial screening were reviewed for final inclusion by two neuroradiologists (E.G., J.S.).

2.3. Data synthesis and analysis

Data extraction from each manuscript was performed by two board-certified radiologists, one with a certificate of added qualification in neuroradiology (E.G.) and the other with specialty training in neuroradiology (J.S.). Data extracted from each article included: authors, title, country of origin, number of patients with brain MRI imaging findings described, age and gender of the patients, clinical presentation, clinical parameters, and specific findings on brain MRI exams. One patient (Table 3, patient #2) was described in two different manuscripts.<sup>7,8</sup>

3. Results

3.1. Manuscript searches

We identified 166 articles (Fig. 1). After removal of duplicates, 79 articles remained for screening. After screening, 25 articles were fully

Table 1

Manuscripts describing Brain MRI findings in COVID-19 patients with PRES.

Manuscripts describing MRI findings in Covid-19 patients with PRES	
Articles	20
Journals	16
Countries	7
USA	9
Italy	4
India	2
Spain	2
Australia	1
Brazil	1
Mexico	1
Patients with MR imaging of the brain described	30
Case report	11
Case series	8
Letter to editor	1

assessed for eligibility. Of the 25 articles evaluated for eligibility, 5 articles were excluded secondary to: 4 articles not describing brain MRI findings, and 1 with discordant description of brain MRI findings and the provided figure. This resulted in the inclusion of 20 manuscripts (Table 1). These included: 11 case reports, 8 case series, and a letter to an editor. The manuscripts originated from 7 different countries (United States: 9, Italy: 4, India: 2, Spain: 2, Australia: 1, Brazil: 1, and Mexico: 1).

3.2. Patients

Thirty patients with COVID-19 and PRES with described brain MRI findings were included in the analysis (Table 2). The mean age was 57

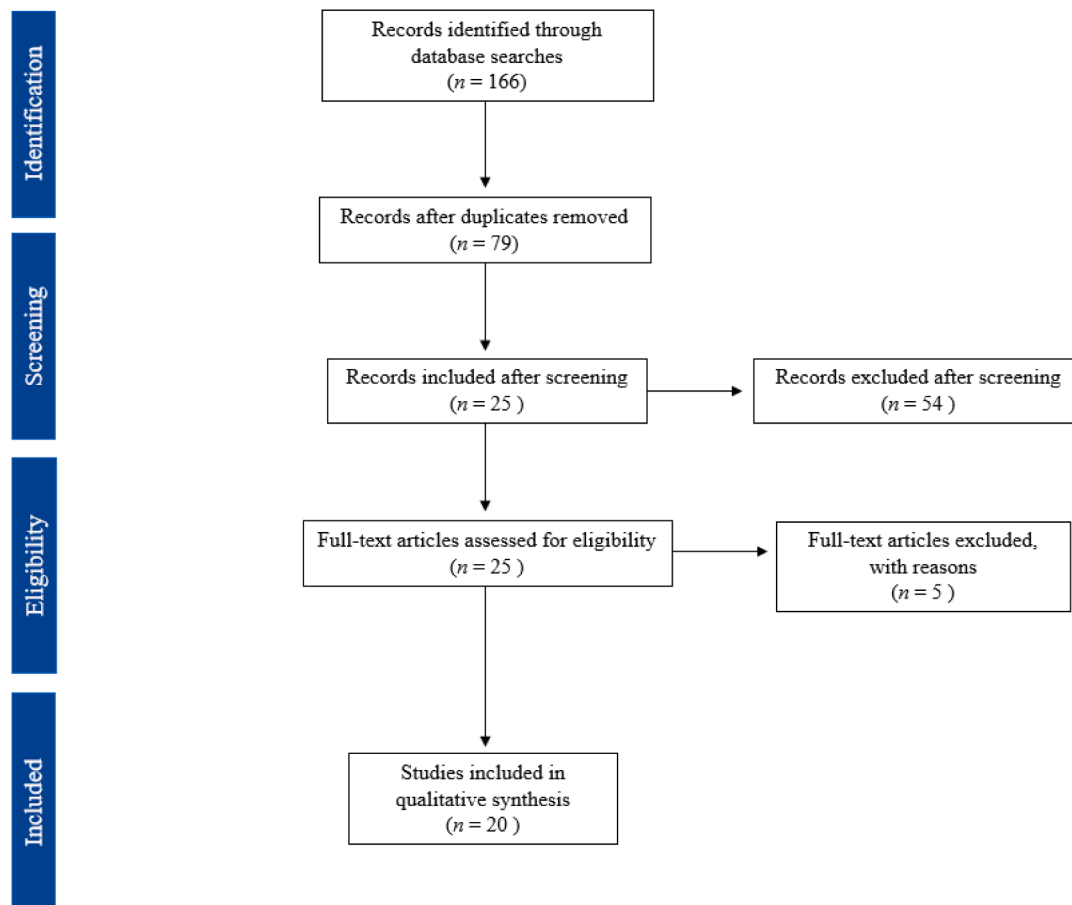


Fig. 1. Literature search results.

**Table 2**  
Patient characteristics and brain MRI findings in COVID-19 patients with PRES.

		COVID-19 patients with PRES (n = 30)	
Demographics	Age		
	Range	24–74	
	Mean	57	
	Median	63	
	n		%
	Male	13	43%
	Female	16	53%
	Gender not reported	1	3%
Clinical presentation	>1 hypertensive episode	22	73%
	Visual changes	14	45%
	Altered mental status	25	83%
	Seizure	14	42%
Clinical intervention	Mechanical ventilation	24	80%
	Immunotherapy	9	30%
Imaging findings	Hemorrhage	15	50%
	Diffusion restriction	7	23%
Clinical outcome	Death	3	10%
	Discharged	23	77%

years (range 24–74), and 16 were female. Of the clinical presentations associated with PRES, there were 22 patients with hypertensive episodes, 14 with visual changes, 25 with altered mental status and 14 with seizure. Twenty-four (80%) of the patients required mechanical ventilation, and 9 patients (30%) received immunotherapy. In most cases, patients exhibited symptoms of COVID-19 related illness prior to hospitalization and development of PRES as an inpatient. Eight manuscripts provided descriptions of CSF results, most of which were within normal limits. Only two manuscripts mentioned if CSF was tested for the SARS-CoV-2 virus. Only 2 manuscripts mentioned that patients were given pressors (patients 17 and 18), and three were administered steroid therapy (patients 15, 22, 29).

### 3.3. Imaging findings

MRI brain findings varied from brief statements such as, “MRI brain consistent with PRES”, to more comprehensive explanations detailing findings on different pulse sequences. Most manuscripts did not provide MRI protocols utilized, nor field strength of the MRI magnet used. Most manuscripts did not specify whether gradient echo or susceptibility-weighted imaging sequences were used for detecting blood products, and was only provided in ten cases. Eight cases (patients 3, 4, 5, 7, 17, 19, 20, 29) utilized SWI, and two cases (patients 2, 14) utilized gradient echo sequences. On brain MRI, 15 patients (50%) had foci of hemorrhage superimposed on described findings of PRES, and 7 patients (23%) had superimposed foci of restricted diffusion. The described brain MRI findings within the manuscripts precluded adequate tabulation of the distribution of FLAIR signal abnormalities typical of PRES. Additionally, few articles mentioned whether or not there was abnormal intracranial contrast enhancement.

## 4. Discussion

This first systematic review of brain MRI findings in COVID-19 patients with PRES utilizing PRISMA guidelines shows that PRES patients who have COVID-19 may have similar to mildly increased rates of hemorrhage compared to PRES patients who do not have COVID-19.

Numerous neurological and neuroimaging manifestations of COVID-19 infection have been described including intracranial hemorrhage, acute strokes, leukoencephalopathy, and CNS inflammatory disorders. As the pandemic continues, more and more case reports and case series are describing an association of COVID-19 disease with clinical and imaging findings typical of PRES. While the complex pathogenesis and possible neurotropism of the SARS-CoV-2 virus is still being elucidated, there is growing evidence that the intracranial complications of COVID-19 disease may at least in part be due to the cytokine release syndrome

(a.k.a. ‘cytokine storm’).<sup>9,10</sup> Typical laboratory findings of cytokine release syndrome include decreased T-cells and natural killer cells, and an increase in interleukin 6,<sup>11</sup> among elevation of other inflammatory markers.<sup>9</sup> PRES is commonly linked to alterations in the blood-brain barrier secondary to loss of autoregulation or endothelial dysfunction.<sup>11</sup> The massive release of cytokines and inflammatory markers that can occur in COVID-19 patients, may result in breakdown of the blood-brain barrier and endothelial injury that leads to PRES.<sup>11,12</sup>

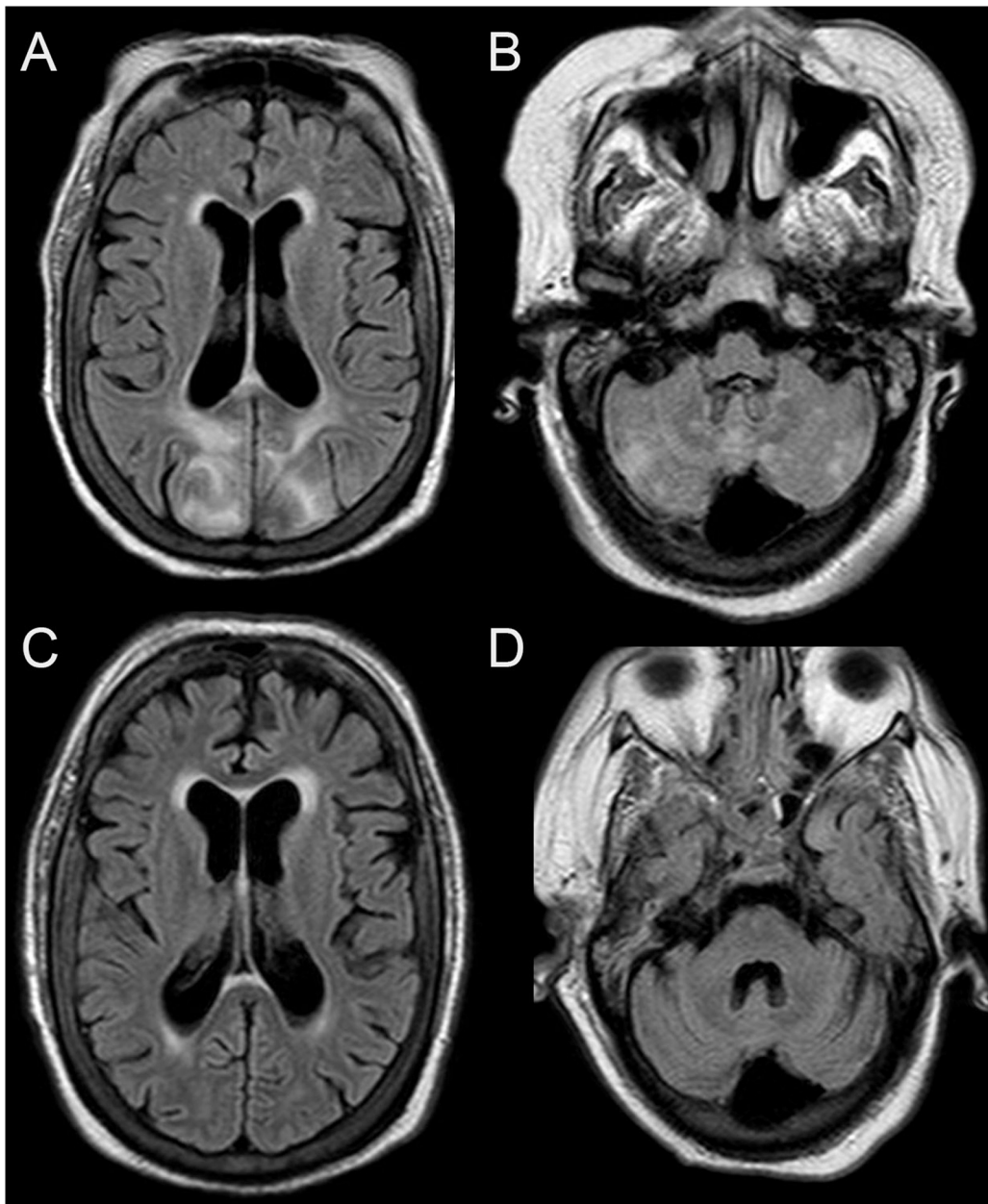
In the absence of established diagnostic criteria, PRES is often diagnosed in the context of clinical and imaging findings after other possibilities have been excluded.<sup>13</sup> Typical clinical presentations include either seizure, headache, visual disturbance, or altered mental status and often occurs in the setting of elevated blood pressures.<sup>14</sup> Numerous additional causes have been associated with PRES including: eclampsia, immunosuppressive drugs, as well as an array of additional drugs and diseases.<sup>14</sup> On imaging, typical PRES is characterized by vasogenic edema preferentially involving the parietooccipital regions, whereas atypical PRES can involve the frontal lobes, basal ganglia, brainstem, and cerebellum (Fig. 2).<sup>14</sup> Three hemispheric pattern variants can be observed (holohemispheric, superior frontal sulcal, and primary parietal-occipital), which resemble brain watershed zones.<sup>15</sup> Predominant involvement of the basal ganglia, brain stem, and deep white matter with less hemispheric involvement can lead to a challenging diagnosis of PRES.<sup>15</sup> Catheter cerebral angiogram or MRA time-of-flight imaging reveals vasculopathy with diffuse vasoconstriction, focal vasoconstriction/vasodilatation, and usually resolves on repeat imaging.<sup>15</sup> Reports of perfusion patterns in PRES have varied including descriptions of hyperperfusion and hypoperfusion.<sup>15</sup>

The key difference between PRES associated with COVID-19 and PRES in other settings appears to be the similar to mildly higher rate of hemorrhage, while the rate of restricted diffusion is approximately the same. Prior reports described hemorrhage in PRES patients occurring in approximately 15–17% of patients,<sup>15,16</sup> and a more recent report demonstrated 36% of hemorrhage in PRES patients.<sup>17</sup> T2-star weighted imaging was utilized in two of these manuscripts.<sup>16,17</sup> In a more recent report that utilized SWI, hemorrhage was present in 64.5% of patients with PRES.<sup>18</sup> In our analysis, MRI techniques for detecting hemorrhage was described in only ten patients (SWI was used in eight patients) resulting in a limitation to our study. Foci of restricted diffusion can occur 16–17% of cases<sup>19</sup>, and we observed 23%. In our analysis, too few manuscripts commented on the absence or presence of intracranial contrast enhancement, precluding adequate comparison with non-COVID-19 PRES patients.

PRES is typically associated with a favorable outcome with proper medical management.<sup>14</sup> However, the presence of hemorrhage or restricted diffusion is associated with worse clinical outcomes.<sup>17</sup> Of the cases we reviewed, 3 patients (10%) expired. Our study is limited in evaluating outcomes in COVID-19 patients with PRES due to a small sample size, and a formal meta-analysis with a larger patient sample would be needed to compare mortality rates between PRES patients with and without COVID-19.

The majority of patients in our study required mechanical ventilation, indicative of severe disease, and 9 of the patients received immunotherapy. Guidelines from the national institutes of health recommend use of baricitinib and tocilizumab in certain hospitalized patients: 1) hospitalized patients requiring oxygen through a high-flow device or noninvasive ventilation, and with increasing oxygen need and systemic inflammation after a recent hospitalization, and 2) hospitalized patients requiring mechanical ventilation or ECMO, and are within 24 h of ICU admission. Larger studies are needed to investigate whether immunomodulators cause PRES in COVID-19 patients.<sup>20</sup>

Our study is limited by reliance on descriptions rather than direct interpretation of brain MRI findings, and the presumed diagnosis of PRES. This precludes adequate review of the distribution of parenchymal abnormalities which can be variable in PRES. Insofar as there may be overlap in the imaging findings of PRES and COVID-19 related



**Fig. 2.** PRES in a patient with COVID-19.

Brain MRI images in a 61-year-old female with COVID-19 and respiratory failure requiring mechanical ventilations. Axial T2/FLAIR images (A and B) demonstrate T2/FLAIR hyperintensities predominately with the bilateral parietooccipital regions. Foci of T2/FLAIR hyperintensities were also present with the bilateral cerebellum. Imaging findings were consistent with PRES. A follow-up Brain MRI exam (C and D) approximately 3 weeks later demonstrated resolution of the parenchymal abnormalities. There was no evidence of restricted diffusion or hemorrhagic foci on the first Brain MRI exam.

neuroimaging findings, such as COVID-19 related leukoencephalopathy or acute hemorrhagic leukoencephalitis, this may be a significant source of bias. Recent reports<sup>4,21–23</sup> have described confluent white matter T2 hyperintensities in patients with severe COVID-19 disease and prolonged mechanical ventilation, in some cases with superimposed foci of restricted diffusion and microhemorrhages, possibly due to hypoxemia.<sup>4</sup> In two studies the leukoencephalopathy was reported to have a posterior predominance.<sup>21,24</sup> Microhemorrhages have also been described as a common finding in patients with COVID-19.<sup>25</sup> Recent reports of acute hemorrhagic leukoencephalitis in COVID-19 patients, have described multifocal white matter lesions with hemorrhages and foci of restricted diffusion.<sup>26,27</sup> Distinction between PRES, COVID-19 related leukoencephalopathy, and acute hemorrhagic leukoencephalitis may be relevant clinically as it may alter clinical management. Further studies may be helpful in confidently distinguishing between these entities on brain MRI.

The medical community's understanding of COVID-19 is rapidly changing as the pandemic evolves. While our study aimed to incorporate

all cases of COVID-19 and PRES, there may be some cases that were missed or will subsequently be published. Additional and larger studies will be needed to further understand the interplay between COVID-19 and PRES.

## 5. Conclusion

PRES is a potential neurological complication of COVID-19 related disease. COVID-19 patients with PRES may exhibit similar to mildly greater rates of hemorrhage compared to non-COVID-19 PRES patients.

## References

1. Abobaker A, Raba AA, Alzwi A. Extrapulmonary and atypical clinical presentations of COVID-19. *J Med Virol* 2020;92(11):2458–64. <https://doi.org/10.1002/jmv.26157>.
2. Hughes C, Nichols T, Pike M, Subbe C, Elghenzai S. Cerebral venous sinus thrombosis as a presentation of COVID-19. *Eur J Case Rep Intern Med* 2020;7(5): 001691. [https://doi.org/10.12890/2020\\_001691](https://doi.org/10.12890/2020_001691).

3. Oxley TJ, Mocco J, Majidi S, et al. Large-vessel stroke as a presenting feature of Covid-19 in the young. *N Engl J Med* Apr 2020. <https://doi.org/10.1056/NEJMc2009787>.
4. Radmanesh A, Derman A, Lui YW, et al. COVID-19 -associated diffuse leukoencephalopathy and microhemorrhages. *Radiology* 2020;202040. <https://doi.org/10.1148/radiol.2020202040>. May.
5. Sudalagunta SR, Sodalagunta MB, Kumbhat M, Settikere Nataraju A. Posterior reversible encephalopathy syndrome(PRES). *Oxf Med Case Reports* 2017;(4):omx011. <https://doi.org/10.1093/omcr/omx011>. Apr.
6. Moher D, Liberati A, Tetzlaff J, Altman DG, Group P. Preferred reporting items for systematic reviews and meta-analyses: the PRISMA statement. *PLoS Med* 2009;6(7):e1000097. <https://doi.org/10.1371/journal.pmed.1000097>. Jul.
7. Princiotta Cariddi L, Tabae Damavandi P, Carimati F, et al. Reversible encephalopathy syndrome (PRES) in a COVID-19 patient. *J Neurol Nov* 2020;267(11):3157–60. <https://doi.org/10.1007/s00415-020-10001-7>.
8. Colombo A, Martinelli Boneschi F, Beretta S, et al. Posterior reversible encephalopathy syndrome and COVID-19: a series of 6 cases from Lombardy, Italy. *eNeurologicalSci* 2021;22:100306. <https://doi.org/10.1016/j.ensci.2020.100306>. Mar.
9. Ye Q, Wang B, Mao J. The pathogenesis and treatment of the 'cytokine storm' in COVID-19. *J Infect* 2020;80(6):607–13. <https://doi.org/10.1016/j.jinf.2020.03.037>.
10. Mehta P, DF McAuley, Brown M, et al. COVID-19: consider cytokine storm syndromes and immunosuppression. *Lancet* 2020;395(10229):1033–4. [https://doi.org/10.1016/S0140-6736\(20\)30628-0](https://doi.org/10.1016/S0140-6736(20)30628-0). 03.
11. Franceschi AM, Ahmed O, Giliberto L, Castillo M. Hemorrhagic posterior reversible encephalopathy syndrome as a manifestation of COVID-19 infection. *AJNR Am J Neuroradiol* 2020;41(7):1173–6. <https://doi.org/10.3174/ajnr.A6595>. 07.
12. Rogg J, Baker A, Tung G. Posterior reversible encephalopathy syndrome (PRES): another imaging manifestation of COVID-19. *Interdiscip Neurosurg*. Dec 2020;22:100808. <https://doi.org/10.1016/j.inat.2020.100808>.
13. Fischer M, Schmutzhard E. Posterior reversible encephalopathy syndrome. *J Neurol* Aug 2017;264(8):1608–16. <https://doi.org/10.1007/s00415-016-8377-8>.
14. Osborn AG. *Osborn's brain: imaging, pathology, and anatomy.. 1st ed.* xi. Amirsys Pub; 2013. 1272 p.
15. Bartynski WS. Posterior reversible encephalopathy syndrome, part 1: fundamental imaging and clinical features. *AJNR Am J Neuroradiol Jun* 2008;29(6):1036–42. <https://doi.org/10.3174/ajnr.A0928>.
16. Hefzy HM, Bartynski WS, Boardman JF, Lacomis D. Hemorrhage in posterior reversible encephalopathy syndrome: imaging and clinical features. *AJNR Am J Neuroradiol Aug* 2009;30(7):1371–9. <https://doi.org/10.3174/ajnr.A1588>.
17. Schweitzer AD, Parikh NS, Askin G, et al. Imaging characteristics associated with clinical outcomes in posterior reversible encephalopathy syndrome. *Neuroradiology* Apr 2017;59(4):379–86. <https://doi.org/10.1007/s00234-017-1815-1>.
18. McKinney AM, Sarikaya B, Gustafson C, Truitt CL. Detection of microhemorrhage in posterior reversible encephalopathy syndrome using susceptibility-weighted imaging. *AJNR Am J Neuroradiol May* 2012;33(5):896–903. <https://doi.org/10.3174/ajnr.A2886>.
19. McKinney AM, Short J, Truitt CL, et al. Posterior reversible encephalopathy syndrome: incidence of atypical regions of involvement and imaging findings. *AJR Am J Roentgenol Oct* 2007;189(4):904–12. <https://doi.org/10.2214/AJR.07.2024>.
20. Therapeutic Management of Hospitalized Adults With COVID-19. Updated July 8, 2021. Accessed July 19, 2021.
21. Sachs JR, Gibbs KW, Swor DE, et al. COVID-19-associated Leukoencephalopathy. *Radiology* 2020;296(3):E184–5. <https://doi.org/10.1148/radiol.202021753>. 09.
22. Lang M, Buch K, Li MD, et al. Leukoencephalopathy associated with severe COVID-19 infection: sequela of hypoxemia? *AJNR Am J Neuroradiol* 2020;41(9):1641–5. <https://doi.org/10.3174/ajnr.A6671>. 09.
23. Freeman CW, Masur J, Hassankhani A, Wolf RL, Levine JM, Mohan S. Coronavirus disease (COVID-19)-related disseminated leukoencephalopathy: a retrospective study of findings on brain MRI. *AJR Am J Roentgenol* 2021;216(4):1046–7. <https://doi.org/10.2214/AJR.20.24364>. 04.
24. Radmanesh A, Raz E, Zan E, Derman A, Kaminetzky M. Brain imaging use and findings in COVID-19: a single academic center experience in the epicenter of disease in the United States. *AJNR Am J Neuroradiol* 2020;41(7):1179–83. <https://doi.org/10.3174/ajnr.A6610>. 09.
25. Gulko E, Oleksk ML, Gomes W, et al. MRI brain findings in 126 patients with COVID-19: initial observations from a descriptive literature review. *AJNR Am J Neuroradiol* 2020;41(12):2199–203. <https://doi.org/10.3174/ajnr.A6805>. 12.
26. Yong MH, YFZ Chan, Liu J, et al. A rare case of acute hemorrhagic leukoencephalitis in a COVID-19 patient. *J Neurol Sci* 2020;416:117035. <https://doi.org/10.1016/j.jns.2020.117035>. 09.
27. Varadan B, Shankar A, Rajakumar A, et al. Acute hemorrhagic leukoencephalitis in a COVID-19 patient—a case report with literature review. *Neuroradiology* May 2021;63(5):653–61. <https://doi.org/10.1007/s00234-021-02667-1>.
28. Doo FX, Kassim G, Lefton DR, Patterson S, Pham H, Belani P. Rare presentations of COVID-19: PRES-like leukoencephalopathy and carotid thrombosis. *Clin Imaging* Jan 2021;69:94–101. <https://doi.org/10.1016/j.clinimag.2020.07.007>.
29. Kishiy L, Casasola M, Banankhah P, et al. Posterior reversible encephalopathy syndrome (PRES) as a neurological association in severe Covid-19. *J Neurol Sci* 2020;414:116943. <https://doi.org/10.1016/j.jns.2020.116943>. 07.
30. Conte G, Avignone S, Carbonara M, et al. COVID-19-associated PRES-like encephalopathy with perivascular gadolinium enhancement. *AJNR Am J Neuroradiol* 2020;41(12):2206–8. <https://doi.org/10.3174/ajnr.A6762>. 04.
31. Dias DA, de Brito LA, Neves LO, RGS Paiva, Barbosa Júnior OA, JWL Tavares-Júnior. Hemorrhagic PRES: an unusual neurologic manifestation in two COVID-19 patients. *Arq Neuropsiquiatr* 2020;78(11):739–40. <https://doi.org/10.1590/0004-282X20200184>. 03.
32. Parada SC, Gao V, Gewirtz AN, et al. Posterior reversible encephalopathy syndrome in patients with COVID-19. *J Neurol Sci Sep* 2020;416:117019. <https://doi.org/10.1016/j.jns.2020.117019>.
33. Agarwal A, Pinho M, Raj K, et al. Neurological emergencies associated with COVID-19: stroke and beyond. *Emerg Radiol* Dec 2020;27(6):747–54. <https://doi.org/10.1007/s10140-020-01837-7>.
34. López Pérez V, Cora Vicente J, Echevarría Granados C, Salcedo Vázquez ML, Estol F, Tebar Cuesta MY. Postpartum consciousness disturbance: can covid-19 cause posterior reversible encephalopathy syndrome? *Rev Esp Anestesiol Reanim (Engl Ed)* Nov 2020;67(9):511–5. <https://doi.org/10.1016/j.redar.2020.06.008>.
35. D'Amore F, Vinacci G, Agosti E, et al. Pressing issues in COVID-19: probable cause to seize SARS-CoV-2 for its preferential involvement of posterior circulation manifesting as severe posterior reversible encephalopathy syndrome and posterior strokes. *AJNR Am J Neuroradiol* 2020;41(10):1800–3. <https://doi.org/10.3174/ajnr.A6679>. 10.
36. Ghosh R, Lahiri D, Dubey S, Ray BK, Benito-León J. Hallucinatory palinopsia in COVID-19-induced posterior reversible encephalopathy syndrome. *J Neuroophthalmol* 2020;40(4):523–6. <https://doi.org/10.1097/WNO.0000000000001135>. 12.
37. Sripadma PV, Rai A, Wadhwa C. Postpartum Atypical posterior reversible encephalopathy syndrome in a COVID-19 patient - an obstetric emergency. *J Stroke Cerebrovasc Dis* 2020;29(12):105357. <https://doi.org/10.1016/j.jstrokecerebrovasdis.2020.105357>. Dec.
38. Anand P, Lau KHV, Chung DY, et al. Posterior reversible encephalopathy syndrome in patients with coronavirus disease 2019: two cases and a review of the literature. *J Stroke Cerebrovasc Dis* Nov 2020;29(11):105212. <https://doi.org/10.1016/j.jstrokecerebrovasdis.2020.105212>.
39. Ordoñez-Boschetti L, Torres-Romero CM, Ortiz de Leo MJ. Associated posterior reversible encephalopathy syndrome (PRES) to SARS-CoV-2. Case report. *Neurologia (Engl Ed)* 2020;35(9):696–8. <https://doi.org/10.1016/j.nrl.2020.08.001>. 2020 Nov - Dec.
40. Gómez-Enjuto S, Hernando-Requejo V, Lapeña-Motilva J, et al. Verapamil as treatment for refractory status epilepticus secondary to PRES syndrome on a SARS-CoV-2 infected patient. *Seizure* 2020;08(80):157–8. <https://doi.org/10.1016/j.seizure.2020.06.008>.
41. Santos de Lima F, Klein S, El Ammar F, et al. Rapid development of seizures and PRES in a COVID-19 patient. *Epilepsy Behav Rep* 2021;15:100436. <https://doi.org/10.1016/j.ebr.2021.100436>.
42. Wijeratne T, Wijeratne C, Karimi L, Sales C, Crewther SG. Case report: posterior reversible leukoencephalopathy syndrome (PRES) as a Biologically predictable neurological association in severe COVID-19. First reported case from australia and review of internationally published cases. *Front Neurol* 2020;11:600544. <https://doi.org/10.3389/fneur.2020.600544>.
43. Talluri K, Lall N, Moreno MA, Nichols L, Bande D. Posterior reversible encephalopathy syndrome in a patient with SARS-CoV-2 infection treated with tocilizumab. *Cureus Feb* 2021;13(2):e13475. <https://doi.org/10.7759/cureus.13475>.