

CASE REPORT

Hip Arthroscopic Reduction and Fixation for Adolescent Acetabular Posterior Wall Fracture: A Case Report

Rong-mao Shi, MD, PhD¹ , Li-bo Yuan, MM¹, Chao-jun Tan, BM², An-xu Li, MM¹, Xiong Qiu, MM¹,
Bing Yang, MD, PhD³ , Hong-bo Tan, MD, PhD¹ 

¹Department of Orthopaedic Surgery, 920th Hospital of Joint Logistics Support Force and ²Department of Orthopaedic Surgery, Yunnan Boya Hospital, Kunming and ³Jointsurgery, Orthopedics Department, Peking University International Hospital, Beijing, China

Background: Posterior wall fracture is the most common type of acetabular fracture, the traditional open reduction and fixation through the Kocher–Langenbeck approach required a large incision and extensive muscle and soft tissue dissection, resulting in more blood loss, more complications and delayed recovery after the operation. Hip arthroscopy has been widely used in clinical practice but rarely reported in acetabular fractures.

Case Presentation: We present the case of a 14-year-old boy with acetabular posterior wall fracture who was treated with hip arthroscopy reduction and fixation using anchors. He began to walk with partial weight-bearing assisted by double crutches, and returned to school with crutches at 3 days after surgery. Although hip arthroscopy is technically more demanding, it's an optimal choice for selected patients of acetabular fracture with the advantages of less invasive and faster postoperative recovery.

Key words: Acetabulum; Arthroscopic surgery; Fracture fixation; Hip fractures

Introduction

As the most common type of acetabular fracture, the posterior wall fracture is considered to be the simplest and easily treatable fracture. More than 80% of nonoperative patients resulted in unsatisfactory clinical outcomes¹, therefore, open reduction and fixation has become the primary choice for the treatment of acetabular posterior wall fractures. In view of the anatomical characteristics of the acetabulum, an open surgery is accompanied by greater invasive and blood loss. Especially, it is less cost effective in the relatively simple cases that cannot be fixed with plates and screws, it is necessary to explore a minimally invasive reduction and fixation method for such cases. Hip arthroscopy has become the main surgical procedure for diagnosis and treatment of some hip diseases such as femoroacetabular impingement, Labrum injury and so on². Here, we performed a case of adolescent acetabular

posterior wall fracture treated by hip arthroscopy and report a successful outcome.

Case Presentation

A 14-year-old boy unfortunately suffered a traffic accident in a car that resulted pain and limited mobility in his right hip joint. He was initially admitted to the county hospital and computed tomography (CT) showed a fracture of the right posterior acetabular wall. The patient was transferred to our hospital 8 days after the injury. The preoperative 3-dimensional (3D) CT showed the fracture of the right posterior acetabular wall (Fig. 1A) and the major osseous fragment displaced significantly (Fig. 1B). An operative reduction of the fracture is essential to restore the instability of the hip. In order to achieve enhanced recovery after surgery and the patient can go back to school as soon as possible, hip arthroscopic reduction and fixation was performed.

Address for correspondence Hong-bo Tan, Department of Orthopaedic Surgery, 920th Hospital of Joint Logistics, Support Force, Kunming, Yunnan, China 650032 Tel: 13116955623; Fax: 087164774378; Email: tantoo@163.com and Bing Yang, Jointsurgery, Orthopedics Department, Peking University International Hospital, Beijing, China 102206 Tel: 15600583698; Fax: 69006900; Email: yangbin@foxmail.com

Disclosure: The author(s) declared no potential conflicts of interest with respect to the research, authorship, and/or publication of this article.
Received 21 January 2021; Revised 27 February 2021

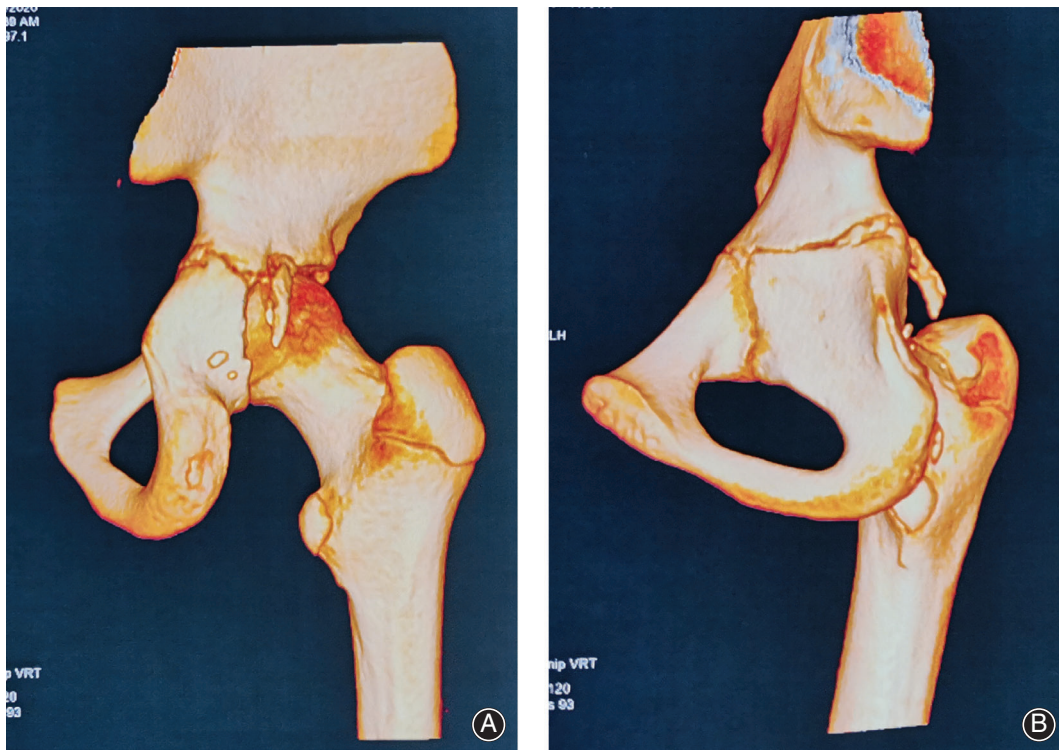


Fig. 1 (A) Preoperative posterior view of 3D-CT showed the fracture of the acetabular posterior wall. (B) Preoperative posterior oblique view of 3D-CT showed the displaced of the major osseous fragment.

Surgical Technique

Patient was in supine position on a fracture table with the right limb in traction after general anesthesia, and a C-arm was used for fluoroscopic guidance to establish the anterolateral portal. Anterior and posterolateral portals were made under direct visualization. After hematoma evacuation by water lavage and synovectomy, the major osseous fragment of the acetabular posterior wall was found (Fig. 2) and used shaver handpiece to push it reduction. Two 2.9 mm bio-absorbable anchors (OSTEORAPTOR Suture Anchor, Smith & Nephew, Andover, MA) were inserted into the superior and inferior of the fracture surface of acetabular posterior wall adjoined the major osseous fragment. The sutures of the anchors embraced the osseous fragment and tied it up to fix (Fig. 3). Finally, a 2.8 mm anchor (TWINFIX Ti anchor; Smith & Nephew, Andover, MA) was used to through the center of the fragment and inserted into the posterior wall, the sutures of this anchor and the bio-absorbable anchors were tied together to enhanced fixation. A diagram (Fig. 4) showed the surgical procedure.

A postoperative 3D-CT was performed and showed anatomical reduction of the major osseous fragment (Fig. 5). The next day after the surgery, the patient began to walk with partial weight-bearing assisted by double crutches and returned to school with crutches at 3 days after surgery.

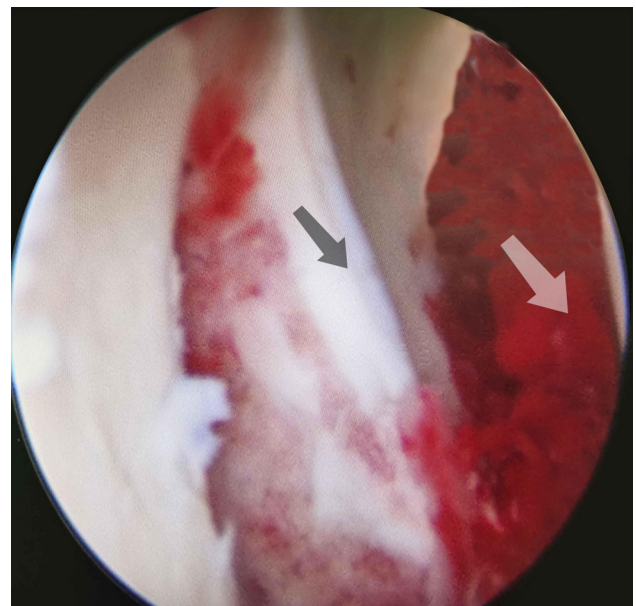


Fig. 2 The arthroscopic view showed the major osseous fragment (black arrow) of the acetabular posterior wall and residual hemarthrosis (white arrow).

At 3 months follow up postoperatively, anteroposterior X-ray of pelvis showed bone union of the acetabular posterior wall (Fig. 6), the patient was pain free and recovered full activities.

Discussion

Bed rest and traction were main conservative treatment methods for acetabular posterior wall fractures that were not significantly displaced and do not affect the stability of the hip joint. Complications of bed rest include thromboembolism, pneumonia, bedsore and Joint stiffness. Most acetabular posterior wall fractures require open reduction and internal fixation, which required wide dissection and led to a prolonged recovery. In this case, the adolescent patient wanted fastest recovery in order to return to school, but the posterior wall fracture was significantly displaced and requires surgical reduction and fixation, compared to hip arthroscopy, open reduction and internal fixation was a viable option but not the optimal option.

As a representative of minimally invasive surgery, arthroscopic technology has been successfully used in the treatment of joint diseases and intra-articular fractures. For the diagnosis and treatment of femoroacetabular impingement, pigmented villonodular synovitis, septic arthritis and synovial chondromatosis, hip arthroscopy is a gold-standard procedure². The application of hip arthroscopy in trauma is still less reported. A systematic review by Niroopan *et al.* in 2016 showed the hip arthroscopy was an effective and safe approach in trauma, 32 studies (25 case reports and seven case series) reported a total of 144 hip traumatic patients underwent hip arthroscopy for six indications: eight patients for bullet extraction, six for femoral head fixation, 82 for loose body removal, six for acetabular fracture fixation, 20 for labral intervention, and 23 for ligamentum teres debridement. Successful surgery was achieved in 96% of these patients³(Table 1).

To our knowledge, there are no cases series of hip arthroscopic treatment of acetabular fractures were reported

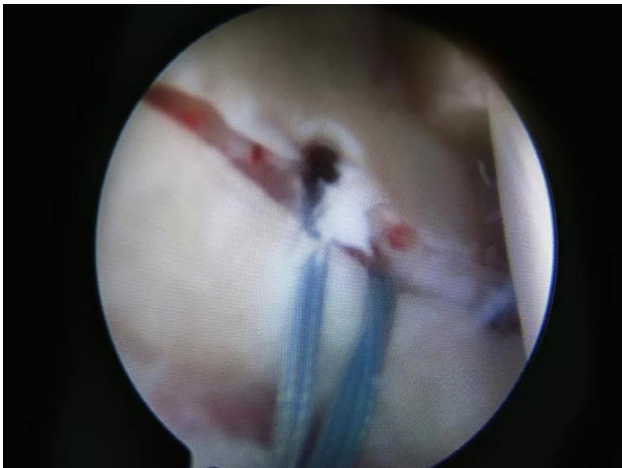

Fig. 3 The arthroscopic view showed the major osseous fragment was replaced and fixed by anchors.

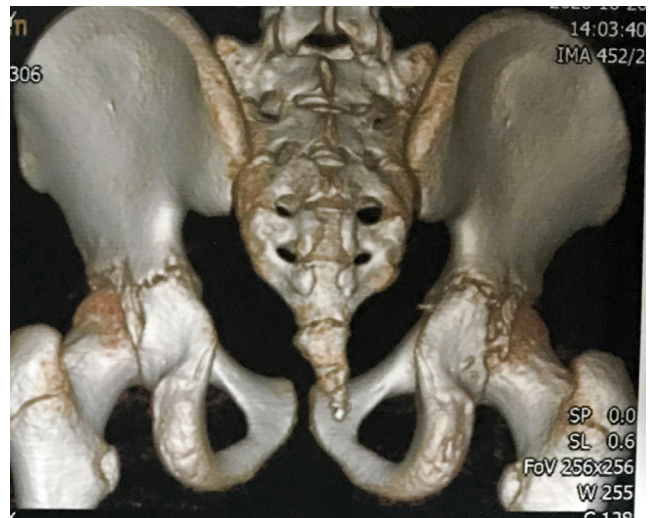


Fig. 5 Postoperative 3D-CT demonstrated anatomical reduction of the major osseous fragment of the posterior wall.

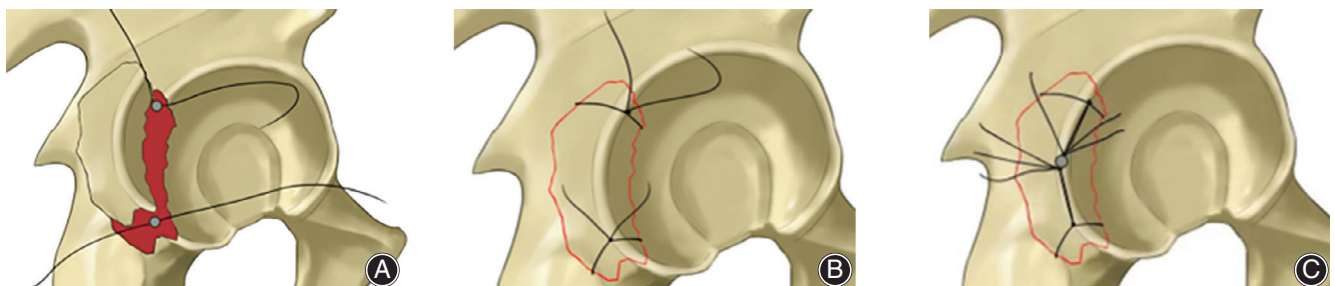


Fig. 4 Surgical procedure diagrams: (A) Placed two bio-absorbable anchors in the superior and inferior of the fracture surface of acetabular posterior wall adjoined the major osseous fragment. (B) Reduced the osseous fragment and tied it up by the sutures of the anchors. (C) Placed a Ti anchor into the posterior wall through the center of the fragment and tied its sutures together with the sutures of bio-absorbable anchors.

so far, only several case reports. In 2003, Yamamoto *et al.* first described the usefulness of hip arthroscopic in hip trauma and reported 11 hips from 10 cases, and one acetabular weight-bearing region fracture was treated by reduction and percutaneous pinning fixation under arthroscopic observation⁴. Yang *et al.* described the technique of percutaneous screw fixation of acetabular fractures using arthroscopy as an assisting tool for intra-articular observation and report two cases resulted satisfied outcomes⁵. A transverse fracture of the acetabulum and another anterior column fracture of the

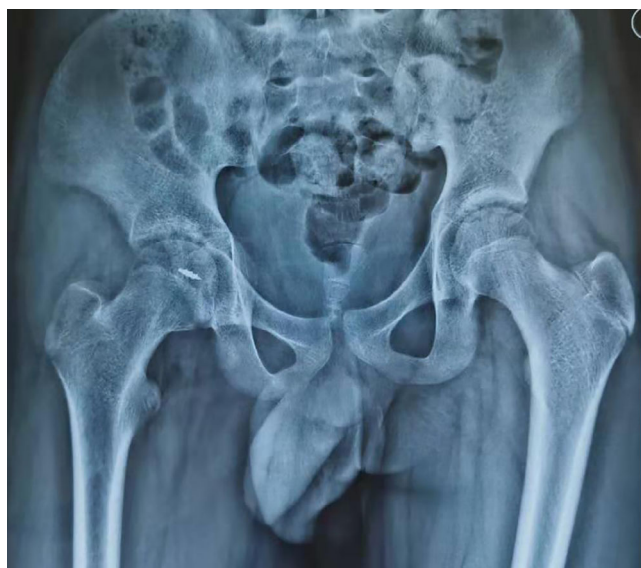

Fig. 6 Postoperative 3 months anteroposterior X-ray of pelvis showed bone union of the acetabular posterior wall.

acetabulum were fixed percutaneously using 6.5-mm-diameter cannulated screws under fluoroscopic guidance and arthroscopy was used for direct visualization of the fracture site until satisfactory compression⁵. Similarly, Kim *et al.* reported two patients in 2014, one posterior acetabular wall fracture and one acetabular anterior column fracture, fixed by percutaneously 4.0-mm-diameter and 3.5-mm-diameter cannulated screws under direct arthroscopic visualization⁷. In addition, Park *et al.*⁹ reported two and Gürpınar *et al.*¹⁰ reported one acetabular posterior wall fractures were treated with the similar surgical technique.

For the acetabular wall fracture fragment too little to fix by cannulated screws, hip arthroscopic debridement to remove osseous fragment or/and osteosynthesis using anchors to fix the fragment was another effective method^{6,8}. For this adolescent patient, the little osseous fragments were removed by lavage to prevent traumatic arthritis, and the primary fragment was fixed by three anchors. The disadvantages of this method are the fixed effect is not as good as screw fixing, and the surgical procedure is more difficult. But the advantage is the whole process is under hip arthroscopy observation and without more fluoroscopic guidance for percutaneous screws.

Kim *et al.* stated that the indications of hip arthroscopic surgery for acetabular fractures is narrow and can be made only for those cases with minimal and moderate displaced⁷. Based on experience, we believe that the indications of osteosynthesis for acetabular fracture under hip arthroscopy were also limited. This osteosynthesis only suitable for the simple acetabular wall fracture with small fragment which easy to reduce through the arthroscopic portals. Indications of hip arthroscopy with percutaneous screw fixation was more than osteosynthesis and can be used for more types of acetabular wall fracture and acetabular anterior or posterior column fractures do not required open reduction^{5,7}. With the improvement of arthroscopic instruments

TABLE 1 Hip arthroscopic management of acetabular fracture reported in the literature

Author	Year	Study design	No. of hips	Main injury	Surgical methods
Yamamoto <i>et al.</i> ⁴	2003	Case series	11 hips (1 acetabular fracture)	Weight-bearing region fracture	Reduction and percutaneous pinning were performed under arthroscopic observation
Yang <i>et al.</i> ⁵	2010	Case report	2	Case 1: transverse fracture Case 2: anterior column fracture	Fixed by percutaneous screw and arthroscopy as an assisting tool for intra-articular observation
Park <i>et al.</i> ⁶	2013	Case report	1	Posterior wall fractures, femoral head fractures, dislocation	The avulsed torn labrum was reattached with 2 anchors through the midanterior portal. Osteochondral fragments were curetted and removed.
Kim <i>et al.</i> ⁷	2014	Case report	2	Case 1: posterior wall fracture Case 2: anterior column fracture	Fixed by cannulated screws under direct arthroscopic visualization
Stabile <i>et al.</i> ⁸	2014	Case report	1	Posterior wall fracture, dislocation, bucket-handle labral tear	Bucket-handle labral tear had an attached osseous fragment that was reduced under direct visualization with the use of a switching stick and fixed by anchors
Park <i>et al.</i> ⁹	2016	Case report	2	Posterior wall fracture	Cannulated screws to fixate the fragment under direct arthroscopic visualization
Gürpınar <i>et al.</i> ¹⁰	2019	Case report	1	Posterior wall fracture	Arthroscopic reduction and fixation using a cannulated screw

for fixation of reduced acetabulum and surgical technique, arthroscopic minimally invasive surgery may be extended to more complex acetabular fracture.

Hip arthroscopy for reduction and fixation of acetabular fracture offers the advantage of superior visualization and reduction of the articular surface, and additional benefits from joint lavage and debridement can help to remove the loose osteochondral fragments, which is thought to cause future osteoarthritis⁴. Although hip arthroscopy is technically more demanding, it is an optimal choice for selected

acetabular fractures with the advantages of less invasive and faster postoperative recovery.

Acknowledgment

The author(s) disclosed receipt of the following financial support for the research, authorship, and/or publication of this article: this work is funded by Yunnan Province Talents Program (2018HB001) and The National Key Research and Development Program of China (2017YFC1103904).

References

1. Baumgaertner MR. Fractures of the posterior wall of the acetabulum. *J Am Acad Orthop Surg*, 1999, 7: 54–65.
2. Jamil M, Dandachli W, Noordin S, Witt J. Hip arthroscopy: indications, outcomes and complications. *Int J Surg*, 2018, 54: 341–344.
3. Niroopan G, de Sa D, Macdonald A, Burrow S, Larson CM, Ayeni OR. Hip arthroscopy in trauma: a systematic review of indications, efficacy, and complications. *Art Ther*, 2016, 32: 692–703.
4. Yamamoto Y, Ide T, Ono T, Hamada Y. Usefulness of arthroscopic surgery in hip trauma cases. *Art Ther*, 2003, 19: 269–273.
5. Yang JH, Chouhan DK, Oh KJ. Percutaneous screw fixation of acetabular fractures: applicability of hip arthroscopy. *Art Ther*, 2010, 26: 1556–1561.
6. Park MS, Yoon SJ, Choi SM. Hip arthroscopic management for femoral head fractures and posterior acetabular wall fractures (Pipkin type IV). *Arthrosc Tech*, 2013, 2: e221–e225.
7. Kim H, Baek J, Park S, Ha Y. Arthroscopic reduction and internal fixation of acetabular fractures. *Knee Surg Sports Traumatol Arthrosc*, 2014, 22: 867–870.
8. Stabile KJ, Neumann JA, Mannava S, Howse EA, Stubbs AJ. Arthroscopic treatment of bucket-handle labral tear and acetabular fracture. *Arthrosc Tech*, 2014, 3: e283–e287.
9. Park JY, Chung WC, Kim CK, Huh SH, Kim SJ, Jung BH. Arthroscopic reduction and transportal screw fixation of acetabular posterior wall fracture: technical note. *Hip Pelvis*, 2016, 28: 120–126.
10. Gürpınar T, Polat B, Kanay E, Polat A, öztürkmen Y. Arthroscopic fixation of a posterior acetabular wall fracture: a case report. *Cureus*, 2019, 11: e6264.