



# First Co-morbidity of *Lophomonas blattarum* and COVID-19 Infections: Confirmed Using Molecular Approach

Maryam Nakhaei<sup>1</sup> · Mahdi Fakhar<sup>1</sup> · Ali Sharifpour<sup>1,2</sup> · Elham Sadat Banimostafavi<sup>1,3</sup> · Zakaria Zakariaei<sup>1,4</sup> · Hossein Mehravaran<sup>1,2</sup> · Reza Saberi<sup>1</sup> · Sepideh Safanavaei<sup>1,2</sup> · Siavash Abedi<sup>1,2</sup> · Masoud Aliyali<sup>1,2</sup> · Mostafa Soleimani<sup>1</sup>

Received: 19 June 2021 / Accepted: 10 September 2021 / Published online: 22 October 2021  
© Witold Stefański Institute of Parasitology, Polish Academy of Sciences 2021

## Abstract

**Introduction** Lophomoniasis is caused by *Lophomonas* spp., a new emerging protozoan, which commonly affects the human lower respiratory tract. The *Lophomonas* parasite mostly lives commensally in the hindgut of cockroaches.

**Case Presentation** We present the case of a 33-year-old woman, 30 weeks pregnant, who had severe COVID-19. She was intubated upon admission and began the routine COVID-19 treatment. To rule out possible super infection dual with COVID-19, microscopic examination of the patient's mini-bronchoalveolar lavage (mini-BAL) specimen, revealed *L. blattarum*, which was identified by the SSU rRNA-PCR and sequencing approaches (accession number: MZ093069). According to that, the patient was treated successfully with metronidazole.

**Conclusion** To prevent serious complications, lophomoniasis should be listed in co-morbidity cases of COVID-19 infection during the COVID-19 pandemic worldwide. To the best of our knowledge, this is the first co-infection of *Lophomonas blattarum* and COVID-19 in the world which has been confirmed using a molecular approach.

**Keywords** *Lophomonas blattarum* · COVID-19 · Co-morbidity · PCR · Iran

## Introduction

SARS-CoV-2 infection causes COVID-19, a disease with a wide range of clinical symptoms. While the majority of patients with COVID-19 experience only asymptomatic or moderate disease, at-risk patients can develop serious diseases that necessitate hospitalization and respiratory support. Older age, as well as underlying comorbidities like hypertension, cardiovascular disease, and diabetes, has been identified as risk factors for disabling conditions [1]. There is currently little known about SARS-CoV-2 infections in pregnancy. It is linked to an increased risk of preterm birth in pregnant women and, in some countries, a higher risk of maternal death [2]. Pregnancy may complicate the already complex management of infection with an emerging pathogen in the subset of pregnant women who develop severe or critical disease [3]. *Lophomonas* is a neglected and emerging protozoan which infects human lower (mostly) and upper respiratory tracts. It mostly lives as a commensal agent in the hindgut of cockroaches [4, 5]. For the last decades, lower and upper respiratory infections due to *Lophomonas* have been reported in some areas of the world, particularly in

✉ Mahdi Fakhar  
mahdif53@yahoo.com

✉ Ali Sharifpour  
asharifpour0209@yahoo.com

<sup>1</sup> Toxoplasmosis Research Center, School of Medicine, Communicable Diseases Institute, Iranian National Registry Center for Lophomoniasis and Toxoplasmosis, Mazandaran University of Medical Sciences, Km 18, Farah-Abad Road, PO Box 48471–91971, Sari, Iran

<sup>2</sup> Pulmonary and Critical Care Division, Imam Khomeini Hospital, Iranian National Registry Center for Lophomoniasis (INRCL), Mazandaran University of Medical Sciences, PO Box 48166-33131, Sari, Iran

<sup>3</sup> Department of Radiology, Imam Khomeini Hospital, Mazandaran University of Medical Sciences, Sari, Iran

<sup>4</sup> Toxicology and Forensic Medicine Division, Imam Khomeini Hospital, Mazandaran University of Medical Sciences, Sari, Iran

China and Iran. Iran has been known for the highest number of lophomoniasis cases reported in the world [6–11]. Moreover, *Lophomonas blattarum* (*L. blattarum*) has recently been isolated from the cockroaches in Mazandaran province, northern Iran [5].

To date, co-infections of lophomoniasis with other infectious diseases have been reported rarely all over the world. There is some evidence regarding co-morbidity of lophomoniasis with HIV and tuberculosis [4, 9, 12]. According to our knowledge, there have been no reports of lophomoniasis/COVID-19 co-infection. In this case study, we describe the diagnosis and treatment of a woman who was infected with *Lophomonas* and COVID-19 at the same time.

## Case Presentation

A 33-year-old pregnant woman, at 30 weeks' gestation, was admitted to the emergency unit on December 6, 2020. She suffered from hypertension, low back pain (LBP) with leg pain, fever, cough, shortness of breath and bilateral conjunctivitis. The patient had anemia (HG = 10.3), leukocytosis (20.4), neutrophilia (90.5%) and lymphopenia (6.1%) in the initial studies, with elevated ESR (100), CRP (53.7), and LDH (939), but all other parameters were normal.

Her chest was imaged using high-resolution computed tomography (HRCT) and revealed bilateral multilobar patchy ground glass opacities, alveolar consolidations, and mild to moderate pleural effusion.

Due to the pandemic of COVID-19 and the patient's suspicion of this infection, a sample was taken from the patient's throat and larynx. The patient's real-time reverse transcriptase–polymerase chain reaction (RT-PCR) test was positive, and she was admitted to the intensive care unit (ICU). Gradually, the patient's shortness of breath increased, and the patient underwent intubation. Because of the risk of fetal death, the patient underwent cesarean section. The newborn was delivered from her mother with good health and negative RT-PCR results for COVID-19. The patient was treated with enoxaparin sodium, ticlopidine, remdesivir, amikacin, colomycin, methylprednisolone pulse therapy, magnesium sulfate and *N*-Acetylcystein (NAC). After 20 days, the patient was extubated from the mechanical ventilator. However, due to the persistence of cough and tracheal secretions, mini-BAL procedure, as less invasive, safe and quick approach, was performed by a sterile suction catheter of size 12 French. About 20 mL of sodium chloride 0.9% were instilled through the catheter and aspirate was collected in a sterile polypropylene tube by suction. After that, the endotracheal secretions at ambient condition were transported to the Iranian National Registry Center for Lophomoniasis (INRCL) at Imam Khomeini hospital,

Mazandaran University of Medical Sciences, Sari, Iran, to rule out the lophomoniasis.

Based on microscopic and specific PCR techniques which are described below, lophomoniasis was confirmed. Thus, metronidazole 500 mg three times daily for two weeks was added to COVID-19 treatment to treat *Lophomonas* infection. The patient was discharged from the hospital after 27 days with complete recovery. This study was reviewed and approved by the research ethics committee of Mazandaran University of Medical Sciences (IR.MAZUMS.REC. 1399.255).

## Laboratory Approaches and Findings to Rule Out Lophomoniasis

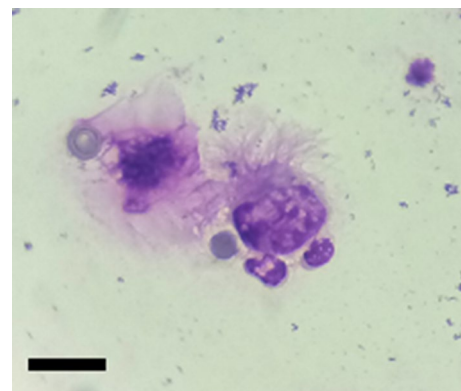
### Microscopic Examination

A mini-BAL specimen (about 20 mL) was centrifuged at  $2000 \times g$  for 5 min. Then, the sediment was observed under ( $\times 40$ ) magnification light microscope. Motile trophozoite of *Lophomonas* was detected in a direct wet-mount examination, which was confirmed by Giemsa staining technique (see Fig. 1).

### Molecular Identification

#### DNA Extraction

The sediment of the mini-BAL specimen was submitted to DNA extraction using the 200  $\mu\text{L}$  of the specimen was homogenized in 200  $\mu\text{L}$  of digestive buffer containing 50 mM Tris–HCl (pH 7.6), 1 mM EDTA and 1% Tween 20, to which 20  $\mu\text{L}$  of the proteinase K solution (20 mg enzyme/mL) was added. The homogenized solution was then incubated overnight at 45 °C. The subsequent homogenate was



**Fig. 1** Giemsa stained smear showing a trophozoite of *Lophomonas blattarum* in mini-BAL specimen ( $\times 1000$ ). Bar = 10  $\mu\text{m}$

then given 200  $\mu\text{L}$  of phenol:chloroform:isoamyl alcohol (25:24:1) solution. The solution was centrifuged at 14,000 g for 15 min after being vigorously shaken. The supernatant was put into a new microtube, which was then filled with 400 mL of cold 100% ethanol and maintained at  $-20\text{ }^{\circ}\text{C}$  for 2 h. Following that, 200  $\mu\text{L}$  of 70% ethanol were added to the sediment, centrifuged, and the precipitate was suspended in 50  $\mu\text{L}$  of double-distilled water and kept at  $4\text{ }^{\circ}\text{C}$  until use.

### SSU rRNA-PCR and Sequencing

Molecular detection of *Lophomonas* was performed by genus-specific small subunit ribosomal RNA (SSU rRNA) PCR. The initial pairs used were forward (F) 5'-GAG AAG GCG CCT GAG AGA T-3' and reverse (R) 5'-ATG GGA GCA AAC TCG CAG A-3' as described by Fakhar *et al.* [10], amplifying a region of 214 base pairs (bp) (Fakhar *et al.* 2019). The amplified operations used a total volume of 25  $\mu\text{L}$ , which included 12.5  $\mu\text{L}$  Master Mix (Fermentas, Inc.), 1  $\mu\text{L}$  of each primer, 5  $\mu\text{L}$  of extracted DNA, and 5.5  $\mu\text{L}$  of distilled water. In a thermocycler (Corbett Research, Sydney, Australia), 35 cycles were done, with an initial denaturation at  $94\text{ }^{\circ}\text{C}$  for 2 min, followed by 40 cycles of  $94\text{ }^{\circ}\text{C}$  for 1 min,  $57\text{ }^{\circ}\text{C}$  for 1 min, and  $94\text{ }^{\circ}\text{C}$  for 1 min.

The PCR products were then electrophoresed on a 1.5 percent (w/v) agarose gel in Tris–borate–EDTA (TBE) buffer for 6  $\mu\text{L}$ . After staining with SafeView™ DNA Stains, a 214-bp band was identified using UV transillumination (Applied Biological Materials, Inc.). Then, to species identification, the PCR product was sequenced using Sanger sequencing technology and then edited with BioEdit software (v.7.2). Next, the sequence result of the isolate was deposited in the GenBank by BanKit (Accession Numbers: MZ093069). The identity of this isolate in comparison with others available *L. blattarum* that was reported from Iran (Accession Numbers: MZ093070-78 and MN: 243135.1), were 98.5% and 99–100%, respectively.

### Discussion

According to a systematic study, the most frequent clinical symptoms of COVID-19 in pregnant women are fever and cough, with sore throat and diarrhea being less common. Elevated neutrophil ratios and reduced lymphocyte ratios are typical at laboratory demonstrations. The majority of births result in a cesarean operation, which is far higher than the WHO's prescription for vaginal delivery, which may be considered by a gynecologist to avoid maternal respiratory distress during pregnancy. It is one of the most common obstetrical complications and the leading cause of neonatal morbidity and mortality. They would have chronic long-term health problems if they survived [13, 14]. The cords

of affected mothers should be removed as soon as possible, and their newborns should be isolated and tested as soon as possible [15].

*Lophomonas* is a neglected parasite reported from a few countries which still remains unknown to many medical scientists [16]. Lophomoniasis is endemic in several areas of Iran [5–11]. About the fact that this condition is commonly seen in patients with immunodeficiency in other countries [17], it is often reported in patients with immunocompetent in Iran [6–11]. Lophomoniasis symptoms such as cough, fever and dyspnea are common in other respiratory infections. As a result, diagnosing and treating this infection is challenging [18]. Metronidazole is considered as the first-line therapeutic choice for lophomoniasis treatment [18]. Recent studies have revealed that metronidazole reduces the levels of inflammatory factors such as IL8, IL6, IL1B, TNF $\alpha$ , IL12, and IFN $\gamma$ , as well as the levels of CRP and neutrophil count, which were increased during COVID-19 infection. Additionally, metronidazole has the potential to increase the number of circulatory lymphocytes [19]. Prescribing this drug, in addition to eliminating the *Lophomonas* infection, may have accelerated the patient's response to treatment for COVID-19 infection.

In several reports, *L. blattarum* was considered an opportunistic infection in patients with kidney and liver allograft transplantation, under corticosteroid therapy, HIV infection, and tuberculosis [4]. SARS-CoV-2 infection impairs the immune system, making individuals more susceptible to other infections and reactivating latent infections [20]. According to a meta-analysis study, patients with chronic pulmonary disease who have underlying lung scratches are at risk of developing severe cases of COVID-19 [21]. Many problems which occur from co-infection in a pregnant woman with COVID-19, which may be due to complications of COVID-19 itself that are caused by another infection. All infections may intensify each other's complications, or drug reactions between medications used to treat certain infections [13].

*Lophomonas* parasite appears to be involved in the severity of COVID-19 disease and can be considered as a risk factor. Hence, managing and diagnosing co-infections is critical in clinical practice. Since lophomoniasis is prevalent in several areas of the world such as Iran [6–11], consequently, it should be listed in co-morbidity cases of COVID-19 infection through the COVID-19 pandemic worldwide.

### Conclusion

To the best of our knowledge, for the first time, co-occurrence of COVID-19 and lophomoniasis is reported in this paper. Many febrile infections can look like COVID-19, and SARS-CoV-2 infection can help spread or reactivate

infectious diseases. We must not overlook other infectious diseases with related clinical manifestations in the midst of the COVID-19 pandemic. We recommend that healthcare systems be vigilant to enable early identification of co-infections such as *Lophomonas* with COVID-19. All symptomatic COVID-19 cases with similar symptoms should be investigated for other common infections in endemic regions, especially in pregnant women to avoid complications.

**Acknowledgements** The authors would like to express their appreciation to all hospital nurses who worked tirelessly during the COVID-19 pandemic.

**Funding** Financial support for this study was received from the INRCL at Mazandaran University of Medical Sciences, Sari, Iran (No: 7712).

## References

- Gebrecherkos T, Gessesse Z, Kebede Y, Gebreegzabher A, Tassew G, Abdulkader M, Ebuy H, Desta A, Hailu A, Harris V (2021) Effect of co-infection with parasites on severity of COVID-19. medRxiv PPR277525. <https://doi.org/10.1101/2021.02.02.21250995>
- Lorenz C, Azevedo TS, Chiaravalloti-Neto F (2020) COVID-19 and dengue fever: a dangerous combination for the health system in Brazil. *Travel Med Infect Dis* 35:1–2. <https://doi.org/10.1016/j.tmaid.2020.101659>
- Kucirka LM, Norton A, Sheffield JS (2020) Severity of COVID-19 in pregnancy: a review of current evidence. *Am J Reprod Immunol* 84:e13332. <https://doi.org/10.1111/aji.13332>
- Li R, Gao ZC (2016) *Lophomonas blattarum* infection or just the movement of ciliated epithelial cells? *Chin Med J* 129:739–742. <https://doi.org/10.4103/0366-6999.178025>
- Motevalli-Haghi SF, Shemshadian A, Nakhaei M, Faridnia R, Dehghan O, Shafaroudi MM, Kelarijani MN, Nikookar SH, Kalani H, Fakhar M (2021) First report of *Lophomonas* spp. in German cockroaches (*Blattella germanica*) trapped in hospitals, northern Iran. *J Parasit Dis*. <https://doi.org/10.1007/s12639-021-01381-2>
- Berenji F, Fata A, Vakili V, Sayedi SJ, Abdollahi B, Imanfar H, Nakhaei M, Parian M, Khorasani SR (2016) Unexpected high rate of *Lophomonas blattarum* in resistant upper and lower respiratory infection. *Health Sci* 5:74–80. <https://doi.org/10.1003/0326-6039.108011>
- Mirzazadeh F, Berenji F, Amini M, Salehi M, Shamsian A, Fata A, Parian M, Nakhaei M, Ghofraniha L (2017) *Lophomonas blattarum* in asthmatic patients and control group. *J Res Med Dent Sci* 5:1–5. <https://doi.org/10.24896/jrmds.2017551>
- Ghafarian N, Bakhtiari E, Berenji F, Nakhaei M, Nakhaei B, Jamali-Behnam F, Sayedi J (2018) The study of *Lophomonas blattarum* infection in children with respiratory symptoms: a descriptive clinical study in north east of Iran. *Int J Pediatr* 6:7797–7802. <https://doi.org/10.22038/ijp.2018.29199.2555>
- Talebian M, Berenji F, Amini M, Sayedi SJ, Shamsian A, Afzalaghae M, Fata A, Parian M, Nakhaei M (2018) A study about clinical symptoms and laboratory signs of adult and pediatric patients with *Lophomonas blattarum*. *J Res Med Dent Sci* 6:312–317. <https://doi.org/10.24896/jrmds.20186151>
- Fakhar M, Nakhaei M, Sharifpour A, Banimostafavi ES, Abedi S, Safanavaei S, Aliyali M (2019) First molecular diagnosis of *Lophomoniasis*: the end of a controversial story. *Acta Parasitol* 64:390–393. <https://doi.org/10.2478/s11686-019-00084-2>
- Fakhar M, Nakhaei M, Sharifpour A, Safanavaei S, Abedi S, Tabaripour R, Aliyali M, Modanloo M, Saberi R, Kalani H, Banimostafavi ES (2021) Morphological and molecular identification of emerged *Lophomonas blattarum* infection in Mazandaran Province, northern Iran: first registry-based study. *Acta Parasitol*. <https://doi.org/10.1007/s11686-021-00422-3>
- Verma S VG, Singh DV, Mokta J, Negi RS, Jhobta A, Kanga A (2015) Dual infection with pulmonary tuberculosis and *Lophomonas blattarum* in India. *Int J Tuberc Lung Dis* 19:368–369. <https://doi.org/10.5588/ijtld.14.0513>
- Abbas AM, Salah S, Fathy SK, Rashad A, AboBakr A, Yousof EA, Saeed A, Youssef EN, Shaltout AS, Ahmed OA (2020) Role of co-infection in the immunopathology of COVID-19 in pregnancy. *Arch Health Sci* 4:1–6. [https://doi.org/10.31829/2641-7456/ahs2020-4\(1\)-117](https://doi.org/10.31829/2641-7456/ahs2020-4(1)-117)
- Hassanipour S, Faradonbeh SB, Momeni K, Heidarifard Z, Khosousi M-J, Khosousi L, Ameri H, Arab-Zozani M (2020) A systematic review and meta-analysis of pregnancy and COVID-19: signs and symptoms, laboratory tests, and perinatal outcomes. *Int J Reprod Biomed* 18:1005–1018. <https://doi.org/10.18502/ijrm.v18i12.8022>
- Asadi L, Tabatabaei RS, Safinejad H, Mohammadi M (2020) New corona virus (COVID-19) management in pregnancy and childbirth. *Arch Clin Infect Dis* 15:e102938. <https://doi.org/10.5812/archcid.102938>
- Keighobadi M, Nakhaei M, Sharifpour A, Khasseh AA, Safanavaei S, Tabaripour R, Aliyali M, Abedi S, Mehravaran H, Banimostafavi ES (2020) A bibliometric analysis of global research on *Lophomonas* sp. in scopus (1933–2019). *Infect Disord Drug Targets* 21:230–237. <https://doi.org/10.2174/1871526520666200727153142>
- Xue J LYL, Yu X-M, Li D-K, Liu M-F, Qiu J-F, Xue J-J (2014) Bronchopulmonary infection of *Lophomonas blattarum*: a case and literature review. *Korean J Parasitol* 52:521–525. <https://doi.org/10.3347/kjp.2014.52.5.521>
- Martinez-Girón R, van Woerden HC (2013) *Lophomonas blattarum* and bronchopulmonary disease. *J Med Microbiol* 62:1641–1648. <https://doi.org/10.1099/jmm.0.059311-0>
- Gharebaghi R, Heidary F, Moradi M, Parvizi M (2020) Metronidazole; a potential novel addition to the COVID-19 treatment regimen. *Arch Acad Emerg Med* 8:e40. <https://doi.org/10.1139/aaem.1.559332-5>
- Chen X, Liao B, Cheng L, Peng X, Xu X, Li Y, Hu T, Li J, Zhou X, Ren B (2020) The microbial coinfection in COVID-19. *Appl Microbiol Biotechnol* 104:7777–7785. <https://doi.org/10.1007/s00253-020-10814-6>
- Liu H, Chen S, Liu M, Nie H, Lu H (2020) Comorbid chronic diseases are strongly correlated with disease severity among COVID-19 patients: a systematic review and meta-analysis. *Aging Dis* 11:668–678. <https://doi.org/10.14336/AD.2020.0502>

**Publisher's Note** Springer Nature remains neutral with regard to jurisdictional claims in published maps and institutional affiliations.