



Since January 2020 Elsevier has created a COVID-19 resource centre with free information in English and Mandarin on the novel coronavirus COVID-19. The COVID-19 resource centre is hosted on Elsevier Connect, the company's public news and information website.

Elsevier hereby grants permission to make all its COVID-19-related research that is available on the COVID-19 resource centre - including this research content - immediately available in PubMed Central and other publicly funded repositories, such as the WHO COVID database with rights for unrestricted research re-use and analyses in any form or by any means with acknowledgement of the original source. These permissions are granted for free by Elsevier for as long as the COVID-19 resource centre remains active.



## Case Report

# Pure red cell aplasia accompanied by COVID-19 successfully treated using cyclosporine

Susumu Yamazaki<sup>a,\*</sup>, Erika Naito<sup>a</sup>, Ryu Sekiya<sup>a</sup>, Saneshiro Yogi<sup>a</sup>, Kenichiro Komiyama<sup>a</sup>, Yoshitaka Miyakawa<sup>b</sup>, Makoto Nagata<sup>a</sup>

<sup>a</sup> Department of Respiratory Medicine, Saitama Medical University Hospital, Saitama, Japan

<sup>b</sup> Department of General Internal Medicine, Saitama Medical University Hospital, Saitama, Japan



## ARTICLE INFO

**Keywords:**  
COVID-19  
Pure red cell aplasia  
Cyclosporine

## ABSTRACT

A 67-year-old Japanese man was admitted to our hospital with severe coronavirus disease 2019 (COVID-19) in March 2020. Mechanical ventilation was initiated 8 days after admission, due to severe respiratory failure. Multiple severe complications such as liver dysfunction, arrhythmia, brain infarction, and venous thromboembolism were also observed. We initially diagnosed Coombs test-positive warm autoimmune hemolytic anemia. Corticosteroids proved ineffective and anemia worsened with severe erythroid hypoplasia (0.5% erythroblasts in bone marrow), so we diagnosed pure red cell aplasia (PRCA). We also identified massive infiltration of cytotoxic T-lymphocytes expressing CD8, granzyme B, and perforin in bone marrow. Systemic cyclosporine was started, with full resolution of anemia and no need for blood transfusions after 4 weeks. We believe that this represents the first report of COVID-19-associated PRCA successfully treated using cyclosporine.

## Funding

None.

## Authorship statement

ICMJE Statement.

All authors contributed to the writing of the final manuscript.

Susumu Yamazaki: attending physician, corresponding author, design of the work.

Erika Naito: attending physician, correction of the case report.

Ryu Sekiya: attending physician, correction of the case report.

Saneshiro Yogi: attending physician, correction of the case report.

Kenichiro Komiyama: attending physician, correction of the case report.

Yoshitaka Miyakawa: attending physician, correction of the case report, design of the work.

Makoto Nagata: correction of the case report, design of the work.

## 1. Introduction

Coronaviruses are well-known respiratory pathogens in humans and other animals. A novel coronavirus was identified as the cause of an outbreak of fatal pneumonia in Wuhan, Hubei, China at the end of 2019. That infection spread rapidly, resulting in a global pandemic. The resulting pathology was termed coronavirus disease 2019 (COVID-19) by the World Health Organization [1], and the causative coronavirus was named severe acute respiratory syndrome coronavirus 2 (SARS-CoV-2) by the International Committee on Taxonomy of Viruses [2]. COVID-19 causes fatal severe respiratory failure or acute respiratory distress syndrome, in addition to complications such as arrhythmia, acute heart failure, acute renal failure, and thromboembolism. Here we report a case of pure red cell aplasia (PRCA) following an initial presentation with warm auto immune hemolytic anemia (AIHA) during the course of treatment for severe COVID-19.

## 2. Case report

A 67-year-old male Japanese office worker traveled in northern Africa in February 2020. After returning to Japan, he experienced high

\* Corresponding author.

E-mail addresses: [yamapan2@saitama-med.ac.jp](mailto:yamapan2@saitama-med.ac.jp) (S. Yamazaki), [enaito@saitama-med.ac.jp](mailto:enaito@saitama-med.ac.jp) (E. Naito), [rsekiya@saitama-med.ac.jp](mailto:rsekiya@saitama-med.ac.jp) (R. Sekiya), [yogi297@saitama-med.ac.jp](mailto:yogi297@saitama-med.ac.jp) (S. Yogi), [komiken@saitama-med.ac.jp](mailto:komiken@saitama-med.ac.jp) (K. Komiyama), [miyakawa@saitama-med.ac.jp](mailto:miyakawa@saitama-med.ac.jp) (Y. Miyakawa), [favre4mn@saitama-med.ac.jp](mailto:favre4mn@saitama-med.ac.jp) (M. Nagata).

<https://doi.org/10.1016/j.jiac.2021.10.018>

Received 2 September 2021; Received in revised form 19 October 2021; Accepted 21 October 2021

Available online 25 October 2021

1341-321X/© 2021 Japanese Society of Chemotherapy and The Japanese Association for Infectious Diseases. Published by Elsevier Ltd. All rights reserved.

fever, headache and loose stools, and subsequent polymerase chain reaction (PCR) testing for SARS-CoV-2 yielded positive results. On admission, the patient showed high fever (40.2 °C) and needed supplemental oxygen at 2 L/min via nasal cannula because of hypoxia. Chest computed tomography (CT) (Fig. 1) showed patchy ground glass opacities and consolidations in both lungs. Blood testing on admission revealed inflammation, mild liver dysfunction and elevated levels of D-dimer (Table 1). As ciclesonide, lopinavir-ritonavir, levofloxacin, and meropenem all proved ineffective, respiratory failure progressed and the patient was intubated on day 8. On day 38, we diagnosed venous thromboembolism from contrast-enhanced CT and started the anti-Xa inhibitor edoxaban.

The patient was extubated on day 24, but became dependent on red blood cell (RBC) transfusion. Hemoglobin was 7.4 g/dL with low haptoglobin (3 mg/dL) and increases in both serum lactate dehydrogenase (327 U/L) and reticulocytes (27.1%) on day 26, while total bilirubin was 2.6 mg/dL and indirect bilirubin was 0.6 mg/dL. As the direct Coombs test (immunoglobulin [Ig]G) yielded positive results, we diagnosed warm autoimmune hemolytic anemia (AIHA) and started prednisolone at 60 mg/day (1 mg/kg/day) on day 52. However, prednisolone proved ineffective and was tapered after 2 weeks.

We performed bone marrow biopsy on day 65 and diagnosed PRCA. To our surprise, bone marrow showed severely infiltration of CD8<sup>+</sup>, perforin-positive, granzyme B-positive cytotoxic T cells (Fig. 2). Testing for IgM for B19 parvovirus and anti-nuclear antibody yielded negative results, excluding the possibilities of parvovirus infection or collagen vascular diseases, which are known causes of secondary PRCA.

Bone marrow was hypercellular, and the myeloid/erythroid ratio was 81. Erythroid precursor cells were notably absent (erythroblasts, 0.5%; proerythroblasts, 0.1%; basophilic erythroblasts, 0.2%; polychromatic erythroblasts, 0.1%; orthochromatic, 0.1%). Other myeloid cells were all normal. Chromosomal analysis of bone marrow cells showed normal results, excluding the possibility of hematological malignancies. Anemia remained unimproved with systemic corticosteroid therapy and frequent RBC transfusions were required, so systemic cyclosporine at 3 mg/kg was started on day 106 for PRCA. No further RBC transfusions were required after 4 weeks of cyclosporine, and hemoglobin recovered to 11.0 g/dL on day 373 (Fig. 3).

### 3. Discussion

The patient in this case was diagnosed with AIHA and PRCA during the clinical course of severe COVID-19. We believed that this represents the first description of PRCA associated with COVID-19. Previous reports

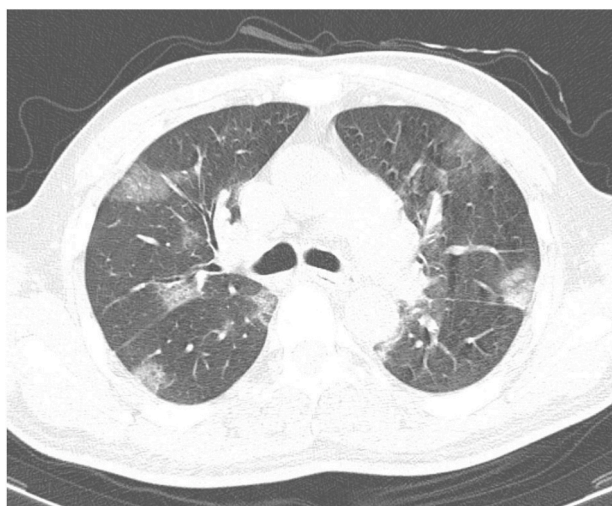


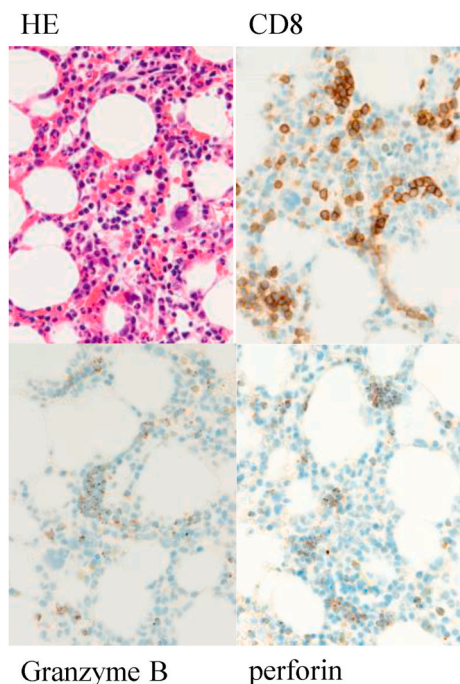
Fig. 1. Chest CT on admission Patchy ground glass opacities and consolidations are evident in both lungs.

Table 1  
Results of laboratory tests on admission.

Hematology		Biochemistry		Urinalysis	
WBC	12,610/ μL	TP	6.6 g/ dL	Specific gravity	1.018
NEUT	23.3%	Albumin	4.0 g/ dL	pH	6.0
LYMP	72.4%	CK	92 U/ L	WBC	(-)
MONO	3.6%	AST	35 U/ L	Nitrites	(-)
EOSI	0.5%	ALT	30 U/ L	Proteins	30
BASO	0.2%	LDH	271 U/L	Glucose	(-)
RBC	3.05 × 10 <sup>5</sup> /μL	ALP	309 U/L	Ketones	(-)
Hb	10.7	γ-GTP	81 U/ L	Urobilinogen	Normal
Hct	31.2	BUN	19.1 mg/ dL	Bilirubin	(-)
MCV	102.3	Creatinine	0.85 mg/ dL	Occult blood	(-)
MCH	35.1	Uric acid	5.1 mg/ dL		
MCHC	34.3	Sodium	143 mEq/ L		
PLT	10.5 × 10 <sup>4</sup> /μL	Chloride	108 mEq/ L	Serology/ Plasma	14.87 mg/dL
		Potassium	3.9 mEq/ L	CRP	
Coagulation system		Amylase	47 U/ L	Blood glucose	202 mg/dL
APTT	49.4 sec	T-bil	0.6 mg/ dL	HbA1c	5.6%
PT	12.8 sec			KL-6	290 U/ mL
PT%	91%			Procalcitonin	0.78 ng/mL
PT-INR	1.05			BNP	15.0 pg/mL
FIB	516 mg/ dL				
FDP	3.2 μg/ mL				
D-dimer	1.08 μg/ mL				

WBC: white blood cell, NEUT: neutrophil, LYMP: lymphocyte, MONO: monocyte, EOSI: eosinophil, BASO: basophil, RBC: red blood cell, Hb: hemoglobin, Hct: hematocrit, MCV: mean corpuscular volume, MCH: mean corpuscular hemoglobin, MCHC: mean corpuscular hemoglobin concentration, PLT: platelets, APTT: activated partial thromboplastin time, PT: prothrombin time, PT-INR: prothrombin time international normalized ratio, FIB: fibrinogen, FDP: fibrin and fibrinogen degradation products, TP: total protein, CK: creatine kinase, AST: aspartate aminotransferase, ALT: alanine aminotransferase, LDH: lactate dehydrogenase, ALP: alkaline phosphatase, γ-GTP: γ-glutamyl transpeptidase, BUN: blood urea nitrogen, T-Bil: total bilirubin, CRP: C-reactive protein, HbA1c: Hemoglobin A1c, KL-6: sialylated carbohydrate antigen, Krebs von den Lungen-6, BNP: brain natriuretic peptide.

have described COVID-19 accompanied by several autoimmune diseases and inflammatory disorders, such as Guillan-Barré syndrome, immune thrombocytopenia, AIHA, antiphospholipid syndrome and Kawasaki disease. Aberrant activation and dysregulation of CD8<sup>+</sup> T cells have been described in patients with severe COVID-19, following cytokine storm involving inflammatory cytokines such as interleukin-1, interleukin-6, tumor necrosis factor-α, interferon gamma-inducible protein 10 and monocyte chemoattractant protein 1.



**Fig. 2.** Bone marrow biopsy (× 40)  
 Bone marrow biopsy (Day 65) demonstrated the infiltration of cytotoxic T lymphocytes expressing CD8, granzyme B and perforin. HE: hematoxylin eosin.

PRCA is an intractable anemia characterized by selective reduction of erythropoiesis in the bone marrow and consequent marked depletion of reticulocytes (<1%) and development of normocytic anemia [3]. PRCA is a rare benign blood disorder. The annual incidence of PRCA in Japan has been estimated as 0.3 per million population. No sex predominance is considered present. The pathogenesis of PRCA is idiopathic in 39% of cases, thymoma in 23%, and lymphoproliferative disorder in 14% [4]. In this case, we excluded infections with B19 parvovirus [5], acute hepatitis A [6], human immunodeficiency virus, human T-cell leukemia virus type 1, and Epstein-Barr virus based on serological tests and PCR. As the p-antigen on RBC progenitors is known to act as the receptor for B19 parvovirus, we speculate that cytotoxic T cells might destroy erythroid progenitors in the bone marrow [7].

PRCA is classified into acute or chronic forms based on the pathogenesis, but criteria for categorizing the duration into acute or chronic forms have yet to be established. Most cases of PRCA caused by infection

or medication present with acute pathology, with recovery of both reticulocytes and anemia seen approximately 1–3 weeks after resolution of the infection or discontinuation of the causative medication. On the other hand, 10–15% of cases diagnosed with idiopathic PRCA, representing chronic PRCA, spontaneously remit over the disease course [8]. This case was presumed to be the acute type, because development of PRCA occurred during SARS-CoV-2 infection. However, the clinical course did not reveal an acute type. Unlike acute-type PRCA caused by other viral infections, anemia requiring RBC transfusions persisted for several months, even after improvement of COVID-19, and the patient proved resistant to systemic corticosteroids and required concomitant use of systemic cyclosporine.

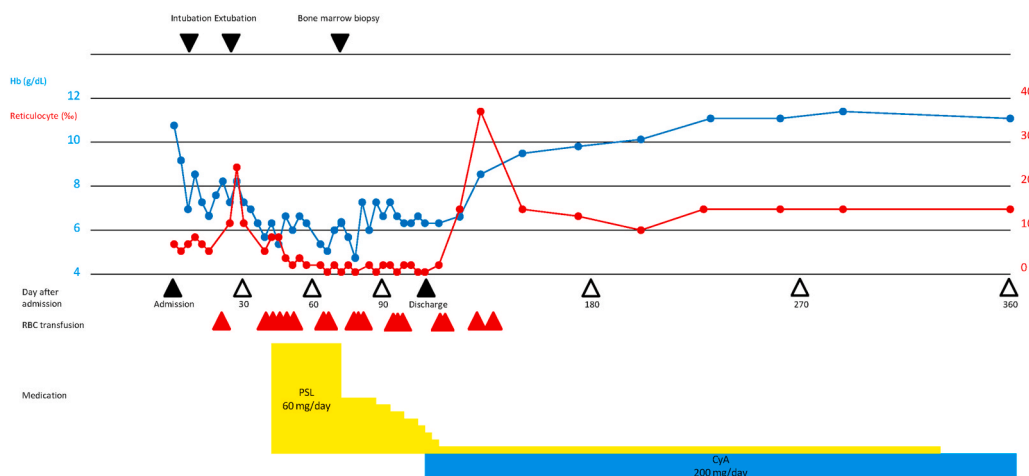
In the present case, the patient was initially diagnosed with warm AIHA based on positive test results from the direct Coombs test [9–11]. Given the clinical resistance to systemic corticosteroids, bone marrow biopsy was performed and led to the diagnosis of PRCA, and the patient was successfully treated using immunosuppressive therapy with cyclosporine. At the time this case was diagnosed and treated, systemic corticosteroids had not been approved for use against COVID-19, as their clinical efficacy was not established and approved for coverage by public health insurance until spring 2020. In this case, a more up-to-date treatment strategy centered on anti-inflammatory treatment might thus have prevented the onset of AIHA or PRCA in the first place.

Several reports have described PRCA after AIHA, and we speculate that this case was caused by similar mechanisms [12–16].

In this case, angiotensin-converting enzyme 2 receptors on endothelial cells may have contributed to the entry of SARS-CoV-2, followed by severe inflammation, acute respiratory failure, and coagulation disorders [17]. Although we confirmed massive infiltration of cytotoxic T cells into bone marrow and PRCA in this case, the mechanisms by which those T cells were induced by SARS-CoV-2 infection remain uncertain. In this case, the onset of anemia was slower than in previously reported cases. As the amount of RBC transfusion was initially not high, the diagnosis of PRCA was delayed. The exact mechanisms involved in this case remain uncertain, but we speculate that individual differences, magnitude of viral load, and/or strength of cytokine storms might have been contributing factors. Compared to idiopathic PRCA, little is known regarding the prognosis or optimal treatment for COVID-19-associated PRCA. We therefore expect this case report will provide helpful information in understanding secondary blood disorders caused by SARS-CoV-2.

#### 4. Conclusion

We encountered a case of PRCA complicated by COVID-19,



**Fig. 3.** Clinical course of the patient Please cite this Figure in the main text.

accompanied by massive infiltration of cytotoxic T cells into bone marrow. Treatment with systemic cyclosporine proved successful.

#### Declaration of competing interest

None.

#### References

- [1] WHO. Director-General's remarks at the media briefing on 2019-nCoV on 11 February 2020. <https://www.who.int/dg/speeches/detail/who-director-general-remarks-at-the-media-briefing-on-2019-ncov-on-11-february-2020>. [Accessed 15 October 2021].
- [2] Coronaviridae Study Group of the International Committee on Taxonomy of Viruses. The species severe acute respiratory syndrome-related coronavirus: classifying 2019-nCoV and naming it SARS-CoV-2. *Nature Microbiology* 2020;5: 536–44. <https://doi.org/10.1038/s41564-020-0695-z>.
- [3] Dessypris ELJ. Red cell aplasia. In: Greer JP, et al., editors. *Wintrobe's clinical hematology*. twelfth ed. Philadelphia and London: Lippincot Williams & Wilkins; 2009. p. 1196–211.
- [4] Sawada K, Hirokawa M, Fujishima N, Teramura M, Bessho M, Dan K, et al. Long-term outcome of patients with acquired primary idiopathic pure red cell aplasia receiving cyclosporine A. A nationwide cohort study in Japan for the PRCA Collaborative Study Group. *Haematologica* 2007;92:1021–8.
- [5] El Khoury C, Farhat H. Severe acute anemia attributable to concomitant occurrence of AIHA with PRCA induced by parvovirus B19 infection. *Blood* 2018;131:1388.
- [6] Chang HJ, Sinn DH, Cho SG, Oh TH, Jeon TJ, Shin WC, et al. Pure red-cell aplasia and autoimmune hemolytic anemia in a patient with acute hepatitis A. *Clin Mol Hepatol* 2014;20:204–7.
- [7] Brown KE, Anderson SM, Young NS. Erythrocyte P antigen: cellular receptor for B19 parvovirus. *Science* 1993;262:114–7.
- [8] Dessypris EN. *Pure red cell aplasia*. Baltimore and London: Johns Hopkins University Press; 1988.
- [9] Lazarian G, Quinquenel A, Bellal M, et al. Autoimmune haemolytic anaemia associated with COVID-19 infection. *Br J Haematol* 2020;190:29–31.
- [10] Lopez C, Kim J, Pandey A, Huang T, DeLoughery TG. Simultaneous onset of COVID-19 and autoimmune haemolytic anaemia. *Br J Haematol* 2020;190:31–2.
- [11] Capes A, Bailly S, Hantson P, Gerard L, Laterre PF. COVID-19 infection associated with autoimmune hemolytic anemia. *Ann Hematol* 2020;99:1679–80.
- [12] Saha M, Ray S, Kundu S, Chakrabarti P. Pure red cell aplasia following autoimmune hemolytic anemia: an enigma. *J Postgrad Med* 2013;59:51–3.
- [13] Koiso H, Kobayashi S, Ueki K, Hamada T, Tsukamoto N, Karasawa M, et al. Pure red cell aplasia accompanied by autoimmune hemolytic anemia in a patient with type A viral hepatitis. *Rinsho Ketsueki* 2009;50:424–9.
- [14] Tohda S, Nara N, Tanikawa S, Imai Y, Murakami N, Aoki N. Pure red cell aplasia following autoimmune haemolytic anaemia. Cell-mediated suppression of erythropoiesis as a possible pathogenesis of pure red cell aplasia. *Acta Haematol* 1992;87:98–102.
- [15] Mangan KF, Besa EC, Shaddock RK, Tedrow H, Ray PK. Demonstration of two distinct antibodies in autoimmune hemolytic anemia with reticulocytopenia and red cell aplasia. *Exp Hematol* 1984;12:788–93.
- [16] Adachi M. Simultaneous occurrence of autoimmune hemolytic anemia and pure red cell aplasia. *Rinsho Ketsueki* 2016;57:2512–6 [in Japanese].
- [17] Lan J, Ge J, Yu J, Shan S, Shan S, Zhou H, et al. Structure of the SARS-CoV-2 spike receptor-binding domain bound to the ACE2 receptor. *Nature* 2020;581:215–20.