

Metagenomic Next-Generation Sequencing for Pulmonary Fungal Infection Diagnosis: Lung Biopsy versus Bronchoalveolar Lavage Fluid

Lei Yang¹
Junxiu Song¹
Yubao Wang²
Jing Feng¹

¹Department of Respiratory and Critical Care Medicine, Tianjin Medical University General Hospital, Tianjin, People's Republic of China; ²Institute of Infectious Diseases, The Second Hospital of Tianjin Medical University, Tianjin, People's Republic of China

Purpose: Metagenomic next-generation sequencing (mNGS) is widely used for pulmonary infection; nonetheless, the experience from its clinical use in diagnosing pulmonary fungal infections is sparse. This study aimed to compare mNGS results from lung biopsy and bronchoalveolar lavage fluid (BALF) and determine their clinical diagnostic efficacy.

Patients and Methods: A total of 106 patients with suspected pulmonary fungal infection from May 2018 to January 2020 were included in this retrospective study. All patients' lung biopsy and BALF specimens were collected through bronchoscopy. Overall, 45 (42.5%) patients had pulmonary fungal infection. The performance of lung biopsy and BALF used for mNGS in diagnosing pulmonary fungal infections and identifying pathogens was compared. Additionally, mNGS was compared with conventional tests (pathology, galactomannan test, and cultures) with respect to the diagnosis of pulmonary fungal infections.

Results: Lung biopsy-mNGS and BALF-mNGS exhibited no difference in terms of sensitivity (80.0% vs 84.4%, $P=0.754$) and specificity (91.8% vs 85.3%, $P=0.39$). Additionally, there was no difference in specificity between mNGS and conventional tests; however, the sensitivity of mNGS (lung biopsy, BALF) in diagnosing pulmonary fungal infections was significantly higher than that of conventional tests (conventional tests vs biopsy-mNGS: 44.4% vs 80.0%, $P<0.05$; conventional tests vs BALF-mNGS: 44.4% vs 84.4%, $P<0.05$). Among 32 patients with positive mNGS results for both biopsy and BALF specimens, 23 (71.9%) cases of consistency between the two tests for the detected fungi and nine (28.1%) cases of a partial match were identified. Receiver operating curve analysis revealed that the area under the curve for the combination of biopsy and BALF was significantly higher than that for BALF-mNGS ($P=0.018$).

Conclusion: We recommend biopsy-based or BALF-based mNGS for diagnosing pulmonary fungal infections because of their diagnostic advantages over conventional tests. The combination of biopsy and BALF for mNGS can be considered when higher diagnostic efficacy is required.

Keywords: mNGS, diagnosis, sensitivity, specificity

Correspondence: Yubao Wang
Institute of Infectious Diseases, The
Second Hospital of Tianjin Medical
University, Pingjiang Road NO. 23, Tianjin,
300211, People's Republic of China
Email yubaowang2020@hotmail.com

Jing Feng
Department of Respiratory and Critical
Care Medicine, Tianjin Medical University
General Hospital, Anshan Road No. 154,
Heping District, Tianjin, 300052, People's
Republic of China
Email zyyhxkfj@126.com

Introduction

In recent years, with the increase in high-risk groups requiring immunosuppressant use, the prevalence of pulmonary fungal disease has shown a significant upward trend. The main sources of fungal infections in human lungs are opportunistic fungi: *Aspergillus*, *Cryptococcus*, *Pneumocystis jirovecii*, and endemic fungi. Among them, *Aspergillus* and *Cryptococcus* are the main fungal pathogens associated with lung infections.¹ Microscopic smears and cultures are conventional microbial methods used for



pathogen identification; however, both methods are time consuming and not highly sensitive. The gold standard for the detection of invasive fungal infections is histopathological diagnosis. However, it is time consuming, it cannot identify pathogens, and it has low sensitivity. For *Aspergillus* infections, the positive predictive value (PPV) of respiratory specimen cultures obtained by sputum induction or bronchoalveolar lavage fluid (BALF) is low (approximately 72%).² When testing patients with non-hematological diseases or those who have been treated with antifungal drugs, the PPV may be even lower.³ Clinically, BALF's galactomannan (GM) test results are affected by various factors, which can lower the sensitivity and increase the false positivity rate.⁴⁻⁷

Since the conventional tests for the diagnosis of pulmonary fungal infections have a low sensitivity and are influenced by various factors, there is an urgent need for new technology with a higher sensitivity for the diagnosis of pulmonary fungal infections. Currently, metagenomic next-generation sequencing (mNGS) is a widely used method for the clinical detection of pathogens and has obvious advantages in pathogen detection.⁸ One study showed that mNGS can improve the sensitivity of pathogen detection and that it is less affected by antibiotic exposure before detection.⁹ In the studies that used mNGS for the detection of lung infections,¹⁰⁻¹³ there have been advantages identified over traditional detection methods, indicating that mNGS can be used to detect lung infections. However, there is limited experience from the clinical use of mNGS in the diagnosis of pulmonary fungal infections.

In this study, we used bronchoscopy to obtain lung biopsy and BALF for mNGS from 106 patients with suspected pulmonary fungal infection to identify pathogens. We compared the mNGS results from lung biopsy and BALF to specifically determine the difference between the two mNGS results and the clinical diagnostic efficacy. Additionally, mNGS (BALF) was compared with conventional tests (pathology, GM test, and cultures).

Patients and Methods

Specimen Collection and Processing

The present study is a retrospective cohort study. Patients admitted to the Respiratory Department at Tianjin Medical University General Hospital for suspected pulmonary fungal infection from May 2018 to January 2020 provided informed consent to undergo bronchoscopy and mNGS. Experienced physicians collected the patient's lung biopsy and BALF

specimens through bronchoscopy based on canonical operational procedures.¹⁴ During bronchoscopy, the operating physician recorded complications such as bleeding, fatal hemoptysis, arrhythmia, and death. Six to ten lung biopsy specimens collected from the enrolled patients were used for pathology, rapid on-site evaluation (ROSE), and mNGS. Within 2 hours, the lung biopsy specimens were sent to the histopathology laboratory and then processed using standard procedures.¹⁵ The remaining lung biopsy specimens were stored at -80°C for mNGS. Part of the BALF was used for fungal and bacterial culture. Another part of the BALF was used for Xpert MTB, GM test, and smear. The remaining BALF specimens were stored at -80°C for mNGS.

mNGS and Analyses

The TIANamp Micro DNA Kit (DP316, TIANGEN BIOTECH) was used to extract the DNA from the BALF and lung biopsy homogenates based on the company's recommendation. DNA libraries were constructed based on the Beijing Genomics Institute sequencer-100. By removing low-quality and shorter (<35 bp) readings, high-quality sequencing data were generated. Burrows-Wheeler Aligner software was applied to map to a human reference (hg19) to identify human sequence data. Microbial genome databases were used to classify the remaining data.^{9,16,17} The classification reference databases were downloaded from NCBI (<ftp://ftp.ncbi.nlm.nih.gov/genomes/>).

Criteria of Diagnosis of Pulmonary Fungal Infection

Pulmonary fungal infection was defined based on the European Organization for Research and Treatment of Cancer (EORTC)/Mycoses Study Group (MSG) criteria.¹⁸ In our study, for proven Invasive Fungal Disease (IFDs), histopathological findings of hyphae on lung biopsy were considered an IFI diagnosis, and this criterion was adapted for any patient. For probable IFDs, experts in the respiratory department of our hospital reviewed the chest CT images of pulmonary fungal infection, which was one of the clinical diagnostic criteria, and evaluated possible mycological evidence such as the GM antigen test. Patients with no proven or probable IFDs throughout the study period were categorized as exclude IFDs.

The pathogen responsible for the fungal infections was diagnosed if it met any of the following thresholds. First, culture and/or histopathological examination positive for fungi; it is strongly recommended to use BALF GM to

diagnose invasive pulmonary aspergillosis in immunosuppressed patients.⁴ Second, at least 50 unique reads from a single species of fungi; for pathogens with unique reads less than 50, the diagnosis of pulmonary fungal infection can still be made based on the clinical situation.¹³

Statistical Analysis

In order to determine the sensitivity, specificity, PPV, and negative predictive value (NPV), 2×2 contingency tables were derived. All data are reported as the absolute value of their 95% confidence intervals (CI). Diagnostic accuracy of pulmonary fungal infections based on the fungal reads from mNGS and area under the curve (AUC) was calculated after conducting the corresponding receiver operating characteristic (ROC) curve analysis. Data were analyzed using SPSS 26.0 (IBM Corp., Armonk, NY, USA) and MedCalc 19 (MedCalc Software Ltd., Ostend, Belgium). *P*-values <0.05 were considered statistically significant.

Ethics

The study was approved by the Ethics Committee of Tianjin Medical University General Hospital. The need for informed consent was waived due to the retrospective nature of the study and because the data were anonymously analyzed.

Results

Patient Characteristics and mNGS

Results

Overall, 106 patients were included in the study; 76 (71.7%) were males, and the average age was 43.2±18.5 years. Eighty-four (79.3%) patients had immunocompromised function, and 79 of them suffered from hematological diseases (Table 1). In total, 45 (42.5%) patients were diagnosed with pulmonary fungal infections (Table 2 and Figure 1).

Comparison Between mNGS and Conventional Tests

Among the 106 patients with suspected pulmonary fungal infection, the diagnostic efficacy of mNGS for lung biopsy and BALF is shown in Table 3. The sensitivity and specificity of lung biopsy-mNGS for the diagnosis of pulmonary fungal infections were 80.0% (95% CI, 65.0–89.9%) and 91.8% (95% CI, 81.2–96.9%), and the PPV and NPV were 87.8% (95% CI, 73.0–95.4%) and 86.2% (95% CI, 74.8–93.1%), respectively. The sensitivity and specificity of BALF-mNGS for the diagnosis of pulmonary fungal infections were 84.4% (95% CI, 69.9–93.0%) and 85.3% (95% CI, 73.3–92.6%), and the PPV and NPV were 80.9% (95% CI, 66.3–90.4%) and 88.1% (95% CI, 76.5–94.7%), respectively.

The sensitivity and specificity of conventional tests in diagnosing pulmonary fungal infections were 44.4% (95% CI, 30.0–59.9%) and 88.5% (95% CI, 77.2–94.9%), whereas the PPV and NPV were 74.1% (95% CI, 53.4–88.1%) and 68.4% (95% CI, 56.8–78.1%), respectively. There was no significant difference in the specificity between mNGS and conventional tests; however, the sensitivity of mNGS (lung biopsy, BALF) in diagnosing pulmonary fungal infections was significantly higher than that of conventional tests (conventional tests vs biopsy-mNGS: 44.4% vs 80.0%, *P*<0.05; conventional tests vs BALF-mNGS: 44.4% vs 84.4%, *P*<0.05) (Table 3). There were no fungi detected based on the mNGS results for specimens obtained from three patients (patient nos. 91, 101, and 105); nevertheless, the presence of fungi was confirmed in the pathology or culture results. Both mNGS (BALF) and traditional detection methods were positive for pulmonary fungal infections in 19 patients. The pathology of the lung biopsy for 11 patients revealed fungal hyphae. Among all fungal cultures, the fungal culture results for six patients suggested the growth of mold. Of the 10 positive results using BALF from the GM test, six were false positives.

Table 1 Patient Demographic Characteristics

Characteristics		Patient, N (%)
Age		43.2±18.5
Sex	Male	76 (71.7%)
	Female	30 (28.3%)
Underlying disease	Immunocompromised	84 (79.3%)
	Non-Immunocompromised	22 (20.8%)

Table 2

Patient ID	Sex	Age/yr	Underlying Disease	Immunocompromised	Pathology Results	Culture Results	GM Test	mNGS (Biopsy) Based Diagnosis	mNGS (BAL) Based Diagnosis	Final Clinical Diagnosis
1	Male	46	ALL	Yes	Pink amorphous substance, negative for PAS, hexamine silver and acid-fast staining	Mold growth	Negative	Pulmonary fungal infection	Pulmonary fungal infection	Pulmonary fungal infection
2	Male	19	ALL	Yes	Alveolar septal fibrous tissue hyperplasia	Viridans streptococci	Negative	Exclude pulmonary fungal infection	Exclude pulmonary fungal infection	Exclude pulmonary fungal infection
3	Male	43	AML	Yes	No	Negative	Negative	Exclude pulmonary fungal infection	Exclude pulmonary fungal infection	Exclude pulmonary fungal infection
4	Male	19	T lymphoblastic acute leukemia	Yes	No	Negative	Negative	Exclude pulmonary fungal infection	Exclude pulmonary fungal infection	Exclude pulmonary fungal infection
5	Male	47	No	No	Alveolar septal fibrous tissue hyperplasia with lymphocyte infiltration	Viridans streptococci	Negative	Exclude pulmonary fungal infection	Exclude pulmonary fungal infection	Exclude pulmonary fungal infection
6	Male	63	No	No	Interstitial fibrous tissue hyperplasia, scattered lymphocyte infiltration, alveolar epithelial hyperplasia, fibroblast thrombosis in the alveolar cavity	Viridans streptococci	Negative	Exclude pulmonary fungal infection	Exclude pulmonary fungal infection	Exclude pulmonary fungal infection
7	Female	14	ALL	Yes	Alveolar septal fibrous tissue hyperplasia with lymphocyte infiltration	Viridans streptococci, Micrococcus pharyngis	Negative	Exclude pulmonary fungal infection	Exclude pulmonary fungal infection	Exclude pulmonary fungal infection

8	Male	11	Hodgkin's Lymphoma	Yes	Chronic inflammatory cell infiltration in the alveolar compartment,	Viridans streptococci	Negative	Exclude pulmonary fungal infection	Exclude pulmonary fungal infection	Exclude pulmonary fungal infection
9	Female	39	Mixed connective tissue disease	Yes	Alveolar septal fibrous tissue hyperplasia with lymphocyte infiltration	Streptococcus pneumoniae	Positive	Exclude pulmonary fungal infection	Exclude pulmonary fungal infection	Exclude pulmonary fungal infection
10	Male	15	ALL	Yes	Alveolar septal fibrous tissue mild hyperplasia and chronic inflammatory cell infiltration,	Negative	Positive	Exclude pulmonary fungal infection	Exclude pulmonary fungal infection	Exclude pulmonary fungal infection
11	Male	25	ALL	Yes	Interstitial lymphocytes, plasma cell infiltration, neutrophils, fibrinous exudate	Citrobacter koseri	Positive	Pulmonary fungal infection	Pulmonary fungal infection	Pulmonary fungal infection
12	Male	68	Pancytopenia	Yes	No	Viridans streptococci	Negative	Exclude pulmonary fungal infection	Exclude pulmonary fungal infection	Exclude pulmonary fungal infection
13	Female	51	Rheumatoid Arthritis	Yes	Fibrous tissue hyperplasia and lymphoid tissue hyperplasia,	Viridans streptococci	Negative	Exclude pulmonary fungal infection	Exclude pulmonary fungal infection	Exclude pulmonary fungal infection
14	Male	39	AML	Yes	Widened alveolar space, fibrous tissue hyperplasia, focal alveolar hyperplasia, Scattered lymphocytes and tissue cells infiltration, focal carbon dust deposition	Viridans streptococci, Neisseria sicca	Negative	Exclude pulmonary fungal infection	Pulmonary fungal infection	Pulmonary fungal infection
15	Male	52	ALL	Yes	No	Negative	Negative	Exclude pulmonary fungal infection	Exclude pulmonary fungal infection	Exclude pulmonary fungal infection

(Continued)

Table 2 (Continued).

Patient ID	Sex	Age/yr	Underlying Disease	Immunocompromised	Pathology Results	Culture Results	GM Test	mNGS (Biopsy) Based Diagnosis	mNGS (BAL) Based Diagnosis	Final Clinical Diagnosis
16	Female	30	Chronic gastritis	No	Alveolar septal fibrous tissue hyperplasia, Slurry cellulosic exudate	Citrobacter koseri	Negative	Pulmonary fungal infection	Pulmonary fungal infection	Pulmonary fungal infection
17	Male	32	AML	Yes	Tumorous lesions to be excluded	Negative	Negative	Exclude pulmonary fungal infection	Exclude pulmonary fungal infection	Exclude pulmonary fungal infection
18	Male	56	ALL	Yes	Mild hyperplasia of alveolar septal fibrous tissue, focal type II alveolar epithelial hyperplasia	Viridans streptococci, Neisseria sicca	Negative	Exclude pulmonary fungal infection	Exclude pulmonary fungal infection	Exclude pulmonary fungal infection
19	Male	22	ALL	Yes	Necrotic tissue	Negative	Negative	Exclude pulmonary fungal infection	Exclude pulmonary fungal infection	Exclude pulmonary fungal infection
20	Male	18	Acute B lymphocytic lymphoma	Yes	Mild hyperplasia of alveolar septum fibrous tissue	Negative	Negative	Exclude pulmonary fungal infection	Exclude pulmonary fungal infection	Exclude pulmonary fungal infection
21	Female	34	No	No	Mild hyperplasia of alveolar septum fibrous tissue	Viridans streptococci, Staphylococcus epidermidis	Negative	Exclude pulmonary fungal infection	Exclude pulmonary fungal infection	Exclude pulmonary fungal infection
22	Male	58	MDS	Yes	Alveolar septal fibrous tissue proliferates, scattered lymphocytes infiltrate, fibroblast thrombus formation in the alveolar cavity,	Viridans streptococci	Negative	Exclude pulmonary fungal infection	Exclude pulmonary fungal infection	Exclude pulmonary fungal infection

23	Male	68	AML	Yes	Alveolar septal fibrous tissue hyperplasia with chronic inflammatory cell infiltration, local alveolar epithelial hyperplasia,	Negative	Negative	Negative	Exclude pulmonary fungal infection	Exclude pulmonary fungal infection	Exclude pulmonary fungal infection
24	Male	22	ALL	Yes	No	Negative	Negative	Negative	Pulmonary fungal infection	Pulmonary fungal infection	Pulmonary fungal infection
25	Female	55	AML	Yes	Alveolar septum widening, interstitial fibrous tissue hyperplasia with inflammatory cell infiltration	Acinetobacter baumannii complex	Positive	Exclude pulmonary fungal infection	Exclude pulmonary fungal infection	Exclude pulmonary fungal infection	Exclude pulmonary fungal infection
26	Male	48	AML	Yes	No	Viridans streptococci	Negative	Pulmonary fungal infection	Exclude pulmonary fungal infection	Exclude pulmonary fungal infection	Pulmonary fungal infection
27	Female	63	AML	Yes	Mold hyphae	Negative	Negative	Pulmonary fungal infection	Pulmonary fungal infection	Pulmonary fungal infection	Pulmonary fungal infection
28	Male	60	AML	Yes	Mucosal lamina propria fibrosis with medium to small nuclei and clusters of cells stained with cytoplasm, not supporting myeloid leukemia cells	Negative	Negative	Exclude pulmonary fungal infection	Exclude pulmonary fungal infection	Exclude pulmonary fungal infection	Exclude pulmonary fungal infection
29	Male	47	ALL	Yes	Alveolar septal fibrous tissue hyperplasia, Foamy cell aggregation, No leukemia cells seen	Viridans streptococci	Negative	Pulmonary fungal infection	Pulmonary fungal infection	Pulmonary fungal infection	Pulmonary fungal infection
30	Male	25	ALL	Yes	Inflammatory exudate and coagulated necrotic tissue	Meningeal sepsis Eliza Platinum bacteria, Citrobacter koseri	Negative	Pulmonary fungal infection	Exclude pulmonary fungal infection	Exclude pulmonary fungal infection	Pulmonary fungal infection
31	Female	15	CML	Yes	Coagulating necrotic tissue and very little fibrous tissue	Negative	Negative	Pulmonary fungal infection	Pulmonary fungal infection	Pulmonary fungal infection	Pulmonary fungal infection

(Continued)

Table 2 (Continued).

Patient ID	Sex	Age/yr	Underlying Disease	Immunocompromised	Pathology Results	Culture Results	GM Test	mNGS (Biopsy) Based Diagnosis	mNGS (BAL) Based Diagnosis	Final Clinical Diagnosis
32	Male	58	AML	Yes	No tumor cells seen	<i>Pseudomonas putida</i> , <i>Stenotrophomonas maltophilia</i>	Negative	Exclude pulmonary fungal infection	Exclude pulmonary fungal infection	Exclude pulmonary fungal infection
33	Male	18	ALL	Yes	No	Negative	Negative	Exclude pulmonary fungal infection	Exclude pulmonary fungal infection	Exclude pulmonary fungal infection
34	Male	54	No	No	Chronic inflammation of mucosa	<i>Viridans streptococci</i>	Negative	Exclude pulmonary fungal infection	Exclude pulmonary fungal infection	Exclude pulmonary fungal infection
35	Male	71	MarginalzoneB-cell lymphoma	Yes	Chronic inflammatory cell infiltration in alveolar space	<i>Viridans Streptococci</i>	Negative	Pulmonary fungal infection	Exclude pulmonary fungal infection	Exclude pulmonary fungal infection
36	Female	41	No	No	Fibroblast thrombus formation in the alveolar cavity	<i>Viridans streptococci</i>	Negative	Exclude pulmonary fungal infection	Exclude pulmonary fungal infection	Exclude pulmonary fungal infection
37	Female	42	Acute Laryngitis	No	Fibrous tissue hyperplasia and lymphocyte infiltration	<i>Viridans streptococci</i>	Negative	Exclude pulmonary fungal infection	Exclude pulmonary fungal infection	Exclude pulmonary fungal infection
38	Female	63	CML	Yes	Fibrous tissue hyperplasia, with scattered inflammatory cell infiltration	<i>Enterobacter cloacae</i>	Negative	Exclude pulmonary fungal infection	Exclude pulmonary fungal infection	Exclude pulmonary fungal infection

39	Male	22	ALL	Yes	Interstitial fibrous tissue hyperplasia with inflammatory cell infiltration	Viridans streptococci	Negative	Exclude pulmonary fungal infection	Exclude pulmonary fungal infection	Exclude pulmonary fungal infection
40	Male	38	ALL	Yes	Alveolar septum widening, interstitial fibrous tissue hyperplasia	Viridans streptococci	Negative	Exclude pulmonary fungal infection	Exclude pulmonary fungal infection	Exclude pulmonary fungal infection
41	Female	31	AML	Yes	Legion of Fungi	Enterobacter cloacae	Positive	Pulmonary fungal infection	Pulmonary fungal infection	Pulmonary fungal infection
42	Female	64	Postoperative Breast Tumor	No	Chronic inflammatory cell infiltration with mild fibrous tissue hyperplasia	Viridans Streptococci	Negative	Pulmonary fungal infection	Exclude pulmonary fungal infection	Exclude pulmonary fungal infection
43	Male	42	No	No	Fibroblast thrombus formation in the alveolar cavity	Viridans streptococci	Negative	Exclude pulmonary fungal infection	Exclude pulmonary fungal infection	Exclude pulmonary fungal infection
44	Male	49	AML	Yes	No	Negative	Negative	Exclude pulmonary fungal infection	Exclude pulmonary fungal infection	Exclude pulmonary fungal infection
45	Male	47	Acute leukemia	Yes	A lot of fungus and a little inflammatory exudate	Staphylococcus aureus	Negative	Pulmonary fungal infection	Pulmonary fungal infection	Pulmonary fungal infection
46	Female	49	ALL	Yes	No	Negative	Negative	Pulmonary fungal infection	Exclude pulmonary fungal infection	Pulmonary fungal infection

(Continued)

Table 2 (Continued).

Patient ID	Sex	Age/yr	Underlying Disease	Immunocompromised	Pathology Results	Culture Results	GM Test	mNGS (Biopsy) Based Diagnosis	mNGS (BAL) Based Diagnosis	Final Clinical Diagnosis
47	Male	64	AML	Yes	Mild proliferation of alveolar septal fibrous tissue with a little lymphocyte infiltration	Viridans streptococci	Positive	Exclude pulmonary fungal infection	Exclude pulmonary fungal infection	Exclude pulmonary fungal infection
48	Male	38	Immunorelated pancytopenia	Yes	Alveolar hemorrhage, edema, and hemosiderin deposition	Negative	Negative	Exclude pulmonary fungal infection	Pulmonary fungal infection	Exclude pulmonary fungal infection
49	Female	43	Asthma	No	Fibroblast plug formation	Viridans streptococci	Negative	Exclude pulmonary fungal infection	Pulmonary fungal infection	Exclude pulmonary fungal infection
50	Male	51	AML	Yes	No	Viridans streptococci	Negative	Exclude pulmonary fungal infection	Pulmonary fungal infection	Exclude pulmonary fungal infection
51	Male	61	Diabetes, coronary heart disease	No	Legion of fungi. methenamine silver stain +.	Negative	Positive	Pulmonary fungal infection	Pulmonary fungal infection	Pulmonary fungal infection
52	Male	23	ALL	Yes	Non-neoplastic lesions	Negative	Negative	Pulmonary fungal infection	Pulmonary fungal infection	Pulmonary fungal infection
53	Male	66	Hypertension	No	Fibrous tissue hyperplasia and inflammatory cell infiltration of alveolar septum	Micrococcus pharyngis	Negative	Exclude pulmonary fungal infection	Exclude pulmonary fungal infection	Exclude pulmonary fungal infection

54	Male	61	Chronic obstructive pulmonary disease, hypertension	No	Non-small cell carcinoma, predisposing to squamous cell carcinoma	Negative	Negative	Negative	Pulmonary fungal infection	Pulmonary fungal infection	Pulmonary fungal infection	Exclude pulmonary fungal infection
55	Male	49	Acute nonlymphocytic leukemia	Yes	Powdery cellulose-like exudate, neutrophils, degenerated and necrotic cells	Negative	Negative	Negative	Pulmonary fungal infection	Pulmonary fungal infection	Pulmonary fungal infection	Pulmonary fungal infection
56	Male	51	AML	Yes	No	Negative	Negative	Negative	Exclude pulmonary fungal infection	Exclude pulmonary fungal infection	Exclude pulmonary fungal infection	Exclude pulmonary fungal infection
57	Male	30	Aplastic anemia	Yes	Alveolar septal fibrous tissue hyperplasia with lymphocyte infiltration	Negative	Negative	Negative	Pulmonary fungal infection	Pulmonary fungal infection	Pulmonary fungal infection	Pulmonary fungal infection
58	Female	46	Hypertension	No	Alveolar septum widening, interstitial fibrous tissue proliferation and inflammatory cell infiltration	Negative	Viridans streptococci	Negative	Exclude pulmonary fungal infection	Pulmonary fungal infection	Pulmonary fungal infection	Cryptococcal infection
59	Male	47	Aplastic anemia	Yes	Mold clusters, methenamine silver stain +	Negative	Klebsiella pneumoniae	Negative	Pulmonary fungal infection	Pulmonary fungal infection	Pulmonary fungal infection	Pulmonary fungal infection
60	Male	65	Hypertension, diabetes, coronary heart disease	No	Lymphocyte infiltration, acute and chronic inflammatory cell infiltration	Negative	Viridans streptococci	Negative	Exclude pulmonary fungal infection	Exclude pulmonary fungal infection	Exclude pulmonary fungal infection	Exclude pulmonary fungal infection
61	Male	72	Lung tumor	Yes	Lymphocyte infiltration, alveolar septal fibrous tissue hyperplasia	Negative	Viridans streptococci	Negative	Exclude pulmonary fungal infection	Exclude pulmonary fungal infection	Exclude pulmonary fungal infection	Exclude pulmonary fungal infection

(Continued)

Table 2 (Continued).

Patient ID	Sex	Age/yr	Underlying Disease	Immunocompromised	Pathology Results	Culture Results	GM Test	mNGS (Biopsy) Based Diagnosis	mNGS (BAL) Based Diagnosis	Final Clinical Diagnosis
62	Male	11	Acute mixed cell leukemia	Yes	Acute and chronic inflammatory cell infiltration	Viridans streptococci	Positive	Exclude pulmonary fungal infection	Pulmonary fungal infection	Pulmonary fungal infection
63	Female	64	Diabetes, nodular goiter	No	Alveolar septal fibrous tissue hyperplasia with chronic inflammatory cell infiltration	Escherichia Coli	Negative	Exclude pulmonary fungal infection	Exclude pulmonary fungal infection	Exclude pulmonary fungal infection
64	Male	75	Acute leukemia	Yes	Chronic inflammation	Staphylococcus epidermidis	Positive	Exclude pulmonary fungal infection	Pulmonary fungal infection	Exclude pulmonary fungal infection
65	Male	73	Acute monocytic leukemia	Yes	Inflammatory cell infiltration	Negative	Negative	Pulmonary fungal infection	Pulmonary fungal infection	Pulmonary fungal infection
66	Female	33	AML	Yes	Acute and chronic inflammatory cell infiltration, virus infection not excluded	Negative	Negative	Pulmonary fungal infection	Pulmonary fungal infection	Pulmonary fungal infection
67	Female	18	ALL	Yes	Alveolar epithelial hyperplasia, focal fibroblast thrombus formation, mild hyperplasia of alveolar septal fibrous tissue, and organizing lesions not excluded	Negative	Negative	Exclude pulmonary fungal infection	Pulmonary fungal infection	Pulmonary fungal infection
68	Male	44	T-cell acute lymphoblastic leukemia	Yes	No	Negative	Negative	Pulmonary fungal infection	Pulmonary fungal infection	Pulmonary fungal infection

69	Female	10	Aplastic anemia	Yes	Mesenchymal tissue and large amount of acute exudate	Negative	Negative	Negative	Exclude pulmonary fungal infection	Exclude pulmonary fungal infection	Exclude pulmonary fungal infection
70	Male	38	No	No	Lymphocyte infiltration of alveolar septum with fibrous tissue hyperplasia, fibroblast plug	Negative	Micrococcus pharyngis	Negative	Exclude pulmonary fungal infection	Exclude pulmonary fungal infection	Exclude pulmonary fungal infection
71	Female	39	Leukemia	Yes	Alveolar septal fibrous tissue hyperplasia with chronic inflammatory cell infiltration	Negative	Negative	Negative	Exclude pulmonary fungal infection	Exclude pulmonary fungal infection	Exclude pulmonary fungal infection
72	Male	70	Diabetes, alcoholic cirrhosis	No	No	Positive	Viridans streptococci	Exclude pulmonary fungal infection	Exclude pulmonary fungal infection	Exclude pulmonary fungal infection	Exclude pulmonary fungal infection
73	Male	21	AML	Yes	No tumor cells	Negative	Negative	Exclude pulmonary fungal infection	Exclude pulmonary fungal infection	Exclude pulmonary fungal infection	Exclude pulmonary fungal infection
74	Male	38	Immunorelated pancytopenia	Yes	Chronic inflammation of the mucosa	Negative	Enterococcus faecalis	Exclude pulmonary fungal infection	Exclude pulmonary fungal infection	Exclude pulmonary fungal infection	Exclude pulmonary fungal infection
75	Male	13	ALL	Yes	Legion of Fungi	Negative	Negative	Exclude pulmonary fungal infection	Exclude pulmonary fungal infection	Exclude pulmonary fungal infection	Exclude pulmonary fungal infection
76	Male	69	No	No	Chronic inflammation of mucosa	Negative	Viridans streptococci	Exclude pulmonary fungal infection	Exclude pulmonary fungal infection	Exclude pulmonary fungal infection	Exclude pulmonary fungal infection

(Continued)

Table 2 (Continued).

Patient ID	Sex	Age/yr	Underlying Disease	Immunocompromised	Pathology Results	Culture Results	GM Test	mNGS (Biopsy) Based Diagnosis	mNGS (BAL) Based Diagnosis	Final Clinical Diagnosis
77	Male	66	Hypertension	No	Proliferation of interstitial fibrous tissue and lymphoid tissue with scattered inflammatory cell infiltration,	Viridans streptococci	Negative	Exclude pulmonary fungal infection	Exclude pulmonary fungal infection	Exclude pulmonary fungal infection
78	Male	23	Acute leukemia	Yes	No tumor cells	Viridans streptococci	Negative	Pulmonary fungal infection	Pulmonary fungal infection	Pulmonary fungal infection
79	Male	58	ALL	Yes	Amorphous tissue, small airway mucosa with chronic inflammatory cell infiltration and fibrous tissue proliferation	Negative	Negative	Pulmonary fungal infection	Pulmonary fungal infection	Pulmonary fungal infection
80	Male	31	AML	Yes	No	Viridans streptococci	Negative	Pulmonary fungal infection	Pulmonary fungal infection	Pulmonary fungal infection
81	Male	53	MDS	Yes	Alveolar septal fibrous tissue hyperplasia and local fibroblast thrombus formation.	Negative	Negative	Exclude pulmonary fungal infection	Pulmonary fungal infection	Exclude pulmonary fungal infection
82	Male	17	AML	Yes	No	Candida albicans	Positive	Pulmonary fungal infection	Pulmonary fungal infection	Pulmonary fungal infection
83	Male	29	Aplastic anemia	Yes	No	Achromobacter xylosoxidans	Negative	Pulmonary fungal infection	Pulmonary fungal infection	Pulmonary fungal infection
84	Male	43	ALL	Yes	Suspicious fungus	Negative	Negative	Pulmonary fungal infection	Pulmonary fungal infection	Pulmonary fungal infection

85	Female	9	AML	Yes	No	Negative	Negative	Exclude pulmonary fungal infection	Exclude pulmonary fungal infection	Exclude pulmonary fungal infection	Exclude pulmonary fungal infection
86	Male	53	AML	Yes	No tumor cells seen	Viridans streptococci	Negative	Exclude pulmonary fungal infection	Exclude pulmonary fungal infection	Exclude pulmonary fungal infection	Exclude pulmonary fungal infection
87	Male	66	No	No	Proliferation of interstitial fibrous tissue with scattered inflammatory cell infiltration, fibroblast plugs,	Viridans streptococci	Negative	Exclude pulmonary fungal infection	Pulmonary fungal infection	Exclude pulmonary fungal infection	Exclude pulmonary fungal infection
88	Male	50	Hypertension	No	Interstitial fibrous tissue with inflammatory cell infiltration,	Viridans streptococci	Negative	Pulmonary fungal infection	Exclude pulmonary fungal infection	Exclude pulmonary fungal infection	Exclude pulmonary fungal infection
89	Female	59	Leukemia	Yes	No	<i>C. glabrata</i> , viridans streptococci	Negative	Exclude pulmonary fungal infection	Pulmonary fungal infection	Exclude pulmonary fungal infection	Exclude pulmonary fungal infection
90	Female	56	AML	Yes	Mild hyperplasia of alveolar septum fibrous tissue	Viridans streptococci	Negative	Exclude pulmonary fungal infection	Exclude pulmonary fungal infection	Exclude pulmonary fungal infection	Exclude pulmonary fungal infection
91	Male	48	Lymphoma, hypertension	Yes	Fibrinous exudative necrosis, a small amount of inflammatory cells and epithelial cells	Mold growth	Positive	Exclude pulmonary fungal infection	Exclude pulmonary fungal infection	Exclude pulmonary fungal infection	Pulmonary fungal infection
92	Female	36	AML	Yes	Alveolar septal fibrous tissue hyperplasia	Negative	Negative	Exclude pulmonary fungal infection	Exclude pulmonary fungal infection	Exclude pulmonary fungal infection	Exclude pulmonary fungal infection

(Continued)

Table 2 (Continued).

Patient ID	Sex	Age/yr	Underlying Disease	Immunocompromised	Pathology Results	Culture Results	GM Test	mNGS (Biopsy) Based Diagnosis	mNGS (BAL) Based Diagnosis	Final Clinical Diagnosis
93	Male	35	Diffuse Large B Cell Lymphoma	Yes	Mild hyperplasia of alveolar septum fibrous tissue	Negative	Negative	Exclude pulmonary fungal infection	Exclude pulmonary fungal infection	Pulmonary fungal infection
94	Male	53	AML	Yes	Alveolar septal fibrous tissue hyperplasia	Negative	Positive	Exclude pulmonary fungal infection	Pulmonary fungal infection	Pulmonary fungal infection
95	Female	39	ALL	Yes	Alveolar septal fibrous tissue hyperplasia, foam-like macrophage aggregation, type II alveolar epithelial hyperplasia	Viridans streptococci, staphylococcus epidermidis	Negative	Exclude pulmonary fungal infection	Pulmonary fungal infection	Exclude pulmonary fungal infection
96	Male	37	MDS	Yes	Legion of fungi, methenamine silver stain +	Pseudomonas aeruginosa	Positive	Pulmonary fungal infection	Pulmonary fungal infection	Pulmonary fungal infection
97	Male	26	AML	Yes	Alveolar septal hyperplasia, interstitial fibrous tissue hyperplasia with a small amount of inflammatory cell infiltration	Negative	Negative	Pulmonary fungal infection	Pulmonary fungal infection	Pulmonary fungal infection
98	Male	77	Chronic Lymphocytic Leukemia	Yes	Granulomatous lesions	Negative	Negative	Exclude pulmonary fungal infection	Exclude pulmonary fungal infection	Exclude pulmonary fungal infection
99	Male	25	ALL	Yes	Immunohistochemical staining excludes leukemia involvement	Viridans streptococci, Pneumocystis carinii	Negative	Pulmonary fungal infection	Pulmonary fungal infection	Pulmonary fungal infection
100	Male	73	Chronic Myelocytic Leukemia	Yes	Amorphous necrotic tissue with a small amount of neutrophil infiltration	Viridans streptococci, corynebacterium	Negative	Pulmonary fungal infection	Pulmonary fungal infection	Pulmonary fungal infection

101	Female	16	ALL	Yes	Cellulose exudation and foam cells, lymphocyte infiltration and fibrous tissue proliferation	Mold growth	Negative	Exclude pulmonary fungal infection	Exclude pulmonary fungal infection	Pulmonary fungal infection
102	Female	61	SLE	Yes	Methenamine silver stain +, cryptococcosis	Negative	Positive	Pulmonary fungal infection	Pulmonary fungal infection	Pulmonary fungal infection
103	Female	49	SLE	Yes	No	Mold growth	Negative	Pulmonary fungal infection	Pulmonary fungal infection	Pulmonary fungal infection
104	Male	15	AML	Yes	Extruded peripheral lung tissue, individual alveolar cavity expansion	Negative	Negative	Exclude pulmonary fungal infection	Pulmonary fungal infection	Pulmonary fungal infection
105	Male	74	Autoimmune hemolytic anemia	Yes	Fungal hyphae and spores, PAS-positive and methenamine silver	Negative	Positive	Exclude pulmonary fungal infection	Exclude pulmonary fungal infection	Pulmonary fungal infection
106	Female	21	ALL	Yes	Silk-like structure, histochemical staining shows PAS positive, mold hyphae	Negative	Negative	Pulmonary fungal infection	Pulmonary fungal infection	Pulmonary fungal infection

Abbreviations: AML, acute myeloid leukemia; ALL, acute lymphocytic leukemia; MDS, myelodysplastic syndrome.

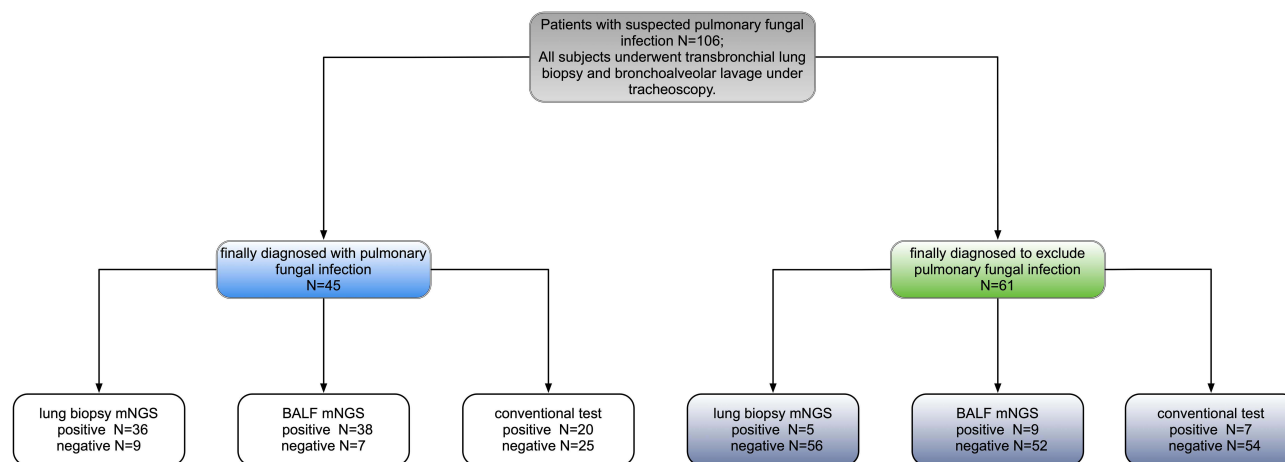


Figure 1 Methods used to diagnose pulmonary fungal infections.

Lung Biopsy and BALF for mNGS

ROC analysis of biopsy-mNGS and BALF-mNGS for the diagnosis of pulmonary fungal infections yielded an AUC of 0.8663 (95% CI, 0.8122–0.9605) and 0.8632 (95% CI, 0.7879–0.9385), respectively (Table 4). Additionally, ROC analysis of mNGS (combination of biopsy and BALF) for the diagnosis of pulmonary fungal infections yielded an AUC of 0.929 (95% CI, 0.862–0.970) (Table 4). When the threshold was greater than 0.3022, the sensitivity and specificity of mNGS (combination of biopsy and BALF) were 77.8% (95% CI, 62.9–88.8%) and 95.1% (95% CI, 86.3–99%), respectively. Pairwise ROC curves are shown in Figure 2 and Table 5. The difference in AUC of the two mNGS was only 0.0231 ($P=0.5748$). The difference in the AUC between mNGS (combination of biopsy and BALF) and lung biopsy-mNGS was 0.0423 ($P=0.0509$). Finally, the difference in AUC between mNGS (combination of biopsy and BALF) and BALF-mNGS was 0.0654 ($P=0.018$).

The mNGS provided specific sequencing reads of all microorganisms and valid data that can be detected in the sample. Based on the definition for the pathogens responsible for fungal infections, in combination with the patient’s clinical data to exclude some fungi considered

for colonization, this study detected pulmonary fungal infections caused by *Rhizopus microsporus*, *Aspergillus flavus*, *Aspergillus oryzae*, *Aspergillus fumigatus*, *Rhizomucor pusillus*, and *Pneumocystis jirovecii*. In lung biopsy-mNGS, most of the fungi detected were *Aspergillus oryzae*, *Aspergillus flavus*, *Pneumocystis jirovecii*, *Rhizomucor pusillus*, and *Aspergillus fumigatus* (Figure 3A). In mNGS (BALF), most of the fungi detected were *Pneumocystis jirovecii*, *Aspergillus fumigatus*, *Aspergillus oryzae*, *Aspergillus flavus*, and *Rhizomucor pusillus* (Figure 3B). The sequencing reads for fungi produced by each sample ranged from 2 to 522,197.

The lung biopsy and BALF results for mNGS were positive for the diagnosis of lung fungal infection in 33 cases. The lung biopsy and BALF from patient no. 54 were used for mNGS to detect *Aspergillus* and *Mycobacterium*; however, the final clinical diagnosis was tuberculosis. Both tests were negative for the diagnosis of pulmonary fungal infection in 51 patients. Eight cases were positive for pulmonary fungal infections using mNGS (biopsy) only, and 14 cases were positive for pulmonary fungal infections using mNGS (BALF) only. In 14 cases, we found that *Pneumocystis jirovecii* was

Table 3 Performance of mNGS and the Conventional Test in the Diagnosis of Pulmonary Fungal Infections

	Sensitivity % (95% CI)	Specificity % (95% CI)	PPV % (95% CI)	NPV % (95% CI)	P value	P value
mNGS (biopsy)	80.0 ^{a,b} (65.0–89.9)	91.8 ^{A,B} (81.2–96.9)	87.8 (73.0–95.4)	86.2 (74.8–93.1)	0.754 ^a	0.388 ^A
mNGS (balf)	84.4 ^{a,c} (69.9–93.0)	85.3 ^{A,C} (73.3–92.6)	80.9 (66.3–90.4)	88.1 (76.5–94.7)	0.002 ^b	0.774 ^B
Conventional test	44.44 ^{b,c} (30.0–59.9)	88.52 ^{B,C} (77.2–94.9)	74.1 (53.4–88.1)	68.4 (56.8–78.1)	0.0003 ^c	0.774 ^C

Notes: Sensitivity: a, biopsy-mNGS vs BALF-mNGS; b, biopsy-mNGS vs conventional test; c, BALF-mNGS vs conventional test. Specificity: A, biopsy-mNGS vs BALF-mNGS; B, biopsy-mNGS vs conventional test; C, BALF-mNGS vs conventional test.

Abbreviations: PPV, positive predictive value; NPV, negative predictive value; CI, confidence interval.

Table 4 Comparison of the ROC for mNGS and the Conventional Tests

	Area Under Curve	95% Confidence Interval	P value
Biopsy combined balf	0.929	0.862–0.970	P<0.0001
Biopsy	0.8663	0.8122–0.9605	P<0.0001
Balf	0.8632	0.7879–0.9385	P<0.0001

detected by mNGS (BALF) in patient no. 58; however, the final diagnosis was cryptococcal infection. Among the 32 patients whose final diagnoses were pulmonary fungal infections and mNGS results were positive, 23 (71.88%) cases of consistency between the two detected fungi and nine (28.13%) cases of a partial match were identified (Figure 4). With respect to the partially matched results, the mNGS results of the two specimens did not appear to be completely different; nevertheless, they were partially contained.

Among 45 patients with a final diagnosis of pulmonary fungal infection, the results from lung biopsy and BALF for mNGS were positive in 32 (75%) patients (Table 6). When multiple types of fungi were detected by mNGS for the two specimens, the fungi with the largest reads were recorded and compared. Among 32 patients with positive mNGS results for both specimens, 27 (84.38%) had more reads of fungi detected by lung biopsy-mNGS than by BALF-mNGS (Figures 5 and 6). In 17 (53.13%) patients, fungal reads detected by lung biopsy-mNGS were more than 10 times greater than those by BALF-mNGS. In 10

patients, the fungal reads detected by lung biopsy-mNGS were between 1 and 10 times greater than those detected by BALF-mNGS. In patient no. 16, the fungal reads detected by BALF-mNGS were significantly greater than those by lung biopsy-mNGS. The fungal reads detected by BALF-mNGS were approximately the same as those by lung biopsy in five patients.

The information from the 22 patients with inconsistent mNGS results is shown in Table 7. Among the eight and 13 cases with positive lung biopsy-mNGS and positive BALF-mNGS, four and five cases were eventually diagnosed with pulmonary fungal infections, respectively. Among the above mentioned 22 patients, 12 patients had false-positive mNGS results. Only four and eight cases had positive lung biopsy-mNGS and BALF-mNGS results, respectively. Among the false positive cases, *Aspergillus*, *Pneumocystis jejeuni*, and *Candida albicans* were most frequently detected, and in 10 (83.33%) patients, the mNGS reads were less than 20. In patients with false positive results, there was a greater frequency of BALF-mNGS cases than lung biopsy-mNGS; however, this difference was not significant ($P>0.05$).

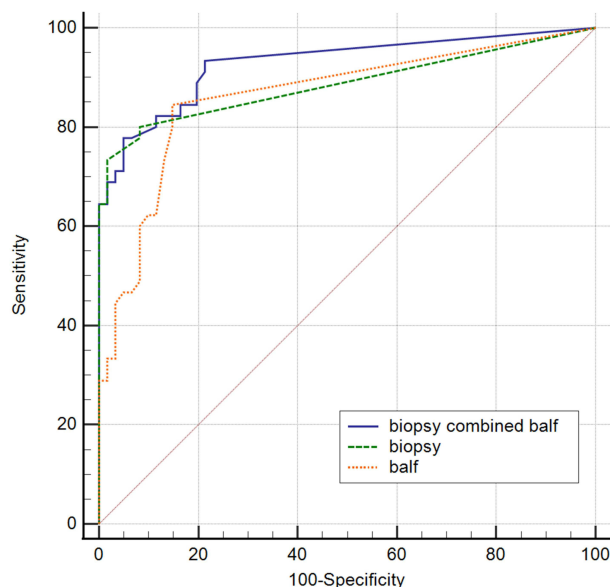


Figure 2 Pairwise comparison of the ROC curves.
Abbreviation: ROC, receiver operating characteristic.

Complications in Bronchoscopy

Among the 106 patients included in this study, lung biopsy and BALF were performed at the same time. During transbronchial lung biopsy, a small amount of bleeding was observed under bronchoscopy in eight patients. After instilling hemocoagulase was injected into the bleeding bronchus through the bronchoscope, no active bleeding was observed under the bronchoscope, and the patient's safety was not threatened. Among the 106 patients who underwent bronchoscopy, none experienced any complications, including fatal hemoptysis, pneumothorax, arrhythmia, and death.

Discussion

Among high-risk groups of patients with immunosuppression, empirical antifungal therapy is becoming increasingly common, which makes the diagnosis of pulmonary fungal infections more difficult.¹⁹ mNGS has been widely

Table 5 Comparison of the Difference in the AUC

	Difference Between Areas	P value
Biopsy combined half~ biopsy	0.0423	0.0509
Biopsy combined half ~ balf	0.0654	0.018
Biopsy ~ balf	0.0231	0.5748

used in infectious diseases, but there is a lack of evidence regarding its use in pulmonary fungal infections. Therefore, this study aimed to address this gap and compare the difference between lung biopsy and BALF for mNGS. A previous study reported that mNGS was better

than cultures in diagnosing pulmonary fungal infections (OR, 4.0 [95% CI, 1.6–10.3], $P < 0.01$).⁹ In the current study, the specificity of conventional tests did not differ compared to mNGS (conventional tests vs biopsy-mNGS: 88.52% vs 91.8%, $P > 0.05$; conventional tests vs BALF-

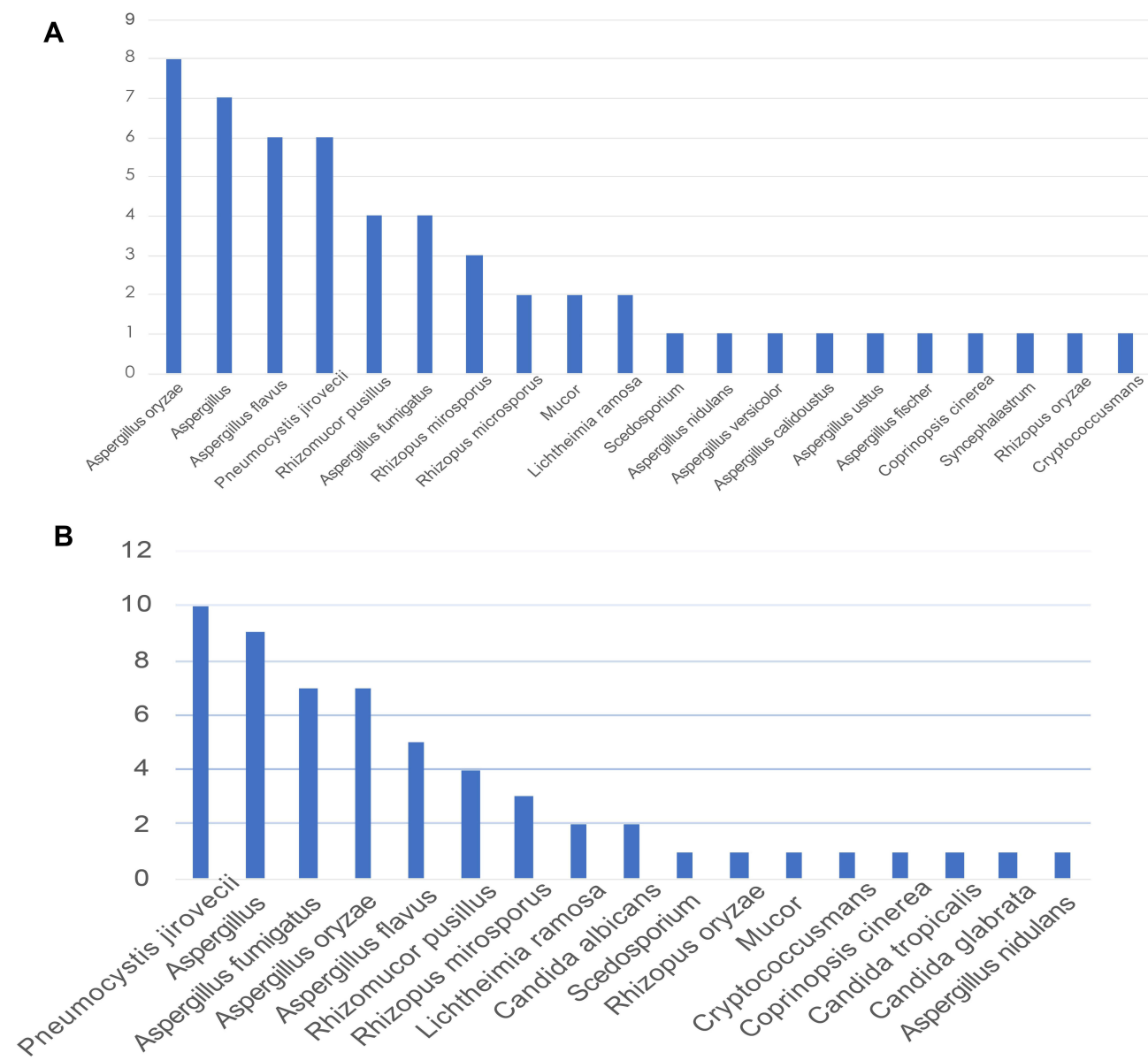


Figure 3 (A) Fungi detected using lung biopsy-mNGS. **(B)** Fungi detected using BALF-mNGS.

Abbreviations: BALF, bronchoalveolar lavage fluid; mNGS, metagenomic next-generation sequencing.

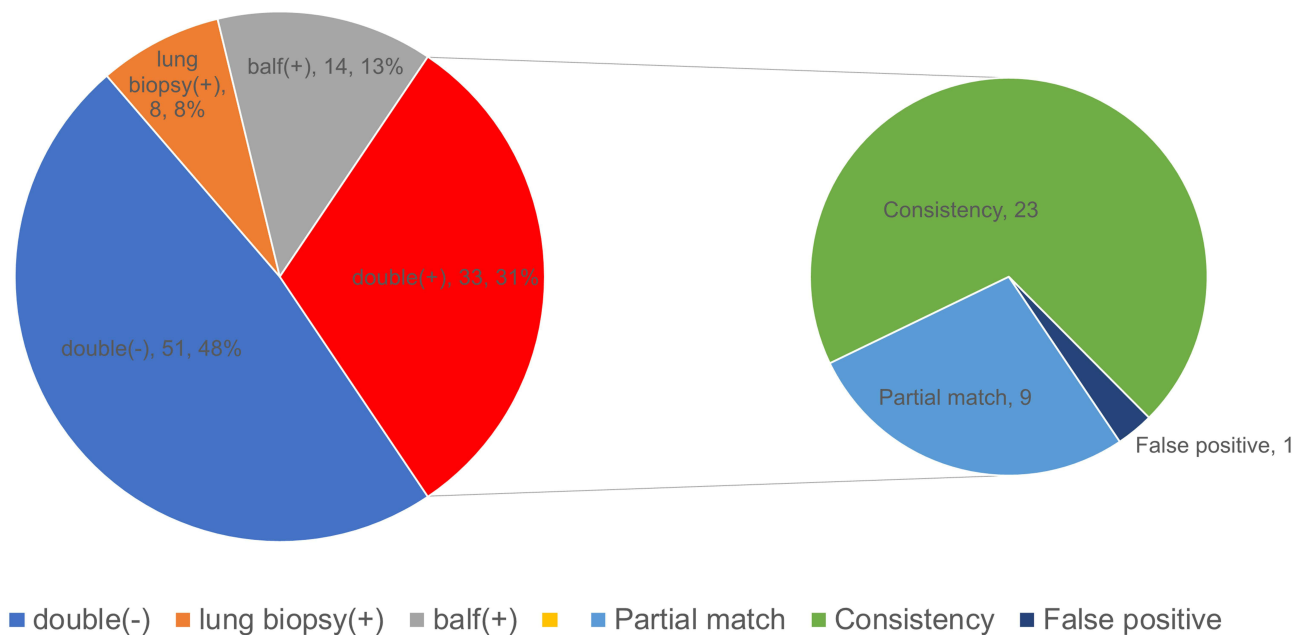


Figure 4 Consistency of the two specimens for mNGS in diagnosing pulmonary fungal infections. The pie chart shows the positive distribution of 106 cases investigated for pulmonary fungal infections using lung biopsy and BALF for mNGS. Among the patients whose mNGS results matched for both specimens, the mNGS results of nine patients showed partial matches, 24 patients showed complete matches, but 54 patients had false-positive results. **Abbreviations:** BALF, bronchoalveolar lavage fluid; mNGS, metagenomic next-generation sequencing.

mNGS: 88.52% vs 85.25%, $P>0.05$), but the sensitivity of mNGS significantly differed (conventional tests vs biopsy-mNGS: 44.44% vs 80.00%, $P<0.05$; conventional test vs BALF-mNGS: 44.44% vs 84.44%, $P<0.05$). The PPV and NPV of conventional tests were 74.07% (95% CI, 53.41–88.13%) and 68.35% (95% CI, 56.80–78.11%), respectively. Since patients with immunodeficiencies were treated with antifungal therapy before the test, the positivity rate of the conventional tests was very low. Compared with the conventional tests, it has been previously reported that mNGS is less affected by antibiotic exposure before detection,⁹ and that mNGS can detect corresponding pathogens, which is beneficial for targeted treatment.

Reviewing the relevant literature, there are many studies on single lung biopsy or BALF for mNGS in pulmonary infections,^{10,12} but few studies have evaluated simultaneous mNGS using lung biopsy and BALF specimens to diagnose pulmonary fungal infections. In this study involving 106 patients with suspected pulmonary fungal infection, mNGS detected fungi in the lung biopsy and/or BALF of 55 patients. The sensitivity of lung biopsy and BALF for mNGS in diagnosing pulmonary fungal infections was 80.00% (95% CI, 64.95–89.91%) and 84.44% (95% CI, 69.94–93.01%), whereas their specificity was 91.8% (95% CI, 81.17–96.94%) and 85.25% (95% CI, 73.32–92.62%), respectively; however, these values did

not show significant difference ($P>0.05$). The smaller difference between the two samples in terms of sensitivity might be explained by the fungal infection method (filamentous fungi spread on the surface of lung tissue, and it is often difficult to wash pathogens off using lavage) and the scope of the alveolar lavage (bronchoalveolar lavage involves more lobe segments and more distant sub-segment bronchi). The positivity rate of lung biopsy-mNGS mainly depends on the location of the lesion, such as whether the lesion is connected to the bronchus or close to the surrounding area. In this study, with the assistance of virtual navigation and ROSE, the sensitivity of mNGS (lung biopsy and BALF) was relatively high. ROC analysis of lung biopsy-mNGS for the diagnosis of pulmonary fungal infections yielded an AUC of 0.8663 (95% CI, 0.8122–0.9605). ROC analysis of BALF-mNGS for the diagnosis of pulmonary fungal infections yielded an AUC of 0.8632 (95% CI, 0.7879–0.9385). The difference in the AUC of the two samples evaluated using mNGS was only 0.0231 ($P=0.5748$). These findings highlight that mNGS (regardless of whether the test specimen was a lung biopsy or BALF) is a better detection method for the diagnosis of pulmonary fungal infections. The difference in the AUC between the mNGS (combination of biopsy and BALF) and the mNGS (lung BALF) was 0.0654 ($P=0.018$). Thus, we found that mNGS (combination of

Table 6 Results of the 32 Patients with Matching mNGS Results

Patient ID	mNGS (Biopsy, Fungus Detected)	mNGS (Balf, Fungus Detected)	Final Clinical Diagnosis	mNGS (Biopsy) /mNGS (BAL)	Matching Level
I	Rhizopus microsporus (1337) Aspergillus oryzae (3)	Rhizopus microsporus (23)	Pulmonary fungal infections	58	Partial match
11	Aspergillus oryzae (1257) Aspergillus flavus (1146)	Aspergillus oryzae (4) Aspergillus flavus (1)	Pulmonary fungal infections	314	Complete match
16	Scedosporium (4)	Scedosporium (127)	Pulmonary fungal infections	0.03	Complete match
24	Aspergillus oryzae (155) Aspergillus flavus (102)	Aspergillus oryzae (11) Aspergillus flavus (6)	Pulmonary fungal infections	14	Complete match
27	Aspergillus nidulans (279,595) Rhizomucor pusillus (3861) Aspergillus versicolor (183) Aspergillus calidoustus (175) Aspergillus ustus (137)	Aspergillus nidulans (234) Rhizomucor pusillus (6)	Pulmonary fungal infections	1195	Partial match
29	Aspergillus fumigatus (922) Aspergillus fischer (5)	Aspergillus fumigatus (207)	Pulmonary fungal infections	4	Partial match
31	Rhizomucor pusillus (5320)	Rhizomucor pusillus (2)	Pulmonary fungal infections	2660	Complete match
41	Aspergillus oryzae (863) Aspergillus flavus (207)	Aspergillus oryzae (9)	Pulmonary fungal infections	96	Partial match
45	Coprinopsis cinerea (1380)	Coprinopsis cinerea (49)	Pulmonary fungal infections	28	Complete match
51	Aspergillus fumigatus (41,388)	Aspergillus fumigatus (74)	Pulmonary fungal infections	559	Complete match
52	Pneumocystis jirovecii (12,496)	Pneumocystis jirovecii (6566)	Pulmonary fungal infections	2	Complete match
55	Aspergillus oryzae (46)	Aspergillus oryzae (4) Aspergillus (5)	Pulmonary fungal infections	12	Partial match
57	Pneumocystis jirovecii (360)	Pneumocystis jirovecii (452)	Pulmonary fungal infections	0.8	Complete match

59	Rhizopus microsporus (522,197) Mucor (5755)	Rhizopus microsporus (159)	Pulmonary fungal infections	3284	Partial match
65	Aspergillus (4)	Aspergillus (7)	Pulmonary fungal infections	0.6	Complete match
66	Aspergillus (3)	Aspergillus flavus (13)	Pulmonary fungal infections	0.2	Complete match
68	Rhizopus microsporus (299,937) Mucor (8925) Syncephalastrum (21)	Rhizopus microsporus (352) Mucor (8) Aspergillus (5)	Pulmonary fungal infections	852	Partial match
75	Aspergillus fumigatus (5938)	Aspergillus fumigatus (1178)	Pulmonary fungal infections	5	Complete match
78	Aspergillus flavus (2)	Aspergillus flavus (3)	Pulmonary fungal infections	0.7	Complete match
79	Aspergillus oryzae (150)	Aspergillus oryzae (21) Aspergillus (32)	Pulmonary fungal infections	7	Partial match
80	Lichtheimia ramosa (196) Rhizomucor pusillus (2)	Lichtheimia ramosa (166) Rhizomucor pusillus (39)	Pulmonary fungal infections	1.2	Complete match
82	Aspergillus flavus (488)	Aspergillus (123)	Pulmonary fungal infections	4	Complete match
83	Lichtheimia ramosa (186)	Lichtheimia ramosa (149)	Pulmonary fungal infections	1.2	Complete match
84	Rhizomucor pusillus (880)	Rhizomucor pusillus (9)	Pulmonary fungal infections	98	Complete match
93	Pneumocystis jirovecii (321)	Pneumocystis jirovecii (4)	Pulmonary fungal infections	80.2	Complete match
96	Aspergillus oryzae (1618) Aspergillus flavus (1344)	Aspergillus oryzae (330) Aspergillus flavus (266)	Pulmonary fungal infections	4.9	Complete match
97	Pneumocystis jirovecii (161,687)	Pneumocystis jirovecii (12,504)	Pulmonary fungal infections	12.9	Complete match

(Continued)

Table 6 (Continued).

Patient ID	mNGS (Biopsy, Fungus Detected)	mNGS (Balf, Fungus Detected)	Final Clinical Diagnosis	mNGS (Biopsy) /mNGS (BAL)	Matching Level
99	Pneumocystis jirovecii (14,006)	Pneumocystis jirovecii (2160)	Pulmonary fungal infections	6.5	Complete match
100	Rhizopus oryzae (42)	Rhizopus oryzae (2)	Pulmonary fungal infections	21	Complete match
102	Cryptococcusmans (557)	Cryptococcusmans (12)	Pulmonary fungal infections	46.4	Complete match
103	Aspergillus fumigatus (28)	Aspergillus fumigatus (20)	Pulmonary fungal infections	1.4	Complete match
106	Aspergillus oryzae (1182)	Aspergillus oryzae (48) Pneumocystis jirovecii (6)	Pulmonary fungal infections	24.6	Partial match

Abbreviation: mNGS/mNGS (BALF), mNGS (Biopsy) most detected fungal reads/mNGS (BAL) most detected fungal reads.

biopsy and BALF) had a better diagnostic value than BALF-mNGS. The difference in the AUC between the mNGS (combination of biopsy and BALF) and the mNGS (lung biopsy) was 0.0423 ($P=0.0509$). Thus, the mNGS (combination of biopsy and BALF) was not better than the lung biopsy-mNGS, possibly because the sample size was not large enough to show a significant difference.

The study detected fungal infections of the lungs caused by *Rhizopus microsporus*, *Aspergillus flavus*, *Aspergillus oryzae*, *Aspergillus fumigatus*, *Rhizomucor pusillus*, and *Pneumocystis jirovecii*. These findings are similar to those reported by Li et al,¹ but the current study only identified one case of cryptococcal infection. In this study, among 32 patients whose lung biopsy and BALF were both positive on the basis of mNGS and were thus diagnosed with pulmonary fungal infection, 23 (71.88%) cases of a complete match between the two detected fungi and nine (28.13%) cases of a partial match were identified. The results from the two different specimens did not completely differ; however, the mNGS results matched completely or contained each other. The findings of this study indicated that lung biopsy and BALF for mNGS showed specific consistency in fungal detection. Out of 32 patients with positive mNGS results for both specimens, 27 (84.38%) had more reads of fungi detected by lung biopsy-mNGS than by BALF-mNGS. Reads of fungi detected by lung biopsy-mNGS were more than 10 times greater than those detected by BALF-mNGS in 17 (53.13%) patients. These findings suggest that the reads of fungi detected by BALF-mNGS were generally small, which may be related to the fungal infection method (filamentous fungi spread on the surface of lung tissue, and it is often difficult to wash pathogens off using lavage). When lung tissues are obtained from the target site of the lesion and used for mNGS, the fungal reads can be detected several times higher than that with BALF.

In this study, 22 patients had inconsistent results from lung biopsy-mNGS and BALF-mNGS. The mNGS results were positive for lung biopsy and negative for BALF in eight patients; this might be attributed to the fact that the fungi are filamentous and spread on the tissue surface, which is difficult to wash down using bronchoalveolar lavage. Furthermore, the mNGS results were negative for lung biopsy and positive for BALF in 14 patients, which might be explained by the fact that the bronchi are not connected to the lesion site or the lesion tissue is not obtained; however, the alveolar lavage involves a wider

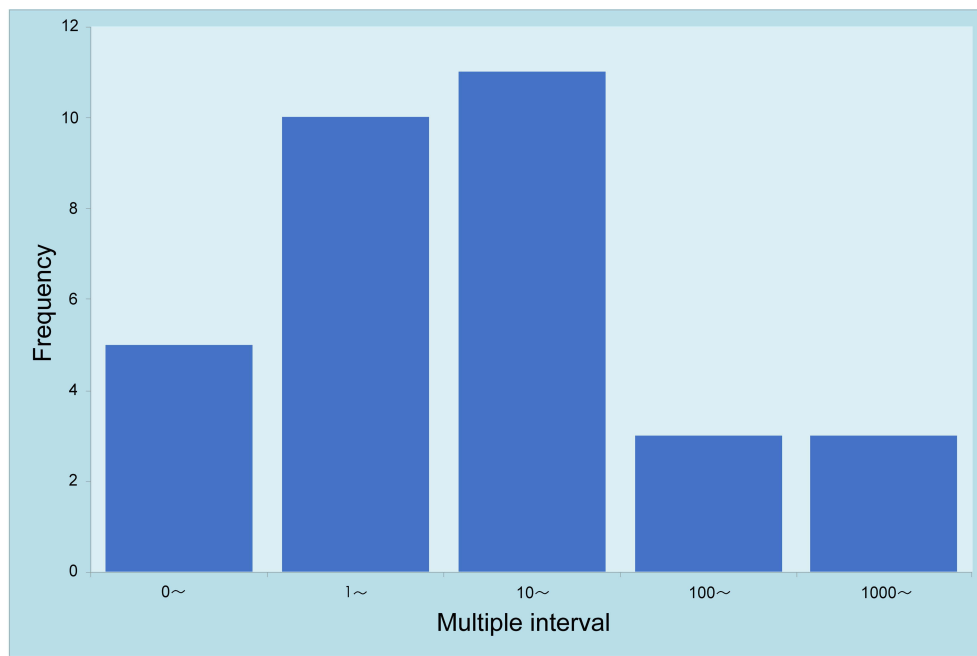


Figure 5 Comparison of the fungal reads detected by lung biopsy and BALF for mNGS. Multiple interval: mNGS (Biopsy) most detected fungal reads/mNGS (BAL) most detected fungal reads.

Abbreviations: BALF, bronchoalveolar lavage fluid; mNGS, metagenomic next-generation sequencing.

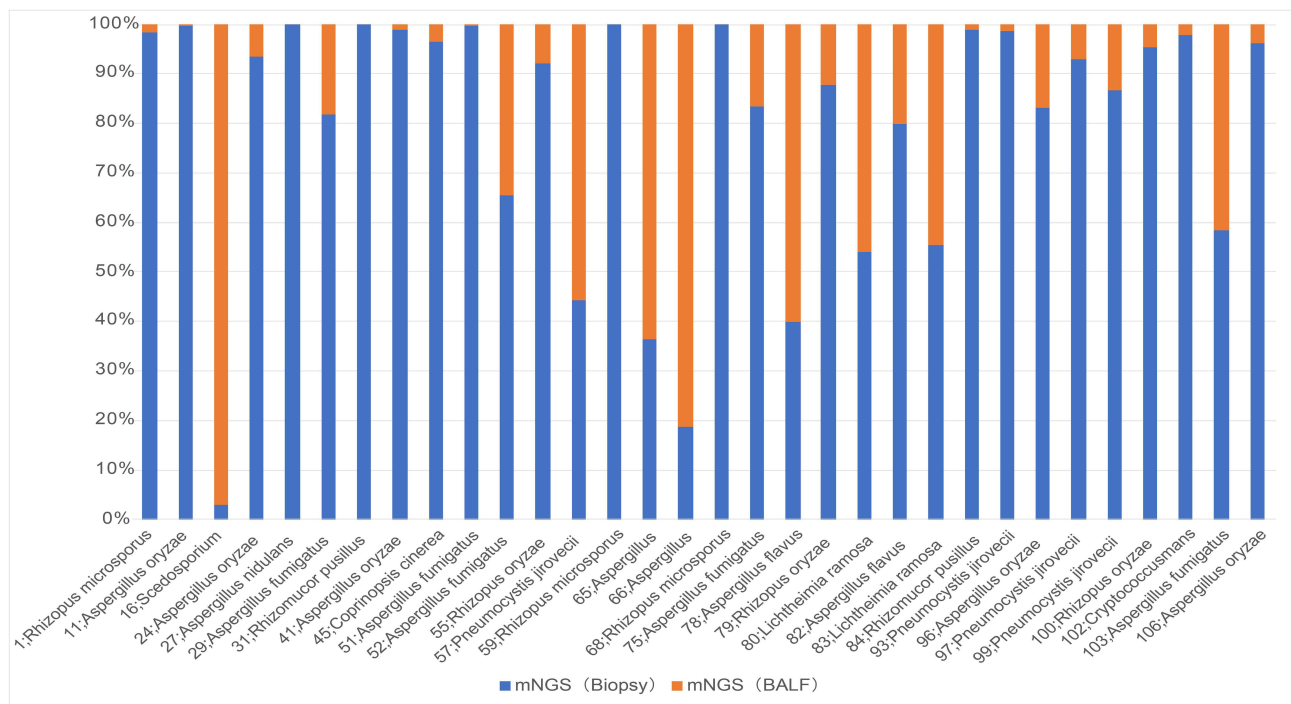


Figure 6 Comparison of the fungal reads detected by mNGS with matching results from both specimens in 32 patients.

Abbreviation: mNGS, metagenomic next-generation sequencing.

range. Since the lavage fluid involves more leaf segments and a more distant sub-segment bronchus, which involves a wider range, we found that BALF-mNGS had more false

positive results than lung biopsy. However, this difference was not significant ($P>0.05$), which may be a result of the small sample size.

Table 7 Sequencing Results for 22 Patients with Inconsistent Lung Biopsy-mNGS and BALF-mNGS

Patient ID	mNGS (Biopsy, Fungus Detected)	mNGS (BALF, Fungus Detected)	Final Clinical Diagnosis
12	Negative	<i>Candida albicans</i> (96)	Exclude pulmonary fungal infection
14	Negative	<i>Aspergillus fumigatus</i> (201)	Pulmonary fungal infection
26	<i>Rhizopus microsporus</i> (476)	Negative	Pulmonary fungal infection
30	<i>Rhizopus microsporus</i> (3)	Negative	Pulmonary fungal infection
35	<i>Aspergillus</i> (3)	Negative	Exclude pulmonary fungal infection
42	<i>Pneumocystis jirovecii</i> (13)	Negative	Exclude pulmonary fungal infection
46	<i>Aspergillus</i> (5)	Negative	Pulmonary fungal infection
48	Negative	<i>Pneumocystis jirovecii</i> (7)	Exclude pulmonary fungal infection
58	Negative	<i>Pneumocystis jirovecii</i> (2)	Pulmonary fungal infection
62	Negative	<i>Aspergillus</i> (4)	Pulmonary fungal infection
64	Negative	<i>Candida albicans</i> (13) <i>Aspergillus</i> (5)	Exclude pulmonary fungal infection
67	Negative	<i>Aspergillus</i> (3)	Pulmonary fungal infection
71	<i>Aspergillus</i> (3)	Negative	Exclude pulmonary fungal infection
73	Negative	<i>Pneumocystis jirovecii</i> (20)	Exclude pulmonary fungal infection
76	<i>Aspergillus</i> (4)	Negative	Pulmonary fungal infection
81	Negative	<i>Candida tropicalis</i> (6)	Exclude pulmonary fungal infection
87	Negative	<i>Aspergillus</i> (3)	Exclude pulmonary fungal infection
88	<i>Aspergillus</i> (3)	Negative	Exclude pulmonary fungal infection
89	Negative	<i>Candida glabrata</i> (146)	Exclude pulmonary fungal infection
94	Negative	<i>Aspergillus fumigatus</i> (4)	Pulmonary fungal infection
95	Negative	<i>Pneumocystis jirovecii</i> (15)	Exclude pulmonary fungal infection
104	Negative	<i>Aspergillus fumigatus</i> (9)	Pulmonary fungal infection

This study was subject to several limitations which merit mentioning here. To date, the mNGS test used in this study has been delivered to commercial laboratories, but not to the hospital's microbiology laboratory. This may increase the turnaround time and reduce the storage capacity, thus reducing the sensitivity of the test. Additionally, the sample size included in this study was not large, which caused a slight deviation in the ROC curve drawn.

Conclusion

This study showed that mNGS has obvious advantages when compared with conventional tests in pulmonary fungal infection. Additionally, there is no difference in

diagnostic performance between lung-biopsy-mNGS and BALF-mNGS. However, lung-mNGS can generally detect several times the fungal reads when compared to BALF-mNGS. Lung biopsy or BALF for mNGS is recommended for patients with suspected pulmonary fungal infection to identify the pathogen as early as possible. The combination of biopsy and BALF for mNGS may be considered when higher diagnostic efficacy is required.

Acknowledgments

We would like to thank Editage (www.editage.cn) for English language editing.

Disclosure

The authors report no conflicts of interest in this work.

References

- Li Z, Lu G, Meng G. Pathogenic fungal infection in the lung. *Front Immunol.* 2019;10. Available from: <https://www.ncbi.nlm.nih.gov/pmc/articles/PMC6616198/>.
- Arvanitis M, Mylonakis E. Diagnosis of invasive aspergillosis: recent developments and ongoing challenges. *Eur J Clin Invest.* 2015;45(6):646–652. doi:10.1111/eci.12448
- Perfect JR, Cox GM, Lee JY, et al. The impact of culture isolation of *Aspergillus* species: a hospital-based survey of aspergillosis. *Clin Infect Dis.* 2001;33(11):1824–1833. doi:10.1086/323900
- Hage CA, Carmona EM, Epelbaum O, et al. Microbiological laboratory testing in the diagnosis of fungal infections in pulmonary and critical care practice. An official American Thoracic Society Clinical Practice Guideline. *Am J Respir Crit Care Med.* 2019;200(5):535–550. doi:10.1164/rccm.201906-1185ST
- Surmont I, Stockman W. Gluconate-containing intravenous solutions: another cause of false-positive galactomannan assay reactivity. *J Clin Microbiol.* 2007;45(4):1373. doi:10.1128/JCM.02373-06
- Hage CA, Reynolds JM, Durkin M, Wheat LJ, Knox KS. Plasmalyte as a cause of false-positive results for *Aspergillus* galactomannan in bronchoalveolar lavage fluid. *J Clin Microbiol.* 2007;45(2):676–677. doi:10.1128/JCM.01940-06
- Racil Z, Kocmanova I, Lengerova M, Winterova J, Mayer J. Intravenous PLASMA-LYTE as a major cause of false-positive results of platelia aspergillus test for galactomannan detection in serum. *J Clin Microbiol.* 2007;45(9):3141–3142. doi:10.1128/JCM.00974-07
- Gu W, Miller S, Chiu CY. Clinical metagenomic next-generation sequencing for pathogen detection. *Annu Rev Pathol Mech Dis.* 2019;14(1):319–338. doi:10.1146/annurev-pathmechdis-012418-012751
- Miao Q, Ma Y, Wang Q, et al. Microbiological diagnostic performance of metagenomic next-generation sequencing when applied to clinical practice. *Clin Infect Dis.* 2018;67(suppl_2):S231–S240. doi:10.1093/cid/ciy693
- Li Y, Sun B, Tang X, et al. Application of metagenomic next-generation sequencing for bronchoalveolar lavage diagnostics in critically ill patients. *Eur J Clin Microbiol Infect Dis off Publ Eur Soc Clin Microbiol.* 2020;39(2):369–374. doi:10.1007/s10096-019-03734-5
- Zhang H-C, Ai J-W, Cui P, et al. Incremental value of metagenomic next generation sequencing for the diagnosis of suspected focal infection in adults. *J Infect.* 2019;79(5):419–425. doi:10.1016/j.jinf.2019.08.012
- Li H, Gao H, Meng H, et al. Detection of pulmonary infectious pathogens from lung biopsy tissues by metagenomic next-generation sequencing. *Front Cell Infect Microbiol.* 2018;8:205. doi:10.3389/fcimb.2018.00205
- Wang J, Han Y, Feng J. Metagenomic next-generation sequencing for mixed pulmonary infection diagnosis. *BMC Pulm Med.* 2019;19(1):252. doi:10.1186/s12890-019-1022-4
- Meyer KC, Raghu G, Baughman RP, et al. An official American Thoracic Society Clinical Practice Guideline: the clinical utility of bronchoalveolar lavage cellular analysis in interstitial lung disease. *Am J Respir Crit Care Med.* 2012;185(9):1004–1014. doi:10.1164/rccm.201202-0320ST
- Huang J, Jiang E, Yang D, et al. Metagenomic next-generation sequencing versus traditional pathogen detection in the diagnosis of peripheral pulmonary infectious lesions. *Infect Drug Resist.* 2020;13:567–576. doi:10.2147/IDR.S235182
- Li H, Durbin R. Fast and accurate short read alignment with Burrows-Wheeler transform. *Bioinforma Oxf Engl.* 2009;25(14):1754–1760. doi:10.1093/bioinformatics/btp324
- Wang J, Xu H, Li Z, et al. Pathogens in patients with granulomatous lobular mastitis. *Int J Infect Dis.* 2019;81:123–127. doi:10.1016/j.ijid.2019.01.034
- Donnelly JP, Chen SC, Kauffman CA, et al. Revision and update of the consensus definitions of invasive fungal disease from the European organization for research and treatment of cancer and the mycoses study group education and research consortium. *Clin Infect Dis.* 2020;71(6):1367–1376. doi:10.1093/cid/ciz1008
- Li N, Cai Q, Miao Q, Song Z, Fang Y, Hu B. High-throughput metagenomics for identification of pathogens in the clinical settings. *Small Methods.* 2021;5(1):2000792. doi:10.1002/smt.202000792

Infection and Drug Resistance

Dovepress

Publish your work in this journal

Infection and Drug Resistance is an international, peer-reviewed open-access journal that focuses on the optimal treatment of infection (bacterial, fungal and viral) and the development and institution of preventive strategies to minimize the development and spread of resistance. The journal is specifically concerned with the epidemiology of

antibiotic resistance and the mechanisms of resistance development and diffusion in both hospitals and the community. The manuscript management system is completely online and includes a very quick and fair peer-review system, which is all easy to use. Visit <http://www.dovepress.com/testimonials.php> to read real quotes from published authors.

Submit your manuscript here: <https://www.dovepress.com/infection-and-drug-resistance-journal>