

## Case series of scleral patch grafts during COVID-19 pandemic

*E Lalitha Siva Jyothi, O Gopala Krishna<sup>1</sup>,  
P Lakshmana Rao<sup>2</sup>, P Raja Sekhar<sup>3</sup>*

Scleral graft is done for clinical conditions as scleral melt post pterygium surgery, immune or infection related scleral melt, for covering the tubes of Ahmed glaucoma valve implant, for covering the orbital implants post enucleation, etc. A review of literature revealed the use of sclera for corneal perforations in the past, but became obsolete after the cornea being used for patch grafts. Now in this COVID-19 time, due to scarcity of corneal tissue, this technique of scleral patch grafts can be considered as an alternative to corneal patch grafts, which serves well the tectonic/therapeutic purpose and helps salvage the eye.

**Key words:** Corneal abscess, patch graft, perforation, sclera

Human scleral grafts are widely used in ophthalmic surgery as in ocular surface reconstruction after complicated filtering bleb surgery, in Ahmed glaucoma valve (AGV) implantation

Access this article online	
<b>Quick Response Code:</b>	<b>Website:</b> www.ijo.in
	<b>DOI:</b> 10.4103/ijo.IJO_3784_20

Chief Consultant, Cornea and Ocular Surface Disorders, Modern Eye Hospital and Research Center, <sup>1</sup>Chief Consultant and Medical Director, Cataract and Anterior Segment, Modern Eye Hospital and Research Center, <sup>2</sup>Chief Consultant and Medical Director, Squint and Refractive Surgeries, Modern Eye Hospital and Research Center, <sup>3</sup>Chief Consultant, Department of Vitreo Retinal Services, Modern Retina Centre, Nellore, Andhra Pradesh, India

**Correspondence to:** Dr. E Lalitha Siva Jyothi, Department of Cornea and Ocular Surface Disorders, Modern Eye Hospital and Research Center, #16-11-101, Pogathota, Nellore - 524 001, Andhra Pradesh, India. E-mail: lalithajyothi030@gmail.com

Received: 04-Jan-2021

Revision: 06-Jun-2021

Accepted: 09-Jul-2021

Published: 25-Aug-2021

surgeries, buckle surgeries, post-ptyerygium surgery sclera melt, etc.<sup>[1-6]</sup> Preparation and processing of sclera are easy compared to corneal transplants, can be stored at least for 1 year, and thus can be used in such crisis or pandemic like COVID-19 times, where there is a scarcity of corneal tissue.<sup>[3,5,6]</sup> Heterogeneous sclera soaked in 5% povidone-iodine solution for 4 min and copiously rinsed with balanced salt solution, dry preserved in glycerol or in 100% ethyl alcohol, and subsequently trimmed in size after lamellar dissection with a crescent blade to fit into the required area of the ocular surface. Routine tests to rule out human immunodeficiency virus, hepatitis B and hepatitis C are done. In 1946, Larson introduced this technique to treat perforated cornea using an autologous scleral transplant for a peripheral corneal perforation with exposure keratopathy in a 7-year-old girl, which proved to be safe with no complications reported.

### Case Reports

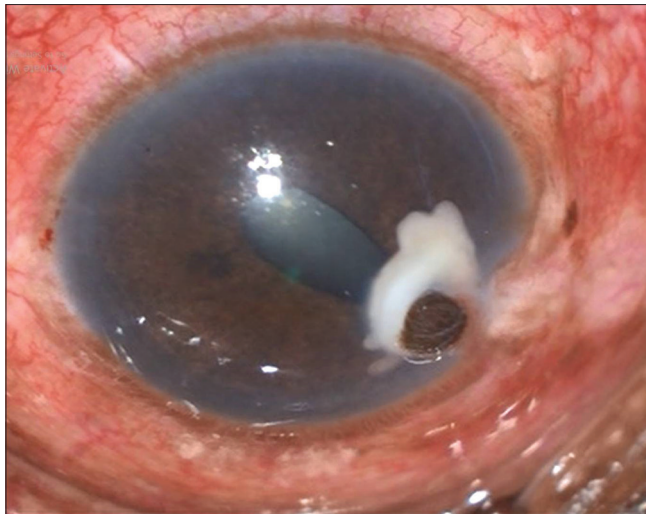
#### Case 1

A 50-year-old farmer presented with complaints of pain and redness following injury with stick 10 days back. Patient was on treatment with moxifloxacin eye drops 6 times per day, but with no relief. On examination, his BCVA was 20/20 Right Eye (RE) and 20/100 Left Eye (LE). Slit-lamp examination revealed deep stromal corneal infiltrate in inferior peripheral quadrant and was advised corneal scraping for Gram's, Potassium Hydroxide (KOH), and culture sensitivity but he denied. Patient was started on the empirical treatment of topical natamycin hourly, fortified vancomycin hourly, tobramycin eye ointment thrice daily, and cycloplegics twice daily, and he was reviewed after 5 days. On review examination, visual acuity dropped to 20/200, we noted a perforated corneal ulcer [Fig. 1] with shallow anterior chamber LE and RE status quo. We planned for a corneal patch graft or tenonoplasty with Amniotic Membrane Graft (AMG). But due to the COVID-19 pandemic, we could not procure cornea from any eye bank/harvest cornea. In view of severe thinning of cornea adjacent to perforation, tenonoplasty with AMG would not be successful

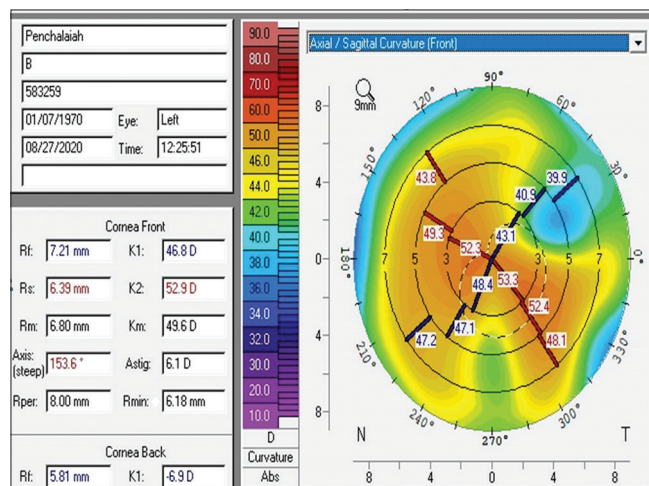
This is an open access journal, and articles are distributed under the terms of the Creative Commons Attribution-NonCommercial-ShareAlike 4.0 License, which allows others to remix, tweak, and build upon the work non-commercially, as long as appropriate credit is given and the new creations are licensed under the identical terms.

**For reprints contact:** WKHLRPMedknow\_reprints@wolterskluwer.com

**Cite this article as:** Siva Jyothi EL, Gopala Krishna O, Lakshmana Rao P, Raja Sekhar P. Case series of scleral patch grafts during COVID-19 pandemic. Indian J Ophthalmol 2021;69:2530-2.



**Figure 1:** Corneal abscess with perforation and iris prolapse

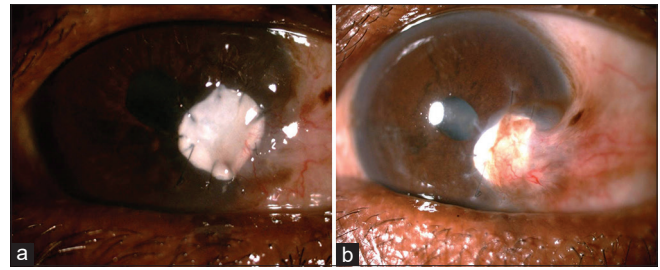


**Figure 3:** Pentacam at 12 weeks post-operatively to assess suture-induced astigmatism

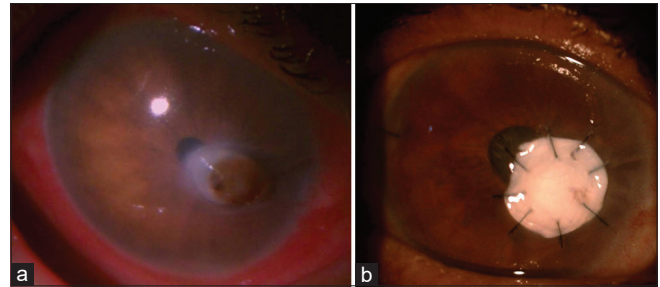
and decided to perform a scleral patch graft. We had 100% ethyl alcohol preserved sclera readily available in our hospital. Hence, we performed a 4-mm lamellar scleral patch graft. At 15-day post-op review, eye was quiet, scleral patch graft *in situ* [Fig. 2a]. LE BSVA was 20/125 with refraction + 1.00/+4.00 cyl at 155. The culture report was Suggest of (s/o). Pneumococci, and therefore the patient was started fortified amikacin, fortified taxim eye drops, and chloramphenicol eye ointment. Twelve weeks later, pentacam was done to assess tight sutures for removal [Fig. 3]. After tight suture removal, the patient's visual acuity improved to 20/70 with -2.00/-2.00 cyl at 65, with stable and well taken up scleral graft, which got vascularized to form pseudopterygium [Fig. 2b].

#### Case 2

A 55-year-old female presented with complaints of pain and diminished vision in RE for 2 weeks. On examination, RE revealed 3 mm paracentral, deep stromal corneal infiltrate with thinning and LE immature cataract. BCVA for RE was PL+ and PR+ and LE was 20/35. The patient was started on fortified vancomycin eye drops hourly and atropine eye drops twice and was reviewed after 3 days. Review examination revealed a perforated paracentral corneal ulcer [Fig. 4a] with iris incarceration in perforation and shallow anterior chamber. We did a scleral patch graft and postoperatively patient was



**Figure 2:** (a) Post-operative scleral patch graft at 4 weeks (b) post-operative scleral patch graft at 12 weeks



**Figure 4:** (a) Corneal abscess with perforation (b) post-operative scleral patch graft at 4 weeks

continued with moxifloxacin eye drops, loteprednol eye drops QID, and Homide eye drops BD. RE post-op first-week examination revealed intact scleral patch graft [Fig. 4b] with quiet anterior chamber and sutures *in situ*. LE was quiet on second postop review after 4 weeks, eye quiet and VA was 20/400 with pinhole improving to 20/200.

#### Case 3

A 50-year-old male, welder, presented with left eye pain and redness following injury with iron piece 10 days prior. On evaluation, BCVA was 20/20 RE and 20/130 LE. Slit lamp examination revealed 3 mm posterior corneal abscess at mid periphery and immature senile cataract. The patient was advised suture biopsy, but he denied it. The patient was started on empirical treatment with fortified Aminogen and fortified vancomycin hourly and reviewed a week later with no improvement. Fortified amphotericin B hourly was added and reviewed in a week. Visual acuity dropped to 20/400 and corneal abscess worsened with increasing stromal edema. The patient was advised corneal or scleral patch graft. Due to the COVID-19 pandemic and scarcity of corneal tissues, we did a lamellar scleral patch graft and the excised corneal button was sent for culture and sensitivity, which reported *Hemophilus influenzae* and the patient was started on topical antibiotics of ofloxacin and amikacin hourly for first 10 days and later 6 times per day. Slit-lamp examination revealed *in situ* sclera graft with formed anterior chamber and immature senile cataract and visual acuity improved to 20/130.

#### Discussion

Sclera can easily be harvested from whole eye donors and preserved either in 100% ethyl alcohol or in glycerol. Scleral tissue serves the tectonic purpose well as it is strong, flexible, and easy to mould to close the defect or perforation. The limitations are poor visibility beyond opaque sclera patch graft, poor cosmetic result, and monitoring for any necrosis or melting of graft as it is avascular. Sclera is well-tolerated, unlike cornea, with minimal rejection rate and inflammatory reaction. Therefore, scleral patch graft is an alternative to corneal patch graft in such a pandemic crisis.

## Conclusion

The technique of scleral patch graft can be considered as an alternative to corneal patch grafts for tectonic or therapeutic purposes, especially in situations where donor corneal tissue is scarce.

### Declaration of patient consent

The authors certify that they have obtained all appropriate patient consent forms. In the form, the patients have given their consent for their images and other clinical information to be reported in the journal. The patients understand that their names and initials will not be published and due efforts will be made to conceal their identity, but anonymity cannot be guaranteed.

### Financial support and sponsorship

Nil.

### Conflicts of interest

There are no conflicts of interest.

## References

1. Agarwal A. Scleral thinning, a complication after pterygium excision. *Ocular Surgery News U.S.* 2010.
2. Nguyen QD, Foster CS. Scleral patch graft in the management of necrotizing scleritis. *Int Ophthalmol Clin* 1999;39:109-31.
3. Sangwan VS, Jain V, Gupta P. Structural and functional outcome of scleral patch graft. *Eye (Lond)* 2007;21:930-5.
4. Barman M, Finger PT, Milman T. Scleral patch grafts in the management of uveal and ocular surface tumors. *Ophthalmology* 2012;119:2631-6.
5. Hodge C, Sutton G, Devasahayam R, Georges P, Treloggen J, Cooper S, *et al.* The use of donor scleral patch in ophthalmic surgery. *Cell Tissue Bank* 2017;18:119-28.
6. Dubey S, Rajurkar K, Kapur N, Acharya M. Heterologous, human donor sclera as the patch graft in glaucoma drainage device surgery. *J Glaucoma* 2017;26:e128-9.