

All children are presently receiving nutritional supplementation and intermittent transfusions. RBC enzymopathies arise from mutations in genes coding for RBC metabolic enzymes. Deficiency of these enzymes leads to impaired cellular energy and/or increases the levels of oxidative stress, leading to premature removal of RBCs in the spleen and decreased red blood cell survival [1]. There are enzymes other than G6PD and PK, which are involved in nucleotide metabolism. The important ones are pyrimidine-5-nucleotidase (pyrimidine metabolism) and adenylate kinase and adenosine deaminase (purine metabolism) [1]. The clinical features of enzymopathies are highly variable, ranging from fully compensated hemolysis to severe transfusion-dependent hemolytic anemia. The severity of anemia may worsen during infections, oxidant exposure any other physiological stress [2-4].

Enzymopathies pose a diagnostic challenge and patients may undergo repeated unsuccessful investigations over the years. Some clues include the presence of normocytic/macrocyclic anemia with signs of hemolysis like indirect hyperbilirubinemia and reticulocytosis, along with a history of episodic/repeated blood transfusion for anemia. The diagnosis of a RBC enzymopathy is mainly based on exclusion; a negative DCT, a normal OFT, no specific RBC morphological abnormalities, and no evidence for abnormal hemoglobin [5]. Timely targeted NGS would help in the confirmation of diagnosis [2].

Treatment remains mainly supportive. Splenectomy is indicated in severe cases. Restoration of normal enzyme levels following bone marrow transplantation has been occasionally reported [5]. A novel treatment including enzyme activator is under development and this might provide a new option for the severe phenotype [6].

MEENA SIVASANKARAN,<sup>1\*</sup> VAMSI KRISHNA REDDY,<sup>2</sup>  
VIMAL KUMAR,<sup>1</sup> DEENADAYALAN MUNIRATHNAM<sup>1</sup>  
From Departments of <sup>1</sup>Pediatric Haemato-Oncology and  
Bone Marrow Transplantation, and <sup>2</sup>Pediatrics,  
Kanchi Kamakoti CHILD Trust Hospital,  
Nungambakkam, Chennai, Tamil Nadu.  
\*meenasanakan04@gmail.com

## REFERENCES

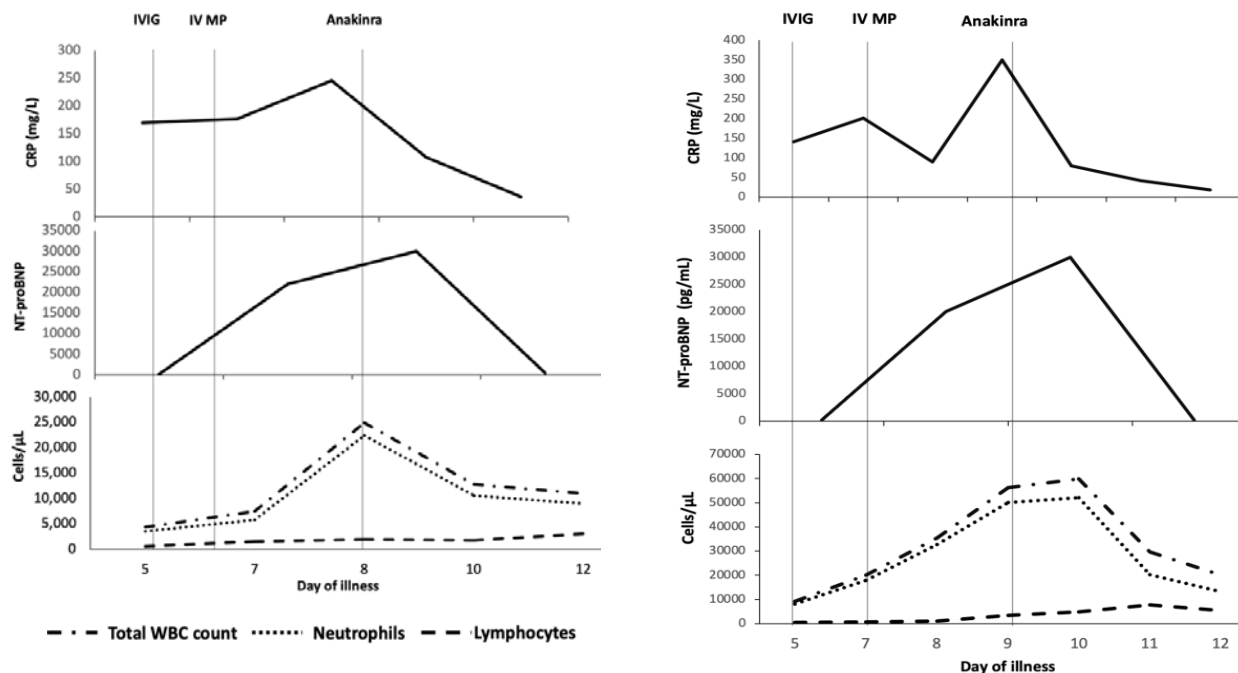
1. Koralkova P, Van Solinge WW, van Wijk R. Rare hereditary red blood cell enzymopathies associated with hemolytic anemia—pathophysiology, clinical aspects, and laboratory diagnosis. *Int J Lab Hematol.* 2014;36:388-97.
2. Jamwal M, Aggarwal A, Das A, et al. Next-generation sequencing unravels homozygous mutation in glucose-6-phosphate isomerase, GPIc. 1040G> A (p. Arg347His) causing hemolysis in an Indian infant. *Clinica Chimica Acta.* 2017;468:81-4.
3. Abrusci P, Chiarelli LR, Galizzi A, et al. Erythrocyte adenylate kinase deficiency: characterization of recombinant mutant forms and relationship with nonspherocytic hemolytic anemia. *Exp Hematol.* 2007;35:1182-9.
4. Grace RF, Bianchi P, van Beers EJ, et al. Clinical spectrum of pyruvate kinase deficiency: data from the Pyruvate Kinase Deficiency Natural History Study. *Blood.* 2018;131:2183-92.
5. Tanphaichitr VS, Suvatte V, Issaragrisil S, et al. Successful bone marrow transplantation in a child with red blood cell pyruvate kinase deficiency. *Bone marrow transplantation.* 2000;26:689-90.
6. Grace RF, Glader B. Red blood cell enzyme disorders. *Pediatr Clin North Am.* 2018;65:579-95.

## Anakinra in Refractory Multisystem Inflammatory Syndrome in Children (MIS-C)

A small proportion of children can develop a hyper-inflammatory condition 2 to 4 weeks following an infection or exposure to SARS-CoV2 virus termed interchangeably as multisystem inflammatory syndrome in children (MIS-C) or Pediatric Inflammatory Multisystem Syndrome temporally associated with SARS-CoV-2 virus (PIMS-TS) [1]. The pathogenesis of this novel condition remains elusive and treatment protocols are predominantly empirical. Intravenous immunoglobulin (IVIG) alone or with corticosteroids are the suggested first line agents [2,3]. In those with refractory disease (defined by the presence of persistent fever and/or significant end-organ involvement despite initial immunomodulation), second line treatment options include IL-1, IL-6, and tumor necrosis factor (TNF) blockers [2,3]. The PIMS-TS arm of the RECOVERY trial is currently evaluating tocilizumab and anakinra for refractory disease [5].

The experience with use of anakinra in India is sparse due to non-availability of the drug. We report our experience with the use of anakinra in two children with refractory MIS-C.

**Case 1:** A 11-year-old boy was referred for fever, abdominal pain and diarrhea of 5 days duration. At presentation he was hypotensive (BP 70/40 mm Hg) with bilateral non purulent conjunctival suffusion and an erythematous maculopapular rash over his trunk. Investigations revealed lymphopenia (total white blood cell count (WBC) 4,350/iL, lymphocytes 4%), elevated inflammatory markers (CRP 170 mg/L, ESR 72 mm/hour, LDH 359 U/L, ferritin 1,200ng/mL, d-Dimer 12,500ng/mL), hyponatremia (130mEq/L) and increased NT-proBNP levels (>20,000pg/mL). Serology was positive for IgG SARS-CoV-2 antibodies (Chemiluminescence, titer 74.9 AU/mL). An echocardiogram showed decreased left ventricular function (LVEF, 40%). A diagnosis of MIS-C was considered, and he was given IVIG (2 g/kg) with intravenous methylprednisolone (IVMP) (2 mg/kg). Noradrenaline infusion (0.15 µg/kg/min) for hypotension and empirical antibiotics were commenced simultaneously. The dose of methylprednisolone was increased (10 mg/kg, once daily for three days), and adrenaline infusion (0.15 µg/kg/min) was started for persistent hypotension. He



IVIG- intravenous immunoglobulin (2 g/kg), IVMP- intravenous methylprednisolone (10mg/kg once daily)

**Fig. 1** Trend of inflammatory markers and therapeutic interventions in (a) Case 1 and (b) Case 2.

continued to be febrile and hypotensive with elevated inflammatory markers (**Fig. 1a**). Considering refractory disease, anakinra (5 mg/kg/day in two divided doses, subcutaneously) was initiated. There was a dramatic improvement in his clinical status with abrupt cessation of fever and normalization of blood pressure within 12 hours. LVEF increased subsequently (60%). Anakinra was discontinued after 48 hours, and he was discharged on a tapering dose of steroids and aspirin. On follow up at two- and six weeks, LVEF continued to be normal.

**Case 2:** A 9-year-old boy presented with fever and diarrhea of five days. On examination, he had bilateral conjunctival suffusion, red lips, strawberry tongue, erythematous maculo-papular rash, and pedal edema. Investigations revealed lymphopenia (WBC count 9,230/ $\mu$ L, lymphocyte 6%), elevated acute phase reactants (CRP 140 mg/L, ESR 60 mm/hr, ferritin 596 ng/mL, d-Dimer 9120 ng/mL), and hyponatremia (127 mEq/L). He tested positive for IgG SARs-CoV-2 anti-bodies (Biomerieux, Index 10.95). An echocardiogram showed dilatation of the right coronary artery (RCA, z-score 2.19). His presentation was consistent with Kawasaki disease like phenotype of MIS-C and he was given IVIG (2 g/kg) with IVMP (2 mg/kg/day). On day 3 of admission, fever recurred, and he developed hypotension necessitating inotropic support (noradrenaline, 0.15  $\mu$ g/kg/min). Inflammatory markers and NT-proBNP levels had further increased (**Fig. 1b**). Repeat echocardiogram showed a decrease in LVEF (35%) and progression of RCA involvement (z-score 3.5). The dose of methylprednisolone was increased to 10 mg/kg once daily for 3 days. On day 5 of admission, his inotropic requirement (adrenaline, 0.5  $\mu$ g/kg/min) and inflammatory markers progressively increased. Anakinra (6 mg/kg/day in two divided doses, subcutaneously) was commenced for

refractory disease. Within 48 hours, he was off inotropic support with defervescence of fever, down trending inflammatory markers and normal LVEF (60%). He was discharged on a slow taper of oral steroids and aspirin. On follow up at two- and six weeks, coronary vessels and LVEF were within normal limits.

Anakinra is a recombinant IL-1R antagonist that blocks the binding of both IL-1 $\alpha$  and IL-1 $\beta$  to IL-1R, thereby inhibiting the proinflammatory effects of IL-1. According to the American College of Rheumatology clinical guidance, anakinra (4-10 mg/kg/day) is the preferred monoclonal antibody in refractory MIS-C [4]. However, the United Kingdom national consensus guidance recommends tocilizumab, anakinra or infliximab depending on clinician preference [3]. In comparison to tocilizumab or infliximab, the short half-life of anakinra makes it more favorable for use in the Indian context where secondary infections are a cause of concern. In fact, anakinra was found to be beneficial in patients with severe sepsis, especially in the subset with macrophage activation syndrome [6]. The cost of treatment with anakinra compares favorably with tocilizumab. Our experience re-emphasizes that anakinra can be an effective therapeutic agent in children with MIS-C who do not respond to IVIG and corticosteroids.

CHANDRIKA S BHAT,<sup>1\*</sup> RAKSHAY SHETTY,<sup>2</sup> DEEPAK RAMESH,<sup>2</sup>  
AFREEN BANU,<sup>2</sup> ATHIMALAI PET V RAMANAN<sup>3</sup>  
From <sup>1</sup>Pediatric Rheumatology Services, and  
<sup>2</sup>Pediatric Intensive Care Services,  
Rainbow Children's Hospital, Bangalore, Karnataka, India;  
<sup>3</sup>Bristol Royal Hospital for Children and Translational Health  
Sciences, University of Bristol, United Kingdom.  
\*chandrika.s.bhat@gmail.com

## REFERENCES

1. Bhat CS, Gupta L, Balasubramanian S, Singh S, Ramanan AV. Hyperinflammatory syndrome in children associated with COVID-19: Need for awareness. *Indian Pediatr.* 2020;57:929-35.
2. Fouriki A, Fougère Y, De Camaret C, et al. Case series of children with multisystem inflammatory syndrome following SARS-CoV-2 infection in Switzerland. *Front Pediatr.* 2021;8:594127.
3. Harwood R, Allin B, Jones CE, et al. PIMS-TS National Consensus Management Study Group. A National Consensus Management Pathway For Paediatric Inflammatory Multisystem Syndrome Temporally Associated With COVID-19 (PIMS-TS): Results of a National Delphi Process. *Lancet Child Adolesc Health.* 2021;5:133-41.
4. Henderson LA, Canna SW, Friedman KG, et al. American College of Rheumatology Clinical Guidance for Multisystem Inflammatory Syndrome in Children Associated With SARS-CoV-2 and Hyperinflammation in Pediatric COVID-19: Version 2. *Arthritis Rheumatol.* 2021;73:e13-e29.
5. Nuffield Department of Population Health. Information for site staff 2020. Accessed June 21, 2021. Available from: <https://www.recoverytrial.net/for-site-staff>
6. Shakoory B, Carcillo JA, Chatham WW, et al. Interleukin-1 receptor blockade is associated with reduced mortality in sepsis patients with features of the macrophage activation syndrome: Re-analysis of a prior phase III trial. *Crit Care Med.* 2016;44:275-28.

## Acute Severe Heart Failure in a Child With Congenital Heart Defect and Multisystem Inflammatory Syndrome in Children (MIS-C)

Myocardial involvement is a known feature of multisystem inflammatory syndrome in children (MIS-C), with mild ventricular dysfunction being the commonest finding. We describe a child who had congenital heart defect with complete heart block (CHB), and presented to us with MIS-C, but due to a rare complication succumbed to intractable heart failure.

A 13-year-old boy was admitted with a history of high-grade fever, rash, body ache and vomiting for 4 days, and mild swelling over feet for 2 days. There was no history of dyspnea, cyanosis, syncope, loss of consciousness, or neurological symptoms. Hailing from a containment zone area for coronavirus disease 19 (COVID-19) two months back, neither the child, nor his family members had been symptomatic nor tested for severe acute respiratory syndrome coronavirus (SARS-CoV-2) infection. He was a known case of corrected transposition of great arteries (CCTGA), moderate pulmonary stenosis (PS), intact interventricular septum, small ostium secundum atrial septal defect (ASD), and CHB, since infancy without any previous admissions.

On admission, he was conscious, irritable and febrile. Pulse rate was 80/min, respiratory rate 28/min, no distress, blood pressure 100/60 mmHg, and saturation 96% on room air. He was underweight (body mass index 12.4 kg/m<sup>2</sup>; <-3 SDS) and had a petechial rash over the body with bilateral pedal edema. The first heart sound was normal and pulmonary component of second heart sound was soft. A grade III/VI ejection systolic murmur in the left upper parasternal area was present. Rest of the systemic examination was unremarkable. We considered MIS-C and dengue fever as the possibilities. Investigations revealed hemoglobin of 13.3 g/dL, total leucocyte count of 7.2×10<sup>9</sup>/L, with relative neutrophilia (80%) and lymphocytopenia (14%), and thrombocytopenia (37×10<sup>9</sup>/L). His C-reactive protein (CRP) was elevated (62.9 mg/L), D-dimer 4674 ng/mL was increased, NT-pro

BNP 14352 pg/mL was highly elevated with hypoalbuminemia (2.9 g/dL). Renal function tests were normal. Anti-SARS-CoV-2 IgG antibody was positive, and IgM antibody was negative. Dengue serology was negative and chest X-ray was normal. ECG showed CHB with a ventricular rate of 78/min. Echocardiogram confirmed the anatomy of CCTGA with mild tricuspid regurgitation (TR), trivial mitral regurgitation (MR), mild right ventricular (RV) dysfunction, normal coronaries and no evidence of infective endocarditis.

We made a diagnosis of MIS-C [2]. Increased NT Pro-BNP and ventricular dysfunction on echocardiography reflected the myocardial involvement in MIS-C [2,3].

He was treated with intravenous immunoglobulin (IVIG) infusion (2 g/kg over 48 hours) along with injection methylprednisolone pulse therapy (10 mg/kg/dose), milrinone infusion and low molecular weight heparin. On day 3 of admission, he started complaining of severe abdominal pain, increased irritability, tachypnea but no tachycardia, and started desaturating (SpO<sub>2</sub> 70%), despite being on high flow oxygen. Grade IV/VI pansystolic murmur was now audible over the left lower parasternal area and apex. Repeat chest X-ray showed cardiomegaly and pulmonary venous congestion, but no parenchymal involvement. Despite being electively put-on mechanical ventilation, the child remained hypoxic. Repeat echocardiogram showed severe MR due to ruptured chordae tendinae of the anterior leaflet, with the mobilized chordae giving an impression of a thrombus/vegetation attached to the edges of the flail leaflet. This caused gross coaptation failure and the regurgitant jet was eccentrically directed towards the ASD, through which there was now right to left shunting, causing cyanosis. The right atrium was dilated, right ventricle was dysfunctional and there was no thrombus/vegetation anywhere else. His heart rate did not show much variation, but inotropes doses were escalated in view of persistent hypotension. Extracorporeal membrane oxygenator (ECMO) and/or surgery was contemplated in view of persistent worsening but he went into sudden cardiac arrest and died.

Myocardial involvement is a known feature of MIS-C, and common cardiovascular complications reported are shock, cardiac arrhythmias, pericardial effusion, coronary artery dilatation, and reduced left ventricular ejection fraction [1-4]. Although the exact