

Question Title	Question Title
8. Do you feel there is a stigma towards migraine patients among healthcare professionals?	10. How many migraine preventive treatments do you try before referring the patient to a headache specialist?
Yes	1
No	2
Question Title	3
9. Have you ever had a migraine?	4
Yes	5+
No	

Pain Medicine, 22(9), 2021, 2138–2141

doi: 10.1093/pm/pnaa459

Advance Access Publication Date: 19 March 2021

Letter to the Editor

OXFORD

Long-Term Results with Adjuvant Ozone Therapy in the Management of Chronic Pelvic Pain Secondary to Cancer Treatment

Bernardino Clavo, MD, PhD, ^{*,†,‡,§,¶} Minerva Navarro, MD[†] Mario Federico, MD, PhD[‡] Emma Borrelli, MD, PhD, ^{||} Ignacio J. Jorge, MD, PhD[†] Ivone Ribeiro, MD[‡] Juan I. Rodríguez-Melcon, MD, PhD, [‡] Miguel A. Caramés, MD, [†] Norberto Santana-Rodríguez, MD, PhD^{§,|||,,†} and Francisco Rodríguez-Esparragón, BSc, PhD***

*Research Unit; [†]Chronic Pain Unit, and; [‡]Radiation Oncology, Dr. Negrín University Hospital, Las Palmas, Spain; [§]Instituto Universitario de Investigaciones Biomédicas y Sanitarias (IUIBS), BioPharm Group, Universidad de Las Palmas de Gran Canaria, Las Palmas, Spain; [¶]Grupo de Investigación Clínica en Oncología Radioterápica (GICOR), Madrid, Spain; ^{||}Department of Medical Biotechnologies, University of Siena, Siena, Italy; ^{|||}Section of Thoracic Surgery, Department of Surgery, King Faisal Specialist Hospital and Research Center, Riyadh, Kingdom of Saudi Arabia; ^{**}College of Medicine, Department of Surgery, Alfaisal University, Riyadh, Kingdom of Saudi Arabia

Funding sources: The publication of this paper and the subsequent randomized clinical trial (EudraCT number: 2019-000821-37, ClinicalTrials.gov: NCT04299893) is supported by a grant (PI 19/00458) from the Instituto de Salud Carlos III (Spanish Ministry of Science and Innovation, Madrid, Spain); a grant (016/2019) from the Fundación DISA (Las Palmas, Spain); and a grant (BF1-19-13), from the Fundación Española del Dolor (Spanish Pain Foundation, Madrid, Spain).

Conflicts of interest: The ozone therapy device Ozonosan Alpha-plus[®] was provided by Dr. Renate Viebahn (Dr. Hänslér GmbH, Iffezheim, Germany). The authors have no conflicts of interest to disclose.

Trial registration: EudraCT (European Union Drug Regulating Authorities Clinical Trials Database) 2019-000821-37; ClinicalTrials.gov NCT04299893.

Prior presentation: Preliminary data were 1) presented as oral communication at the Second International Traditional and Complementary Medicine Congress (Istanbul, Turkey, April 2019), organized with technical sponsorship of the World Health Organization, and 2) published as a Brief Report in the *Journal of Palliative Medicine*: Clavo B, Navarro M, Federico M, et al. Ozone therapy in refractory pelvic pain syndromes secondary to cancer treatment: A new approach warranting exploration. *J Palliat Med* 2020;24(1):97–102.

Key words: Cancer Pain; Cancer Survivorship; Chemotherapy-Induced Side Effects; Neuropathic Pain; Ozone Therapy; Chronic Pelvic Pain; Radiation-Induced Toxicity

Dear Editor,

Recently, we published a preliminary report about the potential benefit of adjuvant use of local and systemic ozone therapy (O₃T) in the management of refractory pelvic pain secondary to cancer treatment, at 3 months after ozone administration [1]. After that, several colleagues contacted us to ask for more details about the overall O₃T schedule and an update of the results at longer follow-up times. The aim of this letter is to try to answer those questions.

Management of local pain after pelvic tumor treatment requires excluding the possibility of tumor relapse and, at the same time, starting analgesic and opioid treatment as needed. If recurrent tumor is not found, persistent pelvic pain can be secondary to cancer treatments. In those patients with potentially prolonged life expectancy, high doses of opioids are controversial because their long-term safety and effectiveness have not been well established [2]. This management can be even more difficult if neuropathic pain is present, which may happen in 34% to 40%

of these patients [3]. We have previously described the potential clinical benefit of O₃T, with a prolonged effect, in the management of several side effects of cancer treatments, the most relevant at the pelvic level [4].

Recently [1], we reported encouraging preliminary results during the first 3 months of O₃T in a group of six cancer patients without evidence of tumor relapse but with refractory chronic pelvic pain secondary to cancer treatment (radiotherapy, chemotherapy, surgery, or a combination of them). All patients had previously received unsuccessful pain management with anti-inflammatory, co-adjuvants or opioid drugs, and half of them had also received treatment with interventional techniques. Moreover, two patients with pelvic pain secondary to cystitis (patients 2 and 4) requested cystectomy and had seriously contemplated suicide because of the pain. Table 1 summarizes patient details. Further clinical characteristics before O₃T were previously described [1]. Patients were evaluated at our multidisciplinary Chronic

Table 1. Relevant clinical characteristics and patient-reported changes after ozone therapy in continuous and acute pelvic pain

Patient Number	Age, years	Sex	Diagnosis	Months with Pain Before O ₃ T	Weeks of treatment	Number of Sessions	Continuous Pelvic Pain Before/After O ₃ T [†]	Acute Pelvic Pain Before/After O ₃ T [†]
1	35	F	Uterine cervix carcinoma. Vaginal pain, after RT+CT. Associated with vaginal dryness and ulceration. Tx: Antibiotics.	4	11	12	7.5/0	7.5/0
2*	54	M	Prostate carcinoma. Bladder pain, after RT (prostatic surgery 3 years earlier). Associated with hematuria. Tx: Opioids, interventional techniques.	15	15	17	10/10	10/10
3	61	M	Prostate carcinoma. Rectal pain, after endoscopic treatment. Associated with tenesmus. Tx: Opioids.	13	58	77	4.5/1	9/2
4*	64	M	Follicular lymphoma Stage IV-A. Bladder pain, after CT. Associated with interstitial cystitis. Tx: Opioids, interventional techniques.	30	46	64	10/0	10/0
5	60	F	Uterine cervix carcinoma. Vaginal and pelvic pain, after RT+CT. Associated with vaginal necrosis and recto-vaginal fistula. Tx: Opioids, antibiotics, hyperbaric oxygen.	15	22	37	7/0	7/0
6	71	F	Rectal adenocarcinoma. Rectal pain, after S+RT+CT. Associated with tenesmus. Tx: Loperamide. Opioids were rejected.	9	33	60	8/0	8/0
Mean ± SD or median (range)				14 (4–30)	28 (11–58)	49 (12–77)	7.8 + 2.1/1.8 + 4	8.6 + 1.3/2 + 4.0
P							0.005 [‡]	

*Patients 2 and 4 had previously requested cystectomy and had seriously contemplated suicide because of the pelvic pain. Patient 2: After further unsuccessful treatments, a cystectomy was performed 9 months after O₃T, although cystectomy did not completely relieve pelvic pain. Patient 4: Intradetrusor infiltrations with botulinum toxin-A and low-pressure bladder hydrodistension were maintained every 6 months as treatment for its interstitial cystitis.

[†]Pelvic pain according to the VAS before and at the end of ozone therapy.

[‡]Paired Student *t* test.

F = female; M = male; S = surgery; RT = radiotherapy; CT = chemotherapy; Tx = previous treatments other than anti-inflammatory and non-opioid drugs; SD = standard deviation.

Pain Unit for compassionate O₃T. Ozone treatment was further approved by the Health Care Ethics Committee and by our Research Ethics Committee (BCV-OZO-2019-01 study). Informed written consent was obtained for all patients. Pain before, during, and after O₃T was assessed on a visual analog scale (VAS) ranging from 0 (no pain) to 10 (worst imaginable pain).

On an outpatient basis, O₃T was administered by rectal, intravesical, and/or intravaginal approaches. Systemic O₃T by rectal insufflation was applied in five patients (patients 2, 3, 4, 5, and 6). Gas volume started at 180 mL/session and was slowly increased (depending on patient tolerance of bowel bloating) up to a maximum volume of 300 mL/session if tolerated. Initial O₃/O₂ concentration was 10 µg/mL (µg of O₃ per mL of O₂), which was increased by 5 µg/mL every two sessions until a final concentration of 30 µg/mL was reached. Intravesical O₃T (by insufflation of O₃/O₂ or instillations of ozonated water) was applied in two patients (patients 2 and 4). Vaginal O₃T (by O₃/O₂ insufflations or vaginal washing with ozonated water) was applied in two patients (patients 1 and 5). Further details were previously described [1]. When possible, the treatment schedule initially consisted of three sessions per week, and sessions were slowly reduced according to clinical improvement, from two sessions per week to one session per month at the very end of the treatment course. The length and final number of O₃T sessions depended on clinical evolution. The median duration of O₃T was 28 weeks (range: 11–58), and the median number of O₃T sessions was 49 weeks (range: 12–77).

After several months of unsuccessful treatments before O₃T, continuous pelvic pain was severe (VAS 7.8 ± 2.1). Pain significantly decreased after 3 months of O₃T applications (VAS 2.8 ± 3.8 , $P = 0.020$) and at the end of O₃T (VAS 1.8 ± 4 , $P = 0.010$). The benefit was maintained at 3 (VAS 1.9 ± 4 , $P = 0.006$), 6 (VAS 1.9 ± 4 , $P = 0.006$), and 9 (VAS 1.9 ± 4 , $P = 0.006$) months' follow-up after the end of O₃T. All but one patient (patient 2) were able to decrease or even discontinue analgesic intake requirements. Patient 2 was treated once per week, which is not an appropriate frequency for the first weeks of O₃T. Except in patient 2, episodes of acute pelvic pain (initial VAS 8.6 ± 1.3), spontaneous or during deposition or urination, also disappeared or decreased in frequency and intensity after 3 months of O₃T applications (VAS 3.1 ± 3.8 , $P = 0.011$) and at the end of O₃T (VAS 2 ± 4 , $P = 0.005$). The benefit was maintained at 3 (VAS 1.9 ± 4 , $P = 0.005$), 6 (VAS 1.7 ± 4.1 , $P = 0.005$), and 9 (VAS 1.7 ± 4.1 , $P = 0.005$) months' follow-up after the end of O₃T. The improvement in associated symptoms (vaginal dryness, hematuria, rectal or vaginal wounds, tenesmus, and the number of bowel movements per day) described in the initial report [1] was also maintained and/or improved during O₃T and after the end of O₃T. Figure 1 shows the evolution of continuous and acute pelvic pain.

In this group of patients, we report for the first time the potential usefulness of ozone as adjuvant therapy in the management of chronic pelvic pain secondary to cancer treatment. Our data show that initial pain decreases during the first 3 months of O₃T [1] and further improves during several months after the end of therapy. As

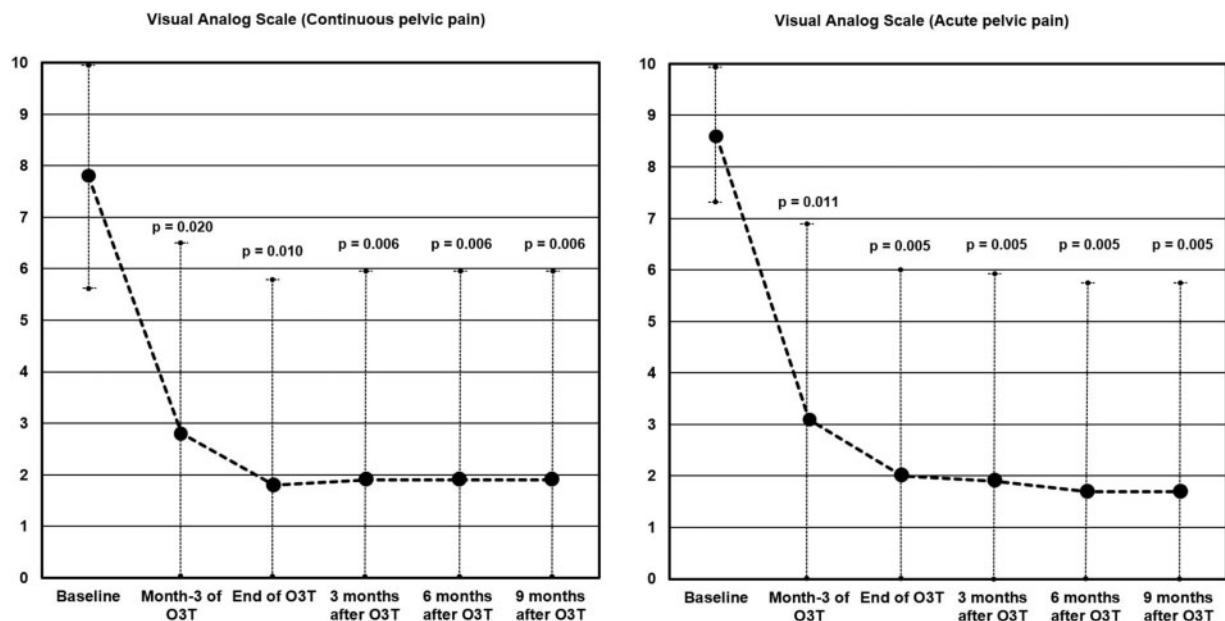


Figure 1. Clinical evolution of continuous and acute pelvic pain during and after ozone therapy. Pain levels according to the VAS. All but one of the patients showed clinically relevant improvement in pain levels after O₃T. (A) Continuous pelvic pain. Initial continuous pelvic pain (7.8 ± 2.1) was significantly decreased after 3 months of O₃T ($P = 0.020$) and at the end of O₃T ($P = 0.010$). The benefit was maintained at 3 ($P = 0.006$), 6 ($P = 0.006$), and 9 ($P = 0.006$) months' follow-up after the end of O₃T. (B) Acute pelvic pain. Initial acute pelvic pain (8.6 ± 1.3) was significantly decreased in frequency at intensity after 3 months of O₃T ($P = 0.011$) and at the end of O₃T ($P = 0.005$). The benefit was maintained at 3 ($P = 0.005$), 6 ($P = 0.005$), and 9 ($P = 0.005$) months' follow-up after the end of O₃T.

previously reported, the main side effects during O₃T were slight intestinal bloating for some hours after each session and occasional and moderate discomfort secondary to rectal tube placement [1, 4].

Oxidative stress, inflammation, and ischemia/hypoxia are the principal mechanisms involved in toxicity secondary to cancer treatments. Ozone therapy can modulate all those factors, inducing a controlled oxidative stress sufficient to induce an adaptive antioxidant and anti-inflammatory response of tissues at the local and/or systemic level, as we have previously described in detail [5].

To conclude, in our small cohort of patients, ozone therapy provided a clinically relevant improvement in patients with chronic pelvic pain secondary to cancer treatment. The potential addition of ozone therapy as adjuvant in the management of this clinical condition merits further research. A related randomized clinical trial is in progress (EudraCT: 2019-000821-37; ClinicalTrials.gov: NCT04299893).

References

1. Clavo B, Navarro M, Federico M, et al Ozone therapy in refractory pelvic pain syndromes secondary to cancer treatment: A new approach warranting exploration. *J Palliat Med* 2021;24(1):97–102.
2. Paice JA, Portenoy R, Lacchetti C, et al Management of chronic pain in survivors of adult cancers: American Society of Clinical Oncology clinical practice guideline. *J Clin Oncol* 2016;34(27):3325–45.
3. Bennett MI, Rayment C, Hjermstad M, et al Prevalence and aetiology of neuropathic pain in cancer patients: A systematic review. *Pain* 2012;153(2):359–65.
4. Clavo B, Ceballos D, Gutierrez D, et al Long-term control of refractory hemorrhagic radiation proctitis with ozone therapy. *J Pain Symptom Manage* 2013;46(1):106–12.
5. Clavo B, Rodriguez-Esparragon F, Rodriguez-Abreu D, et al Modulation of oxidative stress by ozone therapy in the prevention and treatment of chemotherapy-induced toxicity: Review and prospects. *Antioxidants (Basel)* 2019;8(12):588.

CORRIGENDUM

Pain Medicine, 22(9), 2021, 2141

doi: 10.1093/pm/pnab120

Advance Access Publication Date: 5 May 2021

Corrigendum

OXFORD

Corrigendum to: Evidence of Neural Microstructure Abnormalities in Type I Chiari Malformation: Associations among Fiber Tract Integrity, Pain, and Cognitive Dysfunction

James R. Houston , PhD, Michelle L. Hughes, MA, Ilana J. Bennett, PhD, Philip A. Allen, PhD, Jeffrey M. Rogers, PhD, Mei-Ching Lien, PhD, Haylie Stoltz, Ken Sakaie, PhD, Francis Loth, PhD, Jahangir Maleki, MD, PhD, Sarel J. Vorster, MD, and Mark G. Luciano, MD, PhD

Pain Medicine, Volume 21, Issue 10, October 2020, Pages 2323–2335, <https://doi.org/10.1093/pm/pnaa094>

After publication, the authors noted that they reported a sample of all females in the article. However, one of the participant/control pairings was miscoded and should have been coded as a set of males. The authors incorrectly indicated this characteristic of their sample in two places, once in the methods and once in the abstract. The correct information is below.

Abstract:

Published version – “**Methods.** Eighteen female CMI patients and 18 adult age- and education-matched control participants underwent DTI, were. . .”

Corrected version – “**Methods.** Eighteen CMI patients and 18 adult age- and education-matched control participants underwent DTI, were. . .”

Results:

Published version – “Thus, 18 adult CMI female patients and 18 matched adult healthy female controls comprised the final sample.”

Corrected version – “Thus, 18 adult CMI patients (1 male) and 18 matched adult healthy controls (1 male) comprised the final sample.”