

Artificial intelligence in gastroenterology: A state-of-the-art review

Paul T Kröner, Megan ML Engels, Benjamin S Glicksberg, Kipp W Johnson, Obaie Mzaik, Jeanin E van Hooft, Michael B Wallace, Hashem B El-Serag, Chayakrit Krittanawong

ORCID number: Paul T Kröner 0000-0002-7361-7883; Megan ML Engels 0000-0002-4708-3750; Benjamin S Glicksberg 0000-0003-4515-8090; Kipp W Johnson 0000-0002-5102-741X; Obaie Mzaik 0000-0001-7315-2548; Jeanin E van Hooft 0000-0002-4424-0079; Michael B Wallace 0000-0002-6446-5785; Hashem B El-Serag 0000-0001-5964-7579; Chayakrit Krittanawong 0000-0001-7953-335X.

Author contributions: Kröner PT contributed complete manuscript drafting, review of literature and data acquisition, critical manuscript revision; Engels MM contributed review of the literature, data acquisition, figure construction, table construction, manuscript review; Mzaik O contributed literature review, table construction; van Hooft JE and El-Serag HB contributed critical manuscript review; Wallace MB contributed manuscript structure, critical manuscript review; Krittanawong C contributed literature review, editing, critical manuscript review.

Conflict-of-interest statement: Dr. Krittanawong C discloses the following relationships – Member of the American College of Cardiology Solution Set Oversight Committee, the American Heart Association Committee of the Council on Genomic and Precision Medicine, and the American College of Cardiology/American

Paul T Kröner, Megan ML Engels, Obaie Mzaik, Michael B Wallace, Division of Gastroenterology and Hepatology, Mayo Clinic, Jacksonville, FL 32224, United States

Megan ML Engels, Cancer Center Amsterdam, Department of Gastroenterology and Hepatology, Amsterdam UMC, Location AMC, Amsterdam 1105, The Netherlands

Benjamin S Glicksberg, Kipp W Johnson, The Hasso Plattner Institute for Digital Health, Icahn School of Medicine at Mount Sinai, New York, NY 10029, United States

Jeanin E van Hooft, Department of Gastroenterology and Hepatology, Leiden University Medical Center, Amsterdam 2300, The Netherlands

Michael B Wallace, Division of Gastroenterology and Hepatology, Sheikh Shakhboub Medical City, Abu Dhabi 11001, United Arab Emirates

Hashem B El-Serag, Section of Gastroenterology and Hepatology, Michael E. DeBakey VA Medical Center and Baylor College of Medicine, Houston, TX 77030, United States

Hashem B El-Serag, Chayakrit Krittanawong, Section of Health Services Research, Michael E. DeBakey VA Medical Center and Baylor College of Medicine, Houston, TX 77030, United States

Chayakrit Krittanawong, Section of Cardiology, Michael E. DeBakey VA Medical Center, Houston, TX 77030, United States

Corresponding author: Chayakrit Krittanawong, MD, Doctor, Section of Health Services Research, Michael E. DeBakey VA Medical Center and Baylor College of Medicine, 1 Baylor Plaza, Houston, TX 77030, United States. chayakrit.krittanawong@bcm.edu

Abstract

The development of artificial intelligence (AI) has increased dramatically in the last 20 years, with clinical applications progressively being explored for most of the medical specialties. The field of gastroenterology and hepatology, substantially reliant on vast amounts of imaging studies, is not an exception. The clinical applications of AI systems in this field include the identification of premalignant or malignant lesions (*e.g.*, identification of dysplasia or esophageal adenocarcinoma in Barrett's esophagus, pancreatic malignancies), detection of lesions (*e.g.*, polyp identification and classification, small-bowel bleeding lesion on capsule endoscopy, pancreatic cystic lesions), development of objective scoring systems for risk stratification, predicting disease prognosis or treatment response [*e.g.*,

Heart Association (ACC/AHA) Task Force on Performance Measures, The Lancet Digital Health (Advisory Board), European Heart Journal Digital Health (Editorial board), Journal of the American Heart Association (Editorial board), JACC: Asia (Section Editor), The Journal of Scientific Innovation in Medicine (Associate Editor), and Frontiers in Cardiovascular Medicine (Associate Editor).

Open-Access: This article is an open-access article that was selected by an in-house editor and fully peer-reviewed by external reviewers. It is distributed in accordance with the Creative Commons Attribution NonCommercial (CC BY-NC 4.0) license, which permits others to distribute, remix, adapt, build upon this work non-commercially, and license their derivative works on different terms, provided the original work is properly cited and the use is non-commercial. See: <http://creativecommons.org/licenses/by-nc/4.0/>

Manuscript source: Invited manuscript

Specialty type: Gastroenterology and hepatology

Country/Territory of origin: United States

Peer-review report's scientific quality classification

Grade A (Excellent): 0
Grade B (Very good): B
Grade C (Good): 0
Grade D (Fair): 0
Grade E (Poor): 0

Received: May 11, 2021

Peer-review started: May 11, 2021

First decision: June 12, 2021

Revised: June 15, 2021

Accepted: September 15, 2021

Article in press: September 15, 2021

Published online: October 28, 2021

P-Reviewer: Shafqat S

S-Editor: Gao CC

L-Editor: A

P-Editor: Yuan YY

determining survival in patients post-resection of hepatocellular carcinoma), determining which patients with inflammatory bowel disease (IBD) will benefit from biologic therapy], or evaluation of metrics such as bowel preparation score or quality of endoscopic examination. The objective of this comprehensive review is to analyze the available AI-related studies pertaining to the entirety of the gastrointestinal tract, including the upper, middle and lower tracts; IBD; the hepatobiliary system; and the pancreas, discussing the findings and clinical applications, as well as outlining the current limitations and future directions in this field.

Key Words: Artificial intelligence; Machine learning; Deep learning; Clinical applications; Gastroenterology

©The Author(s) 2021. Published by Baishideng Publishing Group Inc. All rights reserved.

Core Tip: Artificial intelligence (AI) clinical applications in gastroenterology and hepatology, which heavily relies on imaging, have dramatically expanded in the last 20 years. These applications include the detection of lesions, identification of pre-malignant or malignant lesions, development of objective scoring systems for risk stratification, predicting disease prognosis or treatment response, or evaluation of metrics such as bowel preparation score or quality of endoscopic examination. The objective of this review is to pool the available AI-related studies pertaining to the entire gastrointestinal tract, discussing findings and clinical applications, as well as outlining the current limitations and future directions in this field.

Citation: Kröner PT, Engels MM, Glicksberg BS, Johnson KW, Mzaik O, van Hooft JE, Wallace MB, El-Serag HB, Krittanawong C. Artificial intelligence in gastroenterology: A state-of-the-art review. *World J Gastroenterol* 2021; 27(40): 6794-6824

URL: <https://www.wjgnet.com/1007-9327/full/v27/i40/6794.htm>

DOI: <https://dx.doi.org/10.3748/wjg.v27.i40.6794>

INTRODUCTION

As artificial intelligence (AI) continues to rapidly evolve in medicine, the clinical applications of this technology are becoming increasingly evident[1]. Relying heavily on endoscopic and radiologic imaging, gastroenterology has become an attractive field in which to apply AI. Special interest has already been devoted to several areas, including the detection of gastrointestinal neoplastic lesions to assist with rapid diagnosis, reduction of misdiagnosis, improvement in quality of imaging, reduction of interobserver variability in visual classifications, and radiologic and histopathologic interpretation[2-4].

AI is a broad term that encompasses disciplines such as machine learning (ML) and subdisciplines or specific techniques such as deep learning (DL) (Figure 1). The central motivation of ML to use large datasets to recognize patterns of interactions between variables, often ultimately in a way that allows the learned function to be applied to new data[5]. ML is composed of both “supervised” and “unsupervised” learning methods. The goal of supervised learning is to predict a labelled output focusing primarily on classifying data input into specific subgroups, or alternately for prediction of quantitative outcomes[6]. An example of supervised learning is training a system to assist in identifying gastric intestinal metaplasia (GIM) using a large database of lesions that have previously been identified by an operator as corresponding to GIM. In comparison, unsupervised learning does not have an output to predict. It relies on attempting to identify naturally occurring patterns from within the input, often to then group them accordingly (*e.g.*, tissue sample clustering based on similar gene expression values)[6]. DL is a subset of ML, based on artificial neural networks (ANN), which are loosely inspired by the neuronal interplay in the human brain. DL autonomously utilizes the data input to learn, identify, and leverage predictive factors of an outcome, which can use multi-layered systems [*i.e.*, convolutional neural networks (CNN)] to process complex information[3,7]. The realization of

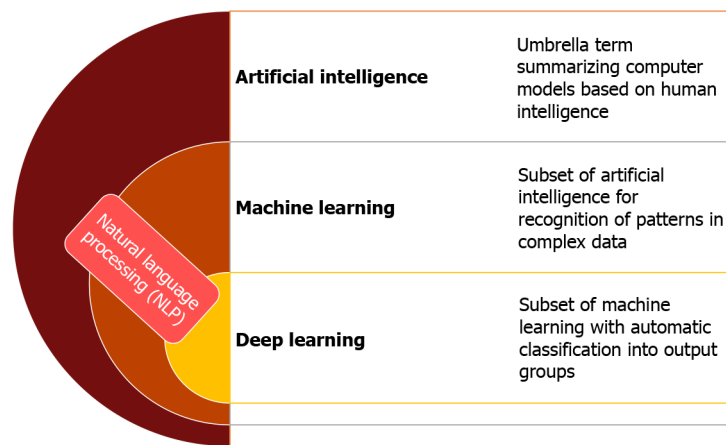


Figure 1 Primary concepts of artificial intelligence.

the concept of DL has recently become possible with rapid advancements in specialized computer hardware, such as increased graphics processing unit power, and accompanying software and algorithmic achievements.

With increased recognition of the importance of AI in gastroenterology, the first global AI in gastroenterology and endoscopy summit was held in Washington D.C. in late 2019, which included multiple experts in the domains of academia, industry and regulatory institutions. The consortium anticipated that in the next 10 years the clinical applications of AI in gastroenterology will positively influence patient care and clinical workflow. The consortium recognized the importance of a close multidisciplinary collaboration between gastroenterologists, industry, and regulatory institutions in the development and application of new technologies in the clinical setting[8]. Therefore, the main objective of this review is to introduce the topic of AI and its clinical applications, outline current limitations and knowledge gaps, and trace the future directions in each field by summarizing the global rapidly expanding pool of ever-changing literature to date (Figures 2 and 3).

UPPER GASTROINTESTINAL TRACT

Detection of premalignant and malignant lesions

The upper gastrointestinal tract has several areas of interest for detection of premalignant and malignant lesions, such as identification of dysplasia and early neoplasia in Barrett's esophagus (BE), esophageal squamous cell carcinoma (SCC), and gastric cancer (GC)[9] (Supplementary Table 1).

Despite the fact that histopathologic analysis is the gold standard to establish the diagnosis of BE and determine the presence of dysplasia, it is of paramount importance for endoscopists to obtain targeted biopsies from specific locations that harbor the actual lesion. By identifying areas that may harbor BE with or without dysplasia, AI can orient the clinician in performing directed biopsies instead of relying on random sampling. Importantly, detection of early esophageal neoplasia with conventional white light imaging (WLI) and digital chromoendoscopy [*i.e.*, narrow band imaging (NBI)] represents a challenge, an issue for which AI has been proposed as a possible solution[10,11].

In total, we included 8 studies that examined BE, all of which addressed the detection of dysplasia or early esophageal adenocarcinoma (EAC) based on endoscopic imaging or laser endomicroscopy[10-17]. The most popular analytic models were CNNs and support vector machines (SVMs), while cross-validation techniques were the primary basis of validation methods. In general, the models were able to discern between normal and dysplastic/neoplastic images with an accuracy of at least 89.9%, performing better than nonexpert endoscopists. De Groof *et al*[12] developed a DL algorithm based on a hybrid ResNet-UNet model using 4-fold per-patient cross-validation to detect early neoplasia in BE. The model was trained in a stepwise fashion, using a database with over 490000 endoscopic still images of the gastrointestinal tract for training, out of which 1247 corresponded to early BE neoplasia. This model achieved higher level of accuracy than non-expert endoscopists and could also detect the optimal biopsy site in up to 97% of patients. Ebigbo *et al*[14] developed a

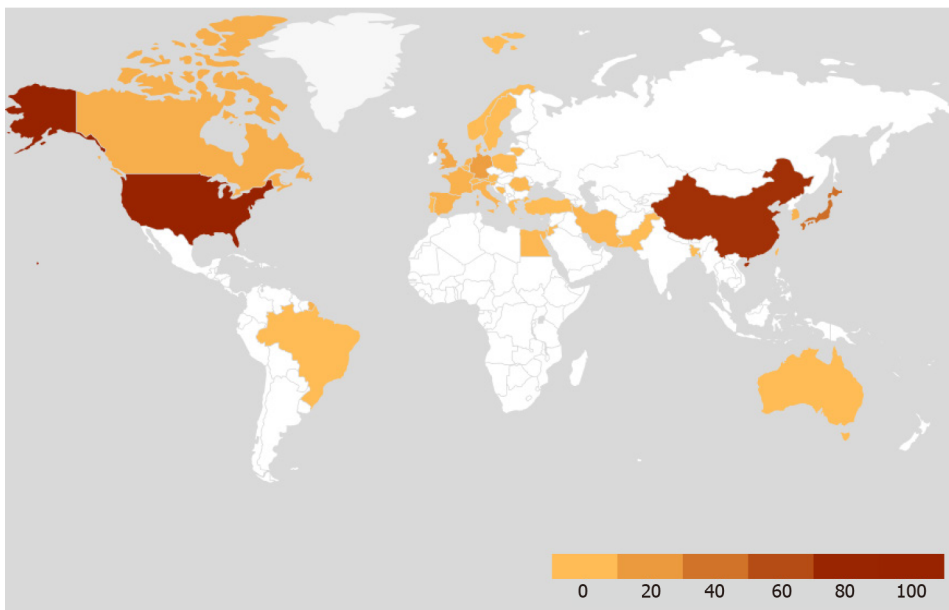


Figure 2 Geographic distribution of country from which the included studies originated.

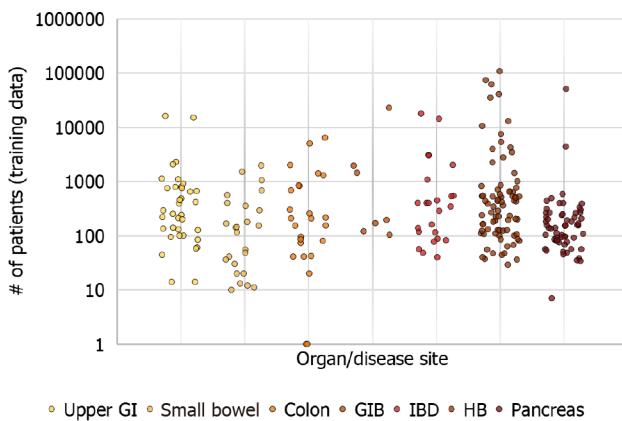


Figure 3 Scatterplot depicting distribution of studies across the organ systems in gastroenterology and hepatology. GI: Gastrointestinal; GIB: Gastrointestinal bleeding; IBD: Inflammatory bowel disease; HB: Hepatobiliary.

computer-aided diagnosis model based on ResNet that differentiated between normal BE and early EAC, with 89.9% accuracy, 83.7 sensitivity and 100% specificity.

Similarly, identification of SCC poses a similar clinical challenge, as traditional diagnostic techniques (*e.g.*, chromoendoscopy with lugol or NBI) have relatively low specificity[18]. As complex novel methods that rely heavily on endoscopic imaging such as endocytoscopy or volumetric laser endomicroscopy have been progressively implemented in clinical practice, the interpretation of large volumes of images has been noted to be a challenging and time-consuming issue[19]. Therefore, AI-assisted image interpretation has also found a use in identifying abnormalities in the image inputs[17].

Thirteen studies examining esophageal cancer were examined, of which 11 specifically studied SCC. Nine of the studies targeted to develop DL models for malignancy detection, while two studies aimed to develop models that predict malignancy depth of invasion with DL models. Most studies (8) were based on CNN models, while others used joint diagonalization principal component analysis (JDPCA), VGG16 Net, or GoogLeNet as classifiers. Although the values of accuracy, sensitivity and specificity in esophageal SCC detection varied between the studies, all models performed at least as good as endoscopists in lesion detection and characterization or substantially improved the endoscopists' lesion detection[20-30]. Fukuda *et al*[21] developed a DL model aimed at detecting suspicious lesions and characterize SCC using more than 28000 NBI-enhanced images in the construction of the model. The model achieved a higher sensitivity for SCC detection and higher accuracy for

SCC characterization from normal tissue than endoscopic experts. Two studies by Nakagawa *et al*[31] and Shimamoto *et al*[32] aimed at developing models that predicted esophageal malignancy depth utilizing a DL model based on a CNN with a belief-propagation decoder using independent validation datasets. These models achieved an accuracy of 89.2% and 91% in predicting invasion depth, with sensitivities of 70.8% and 90.1%, and specificities of 94.4% and 95.8%, respectively.

GC is the fourth most common cause of cancer-related death in the world. Identification of premalignant lesions or early gastric neoplasia is of paramount importance. Unfortunately, as with esophageal diseases, several studies have shown that conventional endoscopic imaging (*e.g.*, WLI or NBI) or other advanced endoscopic modalities (*e.g.*, magnifying endoscopy, blue laser imaging) have relatively low sensitivity and specificity in identifying premalignant or early neoplastic gastric lesions[33-36].

Twenty-four studies examined gastric malignancy or premalignant conditions. Eleven (46%) studies directly addressed early GC (EGC) detection, of which eight models used DL, two used SVM and one used JDPCA. The sample size in the training and validation datasets varied from less than 100 million to 1.03 million. The accuracy in EGC detection of all models ranged from 86.5%-98.7%, with sensitivity of 80.0%-96.7% and specificity of 89.2%-100%[30-37-51]. Specifically, Wu *et al*[52] developed a CNN-based model using over 9000 images to train the algorithm, which not only detected EGC lesions with a 92.5% accuracy, 94.0% sensitivity and 91.0% specificity but also performed significantly better than expert endoscopists at this task. Two studies, one based on faster region-based CNNs and another one based on quantum neural networks, used biomarkers, histology and computed tomography (CT) images to predict metastasis to the liver or lymph nodes. These models predicted metastasis to liver and lymph nodes with sensitivity of 66.7%, specificity 97.1% and an area under the curve (AUC) of 0.95[53,54]. Four studies developed models predicting survival in GC or stratification of risk of developing GC[55,56]. While 1 model based on SVM achieved higher accuracy than the tumor, nodes, metastasis cancer staging (TNM) system to predict overall survival and disease-free survival[57], another model based on a preoperative ANN was not superior in predicting survival compared to TNM [58]. Zhu *et al*[59] developed a ResNet50-based computer-aided detection and diagnosis (CAD) model to predict GC invasion depth, based on endoscopic images. The model achieved an accuracy of 89.16% in identifying GC invasion depth, compared to 71.49% in endoscopists.

Non-malignant conditions

Currently, diagnosis of *Helicobacter pylori* (*H. pylori*) infection (a known risk factor for the development of peptic ulcer disease and GC) relies on stool or breath testing and histopathology (invasive and expensive). Endoscopic identification of *H. pylori* has been a target for AI-assisted systems[60,61]. For *H. pylori* detection and classification, 4 of 4 studies used a CNN model[62-65]. A study by Martin *et al*[62] using gastric biopsy histopathology images as an input with small number of samples ($n = 210$ in training dataset and 90-106 in 2 test datasets) had diagnostic accuracy of 98.9%-99.1% for detecting current *H. pylori* infection. This result was higher than the accuracy achieved in 2 studies using esophagogastroduodenoscopy images as an input with higher number of samples (98.9%-99.1% *vs* 77.5%-87.7%). The mean accuracy of endoscopists for detecting currently infected *H. pylori* in 2 studies was around 79.0%-79.4%[62]. A study by Shichijo *et al*[64] found that the average *H. pylori* diagnostic time for the AI model was 194 s, while it was 230 ± 65 min for endoscopists. The AI model also had a significantly higher accuracy than the endoscopists by 5.3%, demonstrating that AI algorithms had significantly better accuracy and faster diagnostic time for *H. pylori* than the endoscopists. More recently, Nakashima *et al*[63] developed a CAD system based on linked color imaging combined with DL, which achieved 82.5% accuracy, demonstrating comparable diagnostic accuracy of *H. pylori* to that of experienced endoscopists.

In the area of gastrointestinal bleeding (GIB), risk stratification is of paramount importance not only to identify high-risk patients and guide clinical decision-making but to also identify areas where relatively scarce resources require allocation. In general, risk-stratification tools examine risk factors that are associated with a condition to predict one or several outcomes (*e.g.*, survival, length of hospitalization, rebleeding rates, need for endoscopic therapy, response to treatment)[66-68]. Regarding upper GIB, studies focused on developing prognostic models that predict rebleeding or the need for endoscopic/surgical therapy[69].

Seven studies examining outcome measures in GIB were included, all of which were developed by reviewing medical record parameters to construct ML algorithms, which were primarily based on ANN[67-73]. Half of the studies had both internal and

external validation cohorts, and patient sample sizes varied from 147 to over 22800. Shung *et al*[69] developed a gradient-boosting ML model that identified patients with upper GIB who met a composite endpoint with superior AUC, sensitivity and specificity to that of the Glasgow-Blatchford (GBS), Rockall and AIMS-65 scores. Seo *et al*[68] developed 4 different ML algorithms in patients with nonvariceal upper GIB that achieved superior AUC for mortality, rebleeding and hypotension than that of the GBS, particularly with the use of the random forest (RF) analytic model. However, for rebleeding prediction, a gradient-boosting model developed by Ayaru *et al*[73] showed a higher accuracy than the VC model in the aforementioned study (88% *vs* 78.5%). Das *et al*[70] developed a predictive ML model in lower GIB and compared it in internal and external validation cohorts to the validated BLEED score. Both internal and external validation cohorts reached accuracies, sensitivities, and specificities that were superior to the BLEED score.

LOWER GASTROINTESTINAL TRACT

Direct endoscopic visualization of the colon continues to be the gold standard for detection and resection of colonic premalignant lesions. In addition, patient- and polyp-specific characteristics have also been identified as predictors of missed colorectal cancer (CRC)[74]. Therefore, quality measures such as cecal intubation time, withdrawal time, bowel preparation quality and adenoma detection rates (ADR) have been instituted to attempt and standardize practice and mitigate the rates of missed CRC[74,75]. Since colonoscopy is an operator-dependent procedure, this may lead to variability in polyp detection rates, polyp characterization and estimation of depth of invasion of malignant lesions between endoscopists. CAD has been studied to address these current shortcomings, as well as to improve ADR and reduce CRC risk and colon cancer-related deaths[76] (Supplementary Table 2).

Detection of premalignant and malignant lesions

Polyp detection during colonoscopy is the cornerstone of CRC prevention. It is estimated that CRC develops in 2%-6% of cases after colonoscopy but before the next scheduled surveillance and, therefore, could represent missed or new postcolonoscopy CRC[74,77]. A large number of research studies have been devoted to identifying factors that play a role in the detection of premalignant lesions during colonoscopy, as well as factors that are associated with missed CRC[77]. An observation that has gained considerable attention is that the presence of experienced endoscopy nurses, fellows or any trained second observer during the procedure itself improves ADR[78, 79]. Therefore, and answering the call for improved polyp detection measures during colonoscopy, AI has become a promising technology serving the role of a more standardized "second observer," appropriately termed "computer-aided detection" (CADe).

Eighteen studies that evaluated polyp detection were included in this review, thirteen of which employed DL models, while five used other ML models. Nearly all the studies were limited to having internal validation only. The training datasets in these studies utilized still images from colonoscopy videos ranging from 176 to more than 8600 images. Seven studies calculated the ADR of the developed model and compared it to that of endoscopists, most of which found that the AI had significantly higher ADR than endoscopists, with a decreased reaction time, while the remaining studies showed equivalent ADR[80-87]. Repici *et al*[82] conducted a multicenter study showing that the ADR was 40.4% in the study's participating endoscopists alone, while it was 54.8% in the group using the CADe-based GI-Genius (®Medtronic, Minneapolis, MN) module. Similarly, Wang *et al*[85] conducted a study that evaluated over 520 colonoscopies, also examining the use of a CADe model, and found that the ADR increased from 20.34% in endoscopists alone to 29.12% in the CADe-assisted group. Other studies explored the accuracy, sensitivity and specificity of polyp-detection AI models, displaying accuracies of up to 96.4%, sensitivity of up to 99.7% and specificity of up to 93.7%[88-98]. Kominami *et al*[93] designed an SVM-based model using real-time images with NBI and magnification enhancement to detect colon polyps, achieving an accuracy, sensitivity, and specificity of 93.2%, 93.0%, and 93.3%, respectively. Three studies addressed subjects in the realm of CRC, specifically detecting malignancy on colonoscopy with chromoendoscopy and NBI enhancement, hematoxylin-eosin histopathology slides, or estimating invasion depth on regular WLI colonoscopy images[99-101]. Ito *et al*[100] developed a DL model based on CNN to detect deeply invasive CRC based on WLI colonoscopy, which utilized over 9900

images from 41 patients to train the model. Furthermore, over 5000 images were used in the testing cohort, achieving an accuracy, sensitivity and specificity in differentiating invasion depth of 81.2%, 67.5%, and 89.0%, respectively. Kudo *et al*[101] developed a model based on EndoBRAIN (®Cybernet Systems Co., Tokyo, Japan) using colonoscopy with chromoendoscopy and NBI enhancement to detect malignant lesions in the colon. The training sample used over 69000 images and achieved accuracies of 98.0% and 96.0% for chromoendoscopy and NBI enhancement, respectively. These diagnostic parameters were higher than those of expert and nonexpert endoscopists.

In an attempt to morphologically classify polyps according to their malignant potential, numerous classification systems have been developed. As an example, the Paris classification classifies polyps according to whether they are pedunculated, sessile, slightly raised, or excavated[102]. These visual characteristics are then used to predict whether the polyp has invasive potential or lymph node involvement and potentially contribute to clinical decision-making, such as determining whether the polyp is resectable endoscopically[103]. Unfortunately, research has shown that interobserver variability with this classification is moderately high, suggesting that this visual classification should not be routinely used in research or practice[104]. In addition, considering that most resected polyps during colonoscopy are diminutive and that histopathologic analysis of resected polyps is costly, optical diagnosis has been proposed in this subset of polyps and termed “optical biopsy”[105]. The concept of optical biopsy has been proposed to support cost-effective strategies in CRC screening such as resecting-and-discarding, as well as diagnosing-and-leaving this subset of polyps[106]. However, the concept of optical biopsy has the same limitations as endoscopic polyp characterization does: relatively high interobserver variability. Hence, computer-aided diagnosis has been proposed as a potential solution to standardization of interpretation of endoscopic images.

Nine studies pertaining to colonic polyp classification or differentiation were included in this review[107-115]. While some studies did not report on validation methods, others had cross-validation, internal, and external methods. Most studies relied on ML-based algorithms to assess colonoscopy with enhancement measures (e.g., magnification, NBI, endocytoscopy), while deep CNN models were used in studies evaluating real-time polyp differentiation. Sánchez-Montes *et al*[114] developed an SVM-based model to predict polyp histologic classification using high-definition WLI from 225 colonoscopies, achieving accuracy, sensitivity, and specificity of 91.1%, 92.3%, and 89.2%, respectively. Additionally, Misawa *et al*[111] evaluated the performance of EndoBRAIN (®Cybernet Systems Co., Tokyo) analyzing endocytoscopic images obtained during colonoscopy to characterize polyps as neoplastic *vs* non-neoplastic with an accuracy, sensitivity, and specificity of 96.9%, 97.6%, and 95.8%, respectively. These findings hold promise in determining screening and surveillance schedules, and in instituting cost-effective strategies such as “resect-and-leave”.

Knowledge on the depth of invasion of early CRC is critical for determining resection modality. Intramucosal and submucosal cancerous lesions can be resected with endoscopic techniques such as endoscopic mucosal resection or endoscopic submucosal dissection[116]. However, lesions that invade the deeper layers have a higher association with lymph node metastasis and, hence, may require a combined surgical and oncologic approach[116,117]. Several features on direct endoscopic visualization have been associated with deep invasion of a lesion, including lesion depression, fold convergence, and significantly irregular, and heterogeneous surface capillary pattern[118]. As with any image-based field, a significant degree of interobserver variability exists in characterizing lesions and determining their depth or invasion, for which CAD represents an attractive option to standardize the approach of estimating lesion invasion depth.

Finally, 6 studies assessed other subjects within the realm of the lower gastrointestinal tract, including developing models that predict outcomes in patients with CRC, models examining quality of colonoscopy performance, and studies estimating cost reductions of the use of AI[119-122]. Of 4 studies examining prediction of outcomes, 2 were based on DL (*i.e.*, CNN-based) models, using a wide numerical range of histopathologic images: from 300 million to 12 million. Skrede *et al*[123] developed a DL model using over 12 million histopathological images to develop a biomarker for automatic prediction of cancer-specific survival, which outperformed existing markers. The authors conclude this strategy can potentially be utilized in the treatment selection process by identifying high-risk groups. Thakkar *et al*[120] recently developed a DL model aimed at automatically quantifying quality metrics during colonoscopy, providing intra-procedural feedback to the performing endoscopist.

Non-malignant conditions

Video capsule endoscopy: Owing to its ease of use and noninvasiveness, video capsule endoscopy (VCE) is the current diagnostic method of choice to assess the small bowel for conditions such as occult GIB and Crohn's disease (CD). However, since it lacks self-locomotion, it relies on the motility of the bowel to advance within the gastrointestinal tract. Therefore, it requires a very large number of images (up to 60000 per examination) to be automatically obtained, rendering the process of interpretation lengthy and tedious[124]. VCE has been an area of focus for AI since its early stages, seeing the initial AI classifying methods such as SVM and multilayer perceptron network[125-127]. With faster processors, increased computational power by improved graphics processing units and evolving CNNs, DL algorithms have become the modality of choice for image analysis in VCE[128,129]. As in the lower gastrointestinal tract, the same principles of CAde and computer-aided diagnosis could be applied to deep balloon-assisted or motorized enteroscopy systems (Supplementary Table 3).

A total of 31 studies pertaining to VCE were identified. Fifteen studies (48%) developed models to assist in detection of active GIB or angioectasia. Four studies used CNN, five used SVM, and the remaining ones used ML-based analytic models. Five studies reported cross-validation methods. All studies reported accuracy ranging from 94% to 98% in identifying GIB and angioectasias, with sensitivity of 92.0%-100% and specificity of 82.9%-99.9%[130-142]. Specifically, Tsuboi *et al*[140] developed a DL model based on CNN for angioectasia detection, which achieved an AUC of 0.998, with a sensitivity and specificity of 98.8% and 98.4%, respectively.

Six studies assessed for the presence of small-intestinal ulcers, of which five used DL models based on CNN and one used SVM[128,134,143-146]. Aoki *et al*[128,143] conducted 2 studies in testing DL models to detect ulcerations, yielding a sensitivity of 88.2%, a specificity of 90.9%, and an AUC of 0.958, respectively. Two more studies evaluated the detection of small-bowel CD by identifying ulcers on VCE[147,148]. Klang *et al*[147] developed a DL model based on CNN that used over 17000 VCE images to identify CD ulcers, achieving an AUC of 0.99. Two studies examined small intestinal polyp detection using NN-based models, both achieving an accuracy of at least 98%, with sensitivity and specificity of up to 95.5% and 98.5%, respectively[149, 150].

Regarding celiac disease (CeD) detection, 4 studies were evaluated, 3 of which used CNN and 1 that used a clinical decision support system[151]. A study by Zhou *et al* [152] reported 100% sensitivity and specificity in detecting CeD using GoogLeNet as classifier. A study by Wimmer *et al*[153] using AlexNet, VGGf net, and VGG-16 net as classifiers obtained an optimal accuracy of 92.5% using VGG-16, although the report did not include sample size. More recently, Wang *et al*[154] developed a DL model using the CNN-based InceptionV3 as well as the SVM-based ResNet50 that was 95.94% accurate, 97.20% sensitive and 95.63% specific in identifying CeD in VCE images.

Hookworm infection represents a significant healthcare issue in the developing world, with an estimated 600 million people harboring this infection[155]. As this helminth typically dwells in the small bowel, it may occasionally be a finding in VCE. Three studies evaluated hookworm detection, of which two used CNN and one used SVM with all using cross-validation[156-158]. Specifically, He *et al*[157] developed a DL model based on deep CNN, which was trained on a large VCE dataset consisting of more than 440000 images. The model outperformed other handcrafted, feature-based methods, reaching an accuracy of 88.5% and a sensitivity of 84.6% in detecting hookworm in the small bowel.

To assess for quality of bowel preparation during VCE Leenhardt *et al*[159] and Noorda *et al*[160] developed a DL models based on CNN. Both models achieved accuracy of over 95%, with sensitivity and specificity of 94.7%-96.18% and 94.0%-94.33%, respectively. Overall, Ding *et al*[131] developed a DL model based on CNN to identify and categorize all small-bowel ulcers, polyps, bleeding, lymphangiectasia, follicular hyperplasia, protruding lesions, diverticula or inflammation using over 100 million VCE images. The model achieved an impressive 99.90% overall sensitivity and 99.88% specificity, whereas gastroenterologists identified lesions with a 74.57% sensitivity in the per-patient analysis and 76.89% sensitivity in the per-lesion analysis. Furthermore, the reading time per patient was 5.9 min by the CNN model, compared to 96.6 min by conventional reading.

Inflammatory bowel disease: The complex interplay of pathophysiological factors in inflammatory bowel disease (IBD) has led to the realization that differences in patients' biology may confer differences in disease activity and response to therapy- an example of "precision medicine"[161]. Integration of AI algorithms into the IBD realm

brings promise not only in diagnosis or reducing interobserver variability in severity grading but also opens up the possibility of analyzing large databases to identify complex or occult patterns of disease[162-167].

A total of 25 studies pertaining to IBD were included in this review, of which 9 dealt with CD, 6 studied ulcerative colitis (UC,) and 10 investigated both. Five studies aimed to detect CD, UC, or IBD in general from VCE images, endoscopic images, histology, magnetic resonance imaging (MRI) images, and genetics. Most of the studies used cross-validated ML methods, of which SVM was the method of choice; while another study used DL-based CNN. These studies displayed high levels of accuracy in detecting IBD, from 83.3%-90.8% [143,168-171]. Aoki *et al*[143] developed a DL model based on CNN that used more than 10000 VCE images in the validation dataset to detect CD ulcers in the small bowel, achieving an accuracy, sensitivity and specificity of 90.8%, 88.2% and 90.9%, respectively.

Nine studies that addressed predicting disease severity were primarily based on endoscopic imaging; although other studies also used laboratory studies, demographics, histopathology and CT enterography[172-179]. Five studies utilized ML-based analytic models, while the remaining four utilized DL-based models, of which CNNs were the preferred ones. Five studies reported internal validation, and two studies had external validation cohorts; while two studies did not report validation. The size of patient cohorts varied greatly, from 87 to over 3000, with studies reporting up to 40000 images in the validation datasets. Yao *et al*[179] designed a DL model based on CNN to grade the severity of UC using colonoscopy images, which was constructed with over 16000 images from 3000 patients. The reported accuracy, sensitivity, and specificity was 87.6%, 90.2%, and 87.0%, respectively. The authors concluded that these results support the use of AI in UC severity grading, which approximates the scoring of experienced human reviewers. Maeda *et al*[172] designed a ML model with CAD to detect histologic inflammation based on colonoscopy images enhanced with endocytoscopy. The model achieved an accuracy, sensitivity and specificity of 90.0%, 74.0%, and 91.0%, respectively, using over 9900 images from 100 patients in the validation cohort.

To predict therapeutic response in patients with IBD treated with thiopurines or biologics seven studies constructed internally validated ML algorithms, based on RF analytic models. All models achieved an accuracy of 80.0%-89.8% or an AUC of 0.73-0.846 in identifying patients who will respond at 6-8 wk to therapeutic regimens[180-186]. Waljee *et al*[186] designed a model using only demographic and laboratory data from 401 patients to predict response at 8 wk in patients receiving ustekinumab with an AUC of 0.78, potentially laying the foundation to avoid costly therapeutic drug monitoring. Waljee *et al*[184] also constructed a model based on laboratory values and demographics with a validation dataset of over 6100 patients to predict IBD-related hospitalization and outpatient steroid use, achieving an AUC of 0.87, suggesting such AI models could be used to identify patients at risk of an IBD flare and enable precision medicine-based therapeutic approaches (Supplementary Table 4).

A further 2 internally validated ML models using SVM and RF were developed to predict the risk of IBD based on a genomic datasets[187,188]. Isakov *et al*[187] developed a gene prioritization model using 4 combined analytic models (RF, SVM GB, and an elastic net regularized generalized linear model) to identify genes related to IBD, achieving an accuracy of 80.8%. An internally validated natural language processing (NLP) model by Hou *et al*[189] used histopathology reports to identify surveillance *vs* nonsurveillance colonoscopy in patients with IBD, with an accuracy of 80.0%. Lastly, Firouzi *et al*[190] developed an internally validated model based on Waikato Environment for Knowledge Analysis that identified, with an accuracy of up to 89.8%, patients with IBD who required a bone mineral density scan, using electronic health record data.

HEPATOBIILIARY SYSTEM

Liver diseases are broad and complex, ranging from asymptomatic liver chemistry elevation to life-threatening conditions such as acute liver failure or orthotopic liver transplantation (OLT). Hepatology is can be a fertile ground for applying AI in survival models (*e.g.*, model for end-stage liver disease), disease detection models [*e.g.*, early detection of non-alcoholic fatty liver disease (NAFLD)], disease severity models (*e.g.*, alcoholic hepatitis discriminant function), or disease estimation models (*e.g.*, aspartate aminotransferase-to-platelet ratio index), but also for pattern recognition in radiological images, histopathology and even selection of LT candidates[191,192]. A

total of eighty-five studies pertaining to hepatology were examined, out of which twenty assessed prediction of outcome measures, forty-one examined prediction or detection of steatosis, fibrosis or cirrhosis, nine studies examined differentiation of malignant liver neoplasms, six studies explored predictive models for portal hypertension, and eight studies investigated AI models for other purposes.

Nine studies developed models that assisted with detection or classification of hepatobiliary neoplastic lesion, six of which involved DL-based CNN[193-202]. Schmauch *et al*[197] constructed an internally validated CNN-based DL model using ultrasonographic images of the liver to detect and classify focal liver lesions, achieving an overall AUC of 0.891. Six studies constructed models assisting in predicting the presence of portal hypertension complications in patients with all-cause cirrhosis, based on clinical data or radiological images obtained from modalities such as CT scans[203-208]. Dong *et al*[204] constructed an ML-based model on an RF analytic model that used clinical data and predicted the presence of esophageal varices in patients with cirrhosis with an AUC of 0.82, potentially being useful in performing a better triage of patients who actually require an upper endoscopy for variceal screening. Liu *et al*[206] developed an ML model that had a higher diagnostic performance than conventional noninvasive tools (either conventional image-based or serum-based tools) in identifying clinically significant portal hypertension from contrast-enhanced CT or MRI, with an accuracy of 91.1% and 88.9%, respectively.

Forty-two studies developed models addressing detection of steatosis, fibrosis, or cirrhosis based on clinical data, shear-wave elastography, CT or MRI scans, histopathology, or genetics. Of these, 27 studies developed models to detect, quantify, or predict steatosis, fibrosis, or cirrhosis[202,209-234]. Forlano *et al*[215] developed a ML-based model for quantification of steatosis, inflammation, ballooning, and fibrosis using biopsies from patients with NAFLD. The model identified characteristics of NAFLD with intra- and inter-observer agreement from 0.95-0.99, and has a potential use in objective assessment of treatment response in patients with NAFLD. Yasaka *et al*[202] constructed a DCCN model based on over 144000 MRI images from 534 patients to stage hepatic fibrosis, achieving AUCs of 0.84, 0.84, and 0.85 for F4, F3, and F2 fibrosis, respectively. In assessing fibrosis in patients with hepatitis B virus, Wang *et al*[232] created a DL-based CNN model that used ultrasonographic and elastography data from 132 patients to predict fibrosis, with AUCs of 0.97, 0.98 and 0.82 for F4, F3 and F2 fibrosis, respectively. Eight studies developed AI models to establish the diagnosis of fatty liver disease or distinguish between the causes of liver disease[235-242]. In distinguishing NAFLD from non-alcoholic steatohepatitis (NASH), Fialoke *et al*[237] constructed an ML model testing decision tree, linear regression, RF, and extreme gradient boosting (XGB) analytic models, of which the XGB achieved the highest accuracy, AUC, sensitivity, and specificity at 79.7%, 0.876, 77.4%, and 80.8%, respectively. Taylor-Weiner *et al*[239] constructed an ML model that enabled quantitative measurement of liver histology and disease monitoring in NASH, characterizing disease severity, heterogeneity and treatment response in NASH.

Of 20 studies examining outcome predictors, 8 evaluated predictor models in OLT involving donor-recipient matching, recipient survival at determined time frame, graft survival at different time frames, survival predictors, and morbidity predictors[243-250]. Bertsimas *et al*[245] constructed an internally-validated decision tree-based ML model using clinical data that predicted 3-mo waitlist mortality or removal with an AUC of 0.895. Five studies designed models for outcome prediction in patients with hepatocellular carcinoma (HCC), including response to trans-arterial chemoembolization (TACE), recurrence or survival after resection, most of which were based on CNN[251-255]. Saillard *et al*[254] designed an externally-validated model based on a pre-trained CNN based on histology slides from 328 patients that independently predicted survival after HCC resection with a c-index of 0.75. Other studies evaluated outcomes in patients with acetaminophen-related ALF, primary sclerosing cholangitis, predicted the presence of choledocholithiasis, predicted hepatotoxicity of stereotactic body radiation, or mortality in patients with cirrhosis[256-263]. Eaton *et al*[256] constructed a ML model with XGB that accurately predicted hepatic decompensation in patients with primary sclerosing cholangitis with a C-statistic of 0.90.

Other studies focused on developing models for miscellaneous topics such as estimating liver stiffness from MRI, assessing pretransplant cognitive impairment, detecting spectral differences between normal and hepatitis B virus serum samples, classifying seroconversion to HBeAg, predicting hepatotoxicity in early stages of drug development, predicting fibrosis in hepatitis C virus, or AI-assisted liver tumor segmentation[264-272]. Williams *et al*[271] developed a ML model based on a Bayesian network using hepatic safety assays to predict drug-induced liver injury in compounds during drug development, achieving an accuracy, sensitivity, and specificity

of 86.0%, 87.0%, and 85.0%, respectively. An externally-validated ML model based on SVM and radiomics by He *et al*[267] used MRI and clinical data to estimate liver stiffness, achieving an AUC of 0.80, with an accuracy, sensitivity, and specificity of 75.0%, 63.6%, and 82.4%, respectively. Lastly, models addressing prediction of NAFLD or NASH based on clinical or genetic data, as well as models analyzing donor liver texture for steatosis, have also been developed[272-278] (Supplementary Table 5).

PANCREATIC DISEASES

Pancreatic diseases contain areas where AI can be effectively applied. Of primary interest is the use of AI in improving existing disease severity scoring systems or prognostic models in complicated acute pancreatitis (AP) or chronic pancreatitis (CP), based on clinical and radiological data, detection and differentiation of pancreas cystic neoplasms (PCN) with prediction of malignant potential, radiologic early detection of pancreatic ductal adenocarcinoma (PDAC), radiologic differentiation between PDAC and benign pancreatic conditions [*e.g.*, autoimmune pancreatitis (AIP)], and histopathologic interpretation of tissue samples[279-282]. A total of 59 studies pertaining to the pancreas were reviewed. Of these, 20 (34%) addressed prediction of outcomes in patients with pancreatic diseases ranging from AP to neoplasia.

Eleven of these studies examined outcome prediction in AP. All of the studies' ANN models outperformed logistic regression models, Glasgow, and APACHE-II scoring systems in predicting AP severity; while requiring less number of parameters[283-293]. Qiu *et al*[292] compared the performance of SVM, logistic regression analysis, and ANN models to predict multiorgan failure in AP. All 3 models predicted multiorgan failure, with AUC of 0.840, 0.832, and 0.834, respectively, with ANN requiring a lesser number of parameters.

Seven (12%) studies used AI algorithms to construct clinical registries, segment the pancreas based on imaging, or differentiate between certain pancreatic diseases based on cross-sectional imaging or endoscopic ultrasound (EUS)[294-300]. Zhang *et al*[298] constructed a DL station classification model and a segmentation model to reduce the difficulty in EUS interpretation for trainees. The trainee station recognition accuracy improved from 67.2% to 78.4% in the crossover study. Interobserver agreement between endoscopists and deep CNN with Cohen's kappa coefficient was substantial, ranging from 0.826-0.879. The authors conclude that this technology may play a key role in shortening the learning curve of EUS among trainees.

Fifteen studies (25%) addressed prediction of malignancy based on imaging findings, or differentiation of benign from malignant pancreatic conditions[280,301-315]. Marya *et al*[280] developed an EUS-based CNN model that distinguished AIP from normal pancreas with 99% sensitivity and 98% specificity, AIP from CP with 94% sensitivity and 71% specificity, and AIP from PDAC with 90% sensitivity and 93% specificity. Chu *et al*[301] conducted a study utilizing CT radiomics features to differentiate PDAC from normal pancreas tissue. The accuracy of the RF binary classification was 99.2%, with an AUC of 99.9%. All cases of PDAC were correctly identified, with a sensitivity of 100% and specificity of 98.5%.

Eleven studies (19%) evaluated differentiation of PCNs by classifying them into their respective subtypes based on their characteristics on imaging[316-326]. Springer *et al*[324] developed a multimodality ML model that integrated clinical, radiological and genetic/biochemical markers data to determine whether patients with pancreas cyst should undergo surgery, monitoring, or no further surveillance. The model correctly identified serous cystic neoplasms in 65% of the cases with 99% specificity, clearly outperforming the current standard of care of clinical identification in only 18% of cases. The authors conclude that these systems may serve an adjunct role in clinical practice, enabling the clinician to take better-informed clinical decisions[324].

Eight studies addressed PDAC, from developing risk scores for development of PDAC based on urinary biomarkers, predicting clinical performance and response to celiac plexus neurolysis, to prediction of survival time. AI models performed at least as well as the logistic regression models in predicting the selected outcome[327-334].

Six studies directly examined early pancreatic cancer detection in PDAC or PCN by examining the imaging characteristics or identifying high-risk patients on electronic health records based on factors such as family history of pancreatic cancer[335-340]. Roch *et al*[339] developed NLP-based algorithms based on common terminology used by physicians in describing pancreatic cysts and applied them to automatically conduct searches in electronic health records. The algorithm tracked patients with cysts with a 99.9% sensitivity and 98.8% specificity, demonstrating its utility in

capturing patients swiftly and with more ease than manual review. Ozkan *et al*[338] developed a CAD image-processing system using EUS images to diagnose PDAC, taking patient age into consideration. The accuracy of the model was 87.5, with sensitivity and specificity of 83.3% and 93.3%, respectively (Supplementary Table 6).

CURRENT LIMITATIONS AND KNOWLEDGE GAPS

Despite the numerous positive advances in AI, there remain several limitations to current studies and obstacles to overcome for future studies. Most current models are based on labeled data and, hence, interpretation is only as good as the observer who labeled the “gold-standard” data. Current algorithms are specifically fitted for a determined dataset. A sizeable proportion of the AI models applied to the clinical setting are only internally validated. Ideally, models should be externally validated on diverse cohorts to ensure that overfitting does not become an issue. Therefore, this issue could be potentially addressed by the creation of a universal, well-annotated, high-quality dataset, and by creating algorithms with more plasticity. However, creating “universal datasets” creates additional challenges, particularly related to data integrity and privacy. A potential solution to this is the decentralized “federated datasets”, which involves combining multiple datasets stored on their respective servers, addressing these challenges[341]. Specific protocols are required for choosing an analytic model and selecting or developing validation techniques (*e.g.*, external-, internal-, cross-validation) for data fine-tuning or augmentation. Algorithms that yield the best accuracy should be promoted. Calibration has translated into improvements in probability prediction, for which they should be instituted in all models. Most current studies were cohort studies, whereas well-designed randomized controlled trials would be needed to better support conclusions. Some studies utilized custom-built models, which are not explained in detail. Therefore, custom-built algorithms should have their background and processes thoroughly declared. The studies presented numerous different newly developed models, which would require validation to determine whether these can be applied to other datasets. Several studies examine different techniques during an equivalent endoscopic procedure (*e.g.*, endoscopic image processing in NBI, WLI, or chromoendoscopy), which renders comparisons between techniques cumbersome or not possible. Data matrixes should be completely reported[342]. Significant efforts have been devoted to developing guidelines, such as the CONSORT-AI extension, to standardize reporting in trials evaluating performance of the AI. Adherence to current guidelines and flexibility to revise them as technology continues to advance is of paramount importance. The majority of studies use still images and high-definition images, which is not in line with the “real-world experience” of real-time settings, imaging affected by motion artifact or poor image processing from outdated technical equipment.

APPLICATION IN CLINICAL CARE (ARTICLE HIGHLIGHTS)

ML and DL could assist clinicians in the diagnosis of gastrointestinal and liver neoplasms, bleeding, infection, and inflammatory process, and also predict outcome measures in these conditions.

The initial use of ML or DL models might be used in backing up clinicians in establishing diagnoses or determining a treatment plan.

Given its high predictive value, if AI suggestions match the clinician’s reasoning, clinicians could make a decision more confidently. If the answers are discrepant, careful investigation should be undertaken.

In the future, if ML or DL models find a place to be integrated in standard clinical care, to guide in establishing diagnoses, selecting treatment interventions, predicting outcomes, and influencing clinical decision-making. However, future studies are also necessary to explore avenues of how these measures can be better instituted in clinical practice as a whole.

FUTURE DIRECTIONS

As demonstrated by this review, AI applications in clinical gastroenterology and hepatology continue to rapidly expand and evolve at many different levels. For

general clinical care, the recent proliferation in AI applications is likely to enable “precision medicine” on a broader scale. Clinically, it is predicted that invasive diagnostic interventions will generally fall out of favor for some conditions, as better noninvasive ML-based algorithms pave the way for improved clinical prediction models. Some diagnostic interventions, such as VCE interpretation, may see a considerable decrease in human interpretation, minimizing the human role to that of supervision and attestation of findings of the model. AI-assisted technology will prove important in real-time clinical settings (*e.g.*, polyp detection during colonoscopy). Integration of monitoring devices (*e.g.*, smartphones, smart watches) with ML in the management of selected diseases is also predicted to significantly receive more attention the coming years. The creation of a universal, large, high-quality, well-labelled dataset is a necessity, from which algorithms could be developed to better define the epidemiology and risk factors of diseases. Well-harnessed AI assistance should decrease physician workload or at least maximize their productivity by allowing them to shift from menial tasks to faster, more accurate clinical decision-making. ML algorithms based on these datasets can also be used for other quality measures, such as improvement of process efficiency or identifying cost-effective interventions. In terms of data analysis, traditional analytic models (*e.g.*, logistic regression and clinical scoring systems) may be substituted or augmented by ML algorithms to achieve greater capability and accuracy. Developing and maintaining multidisciplinary teams of data scientists, physicians, content subject experts and industry is of paramount importance in the advancement of AI in gastroenterology and hepatology. Finally, educating clinicians and patients in the future paths of AI applications is critical to increase understanding of future value and decrease reluctance in engagement.

CONCLUSION

The latest advances in AI in gastroenterology and hepatology are promising for aspect many fields of clinical care, from detection of neoplastic lesions on endoscopic assessment and improving current survival models to predicting treatment response. The application of AI to large and complex datasets may assist in the identification of new associations between variables, potentially leading to changes in clinical practice. Furthermore, the use of AI-assisted technologies has the potential to dramatically improve the quality of care. Finally, the time for assisted precision medicine is at hand, with the AI being able to tailor a treatment regimen or potentially predict the response to treatment in a specific patient based on extensive amounts of clinical data from large patient datasets. It is important to realize that, while AI currently does not substitute human clinical reasoning, it has a bright future in the betterment of patient care.

ACKNOWLEDGEMENTS

The authors are grateful to for Wang Z, PhD, Zhang HJ, PhD, Sun T, MD, PhD, Hassan Virk H, MD, and Aiumtrakul N, MD assistance with the additional literature search.

REFERENCES

- 1 **Noorbakhsh-Sabet N**, Zand R, Zhang Y, Abedi V. Artificial Intelligence Transforms the Future of Health Care. *Am J Med* 2019; **132**: 795-801 [PMID: 30710543 DOI: 10.1016/j.amjmed.2019.01.017]
- 2 **Calderaro J**, Kather JN. Artificial intelligence-based pathology for gastrointestinal and hepatobiliary cancers. *Gut* 2021; **70**: 1183-1193 [PMID: 33214163 DOI: 10.1136/gutjnl-2020-322880]
- 3 **Le Berre C**, Sandborn WJ, Aridhi S, Devignes MD, Fournier L, Smaïl-Tabbone M, Danese S, Peyrin-Biroulet L. Application of Artificial Intelligence to Gastroenterology and Hepatology. *Gastroenterology* 2020; **158**: 76-94.e2 [PMID: 31593701 DOI: 10.1053/j.gastro.2019.08.058]
- 4 **Kather JN**, Calderaro J. Development of AI-based pathology biomarkers in gastrointestinal and liver cancer. *Nat Rev Gastroenterol Hepatol* 2020; **17**: 591-592 [PMID: 32620817 DOI: 10.1038/s41575-020-0343-3]
- 5 **Hoogenboom SA**, Bagci U, Wallace MB. Artificial intelligence in gastroenterology. The current state of play and the potential. How will it affect our practice and when? *Tech Gastrointest Endosc* 2019; **22**: 42-47 [DOI: 10.1016/j.tgie.2019.150634]

- 6 **Deo RC.** Machine Learning in Medicine. *Circulation* 2015; **132**: 1920-1930 [PMID: 26572668 DOI: 10.1161/CIRCULATIONAHA.115.001593]
- 7 **Wu J,** Chen J, Cai J. Application of Artificial Intelligence in Gastrointestinal Endoscopy. *J Clin Gastroenterol* 2021; **55**: 110-120 [PMID: 32925304 DOI: 10.1097/MCG.0000000000001423]
- 8 **Parasa S,** Wallace M, Bagci U, Antonino M, Berzin T, Byrne M, Celik H, Farahani K, Golding M, Gross S, Jamali V, Mendonca P, Mori Y, Ninh A, Repici A, Rex D, Skrinak K, Thakkar SJ, van Hoof JE, Vargo J, Yu H, Xu Z, Sharma P. Proceedings from the First Global Artificial Intelligence in Gastroenterology and Endoscopy Summit. *Gastrointest Endosc* 2020; **92**: 938-945.e1 [PMID: 32343978 DOI: 10.1016/j.gie.2020.04.044]
- 9 **Mori Y,** Kudo SE, Mohamed HEN, Misawa M, Ogata N, Itoh H, Oda M, Mori K. Artificial intelligence and upper gastrointestinal endoscopy: Current status and future perspective. *Dig Endosc* 2019; **31**: 378-388 [PMID: 30549317 DOI: 10.1111/den.13317]
- 10 **Hashimoto R,** Requa J, Dao T, Ninh A, Tran E, Mai D, Lugo M, El-Hage Chehade N, Chang KJ, Karnes WE, Samarasena JB. Artificial intelligence using convolutional neural networks for real-time detection of early esophageal neoplasia in Barrett's esophagus (with video). *Gastrointest Endosc* 2020; **91**: 1264-1271.e1 [PMID: 31930967 DOI: 10.1016/j.gie.2019.12.049]
- 11 **van der Sommen F,** Zinger S, Curvers WL, Bisschops R, Pech O, Weusten BL, Bergman JJ, de With PH, Schoon EJ. Computer-aided detection of early neoplastic lesions in Barrett's esophagus. *Endoscopy* 2016; **48**: 617-624 [PMID: 27100718 DOI: 10.1055/s-0042-105284]
- 12 **de Groof AJ,** Struyvenberg MR, van der Putten J, van der Sommen F, Fockens KN, Curvers WL, Zinger S, Pouw RE, Coron E, Baldaque-Silva F, Pech O, Weusten B, Meining A, Neuhaus H, Bisschops R, Dent J, Schoon EJ, de With PH, Bergman JJ. Deep-Learning System Detects Neoplasia in Patients With Barrett's Esophagus With Higher Accuracy Than Endoscopists in a Multistep Training and Validation Study With Benchmarking. *Gastroenterology* 2020; **158**: 915-929.e4 [PMID: 31759929 DOI: 10.1053/j.gastro.2019.11.030]
- 13 **de Groof J,** van der Sommen F, van der Putten J, Struyvenberg MR, Zinger S, Curvers WL, Pech O, Meining A, Neuhaus H, Bisschops R, Schoon EJ, de With PH, Bergman JJ. The Argos project: The development of a computer-aided detection system to improve detection of Barrett's neoplasia on white light endoscopy. *United European Gastroenterol J* 2019; **7**: 538-547 [PMID: 31065371 DOI: 10.1177/2050640619837443]
- 14 **Ebigbo A,** Mendel R, Probst A, Manzeneder J, Prinz F, de Souza LA Jr, Papa J, Palm C, Messmann H. Real-time use of artificial intelligence in the evaluation of cancer in Barrett's oesophagus. *Gut* 2020; **69**: 615-616 [PMID: 31541004 DOI: 10.1136/gutjnl-2019-319460]
- 15 **Riaz F,** Ribeiro MD, Pimentel-Nunes P, Coimbra MT. Integral scale histogram local binary patterns for classification of narrow-band gastroenterology images. *Annu Int Conf IEEE Eng Med Biol Soc* 2013; **2013**: 3714-3717 [PMID: 24110537 DOI: 10.1109/EMBC.2013.6610350]
- 16 **Swager AF,** van der Sommen F, Klomp SR, Zinger S, Meijer SL, Schoon EJ, Bergman JJGHM, de With PH, Curvers WL. Computer-aided detection of early Barrett's neoplasia using volumetric laser endomicroscopy. *Gastrointest Endosc* 2017; **86**: 839-846 [PMID: 28322771 DOI: 10.1016/j.gie.2017.03.011]
- 17 **Trindade AJ,** McKinley MJ, Fan C, Leggett CL, Kahn A, Pleskow DK. Endoscopic Surveillance of Barrett's Esophagus Using Volumetric Laser Endomicroscopy With Artificial Intelligence Image Enhancement. *Gastroenterology* 2019; **157**: 303-305 [PMID: 31078625 DOI: 10.1053/j.gastro.2019.04.048]
- 18 **Morita FH,** Bernardo WM, Ide E, Rocha RS, Aquino JC, Minata MK, Yamazaki K, Marques SB, Sakai P, de Moura EG. Narrow band imaging vs lugol chromoendoscopy to diagnose squamous cell carcinoma of the esophagus: a systematic review and meta-analysis. *BMC Cancer* 2017; **17**: 54 [PMID: 28086818 DOI: 10.1186/s12885-016-3011-9]
- 19 **Pannala R,** Krishnan K, Melson J, Parsi MA, Schulman AR, Sullivan S, Trikudanathan G, Trindade AJ, Watson RR, Maple JT, Lichtenstein DR. Artificial intelligence in gastrointestinal endoscopy. *VideoGIE* 2020; **5**: 598-613 [PMID: 33319126 DOI: 10.1016/j.vgie.2020.08.013]
- 20 **Cai SL,** Li B, Tan WM, Niu XJ, Yu HH, Yao LQ, Zhou PH, Yan B, Zhong YS. Using a deep learning system in endoscopy for screening of early esophageal squamous cell carcinoma (with video). *Gastrointest Endosc* 2019; **90**: 745-753.e2 [PMID: 31302091 DOI: 10.1016/j.gie.2019.06.044]
- 21 **Fukuda H,** Ishihara R, Kato Y, Matsunaga T, Nishida T, Yamada T, Ogiyama H, Horie M, Kinoshita K, Tada T. Comparison of performances of artificial intelligence vs expert endoscopists for real-time assisted diagnosis of esophageal squamous cell carcinoma (with video). *Gastrointest Endosc* 2020; **92**: 848-855 [PMID: 32505685 DOI: 10.1016/j.gie.2020.05.043]
- 22 **Guo L,** Xiao X, Wu C, Zeng X, Zhang Y, Du J, Bai S, Xie J, Zhang Z, Li Y, Wang X, Cheung O, Sharma M, Liu J, Hu B. Real-time automated diagnosis of precancerous lesions and early esophageal squamous cell carcinoma using a deep learning model (with videos). *Gastrointest Endosc* 2020; **91**: 41-51 [PMID: 31445040 DOI: 10.1016/j.gie.2019.08.018]
- 23 **Horie Y,** Yoshio T, Aoyama K, Yoshimizu S, Horiuchi Y, Ishiyama A, Hirasawa T, Tsuchida T, Ozawa T, Ishihara S, Kumagai Y, Fujishiro M, Maetani I, Fujisaki J, Tada T. Diagnostic outcomes of esophageal cancer by artificial intelligence using convolutional neural networks. *Gastrointest Endosc* 2019; **89**: 25-32 [PMID: 30120958 DOI: 10.1016/j.gie.2018.07.037]
- 24 **Kumagai Y,** Takubo K, Kawada K, Aoyama K, Endo Y, Ozawa T, Hirasawa T, Yoshio T, Ishihara S, Fujishiro M, Tamaru JI, Mochiki E, Ishida H, Tada T. Diagnosis using deep-learning artificial

- intelligence based on the endocytoscopic observation of the esophagus. *Esophagus* 2019; **16**: 180-187 [PMID: 30547352 DOI: 10.1007/s10388-018-0651-7]
- 25 **Li B**, Cai SL, Tan WM, Li JC, Yalikong A, Feng XS, Yu HH, Lu PX, Feng Z, Yao LQ, Zhou PH, Yan B, Zhong YS. Comparative study on artificial intelligence systems for detecting early esophageal squamous cell carcinoma between narrow-band and white-light imaging. *World J Gastroenterol* 2021; **27**: 281-293 [PMID: 33519142 DOI: 10.3748/wjg.v27.i3.281]
- 26 **Ohmori M**, Ishihara R, Aoyama K, Nakagawa K, Iwagami H, Matsuura N, Shichijo S, Yamamoto K, Nagaike K, Nakahara M, Inoue T, Aoi K, Okada H, Tada T. Endoscopic detection and differentiation of esophageal lesions using a deep neural network. *Gastrointest Endosc* 2020; **91**: 301-309.e1 [PMID: 31585124 DOI: 10.1016/j.gie.2019.09.034]
- 27 **Tan MC**, Bhushan S, Quang T, Schwarz R, Patel KH, Yu X, Li Z, Wang G, Zhang F, Wang X, Xu H, Richards-Kortum RR, Anandasabapathy S. Automated software-assisted diagnosis of esophageal squamous cell neoplasia using high-resolution microendoscopy. *Gastrointest Endosc* 2021; **93**: 831-838.e2 [PMID: 32682812 DOI: 10.1016/j.gie.2020.07.007]
- 28 **Zhao YY**, Xue DX, Wang YL, Zhang R, Sun B, Cai YP, Feng H, Cai Y, Xu JM. Computer-assisted diagnosis of early esophageal squamous cell carcinoma using narrow-band imaging magnifying endoscopy. *Endoscopy* 2019; **51**: 333-341 [PMID: 30469155 DOI: 10.1055/a-0756-8754]
- 29 **Liu G**, Hua J, Wu Z, Meng T, Sun M, Huang P, He X, Sun W, Li X, Chen Y. Automatic classification of esophageal lesions in endoscopic images using a convolutional neural network. *Ann Transl Med* 2020; **8**: 486 [PMID: 32395530 DOI: 10.21037/atm.2020.03.24]
- 30 **Liu DY**, Gan T, Rao NN, Xing YW, Zheng J, Li S, Luo CS, Zhou ZJ, Wan YL. Identification of lesion images from gastrointestinal endoscope based on feature extraction of combinational methods with and without learning process. *Med Image Anal* 2016; **32**: 281-294 [PMID: 27236223 DOI: 10.1016/j.media.2016.04.007]
- 31 **Nakagawa K**, Ishihara R, Aoyama K, Ohmori M, Nakahira H, Matsuura N, Shichijo S, Nishida T, Yamada T, Yamaguchi S, Ogiyama H, Egawa S, Kishida O, Tada T. Classification for invasion depth of esophageal squamous cell carcinoma using a deep neural network compared with experienced endoscopists. *Gastrointest Endosc* 2019; **90**: 407-414 [PMID: 31077698 DOI: 10.1016/j.gie.2019.04.245]
- 32 **Shimamoto Y**, Ishihara R, Kato Y, Shoji A, Inoue T, Matsueda K, Miyake M, Waki K, Kono M, Fukuda H, Matsuura N, Nagaike K, Aoi K, Yamamoto K, Nakahara M, Nishihara A, Tada T. Real-time assessment of video images for esophageal squamous cell carcinoma invasion depth using artificial intelligence. *J Gastroenterol* 2020; **55**: 1037-1045 [PMID: 32778959 DOI: 10.1007/s00535-020-01716-5]
- 33 **Pimentel-Nunes P**, Libânio D, Lage J, Abrantes D, Coimbra M, Esposito G, Hormozdi D, Pepper M, Drasovean S, White JR, Dobru D, Buxbaum J, Raguath K, Annibale B, Dinis-Ribeiro M. A multicenter prospective study of the real-time use of narrow-band imaging in the diagnosis of premalignant gastric conditions and lesions. *Endoscopy* 2016; **48**: 723-730 [PMID: 27280384 DOI: 10.1055/s-0042-108435]
- 34 **White JR**, Sami SS, Reddiar D, Mannath J, Ortiz-Fernández-Sordo J, Beg S, Scott R, Thiagarajan P, Ahmad S, Parra-Blanco A, Kasi M, Telakis E, Sultan AA, Davis J, Figgins A, Kaye P, Robinson K, Atherton JC, Raguath K. Narrow band imaging and serology in the assessment of premalignant gastric pathology. *Scand J Gastroenterol* 2018; **53**: 1611-1618 [PMID: 30600732 DOI: 10.1080/00365521.2018.1542455]
- 35 **Kimura-Tsuchiya R**, Dohi O, Fujita Y, Yagi N, Majima A, Horii Y, Kitaichi T, Onozawa Y, Suzuki K, Tomie A, Okayama T, Yoshida N, Kamada K, Katada K, Uchiyama K, Ishikawa T, Takagi T, Handa O, Konishi H, Kishimoto M, Naito Y, Yanagisawa A, Itoh Y. Magnifying Endoscopy with Blue Laser Imaging Improves the Microstructure Visualization in Early Gastric Cancer: Comparison of Magnifying Endoscopy with Narrow-Band Imaging. *Gastroenterol Res Pract* 2017; **2017**: 8303046 [PMID: 28947900 DOI: 10.1155/2017/8303046]
- 36 **Mouri R**, Yoshida S, Tanaka S, Oka S, Yoshihara M, Chayama K. Evaluation and validation of computed virtual chromoendoscopy in early gastric cancer. *Gastrointest Endosc* 2009; **69**: 1052-1058 [PMID: 19152892 DOI: 10.1016/j.gie.2008.08.032]
- 37 **Guimarães P**, Keller A, Fehlmann T, Lammert F, Casper M. Deep-learning based detection of gastric precancerous conditions. *Gut* 2020; **69**: 4-6 [PMID: 31375599 DOI: 10.1136/gutjnl-2019-319347]
- 38 **Hirasawa T**, Aoyama K, Tanimoto T, Ishihara S, Shichijo S, Ozawa T, Ohnishi T, Fujishiro M, Matsuo K, Fujisaki J, Tada T. Application of artificial intelligence using a convolutional neural network for detecting gastric cancer in endoscopic images. *Gastric Cancer* 2018; **21**: 653-660 [PMID: 29335825 DOI: 10.1007/s10120-018-0793-2]
- 39 **Ishioka M**, Hirasawa T, Tada T. Detecting gastric cancer from video images using convolutional neural networks. *Dig Endosc* 2019; **31**: e34-e35 [PMID: 30449050 DOI: 10.1111/den.13306]
- 40 **Korhani Kangi A**, Bahrampour A. Predicting the Survival of Gastric Cancer Patients Using Artificial and Bayesian Neural Networks. *Asian Pac J Cancer Prev* 2018; **19**: 487-490 [PMID: 29480983 DOI: 10.22034/APJCP.2018.19.2.487]
- 41 **Li L**, Chen Y, Shen Z, Zhang X, Sang J, Ding Y, Yang X, Li J, Chen M, Jin C, Chen C, Yu C. Convolutional neural network for the diagnosis of early gastric cancer based on magnifying narrow band imaging. *Gastric Cancer* 2020; **23**: 126-132 [PMID: 31332619 DOI: 10.1007/s10120-019-00992-2]

- 42 **Miyaki R**, Yoshida S, Tanaka S, Kominami Y, Sanomura Y, Matsuo T, Oka S, Raytchev B, Tamaki T, Koide T, Kaneda K, Yoshihara M, Chayama K. A computer system to be used with laser-based endoscopy for quantitative diagnosis of early gastric cancer. *J Clin Gastroenterol* 2015; **49**: 108-115 [PMID: 24583752 DOI: 10.1097/MCG.000000000000104]
- 43 **Togo R**, Yamamichi N, Mabe K, Takahashi Y, Takeuchi C, Kato M, Sakamoto N, Ishihara K, Ogawa T, Haseyama M. Detection of gastritis by a deep convolutional neural network from double-contrast upper gastrointestinal barium X-ray radiography. *J Gastroenterol* 2019; **54**: 321-329 [PMID: 30284046 DOI: 10.1007/s00535-018-1514-7]
- 44 **Wang S**, Zhu Y, Yu L, Chen H, Lin H, Wan X, Fan X, Heng PA. RMDL: Recalibrated multi-instance deep learning for whole slide gastric image classification. *Med Image Anal* 2019; **58**: 101549 [PMID: 31499320 DOI: 10.1016/j.media.2019.101549]
- 45 **Luo H**, Xu G, Li C, He L, Luo L, Wang Z, Jing B, Deng Y, Jin Y, Li B, Tan W, He C, Seeruttun SR, Wu Q, Huang J, Huang DW, Chen B, Lin SB, Chen QM, Yuan CM, Chen HX, Pu HY, Zhou F, He Y, Xu RH. Real-time artificial intelligence for detection of upper gastrointestinal cancer by endoscopy: a multicentre, case-control, diagnostic study. *Lancet Oncol* 2019; **20**: 1645-1654 [PMID: 31591062 DOI: 10.1016/S1470-2045(19)30637-0]
- 46 **Namikawa K**, Hirasawa T, Nakano K, Ikenoyama Y, Ishioka M, Shiroma S, Tokai Y, Yoshimizu S, Horiuchi Y, Ishiyama A, Yoshio T, Tsuchida T, Fujisaki J, Tada T. Artificial intelligence-based diagnostic system classifying gastric cancers and ulcers: comparison between the original and newly developed systems. *Endoscopy* 2020; **52**: 1077-1083 [PMID: 32503056 DOI: 10.1055/a-1194-8771]
- 47 **Ueyama H**, Kato Y, Akazawa Y, Yatagai N, Komori H, Takeda T, Matsumoto K, Ueda K, Hojo M, Yao T, Nagahara A, Tada T. Application of artificial intelligence using a convolutional neural network for diagnosis of early gastric cancer based on magnifying endoscopy with narrow-band imaging. *J Gastroenterol Hepatol* 2021; **36**: 482-489 [PMID: 32681536 DOI: 10.1111/jgh.15190]
- 48 **Zhou C**, Hu J, Wang Y, Ji MH, Tong J, Yang JJ, Xia H. A machine learning-based predictor for the identification of the recurrence of patients with gastric cancer after operation. *Sci Rep* 2021; **11**: 1571 [PMID: 33452440 DOI: 10.1038/s41598-021-81188-6]
- 49 **Zhang Y**, Li F, Yuan F, Zhang K, Huo L, Dong Z, Lang Y, Zhang Y, Wang M, Gao Z, Qin Z, Shen L. Diagnosing chronic atrophic gastritis by gastroscopy using artificial intelligence. *Dig Liver Dis* 2020; **52**: 566-572 [PMID: 32061504 DOI: 10.1016/j.dld.2019.12.146]
- 50 **Kanesaka T**, Lee TC, Uedo N, Lin KP, Chen HZ, Lee JY, Wang HP, Chang HT. Computer-aided diagnosis for identifying and delineating early gastric cancers in magnifying narrow-band imaging. *Gastrointest Endosc* 2018; **87**: 1339-1344 [PMID: 29225083 DOI: 10.1016/j.gie.2017.11.029]
- 51 **Sakai Y**, Takemoto S, Hori K, Nishimura M, Ikematsu H, Yano T, Yokota H. Automatic detection of early gastric cancer in endoscopic images using a transferring convolutional neural network. *Annu Int Conf IEEE Eng Med Biol Soc* 2018; **2018**: 4138-4141 [PMID: 30441266 DOI: 10.1109/EMBC.2018.8513274]
- 52 **Wu L**, Zhou W, Wan X, Zhang J, Shen L, Hu S, Ding Q, Mu G, Yin A, Huang X, Liu J, Jiang X, Wang Z, Deng Y, Liu M, Lin R, Ling T, Li P, Wu Q, Jin P, Chen J, Yu H. A deep neural network improves endoscopic detection of early gastric cancer without blind spots. *Endoscopy* 2019; **51**: 522-531 [PMID: 30861533 DOI: 10.1055/a-0855-3532]
- 53 **Gao Y**, Zhang ZD, Li S, Guo YT, Wu QY, Liu SH, Yang SJ, Ding L, Zhao BC, Lu Y. Deep neural network-assisted computed tomography diagnosis of metastatic lymph nodes from gastric cancer. *Chin Med J (Engl)* 2019; **132**: 2804-2811 [PMID: 31856051 DOI: 10.1097/CM9.0000000000000532]
- 54 **Jagic T**, Potrc S, Jagic T. Prediction of liver metastases after gastric cancer resection with the use of learning vector quantization neural networks. *Dig Dis Sci* 2010; **55**: 3252-3261 [PMID: 20186483 DOI: 10.1007/s10620-010-1155-z]
- 55 **Chen T**, Zhang C, Liu Y, Zhao Y, Lin D, Hu Y, Yu J, Li G. A gastric cancer LncRNAs model for MSI and survival prediction based on support vector machine. *BMC Genomics* 2019; **20**: 846 [PMID: 31722674 DOI: 10.1186/s12864-019-6135-x]
- 56 **Nakahira H**, Ishihara R, Aoyama K, Kono M, Fukuda H, Shimamoto Y, Nakagawa K, Ohmori M, Iwatsubo T, Iwagami H, Matsuno K, Inoue S, Matsuura N, Shichijo S, Maekawa A, Kanesaka T, Yamamoto S, Takeuchi Y, Higashino K, Uedo N, Matsunaga T, Tada T. Stratification of gastric cancer risk using a deep neural network. *JGH Open* 2020; **4**: 466-471 [PMID: 32514455 DOI: 10.1002/jgh3.12281]
- 57 **Jiang Y**, Xie J, Han Z, Liu W, Xi S, Huang L, Huang W, Lin T, Zhao L, Hu Y, Yu J, Zhang Q, Li T, Cai S, Li G. Immunomarker Support Vector Machine Classifier for Prediction of Gastric Cancer Survival and Adjuvant Chemotherapeutic Benefit. *Clin Cancer Res* 2018; **24**: 5574-5584 [PMID: 30042208 DOI: 10.1158/1078-0432.CCR-18-0848]
- 58 **Que SJ**, Chen QY, Qing-Zhong, Liu ZY, Wang JB, Lin JX, Lu J, Cao LL, Lin M, Tu RH, Huang ZN, Lin JL, Zheng HL, Li P, Zheng CH, Huang CM, Xie JW. Application of preoperative artificial neural network based on blood biomarkers and clinicopathological parameters for predicting long-term survival of patients with gastric cancer. *World J Gastroenterol* 2019; **25**: 6451-6464 [PMID: 31798281 DOI: 10.3748/wjg.v25.i43.6451]
- 59 **Zhu Y**, Wang QC, Xu MD, Zhang Z, Cheng J, Zhong YS, Zhang YQ, Chen WF, Yao LQ, Zhou PH, Li QL. Application of convolutional neural network in the diagnosis of the invasion depth of gastric cancer based on conventional endoscopy. *Gastrointest Endosc* 2019; **89**: 806-815.e1 [PMID: 30452913 DOI: 10.1016/j.gie.2018.11.011]

- 60 **Nakashima H**, Kawahira H, Kawachi H, Sakaki N. Artificial intelligence diagnosis of *Helicobacter pylori* infection using blue laser imaging-bright and linked color imaging: a single-center prospective study. *Ann Gastroenterol* 2018; **31**: 462-468 [PMID: 29991891 DOI: 10.20524/aog.2018.0269]
- 61 **Shichijo S**, Endo Y, Aoyama K, Takeuchi Y, Ozawa T, Takiyama H, Matsuo K, Fujishiro M, Ishihara S, Ishihara R, Tada T. Application of convolutional neural networks for evaluating *Helicobacter pylori* infection status on the basis of endoscopic images. *Scand J Gastroenterol* 2019; **54**: 158-163 [PMID: 30879352 DOI: 10.1080/00365521.2019.1577486]
- 62 **Martin DR**, Hanson JA, Gullapalli RR, Schultz FA, Sethi A, Clark DP. A Deep Learning Convolutional Neural Network Can Recognize Common Patterns of Injury in Gastric Pathology. *Arch Pathol Lab Med* 2020; **144**: 370-378 [PMID: 31246112 DOI: 10.5858/arpa.2019-0004-OA]
- 63 **Nakashima H**, Kawahira H, Kawachi H, Sakaki N. Endoscopic three-categorical diagnosis of *Helicobacter pylori* infection using linked color imaging and deep learning: a single-center prospective study (with video). *Gastric Cancer* 2020; **23**: 1033-1040 [PMID: 32382973 DOI: 10.1007/s10120-020-01077-1]
- 64 **Shichijo S**, Nomura S, Aoyama K, Nishikawa Y, Miura M, Shinagawa T, Takiyama H, Tanimoto T, Ishihara S, Matsuo K, Tada T. Application of Convolutional Neural Networks in the Diagnosis of *Helicobacter pylori* Infection Based on Endoscopic Images. *EBioMedicine* 2017; **25**: 106-111 [PMID: 29056541 DOI: 10.1016/j.ebiom.2017.10.014]
- 65 **Zheng W**, Zhang X, Kim JJ, Zhu X, Ye G, Ye B, Wang J, Luo S, Li J, Yu T, Liu J, Hu W, Si J. High Accuracy of Convolutional Neural Network for Evaluation of *Helicobacter pylori* Infection Based on Endoscopic Images: Preliminary Experience. *Clin Transl Gastroenterol* 2019; **10**: e00109 [PMID: 31833862 DOI: 10.14309/ctg.000000000000109]
- 66 **Yang YJ**, Bang CS. Application of artificial intelligence in gastroenterology. *World J Gastroenterol* 2019; **25**: 1666-1683 [PMID: 31011253 DOI: 10.3748/wjg.v25.i14.1666]
- 67 **Wong GL**, Ma AJ, Deng H, Ching JY, Wong VW, Tse YK, Yip TC, Lau LH, Liu HH, Leung CM, Tsang SW, Chan CW, Lau JY, Yuen PC, Chan FK. Machine learning model to predict recurrent ulcer bleeding in patients with history of idiopathic gastroduodenal ulcer bleeding. *Aliment Pharmacol Ther* 2019; **49**: 912-918 [PMID: 30761584 DOI: 10.1111/apt.15145]
- 68 **Seo DW**, Yi H, Park B, Kim YJ, Jung DH, Woo I, Sohn CH, Ko BS, Kim N, Kim WY. Prediction of Adverse Events in Stable Non-Variceal Gastrointestinal Bleeding Using Machine Learning. *J Clin Med* 2020; **9** [PMID: 32796647 DOI: 10.3390/jcm9082603]
- 69 **Shung DL**, Au B, Taylor RA, Tay JK, Laursen SB, Stanley AJ, Dalton HR, Ngu J, Schultz M, Laine L. Validation of a Machine Learning Model That Outperforms Clinical Risk Scoring Systems for Upper Gastrointestinal Bleeding. *Gastroenterology* 2020; **158**: 160-167 [PMID: 31562847 DOI: 10.1053/j.gastro.2019.09.009]
- 70 **Das A**, Ben-Menachem T, Cooper GS, Chak A, Sivak MV Jr, Gonet JA, Wong RC. Prediction of outcome in acute lower-gastrointestinal haemorrhage based on an artificial neural network: internal and external validation of a predictive model. *Lancet* 2003; **362**: 1261-1266 [PMID: 14575969 DOI: 10.1016/S0140-6736(03)14568-0]
- 71 **Das A**, Ben-Menachem T, Farooq FT, Cooper GS, Chak A, Sivak MV Jr, Wong RC. Artificial neural network as a predictive instrument in patients with acute nonvariceal upper gastrointestinal hemorrhage. *Gastroenterology* 2008; **134**: 65-74 [PMID: 18061180 DOI: 10.1053/j.gastro.2007.10.037]
- 72 **Loftus TJ**, Brakenridge SC, Croft CA, Smith RS, Efron PA, Moore FA, Mohr AM, Jordan JR. Neural network prediction of severe lower intestinal bleeding and the need for surgical intervention. *J Surg Res* 2017; **212**: 42-47 [PMID: 28550920 DOI: 10.1016/j.jss.2016.12.032]
- 73 **Ayaru L**, Ypsilantis PP, Nanapragasam A, Choi RC, Thillanathan A, Min-Ho L, Montana G. Prediction of Outcome in Acute Lower Gastrointestinal Bleeding Using Gradient Boosting. *PLoS One* 2015; **10**: e0132485 [PMID: 26172121 DOI: 10.1371/journal.pone.0132485]
- 74 **Bressler B**, Paszat LF, Chen Z, Rothwell DM, Vinden C, Rabeneck L. Rates of new or missed colorectal cancers after colonoscopy and their risk factors: a population-based analysis. *Gastroenterology* 2007; **132**: 96-102 [PMID: 17241863 DOI: 10.1053/j.gastro.2006.10.027]
- 75 **Jover R**, Zapater P, Polanía E, Bujanda L, Lanás A, Hermo JA, Cubiella J, Ono A, González-Méndez Y, Peris A, Pellisé M, Seoane A, Herreros-de-Tejada A, Ponce M, Marín-Gabriel JC, Chaparro M, Cacho G, Fernández-Díez S, Arenas J, Sopena F, de-Castro L, Vega-Villaamil P, Rodríguez-Soler M, Carballo F, Salas D, Morillas JD, Andreu M, Quintero E, Castells A; COLONPREV study investigators. Modifiable endoscopic factors that influence the adenoma detection rate in colorectal cancer screening colonoscopies. *Gastrointest Endosc* 2013; **77**: 381-389.e1 [PMID: 23218945 DOI: 10.1016/j.gie.2012.09.027]
- 76 **Hassan C**, Spadaccini M, Iannone A, Maselli R, Jovani M, Chandrasekar VT, Antonelli G, Yu H, Areia M, Dinis-Ribeiro M, Bhandari P, Sharma P, Rex DK, Rösch T, Wallace M, Repici A. Performance of artificial intelligence in colonoscopy for adenoma and polyp detection: a systematic review and meta-analysis. *Gastrointest Endosc* 2021; **93**: 77-85.e6 [PMID: 32598963 DOI: 10.1016/j.gie.2020.06.059]
- 77 **Samadder NJ**, Curtin K, Tuohy TM, Pappas L, Boucher K, Provenzale D, Rowe KG, Mineau GP, Smith K, Pimentel R, Kirchoff AC, Burt RW. Characteristics of missed or interval colorectal cancer and patient survival: a population-based study. *Gastroenterology* 2014; **146**: 950-960 [PMID: 24417818 DOI: 10.1053/j.gastro.2014.01.013]
- 78 **Lee CK**, Park DI, Lee SH, Hwangbo Y, Eun CS, Han DS, Cha JM, Lee BI, Shin JE. Participation by

- experienced endoscopy nurses increases the detection rate of colon polyps during a screening colonoscopy: a multicenter, prospective, randomized study. *Gastrointest Endosc* 2011; **74**: 1094-1102 [PMID: 21889137 DOI: 10.1016/j.gie.2011.06.033]
- 79 **Aslanian HR**, Shieh FK, Chan FW, Ciarleglio MM, Deng Y, Rogart JN, Jamidar PA, Siddiqui UD. Nurse observation during colonoscopy increases polyp detection: a randomized prospective study. *Am J Gastroenterol* 2013; **108**: 166-172 [PMID: 23381064 DOI: 10.1038/ajg.2012.237]
- 80 **Gong D**, Wu L, Zhang J, Mu G, Shen L, Liu J, Wang Z, Zhou W, An P, Huang X, Jiang X, Li Y, Wan X, Hu S, Chen Y, Hu X, Xu Y, Zhu X, Li S, Yao L, He X, Chen D, Huang L, Wei X, Wang X, Yu H. Detection of colorectal adenomas with a real-time computer-aided system (ENDOANGEL): a randomised controlled study. *Lancet Gastroenterol Hepatol* 2020; **5**: 352-361 [PMID: 31981518 DOI: 10.1016/S2468-1253(19)30413-3]
- 81 **Klare P**, Sander C, Prinzen M, Haller B, Nowack S, Abdelhafez M, Poszler A, Brown H, Wilhelm D, Schmid RM, von Delius S, Wittenberg T. Automated polyp detection in the colorectum: a prospective study (with videos). *Gastrointest Endosc* 2019; **89**: 576-582.e1 [PMID: 30342029 DOI: 10.1016/j.gie.2018.09.042]
- 82 **Repici A**, Badalamenti M, Maselli R, Correale L, Radaelli F, Rondonotti E, Ferrara E, Spadaccini M, Alkandari A, Fugazza A, Anderloni A, Galtieri PA, Pellegatta G, Carrara S, Di Leo M, Craviotto V, Lamona L, Lorenzetti R, Andrealli A, Antonelli G, Wallace M, Sharma P, Rosch T, Hassan C. Efficacy of Real-Time Computer-Aided Detection of Colorectal Neoplasia in a Randomized Trial. *Gastroenterology* 2020; **159**: 512-520.e7 [PMID: 32371116 DOI: 10.1053/j.gastro.2020.04.062]
- 83 **Su JR**, Li Z, Shao XJ, Ji CR, Ji R, Zhou RC, Li GC, Liu GQ, He YS, Zuo XL, Li YQ. Impact of a real-time automatic quality control system on colorectal polyp and adenoma detection: a prospective randomized controlled study (with videos). *Gastrointest Endosc* 2020; **91**: 415-424.e4 [PMID: 31454493 DOI: 10.1016/j.gie.2019.08.026]
- 84 **Urban G**, Tripathi P, Alkayali T, Mittal M, Jalali F, Karnes W, Baldi P. Deep Learning Localizes and Identifies Polyps in Real Time With 96% Accuracy in Screening Colonoscopy. *Gastroenterology* 2018; **155**: 1069-1078.e8 [PMID: 29928897 DOI: 10.1053/j.gastro.2018.06.037]
- 85 **Wang P**, Berzin TM, Glissen Brown JR, Bharadwaj S, Becq A, Xiao X, Liu P, Li L, Song Y, Zhang D, Li Y, Xu G, Tu M, Liu X. Real-time automatic detection system increases colonoscopic polyp and adenoma detection rates: a prospective randomised controlled study. *Gut* 2019; **68**: 1813-1819 [PMID: 30814121 DOI: 10.1136/gutjnl-2018-317500]
- 86 **Wang P**, Liu X, Berzin TM, Glissen Brown JR, Liu P, Zhou C, Lei L, Li L, Guo Z, Lei S, Xiong F, Wang H, Song Y, Pan Y, Zhou G. Effect of a deep-learning computer-aided detection system on adenoma detection during colonoscopy (CADE-DB trial): a double-blind randomised study. *Lancet Gastroenterol Hepatol* 2020; **5**: 343-351 [PMID: 31981517 DOI: 10.1016/S2468-1253(19)30411-X]
- 87 **Liu WN**, Zhang YY, Bian XQ, Wang LJ, Yang Q, Zhang XD, Huang J. Study on detection rate of polyps and adenomas in artificial-intelligence-aided colonoscopy. *Saudi J Gastroenterol* 2020; **26**: 13-19 [PMID: 31898644 DOI: 10.4103/sjg.SJG_377_19]
- 88 **Bernal J**, Tajbaksh N, Sanchez FJ, Matuszewski BJ, Hao Chen, Lequan Yu, Angermann Q, Romain O, Rustad B, Balasingham I, Pogorelov K, Sungbin Choi, Debarq Q, Maier-Hein L, Speidel S, Stoyanov D, Brandao P, Cordova H, Sanchez-Montes C, Gurudu SR, Fernandez-Esparrach G, Dray X, Jianming Liang, Histace A. Comparative Validation of Polyp Detection Methods in Video Colonoscopy: Results From the MICCAI 2015 Endoscopic Vision Challenge. *IEEE Trans Med Imaging* 2017; **36**: 1231-1249 [PMID: 28182555 DOI: 10.1109/TMI.2017.2664042]
- 89 **Blanes-Vidal V**, Baatrup G, Nadimi ES. Addressing priority challenges in the detection and assessment of colorectal polyps from capsule endoscopy and colonoscopy in colorectal cancer screening using machine learning. *Acta Oncol* 2019; **58**: S29-S36 [PMID: 30836800 DOI: 10.1080/0284186X.2019.1584404]
- 90 **Fernández-Esparrach G**, Bernal J, López-Cerón M, Córdova H, Sánchez-Montes C, Rodríguez de Miguel C, Sánchez FJ. Exploring the clinical potential of an automatic colonic polyp detection method based on the creation of energy maps. *Endoscopy* 2016; **48**: 837-842 [PMID: 27285900 DOI: 10.1055/s-0042-108434]
- 91 **Figueiredo PN**, Figueiredo IN, Pinto L, Kumar S, Tsai YR, Mamonov AV. Polyp detection with computer-aided diagnosis in white light colonoscopy: comparison of three different methods. *Endosc Int Open* 2019; **7**: E209-E215 [PMID: 30705955 DOI: 10.1055/a-0808-4456]
- 92 **Hassan C**, Wallace MB, Sharma P, Maselli R, Craviotto V, Spadaccini M, Repici A. New artificial intelligence system: first validation study vs experienced endoscopists for colorectal polyp detection. *Gut* 2020; **69**: 799-800 [PMID: 31615835 DOI: 10.1136/gutjnl-2019-319914]
- 93 **Kominami Y**, Yoshida S, Tanaka S, Sanomura Y, Hirakawa T, Raytchev B, Tamaki T, Koide T, Kaneda K, Chayama K. Computer-aided diagnosis of colorectal polyp histology by using a real-time image recognition system and narrow-band imaging magnifying colonoscopy. *Gastrointest Endosc* 2016; **83**: 643-649 [PMID: 26264431 DOI: 10.1016/j.gie.2015.08.004]
- 94 **Lequan Yu**, Hao Chen, Qi Dou, Jing Qin, Pheng Ann Heng. Integrating Online and Offline Three-Dimensional Deep Learning for Automated Polyp Detection in Colonoscopy Videos. *IEEE J Biomed Health Inform* 2017; **21**: 65-75 [PMID: 28114049 DOI: 10.1109/JBHI.2016.2637004]
- 95 **Misawa M**, Kudo SE, Mori Y, Cho T, Kataoka S, Yamauchi A, Ogawa Y, Maeda Y, Takeda K, Ichimasa K, Nakamura H, Yagawa Y, Toyoshima N, Ogata N, Kudo T, Hisayuki T, Hayashi T, Wakamura K, Baba T, Ishida F, Itoh H, Roth H, Oda M, Mori K. Artificial Intelligence-Assisted Polyp Detection for Colonoscopy: Initial Experience. *Gastroenterology* 2018; **154**: 2027-2029.e3

- [PMID: 29653147 DOI: 10.1053/j.gastro.2018.04.003]
- 96 **Misawa M**, Kudo SE, Mori Y, Hotta K, Ohtsuka K, Matsuda T, Saito S, Kudo T, Baba T, Ishida F, Itoh H, Oda M, Mori K. Development of a computer-aided detection system for colonoscopy and a publicly accessible large colonoscopy video database (with video). *Gastrointest Endosc* 2021; **93**: 960-967.e3 [PMID: 32745531 DOI: 10.1016/j.gie.2020.07.060]
- 97 **Mori Y**, Kudo SE, Misawa M, Saito Y, Ikematsu H, Hotta K, Ohtsuka K, Urushibara F, Kataoka S, Ogawa Y, Maeda Y, Takeda K, Nakamura H, Ichimasa K, Kudo T, Hayashi T, Wakamura K, Ishida F, Inoue H, Itoh H, Oda M, Mori K. Real-Time Use of Artificial Intelligence in Identification of Diminutive Polyps During Colonoscopy: A Prospective Study. *Ann Intern Med* 2018; **169**: 357-366 [PMID: 30105375 DOI: 10.7326/M18-0249]
- 98 **Wang P**, Xiao X, Glissen Brown JR, Berzin TM, Tu M, Xiong F, Hu X, Liu P, Song Y, Zhang D, Yang X, Li L, He J, Yi X, Liu J, Liu X. Development and validation of a deep-learning algorithm for the detection of polyps during colonoscopy. *Nat Biomed Eng* 2018; **2**: 741-748 [PMID: 31015647 DOI: 10.1038/s41551-018-0301-3]
- 99 **Echle A**, Grabsch HI, Quirke P, van den Brandt PA, West NP, Hutchins GGA, Heij LR, Tan X, Richman SD, Krause J, Alwers E, Jenniskens J, Offermans K, Gray R, Brenner H, Chang-Claude J, Trautwein C, Pearson AT, Boor P, Luedde T, Gaisa NT, Hoffmeister M, Kather JN. Clinical-Grade Detection of Microsatellite Instability in Colorectal Tumors by Deep Learning. *Gastroenterology* 2020; **159**: 1406-1416.e11 [PMID: 32562722 DOI: 10.1053/j.gastro.2020.06.021]
- 100 **Ito N**, Kawahira H, Nakashima H, Uesato M, Miyauchi H, Matsubara H. Endoscopic Diagnostic Support System for cT1b Colorectal Cancer Using Deep Learning. *Oncology* 2019; **96**: 44-50 [PMID: 30130758 DOI: 10.1159/000491636]
- 101 **Kudo SE**, Misawa M, Mori Y, Hotta K, Ohtsuka K, Ikematsu H, Saito Y, Takeda K, Nakamura H, Ichimasa K, Ishigaki T, Toyoshima N, Kudo T, Hayashi T, Wakamura K, Baba T, Ishida F, Inoue H, Itoh H, Oda M, Mori K. Artificial Intelligence-assisted System Improves Endoscopic Identification of Colorectal Neoplasms. *Clin Gastroenterol Hepatol* 2020; **18**: 1874-1881.e2 [PMID: 31525512 DOI: 10.1016/j.cgh.2019.09.009]
- 102 . The Paris endoscopic classification of superficial neoplastic lesions: esophagus, stomach, and colon: November 30 to December 1, 2002. *Gastrointest Endosc* 2003; **58**: S3-43 [PMID: 14652541 DOI: 10.1016/s0016-5107(03)02159-x]
- 103 **Endoscopic Classification Review Group**. Update on the paris classification of superficial neoplastic lesions in the digestive tract. *Endoscopy* 2005; **37**: 570-578 [PMID: 15933932 DOI: 10.1055/s-2005-861352]
- 104 **van Doorn SC**, Hazewinkel Y, East JE, van Leerdam ME, Rastogi A, Pellisé M, Sanduleanu-Dascalescu S, Bastiaansen BA, Fockens P, Dekker E. Polyp morphology: an interobserver evaluation for the Paris classification among international experts. *Am J Gastroenterol* 2015; **110**: 180-187 [PMID: 25331346 DOI: 10.1038/ajg.2014.326]
- 105 **Wang TD**, Van Dam J. Optical biopsy: a new frontier in endoscopic detection and diagnosis. *Clin Gastroenterol Hepatol* 2004; **2**: 744-753 [PMID: 15354274 DOI: 10.1016/S1542-3565(04)00345-3]
- 106 **Hassan C**, Pickhardt PJ, Rex DK. A resect and discard strategy would improve cost-effectiveness of colorectal cancer screening. *Clin Gastroenterol Hepatol* 2010; **8**: 865-869, 869.e1 [PMID: 20621680 DOI: 10.1016/j.cgh.2010.05.018]
- 107 **Byrne MF**, Chapados N, Soudan F, Oertel C, Linares Pérez M, Kelly R, Iqbal N, Chandelier F, Rex DK. Real-time differentiation of adenomatous and hyperplastic diminutive colorectal polyps during analysis of unaltered videos of standard colonoscopy using a deep learning model. *Gut* 2019; **68**: 94-100 [PMID: 29066576 DOI: 10.1136/gutjnl-2017-314547]
- 108 **Chen PJ**, Lin MC, Lai MJ, Lin JC, Lu HH, Tseng VS. Accurate Classification of Diminutive Colorectal Polyps Using Computer-Aided Analysis. *Gastroenterology* 2018; **154**: 568-575 [PMID: 29042219 DOI: 10.1053/j.gastro.2017.10.010]
- 109 **Gross S**, Trautwein C, Behrens A, Winograd R, Palm S, Lutz HH, Schirin-Sokhan R, Hecker H, Aach T, Tischendorf JJ. Computer-based classification of small colorectal polyps by using narrow-band imaging with optical magnification. *Gastrointest Endosc* 2011; **74**: 1354-1359 [PMID: 22000791 DOI: 10.1016/j.gie.2011.08.001]
- 110 **Horiuchi H**, Tamai N, Kamba S, Inomata H, Ohya TR, Sumiyama K. Real-time computer-aided diagnosis of diminutive rectosigmoid polyps using an auto-fluorescence imaging system and novel color intensity analysis software. *Scand J Gastroenterol* 2019; **54**: 800-805 [PMID: 31195905 DOI: 10.1080/00365521.2019.1627407]
- 111 **Misawa M**, Kudo SE, Mori Y, Nakamura H, Kataoka S, Maeda Y, Kudo T, Hayashi T, Wakamura K, Miyachi H, Katagiri A, Baba T, Ishida F, Inoue H, Nimura Y, Mori K. Characterization of Colorectal Lesions Using a Computer-Aided Diagnostic System for Narrow-Band Imaging Endocytoscopy. *Gastroenterology* 2016; **150**: 1531-1532.e3 [PMID: 27072671 DOI: 10.1053/j.gastro.2016.04.004]
- 112 **Mori Y**, Kudo SE, Chiu PW, Singh R, Misawa M, Wakamura K, Kudo T, Hayashi T, Katagiri A, Miyachi H, Ishida F, Maeda Y, Inoue H, Nimura Y, Oda M, Mori K. Impact of an automated system for endocytoscopic diagnosis of small colorectal lesions: an international web-based study. *Endoscopy* 2016; **48**: 1110-1118 [PMID: 27494455 DOI: 10.1055/s-0042-113609]
- 113 **Mori Y**, Kudo SE, Wakamura K, Misawa M, Ogawa Y, Kutsukawa M, Kudo T, Hayashi T, Miyachi H, Ishida F, Inoue H. Novel computer-aided diagnostic system for colorectal lesions by using endocytoscopy (with videos). *Gastrointest Endosc* 2015; **81**: 621-629 [PMID: 25440671 DOI:

- 10.1016/j.gie.2014.09.008]
- 114 **Sánchez-Montes C**, Sánchez FJ, Bernal J, Córdova H, López-Cerón M, Cuatrecasas M, Rodríguez de Miguel C, García-Rodríguez A, Garcés-Durán R, Pellisé M, Llach J, Fernández-Esparrach G. Computer-aided prediction of polyp histology on white light colonoscopy using surface pattern analysis. *Endoscopy* 2019; **51**: 261-265 [PMID: 30360010 DOI: 10.1055/a-0732-5250]
- 115 **Tischendorf JJ**, Gross S, Winograd R, Hecker H, Auer R, Behrens A, Trautwein C, Aach T, Stehle T. Computer-aided classification of colorectal polyps based on vascular patterns: a pilot study. *Endoscopy* 2010; **42**: 203-207 [PMID: 20101564 DOI: 10.1055/s-0029-1243861]
- 116 **Ikehara H**, Saito Y, Matsuda T, Uraoka T, Murakami Y. Diagnosis of depth of invasion for early colorectal cancer using magnifying colonoscopy. *J Gastroenterol Hepatol* 2010; **25**: 905-912 [PMID: 20546444 DOI: 10.1111/j.1440-1746.2010.06275.x]
- 117 **Kitajima K**, Fujimori T, Fujii S, Takeda J, Ohkura Y, Kawamata H, Kumamoto T, Ishiguro S, Kato Y, Shimoda T, Iwashita A, Ajioka Y, Watanabe H, Watanabe T, Muto T, Nagasako K. Correlations between lymph node metastasis and depth of submucosal invasion in submucosal invasive colorectal carcinoma: a Japanese collaborative study. *J Gastroenterol* 2004; **39**: 534-543 [PMID: 15235870 DOI: 10.1007/s00535-004-1339-4]
- 118 **Matsuda T**, Saito Y, Nakajima T, Sakamoto T, Ikematsu H, Sano Y, Fu KI, Fujii T. Macroscopic estimation of submucosal invasion in the colon. *Tech Gastrointest Endosc* 2011; **13**: 24-32 [DOI: 10.1016/j.tgie.2011.01.004]
- 119 **Mori Y**, Kudo SE, East JE, Rastogi A, Bretthauer M, Misawa M, Sekiguchi M, Matsuda T, Saito Y, Ikematsu H, Hotta K, Ohtsuka K, Kudo T, Mori K. Cost savings in colonoscopy with artificial intelligence-aided polyp diagnosis: an add-on analysis of a clinical trial (with video). *Gastrointest Endosc* 2020; **92**: 905-911.e1 [PMID: 32240683 DOI: 10.1016/j.gie.2020.03.3759]
- 120 **Thakkar S**, Carleton NM, Rao B, Syed A. Use of Artificial Intelligence-Based Analytics From Live Colonoscopies to Optimize the Quality of the Colonoscopy Examination in Real Time: Proof of Concept. *Gastroenterology* 2020; **158**: 1219-1221.e2 [PMID: 31945357 DOI: 10.1053/j.gastro.2019.12.035]
- 121 **Reichling C**, Taieb J, Derangere V, Klopfenstein Q, Le Malicot K, Gornet JM, Becheur H, Fein F, Cojocarasu O, Kaminsky MC, Lagasse JP, Luet D, Nguyen S, Etienne PL, Gasmi M, Vanoli A, Perrier H, Puig PL, Emile JF, Lepage C, Ghiringhelli F. Artificial intelligence-guided tissue analysis combined with immune infiltrate assessment predicts stage III colon cancer outcomes in PETACC08 study. *Gut* 2020; **69**: 681-690 [PMID: 31780575 DOI: 10.1136/gutjnl-2019-319292]
- 122 **Kather JN**, Krisam J, Charoentong P, Luedde T, Herpel E, Weis CA, Gaiser T, Marx A, Valous NA, Ferber D, Jansen L, Reyes-Aldasoro CC, Zörnig I, Jäger D, Brenner H, Chang-Claude J, Hoffmeister M, Halama N. Predicting survival from colorectal cancer histology slides using deep learning: A retrospective multicenter study. *PLoS Med* 2019; **16**: e1002730 [PMID: 30677016 DOI: 10.1371/journal.pmed.1002730]
- 123 **Skrede OJ**, De Raedt S, Kleppe A, Hveem TS, Liestøl K, Maddison J, Askautrud HA, Pradhan M, Nesheim JA, Albrechtsen F, Farstad IN, Domingo E, Church DN, Nesbakken A, Shepherd NA, Tomlinson I, Kerr R, Novelli M, Kerr DJ, Danielsen HE. Deep learning for prediction of colorectal cancer outcome: a discovery and validation study. *Lancet* 2020; **395**: 350-360 [PMID: 32007170 DOI: 10.1016/S0140-6736(19)32998-8]
- 124 **Yang YJ**. The Future of Capsule Endoscopy: The Role of Artificial Intelligence and Other Technical Advancements. *Clin Endosc* 2020; **53**: 387-394 [PMID: 32668529 DOI: 10.5946/ce.2020.133]
- 125 **Liu G**, Yan G, Kuang S, Wang Y. Detection of small bowel tumor based on multi-scale curvelet analysis and fractal technology in capsule endoscopy. *Comput Biol Med* 2016; **70**: 131-138 [PMID: 26829705 DOI: 10.1016/j.compbiomed.2016.01.021]
- 126 **Li B**, Meng MQ. Tumor recognition in wireless capsule endoscopy images using textural features and SVM-based feature selection. *IEEE Trans Inf Technol Biomed* 2012; **16**: 323-329 [PMID: 22287246 DOI: 10.1109/TITB.2012.2185807]
- 127 **Li B**, Meng MQ. Computer-based detection of bleeding and ulcer in wireless capsule endoscopy images by chromaticity moments. *Comput Biol Med* 2009; **39**: 141-147 [PMID: 19147126 DOI: 10.1016/j.compbiomed.2008.11.007]
- 128 **Aoki T**, Yamada A, Aoyama K, Saito H, Fujisawa G, Odawara N, Kondo R, Tsuboi A, Ishibashi R, Nakada A, Niikura R, Fujishiro M, Oka S, Ishihara S, Matsuda T, Nakahori M, Tanaka S, Koike K, Tada T. Clinical usefulness of a deep learning-based system as the first screening on small-bowel capsule endoscopy reading. *Dig Endosc* 2020; **32**: 585-591 [PMID: 31441972 DOI: 10.1111/den.13517]
- 129 **Soffer S**, Klang E, Shimon O, Nachmias N, Eliakim R, Ben-Horin S, Kopylov U, Barash Y. Deep learning for wireless capsule endoscopy: a systematic review and meta-analysis. *Gastrointest Endosc* 2020; **92**: 831-839.e8 [PMID: 32334015 DOI: 10.1016/j.gie.2020.04.039]
- 130 **Aoki T**, Yamada A, Kato Y, Saito H, Tsuboi A, Nakada A, Niikura R, Fujishiro M, Oka S, Ishihara S, Matsuda T, Nakahori M, Tanaka S, Koike K, Tada T. Automatic detection of blood content in capsule endoscopy images based on a deep convolutional neural network. *J Gastroenterol Hepatol* 2020; **35**: 1196-1200 [PMID: 31758717 DOI: 10.1111/jgh.14941]
- 131 **Ding Z**, Shi H, Zhang H, Meng L, Fan M, Han C, Zhang K, Ming F, Xie X, Liu H, Liu J, Lin R, Hou X. Gastroenterologist-Level Identification of Small-Bowel Diseases and Normal Variants by Capsule Endoscopy Using a Deep-Learning Model. *Gastroenterology* 2019; **157**: 1044-1054.e5 [PMID: 31251929 DOI: 10.1053/j.gastro.2019.06.025]

- 132 **Fu Y**, Zhang W, Mandal M, Meng MQ. Computer-aided bleeding detection in WCE video. *IEEE J Biomed Health Inform* 2014; **18**: 636-642 [PMID: 24608063 DOI: 10.1109/JBHI.2013.2257819]
- 133 **Hassan AR**, Haque MA. Computer-aided gastrointestinal hemorrhage detection in wireless capsule endoscopy videos. *Comput Methods Programs Biomed* 2015; **122**: 341-353 [PMID: 26390947 DOI: 10.1016/j.cmpb.2015.09.005]
- 134 **Iakovidis DK**, Koulaouzidis A. Automatic lesion detection in capsule endoscopy based on color saliency: closer to an essential adjunct for reviewing software. *Gastrointest Endosc* 2014; **80**: 877-883 [PMID: 25088924 DOI: 10.1016/j.gie.2014.06.026]
- 135 **Leenhardt R**, Vasseur P, Li C, Saurin JC, Rahmi G, Cholet F, Becq A, Marteau P, Histace A, Dray X; CAD-CAP Database Working Group. A neural network algorithm for detection of GI angiectasia during small-bowel capsule endoscopy. *Gastrointest Endosc* 2019; **89**: 189-194 [PMID: 30017868 DOI: 10.1016/j.gie.2018.06.036]
- 136 **Lv G**, Yan G, Wang Z. Bleeding detection in wireless capsule endoscopy images based on color invariants and spatial pyramids using support vector machines. *Annu Int Conf IEEE Eng Med Biol Soc* 2011; **2011**: 6643-6646 [PMID: 22255862 DOI: 10.1109/IEMBS.2011.6091638]
- 137 **Noya F**, Alvarez-Gonzalez MA, Benitez R. Automated angiodysplasia detection from wireless capsule endoscopy. *Annu Int Conf IEEE Eng Med Biol Soc* 2017; **2017**: 3158-3161 [PMID: 29060568 DOI: 10.1109/EMBC.2017.8037527]
- 138 **Pan G**, Yan G, Song X, Qiu X. BP neural network classification for bleeding detection in wireless capsule endoscopy. *J Med Eng Technol* 2009; **33**: 575-581 [PMID: 19639509 DOI: 10.1080/03091900903111974]
- 139 **Sainju S**, Bui FM, Wahid KA. Automated bleeding detection in capsule endoscopy videos using statistical features and region growing. *J Med Syst* 2014; **38**: 25 [PMID: 24696394 DOI: 10.1007/s10916-014-0025-1]
- 140 **Tsuboi A**, Oka S, Aoyama K, Saito H, Aoki T, Yamada A, Matsuda T, Fujishiro M, Ishihara S, Nakahori M, Koike K, Tanaka S, Tada T. Artificial intelligence using a convolutional neural network for automatic detection of small-bowel angioectasia in capsule endoscopy images. *Dig Endosc* 2020; **32**: 382-390 [PMID: 31392767 DOI: 10.1111/den.13507]
- 141 **Xing X**, Jia X, Meng MQ. Bleeding Detection in Wireless Capsule Endoscopy Image Video Using Superpixel-Color Histogram and a Subspace KNN Classifier. *Annu Int Conf IEEE Eng Med Biol Soc* 2018; **2018**: 1-4 [PMID: 30440286 DOI: 10.1109/EMBC.2018.8513012]
- 142 **Yuan Y**, Li B, Meng MQ. Bleeding Frame and Region Detection in the Wireless Capsule Endoscopy Video. *IEEE J Biomed Health Inform* 2016; **20**: 624-630 [PMID: 25675468 DOI: 10.1109/JBHI.2015.2399502]
- 143 **Aoki T**, Yamada A, Aoyama K, Saito H, Tsuboi A, Nakada A, Niikura R, Fujishiro M, Oka S, Ishihara S, Matsuda T, Tanaka S, Koike K, Tada T. Automatic detection of erosions and ulcerations in wireless capsule endoscopy images based on a deep convolutional neural network. *Gastrointest Endosc* 2019; **89**: 357-363.e2 [PMID: 30670179 DOI: 10.1016/j.gie.2018.10.027]
- 144 **Otani K**, Nakada A, Kurose Y, Niikura R, Yamada A, Aoki T, Nakanishi H, Doyama H, Hasatani K, Sumiyoshi T, Kitsuregawa M, Harada T, Koike K. Automatic detection of different types of small-bowel lesions on capsule endoscopy images using a newly developed deep convolutional neural network. *Endoscopy* 2020; **52**: 786-791 [PMID: 32557474 DOI: 10.1055/a-1167-8157]
- 145 **Fan S**, Xu L, Fan Y, Wei K, Li L. Computer-aided detection of small intestinal ulcer and erosion in wireless capsule endoscopy images. *Phys Med Biol* 2018; **63**: 165001 [PMID: 30033931 DOI: 10.1088/1361-6560/aad51c]
- 146 **Wang S**, Xing Y, Zhang L, Gao H, Zhang H. A systematic evaluation and optimization of automatic detection of ulcers in wireless capsule endoscopy on a large dataset using deep convolutional neural networks. *Phys Med Biol* 2019; **64**: 235014 [PMID: 31645019 DOI: 10.1088/1361-6560/ab5086]
- 147 **Klang E**, Barash Y, Margalit RY, Soffer S, Shimon O, Albsheh A, Ben-Horin S, Amitai MM, Eliakim R, Kopylov U. Deep learning algorithms for automated detection of Crohn's disease ulcers by video capsule endoscopy. *Gastrointest Endosc* 2020; **91**: 606-613.e2 [PMID: 31743689 DOI: 10.1016/j.gie.2019.11.012]
- 148 **Charisis VS**, Hadjileontiadis LJ. Potential of hybrid adaptive filtering in inflammatory lesion detection from capsule endoscopy images. *World J Gastroenterol* 2016; **22**: 8641-8657 [PMID: 27818583 DOI: 10.3748/wjg.v22.i39.8641]
- 149 **Saito H**, Aoki T, Aoyama K, Kato Y, Tsuboi A, Yamada A, Fujishiro M, Oka S, Ishihara S, Matsuda T, Nakahori M, Tanaka S, Koike K, Tada T. Automatic detection and classification of protruding lesions in wireless capsule endoscopy images based on a deep convolutional neural network. *Gastrointest Endosc* 2020; **92**: 144-151.e1 [PMID: 32084410 DOI: 10.1016/j.gie.2020.01.054]
- 150 **Yuan Y**, Meng MQ. Deep learning for polyp recognition in wireless capsule endoscopy images. *Med Phys* 2017; **44**: 1379-1389 [PMID: 28160514 DOI: 10.1002/mp.12147]
- 151 **Tenório JM**, Hummel AD, Cohrs FM, Sdepanian VL, Pisa IT, de Fátima Marin H. Artificial intelligence techniques applied to the development of a decision-support system for diagnosing celiac disease. *Int J Med Inform* 2011; **80**: 793-802 [PMID: 21917512 DOI: 10.1016/j.ijmedinf.2011.08.001]
- 152 **Zhou T**, Han G, Li BN, Lin Z, Ciaccio EJ, Green PH, Qin J. Quantitative analysis of patients with celiac disease by video capsule endoscopy: A deep learning method. *Comput Biol Med* 2017; **85**: 1-6 [PMID: 28412572 DOI: 10.1016/j.combiomed.2017.03.031]

- 153 **Wimmer G**, Vécsei A, Uhl A. CNN transfer learning for the automated diagnosis of celiac disease. *IEEE* 2016; 1-6 [DOI: [10.1109/IPTA.2016.7821020](https://doi.org/10.1109/IPTA.2016.7821020)]
- 154 **Wang X**, Qian H, Ciaccio EJ, Lewis SK, Bhagat G, Green PH, Xu S, Huang L, Gao R, Liu Y. Celiac disease diagnosis from videocapsule endoscopy images with residual learning and deep feature extraction. *Comput Methods Programs Biomed* 2020; **187**: 105236 [PMID: [31786452](https://pubmed.ncbi.nlm.nih.gov/31786452/) DOI: [10.1016/j.cmpb.2019.105236](https://doi.org/10.1016/j.cmpb.2019.105236)]
- 155 **Fenwick A**. The global burden of neglected tropical diseases. *Public Health* 2012; **126**: 233-236 [PMID: [22325616](https://pubmed.ncbi.nlm.nih.gov/22325616/) DOI: [10.1016/j.puhe.2011.11.015](https://doi.org/10.1016/j.puhe.2011.11.015)]
- 156 **Chen H**, Chen J, Peng Q, Sun G, Gan T. Automatic hookworm image detection for wireless capsule endoscopy using hybrid color gradient and contourlet transform. *Int Conf Biomed Eng Inf* 2013; 116-120 [DOI: [10.1109/BMEI.2013.6746918](https://doi.org/10.1109/BMEI.2013.6746918)]
- 157 **He JY**, Wu X, Jiang YG, Peng Q, Jain R. Hookworm Detection in Wireless Capsule Endoscopy Images With Deep Learning. *IEEE Trans Image Process* 2018; **27**: 2379-2392 [PMID: [29470172](https://pubmed.ncbi.nlm.nih.gov/29470172/) DOI: [10.1109/TIP.2018.2801119](https://doi.org/10.1109/TIP.2018.2801119)]
- 158 **Wu X**, Chen H, Gan T, Chen J, Ngo CW, Peng Q. Automatic Hookworm Detection in Wireless Capsule Endoscopy Images. *IEEE Trans Med Imaging* 2016; **35**: 1741-1752 [PMID: [26886971](https://pubmed.ncbi.nlm.nih.gov/26886971/) DOI: [10.1109/TMI.2016.2527736](https://doi.org/10.1109/TMI.2016.2527736)]
- 159 **Leenhardt R**, Souchaud M, Houist G, Le Mouel JP, Saurin JC, Cholet F, Rahmi G, Leandri C, Histace A, Dray X. A neural network-based algorithm for assessing the cleanliness of small bowel during capsule endoscopy. *Endoscopy* 2021; **53**: 932-936 [PMID: [33137834](https://pubmed.ncbi.nlm.nih.gov/33137834/) DOI: [10.1055/a-1301-3841](https://doi.org/10.1055/a-1301-3841)]
- 160 **Noorda R**, Nevárez A, Colomer A, Pons Beltrán V, Naranjo V. Automatic evaluation of degree of cleanliness in capsule endoscopy based on a novel CNN architecture. *Sci Rep* 2020; **10**: 17706 [PMID: [33077755](https://pubmed.ncbi.nlm.nih.gov/33077755/) DOI: [10.1038/s41598-020-74668-8](https://doi.org/10.1038/s41598-020-74668-8)]
- 161 **Borg-Bartolo SP**, Boyapati RK, Satsangi J, Kalla R. Precision medicine in inflammatory bowel disease: concept, progress and challenges. *F1000Res* 2020; **9** [PMID: [32047622](https://pubmed.ncbi.nlm.nih.gov/32047622/) DOI: [10.12688/f1000research.20928.1](https://doi.org/10.12688/f1000research.20928.1)]
- 162 **Seyed Tabib NS**, Madgwick M, Sudhakar P, Verstockt B, Korcsmaros T, Vermeire S. Big data in IBD: big progress for clinical practice. *Gut* 2020; **69**: 1520-1532 [PMID: [32111636](https://pubmed.ncbi.nlm.nih.gov/32111636/) DOI: [10.1136/gutjnl-2019-320065](https://doi.org/10.1136/gutjnl-2019-320065)]
- 163 **Olivera P**, Danese S, Jay N, Natoli G, Peyrin-Biroulet L. Big data in IBD: a look into the future. *Nat Rev Gastroenterol Hepatol* 2019; **16**: 312-321 [PMID: [30659247](https://pubmed.ncbi.nlm.nih.gov/30659247/) DOI: [10.1038/s41575-019-0102-5](https://doi.org/10.1038/s41575-019-0102-5)]
- 164 **Bossuyt P**, Vermeire S, Bisschops R. Scoring endoscopic disease activity in IBD: artificial intelligence sees more and better than we do. *Gut* 2020; **69**: 788-789 [PMID: [30954951](https://pubmed.ncbi.nlm.nih.gov/30954951/) DOI: [10.1136/gutjnl-2019-318235](https://doi.org/10.1136/gutjnl-2019-318235)]
- 165 **Iacucci M**, Furfaro F, Matsumoto T, Uraoka T, Smith S, Ghosh S, Kiesslich R. Advanced endoscopic techniques in the assessment of inflammatory bowel disease: new technology, new era. *Gut* 2019; **68**: 562-572 [PMID: [30580249](https://pubmed.ncbi.nlm.nih.gov/30580249/) DOI: [10.1136/gutjnl-2017-315235](https://doi.org/10.1136/gutjnl-2017-315235)]
- 166 **Ozawa T**, Ishihara S, Fujishiro M, Saito H, Kumagai Y, Shichijo S, Aoyama K, Tada T. Novel computer-assisted diagnosis system for endoscopic disease activity in patients with ulcerative colitis. *Gastrointest Endosc* 2019; **89**: 416-421.e1 [PMID: [30367878](https://pubmed.ncbi.nlm.nih.gov/30367878/) DOI: [10.1016/j.gie.2018.10.020](https://doi.org/10.1016/j.gie.2018.10.020)]
- 167 **Zeos P**, Borowski K, Bajaj G, Boland K, Sheasgreen C, Tessolini JM, Silverberg MS. 439 - Toward Computer-Based Automated Mayo Score Classification in Ulcerative Colitis through Classical and Deep Machine Learning. *Gastroenterology* 2018; **154**: S-99 [DOI: [10.1016/S0016-5085\(18\)30773-X](https://doi.org/10.1016/S0016-5085(18)30773-X)]
- 168 **Khorasani HM**, Usefi H, Peña-Castillo L. Detecting ulcerative colitis from colon samples using efficient feature selection and machine learning. *Sci Rep* 2020; **10**: 13744 [PMID: [32792678](https://pubmed.ncbi.nlm.nih.gov/32792678/) DOI: [10.1038/s41598-020-70583-0](https://doi.org/10.1038/s41598-020-70583-0)]
- 169 **Kumar R**, Zhao Q, Seshamani S, Mullin G, Hager G, Dassopoulos T. Assessment of Crohn's disease lesions in wireless capsule endoscopy images. *IEEE Trans Biomed Eng* 2012; **59**: 355-362 [PMID: [22020661](https://pubmed.ncbi.nlm.nih.gov/22020661/) DOI: [10.1109/TBME.2011.2172438](https://doi.org/10.1109/TBME.2011.2172438)]
- 170 **Mahapatra D**, Vos FM, Buhmann JM. Active learning based segmentation of Crohns disease from abdominal MRI. *Comput Methods Programs Biomed* 2016; **128**: 75-85 [PMID: [27040833](https://pubmed.ncbi.nlm.nih.gov/27040833/) DOI: [10.1016/j.cmpb.2016.01.014](https://doi.org/10.1016/j.cmpb.2016.01.014)]
- 171 **Mossotto E**, Ashton JJ, Coelho T, Beattie RM, MacArthur BD, Ennis S. Classification of Paediatric Inflammatory Bowel Disease using Machine Learning. *Sci Rep* 2017; **7**: 2427 [PMID: [28546534](https://pubmed.ncbi.nlm.nih.gov/28546534/) DOI: [10.1038/s41598-017-02606-2](https://doi.org/10.1038/s41598-017-02606-2)]
- 172 **Maeda Y**, Kudo SE, Mori Y, Misawa M, Ogata N, Sasanuma S, Wakamura K, Oda M, Mori K, Ohtsuka K. Fully automated diagnostic system with artificial intelligence using endocytoscopy to identify the presence of histologic inflammation associated with ulcerative colitis (with video). *Gastrointest Endosc* 2019; **89**: 408-415 [PMID: [30268542](https://pubmed.ncbi.nlm.nih.gov/30268542/) DOI: [10.1016/j.gie.2018.09.024](https://doi.org/10.1016/j.gie.2018.09.024)]
- 173 **Matalka II**, Al-Omari FA, Salama RM, Mohtaseb AH. A novel approach for quantitative assessment of mucosal damage in inflammatory bowel disease. *Diagn Pathol* 2013; **8**: 156 [PMID: [24053788](https://pubmed.ncbi.nlm.nih.gov/24053788/) DOI: [10.1186/1746-1596-8-156](https://doi.org/10.1186/1746-1596-8-156)]
- 174 **Niehaus KE**, Uhlig HH, Clifton DA. Phenotypic characterisation of Crohn's disease severity. *Annu Int Conf IEEE Eng Med Biol Soc* 2015; **2015**: 7023-7026 [PMID: [26737909](https://pubmed.ncbi.nlm.nih.gov/26737909/) DOI: [10.1109/EMBC.2015.7320009](https://doi.org/10.1109/EMBC.2015.7320009)]
- 175 **Reddy BK**, Delen D, Agrawal RK. Predicting and explaining inflammation in Crohn's disease patients using predictive analytics methods and electronic medical record data. *Health Informatics J*

- 2019; **25**: 1201-1218 [PMID: [29320910](#) DOI: [10.1177/1460458217751015](#)]
- 176 **Stidham RW**, Enchakalody B, Waljee AK, Higgins PDR, Wang SC, Su GL, Wasnik AP, Al-Hawary M. Assessing Small Bowel Stricture and Morphology in Crohn's Disease Using Semi-automated Image Analysis. *Inflamm Bowel Dis* 2020; **26**: 734-742 [PMID: [31504540](#) DOI: [10.1093/ibd/izz196](#)]
- 177 **Stidham RW**, Liu W, Bishu S, Rice MD, Higgins PDR, Zhu J, Nallamotheu BK, Waljee AK. Performance of a Deep Learning Model vs Human Reviewers in Grading Endoscopic Disease Severity of Patients With Ulcerative Colitis. *JAMA Netw Open* 2019; **2**: e193963 [PMID: [31099869](#) DOI: [10.1001/jamanetworkopen.2019.3963](#)]
- 178 **Takenaka K**, Ohtsuka K, Fujii T, Negi M, Suzuki K, Shimizu H, Oshima S, Akiyama S, Motobayashi M, Nagahori M, Saito E, Matsuoka K, Watanabe M. Development and Validation of a Deep Neural Network for Accurate Evaluation of Endoscopic Images From Patients With Ulcerative Colitis. *Gastroenterology* 2020; **158**: 2150-2157 [PMID: [32060000](#) DOI: [10.1053/j.gastro.2020.02.012](#)]
- 179 **Yao H**, Najarian K, Gryak J, Bishu S, Rice MD, Waljee AK, Wilkins HJ, Stidham RW. Fully automated endoscopic disease activity assessment in ulcerative colitis. *Gastrointest Endosc* 2021; **93**: 728-736.e1 [PMID: [32810479](#) DOI: [10.1016/j.gie.2020.08.011](#)]
- 180 **Doherty MK**, Ding T, Koumpouras C, Telesco SE, Monast C, Das A, Brodmerkel C, Schloss PD. Fecal Microbiota Signatures Are Associated with Response to Ustekinumab Therapy among Crohn's Disease Patients. *mBio* 2018; **9** [PMID: [29535202](#) DOI: [10.1128/mBio.02120-17](#)]
- 181 **Douglas GM**, Hansen R, Jones CMA, Dunn KA, Comeau AM, Bielawski JP, Tayler R, El-Omar EM, Russell RK, Hold GL, Langille MGI, Van Limbergen J. Multi-omics differentially classify disease state and treatment outcome in pediatric Crohn's disease. *Microbiome* 2018; **6**: 13 [PMID: [29335008](#) DOI: [10.1186/s40168-018-0398-3](#)]
- 182 **Waljee AK**, Joyce JC, Wang S, Saxena A, Hart M, Zhu J, Higgins PD. Algorithms outperform metabolite tests in predicting response of patients with inflammatory bowel disease to thiopurines. *Clin Gastroenterol Hepatol* 2010; **8**: 143-150 [PMID: [19835986](#) DOI: [10.1016/j.cgh.2009.09.031](#)]
- 183 **Waljee AK**, Lipson R, Wiitala WL, Zhang Y, Liu B, Zhu J, Wallace B, Govani SM, Stidham RW, Hayward R, Higgins PDR. Predicting Hospitalization and Outpatient Corticosteroid Use in Inflammatory Bowel Disease Patients Using Machine Learning. *Inflamm Bowel Dis* 2017; **24**: 45-53 [PMID: [29272474](#) DOI: [10.1093/ibd/ixz007](#)]
- 184 **Waljee AK**, Liu B, Sauder K, Zhu J, Govani SM, Stidham RW, Higgins PDR. Predicting corticosteroid-free endoscopic remission with vedolizumab in ulcerative colitis. *Aliment Pharmacol Ther* 2018; **47**: 763-772 [PMID: [29359519](#) DOI: [10.1111/apt.14510](#)]
- 185 **Waljee AK**, Sauder K, Patel A, Segar S, Liu B, Zhang Y, Zhu J, Stidham RW, Balis U, Higgins PDR. Machine Learning Algorithms for Objective Remission and Clinical Outcomes with Thiopurines. *J Crohns Colitis* 2017; **11**: 801-810 [PMID: [28333183](#) DOI: [10.1093/ecco-jcc/jjx014](#)]
- 186 **Waljee AK**, Wallace BI, Cohen-Mekelburg S, Liu Y, Liu B, Sauder K, Stidham RW, Zhu J, Higgins PDR. Development and Validation of Machine Learning Models in Prediction of Remission in Patients With Moderate to Severe Crohn Disease. *JAMA Netw Open* 2019; **2**: e193721 [PMID: [31074823](#) DOI: [10.1001/jamanetworkopen.2019.3721](#)]
- 187 **Isakov O**, Dotan I, Ben-Shachar S. Machine Learning-Based Gene Prioritization Identifies Novel Candidate Risk Genes for Inflammatory Bowel Disease. *Inflamm Bowel Dis* 2017; **23**: 1516-1523 [PMID: [28795970](#) DOI: [10.1097/MIB.0000000000001222](#)]
- 188 **Wei Z**, Wang W, Bradfield J, Li J, Cardinale C, Frackelton E, Kim C, Mentch F, Van Steen K, Visscher PM, Baldassano RN, Hakonarson H; International IBD Genetics Consortium. Large sample size, wide variant spectrum, and advanced machine-learning technique boost risk prediction for inflammatory bowel disease. *Am J Hum Genet* 2013; **92**: 1008-1012 [PMID: [23731541](#) DOI: [10.1016/j.ajhg.2013.05.002](#)]
- 189 **Hou JK**, Chang M, Nguyen T, Kramer JR, Richardson P, Sangsriy S, D'Avolio LW, El-Serag HB. Automated identification of surveillance colonoscopy in inflammatory bowel disease using natural language processing. *Dig Dis Sci* 2013; **58**: 936-941 [PMID: [23086115](#) DOI: [10.1007/s10620-012-2433-8](#)]
- 190 **Firouzi F**, Rashidi M, Hashemi S, Kangavari M, Bahari A, Daryani NE, Emam MM, Naderi N, Shalmani HM, Farnood A, Zali M. A decision tree-based approach for determining low bone mineral density in inflammatory bowel disease using WEKA software. *Eur J Gastroenterol Hepatol* 2007; **19**: 1075-1081 [PMID: [17998832](#) DOI: [10.1097/MEG.0b013e3282202bb8](#)]
- 191 **Ahn JC**, Connell A, Simonetto DA, Hughes C, Shah VH. Application of Artificial Intelligence for the Diagnosis and Treatment of Liver Diseases. *Hepatology* 2021; **73**: 2546-2563 [PMID: [33098140](#) DOI: [10.1002/hep.31603](#)]
- 192 **Spann A**, Yasodhara A, Kang J, Watt K, Wang B, Goldenberg A, Bhat M. Applying Machine Learning in Liver Disease and Transplantation: A Comprehensive Review. *Hepatology* 2020; **71**: 1093-1105 [PMID: [31907954](#) DOI: [10.1002/hep.31103](#)]
- 193 **Chen T**, Tu S, Wang H, Liu X, Li F, Jin W, Liang X, Zhang X, Wang J. Computer-aided diagnosis of gallbladder polyps based on high resolution ultrasonography. *Comput Methods Programs Biomed* 2020; **185**: 105118 [PMID: [31671340](#) DOI: [10.1016/j.cmpb.2019.105118](#)]
- 194 **Hamm CA**, Wang CJ, Savic LJ, Ferrante M, Schobert I, Schlachter T, Lin M, Duncan JS, Weinreb JC, Chapiro J, Letzen B. Deep learning for liver tumor diagnosis part I: development of a convolutional neural network classifier for multi-phasic MRI. *Eur Radiol* 2019; **29**: 3338-3347

- [PMID: 31016442 DOI: 10.1007/s00330-019-06205-9]
- 195 **Kim DW**, Lee G, Kim SY, Ahn G, Lee JG, Lee SS, Kim KW, Park SH, Lee YJ, Kim N. Deep learning-based algorithm to detect primary hepatic malignancy in multiphase CT of patients at high risk for HCC. *Eur Radiol* 2021; **31**: 7047-7057 [PMID: 33738600 DOI: 10.1007/s00330-021-07803-2]
- 196 **Kim JW**, Ye Q, Forgues M, Chen Y, Budhu A, Sime J, Hofseth LJ, Kaul R, Wang XW. Cancer-associated molecular signature in the tissue samples of patients with cirrhosis. *Hepatology* 2004; **39**: 518-527 [PMID: 14768006 DOI: 10.1002/hep.20053]
- 197 **Schmauch B**, Herent P, Jehanno P, Dehaene O, Saillard C, Aubé C, Luciani A, Lassau N, Jégou S. Diagnosis of focal liver lesions from ultrasound using deep learning. *Diagn Interv Imaging* 2019; **100**: 227-233 [PMID: 30926443 DOI: 10.1016/j.diii.2019.02.009]
- 198 **Singal AG**, Mukherjee A, Elmunzer BJ, Higgins PD, Lok AS, Zhu J, Marrero JA, Waljee AK. Machine learning algorithms outperform conventional regression models in predicting development of hepatocellular carcinoma. *Am J Gastroenterol* 2013; **108**: 1723-1730 [PMID: 24169273 DOI: 10.1038/ajg.2013.332]
- 199 **Sun C**, Xu A, Liu D, Xiong Z, Zhao F, Ding W. Deep Learning-Based Classification of Liver Cancer Histopathology Images Using Only Global Labels. *IEEE J Biomed Health Inform* 2020; **24**: 1643-1651 [PMID: 31670686 DOI: 10.1109/JBHI.2019.2949837]
- 200 **Wang CJ**, Hamm CA, Savic LJ, Ferrante M, Schobert I, Schlachter T, Lin M, Weinreb JC, Duncan JS, Chapiro J, Letzen B. Deep learning for liver tumor diagnosis part II: convolutional neural network interpretation using radiologic imaging features. *Eur Radiol* 2019; **29**: 3348-3357 [PMID: 31093705 DOI: 10.1007/s00330-019-06214-8]
- 201 **Yasaka K**, Akai H, Abe O, Kiryu S. Deep Learning with Convolutional Neural Network for Differentiation of Liver Masses at Dynamic Contrast-enhanced CT: A Preliminary Study. *Radiology* 2018; **286**: 887-896 [PMID: 29059036 DOI: 10.1148/radiol.2017170706]
- 202 **Yasaka K**, Akai H, Kunimatsu A, Abe O, Kiryu S. Liver Fibrosis: Deep Convolutional Neural Network for Staging by Using Gadoteric Acid-enhanced Hepatobiliary Phase MR Images. *Radiology* 2018; **287**: 146-155 [PMID: 29239710 DOI: 10.1148/radiol.2017171928]
- 203 **Abd El-Salam SM**, Ezz MM, Hashem S, Elakel W, Salama R, ElMakhzangy H, ElHefnawi M. Performance of machine learning approaches on prediction of esophageal varices for Egyptian chronic hepatitis C patients. *Inform Med Unlocked* 2019; **17**: 100267 [DOI: 10.1016/j.imu.2019.100267]
- 204 **Dong TS**, Kalani A, Aby ES, Le L, Luu K, Hauer M, Kamath R, Lindor KD, Tabibian JH. Machine Learning-based Development and Validation of a Scoring System for Screening High-Risk Esophageal Varices. *Clin Gastroenterol Hepatol* 2019; **17**: 1894-1901.e1 [PMID: 30708109 DOI: 10.1016/j.cgh.2019.01.025]
- 205 **Hong WD**, Ji YF, Wang D, Chen TZ, Zhu QH. Use of artificial neural network to predict esophageal varices in patients with HBV related cirrhosis. *Hepat Mon* 2011; **11**: 544-547 [PMID: 22087192]
- 206 **Liu Y**, Ning Z, Örmeci N, An W, Yu Q, Han K, Huang Y, Liu D, Liu F, Li Z, Ding H, Luo H, Zuo C, Liu C, Wang J, Zhang C, Ji J, Wang W, Wang Z, Yuan M, Li L, Zhao Z, Wang G, Li M, Liu Q, Lei J, Tang T, Akçalar S, Çelebioğlu E, Üstüner E, Bilgiç S, Ellik Z, Asiller ÖÖ, Liu Z, Teng G, Chen Y, Hou J, Li X, He X, Dong J, Tian J, Liang P, Ju S, Zhang Y, Qi X. Deep Convolutional Neural Network-Aided Detection of Portal Hypertension in Patients With Cirrhosis. *Clin Gastroenterol Hepatol* 2020; **18**: 2998-3007.e5 [PMID: 32205218 DOI: 10.1016/j.cgh.2020.03.034]
- 207 **Marozas M**, Zyklus R, Sakalauskas A, Kupčinskas L, Lukoševičius A. Noninvasive Evaluation of Portal Hypertension Using a Supervised Learning Technique. *J Healthc Eng* 2017; **2017**: 6183714 [PMID: 29158886 DOI: 10.1155/2017/6183714]
- 208 **Qi X**, An W, Liu F, Qi R, Wang L, Liu Y, Liu C, Xiang Y, Hui J, Liu Z, Qi X, Peng B, Ding H, Yang Y, He X, Hou J, Tian J, Li Z. Virtual Hepatic Venous Pressure Gradient with CT Angiography (CHESS 1601): A Prospective Multicenter Study for the Noninvasive Diagnosis of Portal Hypertension. *Radiology* 2019; **290**: 370-377 [PMID: 30457484 DOI: 10.1148/radiol.2018180425]
- 209 **Ahmed Y**, Hussein RS, Basha TA, Khalifa AM, Ibrahim AS, Abdelmoaty AS, Abdella HM, Fahmy AS. Detecting liver fibrosis using a machine learning-based approach to the quantification of the heart-induced deformation in tagged MR images. *NMR Biomed* 2020; **33**: e4215 [PMID: 31730265 DOI: 10.1002/nbm.4215]
- 210 **Byra M**, Styczynski G, Szmigielski C, Kalinowski P, Michałowski Ł, Paluszkiwicz R, Ziarkiewicz-Wróblewska B, Zieniewicz K, Sobieraj P, Nowicki A. Transfer learning with deep convolutional neural network for liver steatosis assessment in ultrasound images. *Int J Comput Assist Radiol Surg* 2018; **13**: 1895-1903 [PMID: 30094778 DOI: 10.1007/s11548-018-1843-2]
- 211 **Chang EK**, Yu CY, Clarke R, Hackbarth A, Sanders T, Esrailian E, Hommes DW, Runyon BA. Defining a Patient Population With Cirrhosis: An Automated Algorithm With Natural Language Processing. *J Clin Gastroenterol* 2016; **50**: 889-894 [PMID: 27348317 DOI: 10.1097/MCG.0000000000000583]
- 212 **Chen Y**, Luo Y, Huang W, Hu D, Zheng RQ, Cong SZ, Meng FK, Yang H, Lin HJ, Sun Y, Wang XY, Wu T, Ren J, Pei SF, Zheng Y, He Y, Hu Y, Yang N, Yan H. Machine-learning-based classification of real-time tissue elastography for hepatic fibrosis in patients with chronic hepatitis B. *Comput Biol Med* 2017; **89**: 18-23 [PMID: 28779596 DOI: 10.1016/j.combiomed.2017.07.012]
- 213 **Choi KJ**, Jang JK, Lee SS, Sung YS, Shim WH, Kim HS, Yun J, Choi JY, Lee Y, Kang BK, Kim

- JH, Kim SY, Yu ES. Development and Validation of a Deep Learning System for Staging Liver Fibrosis by Using Contrast Agent-enhanced CT Images in the Liver. *Radiology* 2018; **289**: 688-697 [PMID: 30179104 DOI: 10.1148/radiol.2018180763]
- 214 Cui E, Long W, Wu J, Li Q, Ma C, Lei Y, Lin F. Predicting the stages of liver fibrosis with multiphase CT radiomics based on volumetric features. *Abdom Radiol (NY)* 2021; **46**: 3866-3876 [PMID: 33751193 DOI: 10.1007/s00261-021-03051-6]
- 215 Forlano R, Mullish BH, Giannakeas N, Maurice JB, Angkathunyakul N, Lloyd J, Tzallas AT, Tsipouras M, Yee M, Thursz MR, Goldin RD, Manousou P. High-Throughput, Machine Learning-Based Quantification of Steatosis, Inflammation, Ballooning, and Fibrosis in Biopsies From Patients With Nonalcoholic Fatty Liver Disease. *Clin Gastroenterol Hepatol* 2020; **18**: 2081-2090.e9 [PMID: 31887451 DOI: 10.1016/j.cgh.2019.12.025]
- 216 Gatos I, Tsantis S, Spiliopoulos S, Karnabatidis D, Theotokas I, Zoumpoulis P, Loupas T, Hazle JD, Kagadis GC. A new computer aided diagnosis system for evaluation of chronic liver disease with ultrasound shear wave elastography imaging. *Med Phys* 2016; **43**: 1428-1436 [PMID: 26936727 DOI: 10.1118/1.4942383]
- 217 Gatos I, Tsantis S, Spiliopoulos S, Karnabatidis D, Theotokas I, Zoumpoulis P, Loupas T, Hazle JD, Kagadis GC. A Machine-Learning Algorithm Toward Color Analysis for Chronic Liver Disease Classification, Employing Ultrasound Shear Wave Elastography. *Ultrasound Med Biol* 2017; **43**: 1797-1810 [PMID: 28634041 DOI: 10.1016/j.ultrasmedbio.2017.05.002]
- 218 Gatos I, Tsantis S, Spiliopoulos S, Karnabatidis D, Theotokas I, Zoumpoulis P, Loupas T, Hazle JD, Kagadis GC. Temporal stability assessment in shear wave elasticity images validated by deep learning neural network for chronic liver disease fibrosis stage assessment. *Med Phys* 2019; **46**: 2298-2309 [PMID: 30929260 DOI: 10.1002/mp.13521]
- 219 Heinemann F, Birk G, Stierstorfer B. Deep learning enables pathologist-like scoring of NASH models. *Sci Rep* 2019; **9**: 18454 [PMID: 31804575 DOI: 10.1038/s41598-019-54904-6]
- 220 Huang H, Shiffman ML, Friedman S, Venkatesh R, Bzowej N, Abar OT, Rowland CM, Catanese JJ, Leong DU, Sninsky JJ, Layden TJ, Wright TL, White T, Cheung RC. A 7 gene signature identifies the risk of developing cirrhosis in patients with chronic hepatitis C. *Hepatology* 2007; **46**: 297-306 [PMID: 17461418 DOI: 10.1002/hep.21695]
- 221 Konerman MA, Beste LA, Van T, Liu B, Zhang X, Zhu J, Saini SD, Su GL, Nallamothu BK, Ioannou GN, Waljee AK. Machine learning models to predict disease progression among veterans with hepatitis C virus. *PLoS One* 2019; **14**: e0208141 [PMID: 30608929 DOI: 10.1371/journal.pone.0208141]
- 222 Konerman MA, Zhang Y, Zhu J, Higgins PD, Lok AS, Waljee AK. Improvement of predictive models of risk of disease progression in chronic hepatitis C by incorporating longitudinal data. *Hepatology* 2015; **61**: 1832-1841 [PMID: 25684666 DOI: 10.1002/hep.27750]
- 223 Kuppli V, Biswas M, Sreekumar A, Suri HS, Saba L, Edla DR, Marinho RT, Sanches JM, Suri JS. Extreme Learning Machine Framework for Risk Stratification of Fatty Liver Disease Using Ultrasound Tissue Characterization. *J Med Syst* 2017; **41**: 152 [PMID: 28836045 DOI: 10.1007/s10916-017-0797-1]
- 224 Lara J, López-Labrador F, González-Candelas F, Berenguer M, Khudiyakov YE. Computational models of liver fibrosis progression for hepatitis C virus chronic infection. *BMC Bioinformatics* 2014; **15** Suppl 8: S5 [PMID: 25081062 DOI: 10.1186/1471-2105-15-S8-S5]
- 225 Li W, Huang Y, Zhuang BW, Liu GJ, Hu HT, Li X, Liang JY, Wang Z, Huang XW, Zhang CQ, Ruan SM, Xie XY, Kuang M, Lu MD, Chen LD, Wang W. Multiparametric ultrasomics of significant liver fibrosis: A machine learning-based analysis. *Eur Radiol* 2019; **29**: 1496-1506 [PMID: 30178143 DOI: 10.1007/s00330-018-5680-z]
- 226 Meffert PJ, Baumeister SE, Lerch MM, Mayerle J, Kratzer W, Völzke H. Development, external validation, and comparative assessment of a new diagnostic score for hepatic steatosis. *Am J Gastroenterol* 2014; **109**: 1404-1414 [PMID: 24957156 DOI: 10.1038/ajg.2014.155]
- 227 Perakakis N, Polyzos SA, Yazdani A, Sala-Vila A, Kountouras J, Anastasilakis AD, Mantzoros CS. Non-invasive diagnosis of non-alcoholic steatohepatitis and fibrosis with the use of omics and supervised learning: A proof of concept study. *Metabolism* 2019; **101**: 154005 [PMID: 31711876 DOI: 10.1016/j.metabol.2019.154005]
- 228 Piscaglia F, Cucchetti A, Benlloch S, Vivarelli M, Berenguer J, Bolondi L, Pinna AD, Berenguer M. Prediction of significant fibrosis in hepatitis C virus infected liver transplant recipients by artificial neural network analysis of clinical factors. *Eur J Gastroenterol Hepatol* 2006; **18**: 1255-1261 [PMID: 17099373 DOI: 10.1097/01.meg.0000243885.55562.7e]
- 229 Raoufy MR, Vahdani P, Alavian SM, Fekri S, Eftekhari P, Gharibzadeh S. A novel method for diagnosing cirrhosis in patients with chronic hepatitis B: artificial neural network approach. *J Med Syst* 2011; **35**: 121-126 [PMID: 20703578 DOI: 10.1007/s10916-009-9348-8]
- 230 Redman JS, Natarajan Y, Hou JK, Wang J, Hanif M, Feng H, Kramer JR, Desiderio R, Xu H, El-Serag HB, Kanwal F. Accurate Identification of Fatty Liver Disease in Data Warehouse Utilizing Natural Language Processing. *Dig Dis Sci* 2017; **62**: 2713-2718 [PMID: 28861720 DOI: 10.1007/s10620-017-4721-9]
- 231 Sowa JP, Heider D, Bechmann LP, Gerken G, Hoffmann D, Canbay A. Novel algorithm for non-invasive assessment of fibrosis in NAFLD. *PLoS One* 2013; **8**: e62439 [PMID: 23638085 DOI: 10.1371/journal.pone.0062439]
- 232 Wang K, Lu X, Zhou H, Gao Y, Zheng J, Tong M, Wu C, Liu C, Huang L, Jiang T, Meng F, Lu Y,

- Ai H, Xie XY, Yin LP, Liang P, Tian J, Zheng R. Deep learning Radiomics of shear wave elastography significantly improved diagnostic performance for assessing liver fibrosis in chronic hepatitis B: a prospective multicentre study. *Gut* 2019; **68**: 729-741 [PMID: 29730602 DOI: 10.1136/gutjnl-2018-316204]
- 233 **Wei R**, Wang J, Wang X, Xie G, Wang Y, Zhang H, Peng CY, Rajani C, Kwee S, Liu P, Jia W. Clinical prediction of HBV and HCV related hepatic fibrosis using machine learning. *EBioMedicine* 2018; **35**: 124-132 [PMID: 30100397 DOI: 10.1016/j.ebiom.2018.07.041]
- 234 **Lee JH**, Joo I, Kang TW, Paik YH, Sinn DH, Ha SY, Kim K, Choi C, Lee G, Yi J, Bang WC. Deep learning with ultrasonography: automated classification of liver fibrosis using a deep convolutional neural network. *Eur Radiol* 2020; **30**: 1264-1273 [PMID: 31478087 DOI: 10.1007/s00330-019-06407-1]
- 235 **Canbay A**, Kälisch J, Neumann U, Rau M, Hohenester S, Baba HA, Rust C, Geier A, Heider D, Sowa JP. Non-invasive assessment of NAFLD as systemic disease-A machine learning perspective. *PLoS One* 2019; **14**: e0214436 [PMID: 30913263 DOI: 10.1371/journal.pone.0214436]
- 236 **Docherty M**, Regnier SA, Capkun G, Balp MM, Ye Q, Janssens N, Tietz A, Löffler J, Cai J, Pedrosa MC, Schattenberg JM. Development of a novel machine learning model to predict presence of nonalcoholic steatohepatitis. *J Am Med Inform Assoc* 2021; **28**: 1235-1241 [PMID: 33684933 DOI: 10.1093/jamia/ocab003]
- 237 **Fialoke S**, Malarstig A, Miller MR, Dumitriu A. Application of Machine Learning Methods to Predict Non-Alcoholic Steatohepatitis (NASH) in Non-Alcoholic Fatty Liver (NAFL) Patients. *AMIA Annu Symp Proc* 2018; **2018**: 430-439 [PMID: 30815083]
- 238 **Sowa JP**, Atmaca Ö, Kahraman A, Schlattjan M, Lindner M, Sydor S, Scherbaum N, Lackner K, Gerken G, Heider D, Arteel GE, Erim Y, Canbay A. Non-invasive separation of alcoholic and non-alcoholic liver disease with predictive modeling. *PLoS One* 2014; **9**: e101444 [PMID: 24988316 DOI: 10.1371/journal.pone.0101444]
- 239 **Taylor-Weiner A**, Pokkalla H, Han L, Jia C, Huss R, Chung C, Elliott H, Glass B, Pethia K, Carrasco-Zevallos O, Shukla C, Khettry U, Najarian R, Taliano R, Subramanian GM, Myers RP, Wapinski I, Khosla A, Resnick M, Montalto MC, Anstee QM, Wong VW, Trauner M, Lawitz EJ, Harrison SA, Okanoue T, Romero-Gomez M, Goodman Z, Loomba R, Beck AH, Younossi ZM. A Machine Learning Approach Enables Quantitative Measurement of Liver Histology and Disease Monitoring in NASH. *Hepatology* 2021; **74**: 133-147 [PMID: 33570776 DOI: 10.1002/hep.31750]
- 240 **Van Vleck TT**, Chan L, Coca SG, Craven CK, Do R, Ellis SB, Kannry JL, Loos RJF, Bonis PA, Cho J, Nadkarni GN. Augmented intelligence with natural language processing applied to electronic health records for identifying patients with non-alcoholic fatty liver disease at risk for disease progression. *Int J Med Inform* 2019; **129**: 334-341 [PMID: 31445275 DOI: 10.1016/j.ijmedinf.2019.06.028]
- 241 **Vanderbeck S**, Bockhorst J, Kleiner D, Komorowski R, Chalasani N, Gawrieh S. Automatic quantification of lobular inflammation and hepatocyte ballooning in nonalcoholic fatty liver disease liver biopsies. *Hum Pathol* 2015; **46**: 767-775 [PMID: 25776030 DOI: 10.1016/j.humpath.2015.01.019]
- 242 **Vanderbeck S**, Bockhorst J, Komorowski R, Kleiner DE, Gawrieh S. Automatic classification of white regions in liver biopsies by supervised machine learning. *Hum Pathol* 2014; **45**: 785-792 [PMID: 24565203 DOI: 10.1016/j.humpath.2013.11.011]
- 243 **Andres A**, Montano-Loza A, Greiner R, Uhlich M, Jin P, Hoehn B, Bigam D, Shapiro JAM, Kneteman NM. A novel learning algorithm to predict individual survival after liver transplantation for primary sclerosing cholangitis. *PLoS One* 2018; **13**: e0193523 [PMID: 29543895 DOI: 10.1371/journal.pone.0193523]
- 244 **Ayllón MD**, Ciria R, Cruz-Ramírez M, Pérez-Ortiz M, Gómez I, Valente R, O'Grady J, de la Mata M, Hervás-Martínez C, Heaton ND, Briceño J. Validation of artificial neural networks as a methodology for donor-recipient matching for liver transplantation. *Liver Transpl* 2018; **24**: 192-203 [PMID: 28921876 DOI: 10.1002/lt.24870]
- 245 **Bertsimas D**, Kung J, Trichakis N, Wang Y, Hirose R, Vagefi PA. Development and validation of an optimized prediction of mortality for candidates awaiting liver transplantation. *Am J Transplant* 2019; **19**: 1109-1118 [PMID: 30411495 DOI: 10.1111/ajt.15172]
- 246 **Bhat V**, Tazari M, Watt KD, Bhat M. New-Onset Diabetes and Preexisting Diabetes Are Associated With Comparable Reduction in Long-Term Survival After Liver Transplant: A Machine Learning Approach. *Mayo Clin Proc* 2018; **93**: 1794-1802 [PMID: 30522594 DOI: 10.1016/j.mayocp.2018.06.020]
- 247 **Briceño J**, Cruz-Ramírez M, Prieto M, Navasa M, Ortiz de Urbina J, Orti R, Gómez-Bravo MÁ, Otero A, Varo E, Tomé S, Clemente G, Bañares R, Bárcena R, Cuervas-Mons V, Solórzano G, Vinaixa C, Rubín A, Colmenero J, Valdivieso A, Ciria R, Hervás-Martínez C, de la Mata M. Use of artificial intelligence as an innovative donor-recipient matching model for liver transplantation: results from a multicenter Spanish study. *J Hepatol* 2014; **61**: 1020-1028 [PMID: 24905493 DOI: 10.1016/j.jhep.2014.05.039]
- 248 **Kazemi A**, Kazemi K, Sami A, Sharifian R. Identifying Factors That Affect Patient Survival After Orthotopic Liver Transplant Using Machine-Learning Techniques. *Exp Clin Transplant* 2019; **17**: 775-783 [PMID: 30968757 DOI: 10.6002/ect.2018.0170]
- 249 **Lau L**, Kankanige Y, Rubinstein B, Jones R, Christophi C, Muralidharan V, Bailey J. Machine-Learning Algorithms Predict Graft Failure After Liver Transplantation. *Transplantation* 2017; **101**:

- e125-e132 [PMID: 27941428 DOI: 10.1097/TP.0000000000001600]
- 250 **Lee HC**, Yoon SB, Yang SM, Kim WH, Ryu HG, Jung CW, Suh KS, Lee KH. Prediction of Acute Kidney Injury after Liver Transplantation: Machine Learning Approaches vs. Logistic Regression Model. *J Clin Med* 2018; **7** [PMID: 30413107 DOI: 10.3390/jcm7110428]
- 251 **Abajian A**, Murali N, Savic LJ, Laage-Gaupp FM, Nezami N, Duncan JS, Schlachter T, Lin M, Geschwind JF, Chapiro J. Predicting Treatment Response to Intra-arterial Therapies for Hepatocellular Carcinoma with the Use of Supervised Machine Learning-An Artificial Intelligence Concept. *J Vasc Interv Radiol* 2018; **29**: 850-857.e1 [PMID: 29548875 DOI: 10.1016/j.jvir.2018.01.769]
- 252 **Chaudhary K**, Poirion OB, Lu L, Garmire LX. Deep Learning-Based Multi-Omics Integration Robustly Predicts Survival in Liver Cancer. *Clin Cancer Res* 2018; **24**: 1248-1259 [PMID: 28982688 DOI: 10.1158/1078-0432.CCR-17-0853]
- 253 **Morshid A**, Elsayes KM, Khalaf AM, Elmohr MM, Yu J, Kaseb AO, Hassan M, Mahvash A, Wang Z, Hazle JD, Fuentes D. A machine learning model to predict hepatocellular carcinoma response to transcatheter arterial chemoembolization. *Radiol Artif Intell* 2019; **1** [PMID: 31858078 DOI: 10.1148/ryai.2019180021]
- 254 **Saillard C**, Schmauch B, Laifa O, Moarii M, Toldo S, Zaslavskiy M, Pronier E, Laurent A, Amadeo G, Regnault H, Sommacale D, Ziolo M, Pawlowsky JM, Mulé S, Luciani A, Wainrib G, Clozel T, Courtiol P, Calderaro J. Predicting Survival After Hepatocellular Carcinoma Resection Using Deep Learning on Histological Slides. *Hepatology* 2020; **72**: 2000-2013 [PMID: 32108950 DOI: 10.1002/hep.31207]
- 255 **Shan QY**, Hu HT, Feng ST, Peng ZP, Chen SL, Zhou Q, Li X, Xie XY, Lu MD, Wang W, Kuang M. CT-based peritumoral radiomics signatures to predict early recurrence in hepatocellular carcinoma after curative tumor resection or ablation. *Cancer Imaging* 2019; **19**: 11 [PMID: 30813956 DOI: 10.1186/s40644-019-0197-5]
- 256 **Eaton JE**, Vesterhus M, McCauley BM, Atkinson EJ, Schlicht EM, Juran BD, Gossard AA, LaRusso NF, Gores GJ, Karlsen TH, Lazaridis KN. Primary Sclerosing Cholangitis Risk Estimate Tool (PREsTo) Predicts Outcomes of the Disease: A Derivation and Validation Study Using Machine Learning. *Hepatology* 2020; **71**: 214-224 [PMID: 29742811 DOI: 10.1002/hep.30085]
- 257 **Garcia MS**, Agarwal B, Mookerjee RP, Jalan R, Doyle G, Ranco G, Arroyo V, Pavesi M, Garcia E, Saliba F, Banares R, Fernandez J. An Accurate Data Preparation Approach for the Prediction of Mortality in ACLF Patients using the CANONIC Dataset. *Annu Int Conf IEEE Eng Med Biol Soc* 2019; **2019**: 1371-1377 [PMID: 31946148 DOI: 10.1109/EMBC.2019.8857239]
- 258 **Ibragimov B**, Toesca D, Chang D, Yuan Y, Koong A, Xing L. Development of deep neural network for individualized hepatobiliary toxicity prediction after liver SBRT. *Med Phys* 2018; **45**: 4763-4774 [PMID: 30098025 DOI: 10.1002/mp.13122]
- 259 **Jovanovic P**, Salkic NN, Zerem E. Artificial neural network predicts the need for therapeutic ERCP in patients with suspected choledocholithiasis. *Gastrointest Endosc* 2014; **80**: 260-268 [PMID: 24593947 DOI: 10.1016/j.gie.2014.01.023]
- 260 **Kanwal F**, Taylor TJ, Kramer JR, Cao Y, Smith D, Gifford AL, El-Serag HB, Naik AD, Asch SM. Development, Validation, and Evaluation of a Simple Machine Learning Model to Predict Cirrhosis Mortality. *JAMA Netw Open* 2020; **3**: e2023780 [PMID: 33141161 DOI: 10.1001/jamanetworkopen.2020.23780]
- 261 **Speiser JL**, Karvellas CJ, Wolf BJ, Chung D, Koch DG, Durkalski VL. Predicting daily outcomes in acetaminophen-induced acute liver failure patients with machine learning techniques. *Comput Methods Programs Biomed* 2019; **175**: 111-120 [PMID: 31104700 DOI: 10.1016/j.cmpb.2019.04.012]
- 262 **Speiser JL**, Lee WM, Karvellas CJ; US Acute Liver Failure Study Group. Predicting outcome on admission and post-admission for acetaminophen-induced acute liver failure using classification and regression tree models. *PLoS One* 2015; **10**: e0122929 [PMID: 25885260 DOI: 10.1371/journal.pone.0122929]
- 263 **Konerman MA**, Lu D, Zhang Y, Thomson M, Zhu J, Verma A, Liu B, Talaat N, Balis U, Higgins PDR, Lok ASF, Waljee AK. Assessing risk of fibrosis progression and liver-related clinical outcomes among patients with both early stage and advanced chronic hepatitis C. *PLoS One* 2017; **12**: e0187344 [PMID: 29108017 DOI: 10.1371/journal.pone.0187344]
- 264 **Ai H**, Chen W, Zhang L, Huang L, Yin Z, Hu H, Zhao Q, Zhao J, Liu H. Predicting Drug-Induced Liver Injury Using Ensemble Learning Methods and Molecular Fingerprints. *Toxicol Sci* 2018; **165**: 100-107 [PMID: 29788510 DOI: 10.1093/toxsci/kfy121]
- 265 **Banerjee I**, Choi HH, Desser T, Rubin DL. A Scalable Machine Learning Approach for Inferring Probabilistic US-LI-RADS Categorization. *AMIA Annu Symp Proc* 2018; **2018**: 215-224 [PMID: 30815059]
- 266 **Dickerson LK**, Rouhizadeh M, Korotkaya Y, Bowring MG, Massie AB, McAdams-Demarco MA, Segev DL, Cannon A, Guerrero AL, Chen PH, Philoppe BN, Mogul DB. Language impairment in adults with end-stage liver disease: application of natural language processing towards patient-generated health records. *NPJ Digit Med* 2019; **2**: 106 [PMID: 31701020 DOI: 10.1038/s41746-019-0179-9]
- 267 **He L**, Li H, Dudley JA, Maloney TC, Brady SL, Somasundaram E, Trout AT, Dillman JR. Machine Learning Prediction of Liver Stiffness Using Clinical and T2-Weighted MRI Radiomic Data. *AJR Am J Roentgenol* 2019; **213**: 592-601 [PMID: 31120779 DOI: 10.2214/AJR.19.21082]

- 268 **Khan S**, Ullah R, Khan A, Ashraf R, Ali H, Bilal M, Saleem M. Analysis of hepatitis B virus infection in blood sera using Raman spectroscopy and machine learning. *Photodiagnosis Photodyn Ther* 2018; **23**: 89-93 [PMID: 29787817 DOI: 10.1016/j.pdpdt.2018.05.010]
- 269 **Li X**, Chen H, Qi X, Dou Q, Fu CW, Heng PA. H-DenseUNet: Hybrid Densely Connected UNet for Liver and Tumor Segmentation From CT Volumes. *IEEE Trans Med Imaging* 2018; **37**: 2663-2674 [PMID: 29994201 DOI: 10.1109/TMI.2018.2845918]
- 270 **Mueller-Breckenridge AJ**, Garcia-Alcalde F, Wildum S, Smits SL, de Man RA, van Campenhout MJH, Brouwer WP, Niu J, Young JAT, Najera I, Zhu L, Wu D, Racek T, Hundie GB, Lin Y, Boucher CA, van de Vijver D, Haagsmans BL. Machine-learning based patient classification using Hepatitis B virus full-length genome quasispecies from Asian and European cohorts. *Sci Rep* 2019; **9**: 18892 [PMID: 31827222 DOI: 10.1038/s41598-019-55445-8]
- 271 **Williams DP**, Lazic SE, Foster AJ, Semenova E, Morgan P. Predicting Drug-Induced Liver Injury with Bayesian Machine Learning. *Chem Res Toxicol* 2020; **33**: 239-248 [PMID: 31535850 DOI: 10.1021/acs.chemrestox.9b00264]
- 272 **Shousha HI**, Awad AH, Omran DA, Elnegouly MM, Mabrouk M. Data Mining and Machine Learning Algorithms Using IL28B Genotype and Biochemical Markers Best Predicted Advanced Liver Fibrosis in Chronic Hepatitis C. *Jpn J Infect Dis* 2018; **71**: 51-57 [PMID: 29279441 DOI: 10.7883/yoken.JJID.2017.089]
- 273 **Garcia-Carretero R**, Vigil-Medina L, Barquero-Perez O, Ramos-Lopez J. Relevant Features in Nonalcoholic Steatohepatitis Determined Using Machine Learning for Feature Selection. *Metab Syndr Relat Disord* 2019; **17**: 444-451 [PMID: 31675274 DOI: 10.1089/met.2019.0052]
- 274 **Ma H**, Xu CF, Shen Z, Yu CH, Li YM. Application of Machine Learning Techniques for Clinical Predictive Modeling: A Cross-Sectional Study on Nonalcoholic Fatty Liver Disease in China. *Biomed Res Int* 2018; **2018**: 4304376 [PMID: 30402478 DOI: 10.1155/2018/4304376]
- 275 **Moccia S**, Mattos LS, Patrini I, Ruperti M, Poté N, Dondero F, Cauchy F, Sepulveda A, Soubrane O, De Momi E, Diaspro A, Cesaretti M. Computer-assisted liver graft steatosis assessment via learning-based texture analysis. *Int J Comput Assist Radiol Surg* 2018; **13**: 1357-1367 [PMID: 29796834 DOI: 10.1007/s11548-018-1787-6]
- 276 **Perveen S**, Shahbaz M, Keshavjee K, Guergachi A. A Systematic Machine Learning Based Approach for the Diagnosis of Non-Alcoholic Fatty Liver Disease Risk and Progression. *Sci Rep* 2018; **8**: 2112 [PMID: 29391513 DOI: 10.1038/s41598-018-20166-x]
- 277 **Wu CC**, Yeh WC, Hsu WD, Islam MM, Nguyen PAA, Poly TN, Wang YC, Yang HC, Jack Li YC. Prediction of fatty liver disease using machine learning algorithms. *Comput Methods Programs Biomed* 2019; **170**: 23-29 [PMID: 30712601 DOI: 10.1016/j.cmpb.2018.12.032]
- 278 **Yip TC**, Ma AJ, Wong VW, Tse YK, Chan HL, Yuen PC, Wong GL. Laboratory parameter-based machine learning model for excluding non-alcoholic fatty liver disease (NAFLD) in the general population. *Aliment Pharmacol Ther* 2017; **46**: 447-456 [PMID: 28585725 DOI: 10.1111/apt.14172]
- 279 **Gorris M**, Hoogenboom SA, Wallace MB, van Hoof JE. Artificial intelligence for the management of pancreatic diseases. *Dig Endosc* 2021; **33**: 231-241 [PMID: 33065754 DOI: 10.1111/den.13875]
- 280 **Marya NB**, Powers PD, Chari ST, Gleeson FC, Leggett CL, Abu Dayyeh BK, Chandrasekhara V, Iyer PG, Majumder S, Pearson RK, Petersen BT, Rajan E, Sawas T, Storm AC, Vege SS, Chen S, Long Z, Hough DM, Mara K, Levy MJ. Utilisation of artificial intelligence for the development of an EUS-convolutional neural network model trained to enhance the diagnosis of autoimmune pancreatitis. *Gut* 2021; **70**: 1335-1344 [PMID: 33028668 DOI: 10.1136/gutjnl-2020-322821]
- 281 **Tonozuka R**, Mukai S, Itoi T. The Role of Artificial Intelligence in Endoscopic Ultrasound for Pancreatic Disorders. *Diagnostics (Basel)* 2020; **11** [PMID: 33374181 DOI: 10.3390/diagnostics11010018]
- 282 **van den Heever M**, Mittal A, Haydock M, Windsor J. The use of intelligent database systems in acute pancreatitis—a systematic review. *Pancreatol* 2014; **14**: 9-16 [PMID: 24555973 DOI: 10.1016/j.pan.2013.11.010]
- 283 **Andersson B**, Andersson R, Ohlsson M, Nilsson J. Prediction of severe acute pancreatitis at admission to hospital using artificial neural networks. *Pancreatol* 2011; **11**: 328-335 [PMID: 21757970 DOI: 10.1159/000327903]
- 284 **Fei Y**, Gao K, Li WQ. Artificial neural network algorithm model as powerful tool to predict acute lung injury following to severe acute pancreatitis. *Pancreatol* 2018; **18**: 892-899 [PMID: 30268673 DOI: 10.1016/j.pan.2018.09.007]
- 285 **Fei Y**, Gao K, Li WQ. Prediction and evaluation of the severity of acute respiratory distress syndrome following severe acute pancreatitis using an artificial neural network algorithm model. *HPB (Oxford)* 2019; **21**: 891-897 [PMID: 30591306 DOI: 10.1016/j.hpb.2018.11.009]
- 286 **Fei Y**, Hu J, Li WQ, Wang W, Zong GQ. Artificial neural networks predict the incidence of portosplenomesenteric venous thrombosis in patients with acute pancreatitis. *J Thromb Haemost* 2017; **15**: 439-445 [PMID: 27960048 DOI: 10.1111/jth.13588]
- 287 **Hong WD**, Chen XR, Jin SQ, Huang QK, Zhu QH, Pan JY. Use of an artificial neural network to predict persistent organ failure in patients with acute pancreatitis. *Clinics (Sao Paulo)* 2013; **68**: 27-31 [PMID: 23420153 DOI: 10.6061/clinics/2013(01)rc01]
- 288 **Keogan MT**, Lo JY, Freed KS, Raptopoulos V, Blake S, Kamel IR, Weisinger K, Rosen MP, Nelson RC. Outcome analysis of patients with acute pancreatitis by using an artificial neural network. *Acad Radiol* 2002; **9**: 410-419 [PMID: 11942655 DOI: 10.1016/s1076-6332(03)80186-1]
- 289 **Mofidi R**, Duff MD, Madhavan KK, Garden OJ, Parks RW. Identification of severe acute

- pancreatitis using an artificial neural network. *Surgery* 2007; **141**: 59-66 [PMID: 17188168 DOI: 10.1016/j.surg.2006.07.022]
- 290 **Pearce CB**, Gunn SR, Ahmed A, Johnson CD. Machine learning can improve prediction of severity in acute pancreatitis using admission values of APACHE II score and C-reactive protein. *Pancreatol* 2006; **6**: 123-131 [PMID: 16327290 DOI: 10.1159/000090032]
- 291 **Pofahl WE**, Walczak SM, Rhone E, Izenberg SD. Use of an artificial neural network to predict length of stay in acute pancreatitis. *Am Surg* 1998; **64**: 868-872 [PMID: 9731816 DOI: 10.1016/S0016-5085(98)81989-6]
- 292 **Qiu Q**, Nian YJ, Guo Y, Tang L, Lu N, Wen LZ, Wang B, Chen DF, Liu KJ. Development and validation of three machine-learning models for predicting multiple organ failure in moderately severe and severe acute pancreatitis. *BMC Gastroenterol* 2019; **19**: 118 [PMID: 31272385 DOI: 10.1186/s12876-019-1016-y]
- 293 **Qiu Q**, Nian YJ, Tang L, Guo Y, Wen LZ, Wang B, Chen DF, Liu KJ. Artificial neural networks accurately predict intra-abdominal infection in moderately severe and severe acute pancreatitis. *J Dig Dis* 2019; **20**: 486-494 [PMID: 31328389 DOI: 10.1111/1751-2980.12796]
- 294 **Al-Haddad MA**, Friedlin J, Kesterson J, Waters JA, Aguilar-Saavedra JR, Schmidt CM. Natural language processing for the development of a clinical registry: a validation study in intraductal papillary mucinous neoplasms. *HPB (Oxford)* 2010; **12**: 688-695 [PMID: 21083794 DOI: 10.1111/j.1477-2574.2010.00235.x]
- 295 **Gao X**, Wang X. Performance of deep learning for differentiating pancreatic diseases on contrast-enhanced magnetic resonance imaging: A preliminary study. *Diagn Interv Imaging* 2020; **101**: 91-100 [PMID: 31375430 DOI: 10.1016/j.diii.2019.07.002]
- 296 **Mashayekhi R**, Parekh VS, Faghhi M, Singh VK, Jacobs MA, Zaheer A. Radiomic features of the pancreas on CT imaging accurately differentiate functional abdominal pain, recurrent acute pancreatitis, and chronic pancreatitis. *Eur J Radiol* 2020; **123**: 108778 [PMID: 31846864 DOI: 10.1016/j.ejrad.2019.108778]
- 297 **Roth HR**, Lu L, Lay N, Harrison AP, Farag A, Sohn A, Summers RM. Spatial aggregation of holistically-nested convolutional neural networks for automated pancreas localization and segmentation. *Med Image Anal* 2018; **45**: 94-107 [PMID: 29427897 DOI: 10.1016/j.media.2018.01.006]
- 298 **Zhang J**, Zhu L, Yao L, Ding X, Chen D, Wu H, Lu Z, Zhou W, Zhang L, An P, Xu B, Tan W, Hu S, Cheng F, Yu H. Deep learning-based pancreas segmentation and station recognition system in EUS: development and validation of a useful training tool (with video). *Gastrointest Endosc* 2020; **92**: 874-885.e3 [PMID: 32387499 DOI: 10.1016/j.gie.2020.04.071]
- 299 **Zheng H**, Chen Y, Yue X, Ma C, Liu X, Yang P, Lu J. Deep pancreas segmentation with uncertain regions of shadowed sets. *Magn Reson Imaging* 2020; **68**: 45-52 [PMID: 31987903 DOI: 10.1016/j.mri.2020.01.008]
- 300 **Zhu J**, Wang L, Chu Y, Hou X, Xing L, Kong F, Zhou Y, Wang Y, Jin Z, Li Z. A new descriptor for computer-aided diagnosis of EUS imaging to distinguish autoimmune pancreatitis from chronic pancreatitis. *Gastrointest Endosc* 2015; **82**: 831-836.e1 [PMID: 25952089 DOI: 10.1016/j.gie.2015.02.043]
- 301 **Chu LC**, Park S, Kawamoto S, Fouladi DF, Shayesteh S, Zinreich ES, Graves JS, Horton KM, Hruban RH, Yuille AL, Kinzler KW, Vogelstein B, Fishman EK. Utility of CT Radiomics Features in Differentiation of Pancreatic Ductal Adenocarcinoma From Normal Pancreatic Tissue. *AJR Am J Roentgenol* 2019; **213**: 349-357 [PMID: 31012758 DOI: 10.2214/AJR.18.20901]
- 302 **Das A**, Nguyen CC, Li F, Li B. Digital image analysis of EUS images accurately differentiates pancreatic cancer from chronic pancreatitis and normal tissue. *Gastrointest Endosc* 2008; **67**: 861-867 [PMID: 18179797 DOI: 10.1016/j.gie.2007.08.036]
- 303 **Gao X**, Wang X. Deep learning for World Health Organization grades of pancreatic neuroendocrine tumors on contrast-enhanced magnetic resonance images: a preliminary study. *Int J Comput Assist Radiol Surg* 2019; **14**: 1981-1991 [PMID: 31555998 DOI: 10.1007/s11548-019-02070-5]
- 304 **Kaissis G**, Ziegelmayer S, Lohöfer F, Steiger K, Algül H, Muckenhuber A, Yen HY, Rummeny E, Friess H, Schmid R, Weichert W, Siveke JT, Braren R. A machine learning algorithm predicts molecular subtypes in pancreatic ductal adenocarcinoma with differential response to gemcitabine-based vs FOLFIRINOX chemotherapy. *PLoS One* 2019; **14**: e0218642 [PMID: 31577805 DOI: 10.1371/journal.pone.0218642]
- 305 **Kaissis GA**, Ziegelmayer S, Lohöfer FK, Harder FN, Jungmann F, Sasse D, Muckenhuber A, Yen HY, Steiger K, Siveke J, Friess H, Schmid R, Weichert W, Makowski MR, Braren RF. Image-Based Molecular Phenotyping of Pancreatic Ductal Adenocarcinoma. *J Clin Med* 2020; **9** [PMID: 32155990 DOI: 10.3390/jcm9030724]
- 306 **E L**, Xu Y, Wu Z, Li L, Zhang N, Yang H, Schwartz LH, Lu L, Zhao B. Differentiation of Focal-Type Autoimmune Pancreatitis From Pancreatic Ductal Adenocarcinoma Using Radiomics Based on Multiphasic Computed Tomography. *J Comput Assist Tomogr* 2020; **44**: 511-518 [PMID: 32697521 DOI: 10.1097/RCT.0000000000001049]
- 307 **Momeni-Boroujeni A**, Yousefi E, Somma J. Computer-assisted cytologic diagnosis in pancreatic FNA: An application of neural networks to image analysis. *Cancer Cytopathol* 2017; **125**: 926-933 [PMID: 28885766 DOI: 10.1002/cncy.21915]
- 308 **Norton ID**, Zheng Y, Wiersema MS, Greenleaf J, Clain JE, Dimagno EP. Neural network analysis of EUS images to differentiate between pancreatic malignancy and pancreatitis. *Gastrointest Endosc*

- 2001; **54**: 625-629 [PMID: [11677484](#) DOI: [10.1067/mge.2001.118644](#)]
- 309 **Qiu W**, Duan N, Chen X, Ren S, Zhang Y, Wang Z, Chen R. Pancreatic Ductal Adenocarcinoma: Machine Learning-Based Quantitative Computed Tomography Texture Analysis For Prediction Of Histopathological Grade. *Cancer Manag Res* 2019; **11**: 9253-9264 [PMID: [31802945](#) DOI: [10.2147/CMAR.S218414](#)]
- 310 **Săftoiu A**, Vilmann P, Dietrich CF, Iglesias-Garcia J, Hocke M, Seicean A, Ignee A, Hassan H, Streba CT, Ionică AM, Gheonea DI, Ciurea T. Quantitative contrast-enhanced harmonic EUS in differential diagnosis of focal pancreatic masses (with videos). *Gastrointest Endosc* 2015; **82**: 59-69 [PMID: [25792386](#) DOI: [10.1016/j.gie.2014.11.040](#)]
- 311 **Săftoiu A**, Vilmann P, Gorunescu F, Gheonea DI, Gorunescu M, Ciurea T, Popescu GL, Iordache A, Hassan H, Iordache S. Neural network analysis of dynamic sequences of EUS elastography used for the differential diagnosis of chronic pancreatitis and pancreatic cancer. *Gastrointest Endosc* 2008; **68**: 1086-1094 [PMID: [18656186](#) DOI: [10.1016/j.gie.2008.04.031](#)]
- 312 **Săftoiu A**, Vilmann P, Gorunescu F, Janssen J, Hocke M, Larsen M, Iglesias-Garcia J, Arcidiacono P, Will U, Giovannini M, Dietrich CF, Havre R, Gheorghe C, McKay C, Gheonea DI, Ciurea T; European EUS Elastography Multicentric Study Group. Efficacy of an artificial neural network-based approach to endoscopic ultrasound elastography in diagnosis of focal pancreatic masses. *Clin Gastroenterol Hepatol* 2012; **10**: 84-90.e1 [PMID: [21963957](#) DOI: [10.1016/j.cgh.2011.09.014](#)]
- 313 **Yeaton P**, Sears RJ, Ledet T, Salmon I, Kiss R, Decaestecker C. Discrimination between chronic pancreatitis and pancreatic adenocarcinoma using artificial intelligence-related algorithms based on image cytometry-generated variables. *Cytometry* 1998; **32**: 309-316 [PMID: [9701400](#) DOI: [10.1002/\(sici\)1097-0320\(19980801\)32:4<309::aid-cyto8>3.0.co;2-c](#)]
- 314 **Zhu M**, Xu C, Yu J, Wu Y, Li C, Zhang M, Jin Z, Li Z. Differentiation of pancreatic cancer and chronic pancreatitis using computer-aided diagnosis of endoscopic ultrasound (EUS) images: a diagnostic test. *PLoS One* 2013; **8**: e63820 [PMID: [23704940](#) DOI: [10.1371/journal.pone.0063820](#)]
- 315 **Luo Y**, Chen X, Chen J, Song C, Shen J, Xiao H, Chen M, Li ZP, Huang B, Feng ST. Preoperative Prediction of Pancreatic Neuroendocrine Neoplasms Grading Based on Enhanced Computed Tomography Imaging: Validation of Deep Learning with a Convolutional Neural Network. *Neuroendocrinology* 2020; **110**: 338-350 [PMID: [31525737](#) DOI: [10.1159/000503291](#)]
- 316 **Chakraborty J**, Midya A, Gazit L, Attiyeh M, Langdon-Embry L, Allen PJ, Do RKG, Simpson AL. CT radiomics to predict high-risk intraductal papillary mucinous neoplasms of the pancreas. *Med Phys* 2018; **45**: 5019-5029 [PMID: [30176047](#) DOI: [10.1002/mp.13159](#)]
- 317 **Corral JE**, Hussein S, Kandel P, Bolan CW, Bagci U, Wallace MB. Deep Learning to Classify Intraductal Papillary Mucinous Neoplasms Using Magnetic Resonance Imaging. *Pancreas* 2019; **48**: 805-810 [PMID: [31210661](#) DOI: [10.1097/MPA.0000000000001327](#)]
- 318 **Dmitriev K**, Kaufman AE, Javed AA, Hruban RH, Fishman EK, Lennon AM, Saltz JH. Classification of Pancreatic Cysts in Computed Tomography Images Using a Random Forest and Convolutional Neural Network Ensemble. *Med Image Comput Assist Interv* 2017; **10435**: 150-158 [PMID: [29881827](#) DOI: [10.1007/978-3-319-66179-7_18](#)]
- 319 **Kurita Y**, Kuwahara T, Hara K, Mizuno N, Okuno N, Matsumoto S, Obata M, Koda H, Tajika M, Shimizu Y, Nakajima A, Kubota K, Niwa Y. Diagnostic ability of artificial intelligence using deep learning analysis of cyst fluid in differentiating malignant from benign pancreatic cystic lesions. *Sci Rep* 2019; **9**: 6893 [PMID: [31053726](#) DOI: [10.1038/s41598-019-43314-3](#)]
- 320 **Kuwahara T**, Hara K, Mizuno N, Okuno N, Matsumoto S, Obata M, Kurita Y, Koda H, Toriyama K, Onishi S, Ishihara M, Tanaka T, Tajika M, Niwa Y. Usefulness of Deep Learning Analysis for the Diagnosis of Malignancy in Intraductal Papillary Mucinous Neoplasms of the Pancreas. *Clin Transl Gastroenterol* 2019; **10**: 1-8 [PMID: [31117111](#) DOI: [10.14309/ctg.0000000000000045](#)]
- 321 **Li H**, Shi K, Reichert M, Lin K, Tselousov N, Braren R, Fu D, Schmid R, Li J, Menze B. Differential Diagnosis for Pancreatic Cysts in CT Scans Using Densely-Connected Convolutional Networks. *Annu Int Conf IEEE Eng Med Biol Soc* 2019; **2019**: 2095-2098 [PMID: [31946314](#) DOI: [10.1109/EMBC.2019.8856745](#)]
- 322 **Okoń K**, Tomaszewska R, Nowak K, Stachura J. Application of neural networks to the classification of pancreatic intraductal proliferative lesions. *Anal Cell Pathol* 2001; **23**: 129-136 [PMID: [12082293](#) DOI: [10.1155/2001/657268](#)]
- 323 **Song JW**, Lee JH, Choi JH, Chun SJ. Automatic differential diagnosis of pancreatic serous and mucinous cystadenomas based on morphological features. *Comput Biol Med* 2013; **43**: 1-15 [PMID: [23200461](#) DOI: [10.1016/j.compbiomed.2012.10.009](#)]
- 324 **Springer S**, Masica DL, Dal Molin M, Douville C, Thoburn CJ, Afsari B, Li L, Cohen JD, Thompson E, Allen PJ, Klimstra DS, Schattner MA, Schmidt CM, Yip-Schneider M, Simpson RE, Fernandez-Del Castillo C, Mino-Kenudson M, Brugge W, Brand RE, Singhi AD, Scarpa A, Lawlor R, Salvia R, Zamboni G, Hong SM, Hwang DW, Jang JY, Kwon W, Swan N, Geoghegan J, Falconi M, Crippa S, Doglioni C, Paulino J, Schulick RD, Edil BH, Park W, Yachida S, Hijioka S, van Hooft J, He J, Weiss MJ, Burkhart R, Makary M, Canto MI, Goggins MG, Ptak J, Dobbyn L, Schaefer J, Sillman N, Popoli M, Klein AP, Tomasetti C, Karchin R, Papadopoulos N, Kinzler KW, Vogelstein B, Wolfgang CL, Hruban RH, Lennon AM. A multimodality test to guide the management of patients with a pancreatic cyst. *Sci Transl Med* 2019; **11** [PMID: [31316009](#) DOI: [10.1126/scitranslmed.aav4772](#)]
- 325 **Wei R**, Lin K, Yan W, Guo Y, Wang Y, Li J, Zhu J. Computer-Aided Diagnosis of Pancreas Serous Cystic Neoplasms: A Radiomics Method on Preoperative MDCT Images. *Technol Cancer Res Treat*

- 2019; **18**: 1533033818824339 [PMID: 30803366 DOI: 10.1177/1533033818824339]
- 326 **Yang J**, Guo X, Ou X, Zhang W, Ma X. Discrimination of Pancreatic Serous Cystadenomas From Mucinous Cystadenomas With CT Textural Features: Based on Machine Learning. *Front Oncol* 2019; **9**: 494 [PMID: 31245294 DOI: 10.3389/fonc.2019.00494]
- 327 **Blyuss O**, Zaikin A, Cherepanova V, Munblit D, Kiseleva EM, Prytomanova OM, Duffy SW, Crnogorac-Jurcevic T. Development of PancRISK, a urine biomarker-based risk score for stratified screening of pancreatic cancer patients. *Br J Cancer* 2020; **122**: 692-696 [PMID: 31857725 DOI: 10.1038/s41416-019-0694-0]
- 328 **Facciorusso A**, Del Prete V, Antonino M, Buccino VR, Muscatiello N. Response to repeat echoendoscopic celiac plexus neurolysis in pancreatic cancer patients: A machine learning approach. *Pancreatology* 2019; **19**: 866-872 [PMID: 31375433 DOI: 10.1016/j.pan.2019.07.038]
- 329 **Hayward J**, Alvarez SA, Ruiz C, Sullivan M, Tseng J, Whalen G. Machine learning of clinical performance in a pancreatic cancer database. *Artif Intell Med* 2010; **49**: 187-195 [PMID: 20483571 DOI: 10.1016/j.artmed.2010.04.009]
- 330 **Kaissis G**, Ziegelmayer S, Lohöfer F, Algül H, Eiber M, Weichert W, Schmid R, Friess H, Rummeny E, Ankerst D, Siveke J, Braren R. A machine learning model for the prediction of survival and tumor subtype in pancreatic ductal adenocarcinoma from preoperative diffusion-weighted imaging. *Eur Radiol Exp* 2019; **3**: 41 [PMID: 31624935 DOI: 10.1186/s41747-019-0119-0]
- 331 **Li K**, Xiao J, Yang J, Li M, Xiong X, Nian Y, Qiao L, Wang H, Eresen A, Zhang Z, Hu X, Wang J, Chen W. Association of radiomic imaging features and gene expression profile as prognostic factors in pancreatic ductal adenocarcinoma. *Am J Transl Res* 2019; **11**: 4491-4499 [PMID: 31396352]
- 332 **Walczak S**, Velanovich V. An Evaluation of Artificial Neural Networks in Predicting Pancreatic Cancer Survival. *J Gastrointest Surg* 2017; **21**: 1606-1612 [PMID: 28776157 DOI: 10.1007/s11605-017-3518-7]
- 333 **Xu W**, Liu Y, Lu Z, Jin ZD, Hu YH, Yu JG, Li ZS. A new endoscopic ultrasonography image processing method to evaluate the prognosis for pancreatic cancer treated with interstitial brachytherapy. *World J Gastroenterol* 2013; **19**: 6479-6484 [PMID: 24151368 DOI: 10.3748/wjg.v19.i38.6479]
- 334 **Zhang Y**, Lobo-Mueller EM, Karanicolas P, Gallinger S, Haider MA, Khalvati F. CNN-based survival model for pancreatic ductal adenocarcinoma in medical imaging. *BMC Med Imaging* 2020; **20**: 11 [PMID: 32013871 DOI: 10.1186/s12880-020-0418-1]
- 335 **Li S**, Jiang H, Wang Z, Zhang G, Yao YD. An effective computer aided diagnosis model for pancreas cancer on PET/CT images. *Comput Methods Programs Biomed* 2018; **165**: 205-214 [PMID: 30337075 DOI: 10.1016/j.cmpb.2018.09.001]
- 336 **Liu SL**, Li S, Guo YT, Zhou YP, Zhang ZD, Lu Y. Establishment and application of an artificial intelligence diagnosis system for pancreatic cancer with a faster region-based convolutional neural network. *Chin Med J (Engl)* 2019; **132**: 2795-2803 [PMID: 31856050 DOI: 10.1097/CM9.0000000000000544]
- 337 **Mehrabi S**, Krishnan A, Roch AM, Schmidt H, Li D, Kesterson J, Beesley C, Dexter P, Schmidt M, Palakal M, Liu H. Identification of Patients with Family History of Pancreatic Cancer--Investigation of an NLP System Portability. *Stud Health Technol Inform* 2015; **216**: 604-608 [PMID: 26262122]
- 338 **Ozkan M**, Cakiroglu M, Kocaman O, Kurt M, Yilmaz B, Can G, Korkmaz U, Dandil E, Eksi Z. Age-based computer-aided diagnosis approach for pancreatic cancer on endoscopic ultrasound images. *Endosc Ultrasound* 2016; **5**: 101-107 [PMID: 27080608 DOI: 10.4103/2303-9027.180473]
- 339 **Roch AM**, Mehrabi S, Krishnan A, Schmidt HE, Kesterson J, Beesley C, Dexter PR, Palakal M, Schmidt CM. Automated pancreatic cyst screening using natural language processing: a new tool in the early detection of pancreatic cancer. *HPB (Oxford)* 2015; **17**: 447-453 [PMID: 25537257 DOI: 10.1111/hpb.12375]
- 340 **Zhang MM**, Yang H, Jin ZD, Yu JG, Cai ZY, Li ZS. Differential diagnosis of pancreatic cancer from normal tissue with digital imaging processing and pattern recognition based on a support vector machine of EUS images. *Gastrointest Endosc* 2010; **72**: 978-985 [PMID: 20855062 DOI: 10.1016/j.gie.2010.06.042]
- 341 **Liu X**, Rivera SC, Moher D, Calvert MJ, Denniston AK; SPIRIT-AI and CONSORT-AI Working Group. Reporting guidelines for clinical trial reports for interventions involving artificial intelligence: the CONSORT-AI Extension. *BMJ* 2020; **370**: m3164 [PMID: 32909959 DOI: 10.1136/bmj.m3164]
- 342 **Krittana Wong C**, Johnson KW, Rosenson RS, Wang Z, Aydar M, Baber U, Min JK, Tang WHW, Halperin JL, Narayan SM. Deep learning for cardiovascular medicine: a practical primer. *Eur Heart J* 2019; **40**: 2058-2073 [PMID: 30815669 DOI: 10.1093/eurheartj/ehz056]



Published by **Baishideng Publishing Group Inc**
7041 Koll Center Parkway, Suite 160, Pleasanton, CA 94566, USA
Telephone: +1-925-3991568
E-mail: bpgoffice@wjgnet.com
Help Desk: <https://www.f6publishing.com/helpdesk>
<https://www.wjgnet.com>

