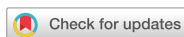

Original Article  
Oncology & Hematology



# Natural Progression of Ground-glass Nodules after Curative Resection for Non-small Cell Lung Cancer

Kanghoon Lee ,<sup>1</sup> Hyeong Ryul Kim ,<sup>2</sup> Seung-Il Park ,<sup>2</sup> Dong Kwan Kim ,<sup>2</sup> Yong-Hee Kim ,<sup>2</sup> Sehoon Choi ,<sup>2</sup> and Geun Dong Lee <sup>2</sup>

<sup>1</sup>Department of Thoracic and Cardiovascular Surgery, International St. Mary's Hospital, Catholic Kwandong University, College of Medicine, Incheon, Korea

<sup>2</sup>Department of Thoracic and Cardiovascular Surgery, Asan Medical Center, University of Ulsan College of Medicine, Seoul, Korea



Received: Jun 15, 2021

Accepted: Sep 3, 2021

**Address for Correspondence:**

Hyeong Ryul Kim, MD, PhD

Department of Thoracic and Cardiovascular Surgery, Asan Medical Center, University of Ulsan College of Medicine, 88 Olympic-ro 43-gil, Songpa-gu, Seoul 05505, Korea.  
E-mail: friendlykill@hanmail.net

© 2021 The Korean Academy of Medical Sciences.

This is an Open Access article distributed under the terms of the Creative Commons Attribution Non-Commercial License (<https://creativecommons.org/licenses/by-nc/4.0/>) which permits unrestricted non-commercial use, distribution, and reproduction in any medium, provided the original work is properly cited.

**ORCID iDs**

Kanghoon Lee   
<https://orcid.org/0000-0001-5811-5407>  
Hyeong Ryul Kim   
<https://orcid.org/0000-0002-6691-7693>  
Seung-Il Park   
<https://orcid.org/0000-0002-8729-0498>  
Dong Kwan Kim   
<https://orcid.org/0000-0003-1984-0352>  
Yong-Hee Kim   
<https://orcid.org/0000-0003-2177-4876>  
Sehoon Choi   
<https://orcid.org/0000-0002-9961-9289>  
Geun Dong Lee   
<https://orcid.org/0000-0003-1890-7455>

**Disclosure**

The authors have no potential conflicts of interest to disclose.

## ABSTRACT

**Background:** This retrospective study investigated the natural course of synchronous ground-glass nodules (GGNs) that remained after curative resection for non-small-cell lung cancer (NSCLC).

**Methods:** Prospectively collected retrospective data were reviewed concerning 2,276 patients who underwent curative resection for NSCLC between 2008 and 2017. High-resolution computed tomography or thin-section computed tomography data of 82 patients were included in the study. Growth in size was considered the most valuable outcome, and patients were grouped according to GGN size change. Patient demographic data (e.g., age, sex, and smoking history), perioperative data (e.g., GGN characteristics, histopathology and pathological stage of the resected tumours), and other medical history were evaluated in a risk factor analysis concerning GGN size change.

**Results:** The median duration of follow-up was 36.0 months (interquartile range, 23.0–59.3 months). GGN size decreased in 6 patients (7.3%), was stationary in 43 patients (52.4%), and increased in 33 patients (40.2%). In univariate analysis, male sex, the GGN size on initial CT, part-solid GGN and smoking history ( $\geq 10$  pack-years) were significant risk factors. Among them, multivariate analysis revealed that larger GGN size, part-solid GGN and smoking history were independent risk factors.

**Conclusion:** During follow-up, 40.2% of GGNs increased in size, emphasising that patients with larger GGNs, part-solid GGN or with a smoking history should be observed.

**Keywords:** Ground-Glass Nodule; Lung Cancer; Computed Tomography

## INTRODUCTION

Lung cancer is one of the most common causes of cancer death. Several clinical trials of lung cancer screening using low-dose computed tomography (CT) have demonstrated a significant reduction in lung cancer mortality.<sup>1,2</sup> The presentation of the Dutch/Belgian Nederland-Leuven Longkanker screenings Onderzoek (NELSON) trial at the World Conference on Lung Cancer in 2018 reported decreased mortality in women (39–61%).<sup>3</sup> Furthermore, lung cancer screening using low-dose CT has additional benefits of early detection of other diseases.<sup>4,5</sup>

**Author Contributions**

Conceptualization: Kim HR. Data curation: Lee K. Formal analysis: Lee K. Investigation: Lee K. Methodology: Kim HR, Lee K. Resources: Kim HR, Park SI, Kim DK, Kim YH, Choi SH, Lee GD. Writing - original draft: Lee K. Writing - review & editing: Kim HR.

The increasing frequency of lung cancer screening has led to increased detection of ground-glass nodules (GGNs).<sup>6-8</sup> GGNs are lung nodules with a hazy increased attenuation indicative of preserved underlying bronchiolar or vascular structure, and their volume-doubling time is reportedly 769–1,005 days.<sup>9</sup> Although there is a concern of overdiagnosis,<sup>10</sup> stable or slowly growing GGNs are often associated with adenocarcinoma.<sup>11,12</sup> According to the Early Lung Cancer Action Project study, subsolid nodules have a higher incidence of malignancy than do solid nodules, and part-solid nodules have the highest incidence of malignancy (63%).<sup>1</sup>

Although several studies have provided new data concerning the natural course of subsolid pulmonary nodules (i.e., GGNs), there is no definitive protocol for the treatment of accompanying GGNs encountered during curative resection for NSCLC. The current Fleischner Society guidelines are not indicated for patients with a history of malignancy,<sup>13</sup> presumably due to the lack of data concerning the natural course of accompanying GGNs. There is evidence that a history of lung cancer is a major risk factor for GGN growth.<sup>1,9,14</sup> Thus, to determine a follow-up strategy, there is a need to examine the natural course of accompanying GGNs that remain after curative resection for lung cancer.

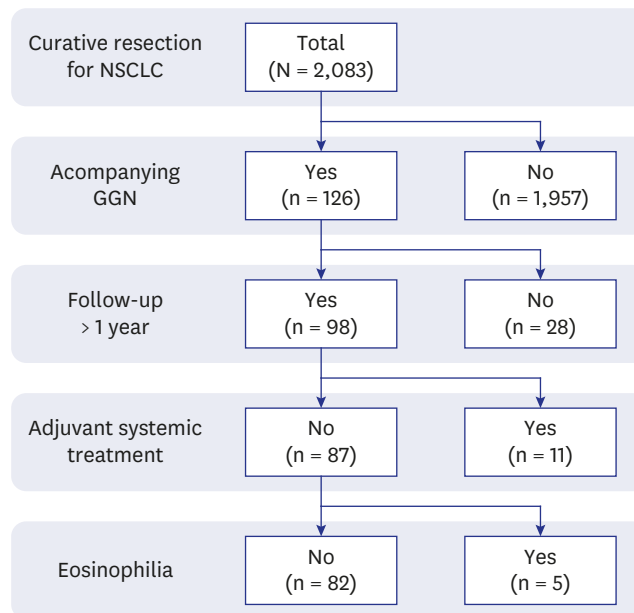
The primary purpose of this study was to review the natural course of synchronous accompanying GGNs found outside the dominant primary lung cancer, and the secondary purpose was to determine which clinical and radiological factors constitute risk factors for the growth of such GGNs.

## METHODS

In total, 2,083 patients underwent curative resection for lung cancer between July 2009 and February 2018. Among these, the data of 126 patients who had synchronous accompanying GGNs were collected prospectively. In this study, we reviewed the retrospective data of 82 patients who had been followed up for more than 1 year (**Fig. 1**). We obtained informed consent from each patient for the storage of medical data, together with consent for surgery.

Contrast-enhanced CT, [F-18] fluorodeoxyglucose positron emission tomography-CT, contrast-enhanced magnetic resonance imaging of the brain, bone scans, and pulmonary function testing (including assessment of diffusion capacity) were performed on all patients during preoperative evaluations. In addition, endobronchial ultrasound-transbronchial needle aspiration was performed when nodal metastasis was suspected. Patients who had pulmonary metastasis were excluded from this study.

The general principles of surgical resection were to resect all suspected malignant lesions, and the extent of resection was often discussed with a multidisciplinary team. Generally, the extent of surgical resection was determined on the basis of tumour stage, estimated postoperative pulmonary function, preoperative comorbidities, and tumour location. In addition, the distribution of lesions was an important consideration during the resection of multiple primary lesions. Lobar resections were primarily preferred, but sublobar resections were conducted in selected instances (e.g., a patient diagnosed with clinical stage cT1a by 7th-edition staging, or a patient with poor lung function or general condition). If a patient had sufficient pulmonary function and seemed capable of tolerating bilateral resection, two-stage simultaneous bilateral surgical resection was performed. Thus, only small GGNs with unknown significance remained for subsequent follow-up.



**Fig. 1.** Flow diagram of patient enrolment.  
NSCLC = non-small-cell lung cancer, GGN = ground-glass nodule.

In the first 2 years after surgery, patients visited the outpatient clinic at 3-month intervals for a history, plain chest radiography, and a physical examination. Chest CT scans were performed at 6-month intervals for up to 5 years after surgery. Then, follow-up CT scans were continued annually. Each CT scan included a high-resolution CT scan or a thin-section CT scan.

For person-based analyses, tumour size was determined based on the largest GGN. The size of a GGN was measured as the longest length in any section on a three-dimensional reconstructed CT scan. Definitions of GGN growth were a  $\geq 2$ -mm increase in total size,  $\geq 1$ -mm increase in solid component size, or the development of a new solid component.<sup>9,14</sup> Although changes in GGN numbers were closely followed, this study considered nodule size to be a more significant outcome. The clinical and pathological stages were reclassified in accordance with the 8th edition of the TNM classification for lung cancer.<sup>15</sup> Histopathological diagnoses were reclassified in accordance with the 2015 World Health Organization classification of lung tumours.<sup>16</sup>

Categorical variables are expressed as numbers and percentages, and were compared using the  $\chi^2$  test or Fisher's exact test. Continuous values that exhibited normal distributions are expressed as means and standard deviations. Continuous values that did not exhibit normal distributions are expressed as medians and interquartile ranges. Student's *t*-test and the Mann-Whitney *U* test were used to evaluate differences between continuous variables, depending on the results of the Shapiro-Wilk normality test. Logistic regression was used for multivariate analyses. Two-sided *P* values  $< 0.05$  were considered statistically significant. All statistical analyses were performed using IBM SPSS Statistics, version 22.0 (IBM Corp. Armonk, NY, USA).

### Ethics statement

This retrospective study was approved by the Institutional Review Board of the Asan Medical Center, Seoul, Republic of Korea, and the need for informed consent was waived (S2018-2025-0001).

## RESULTS

The clinical characteristics of the included patients are shown in **Table 1**. There were 41 women and 41 men, and their mean age was  $61.0 \pm 8.7$  years. Fifty-one patients (62.2%) were never-smokers, and 20 patients (24.4%) had one or more histories of other malignancies. Multiple lesions were resected during the first operation in 21 of 82 patients (25.6%), and all lesions were classified as adenocarcinoma. Most of the patients with multiple tumours had one or more lepidic-type adenocarcinomas or atypical adenomatous hyperplasia (19 of 21; 90.5%).

The characteristics of the accompanying GGNs (each patient's largest GGN) are shown in **Table 2**. Fourteen patients (17.1%) had GGNs with a solid component, 16 had three or more remnant GGNs, and the GGN size was  $< 10$  mm in 55 patients. In addition, the distribution of the remaining multiple GGNs (three or more) was limited to a single lobe in 7 patients.

The median duration of follow-up was 36.0 months (interquartile range, 23.0–59.3 months). No patient died during follow-up, but Tumour recurrence was observed in five patients. The natural courses of the accompanying GGNs are shown in **Fig. 2**. During the follow-up period, a decrease in GGN size was observed in only 6 patients (7.3%, group A) and no change in GGN size was detected in approximately half of the patients (43 of 82, 52.4%, group B). GGNs increased in size in 33 patients (40.2%, group C), and there was no statistical difference of follow-up period between the groups B and C ( $P = 0.259$ ).

**Table 1.** Baseline characteristics and operative outcomes of the patients

Characteristics	No. of patients (%) (n = 82)
Age at diagnosis, yr	61.0 $\pm$ 8.7
Sex	
Female	41 (50.0)
Male	41 (50.0)
Smoking	
< 10 pack-years	56 (68.3)
$\geq$ 10 pack-years	26 (31.7)
History of malignancy	
No	62 (75.6)
Yes	20 (24.4)
Multiple tumour resection during the first surgery	
No	61 (74.4)
Yes	21 (25.6)
Pathophysiology of resected tumour	
Adenocarcinoma	78 (95.1)
Others	4 (4.9)

Values are expressed as mean  $\pm$  standard deviation or number (%).

**Table 2.** GGN characteristics

Characteristics	No. of patients (%) (n = 82)
GGN type	
Pure	68 (82.9)
Part-solid	14 (17.1)
GGN size on initial CT scan, mm	8.6 $\pm$ 4.8
No. of GGNs	
1–2	66 (80.5)
$\geq$ 3	16 (19.5)
Multiple GGNs in one lobe	
No	75 (91.5)
Yes	7 (8.5)

Values are expressed as mean  $\pm$  standard deviation or number (%).

GGN = ground-glass nodule.

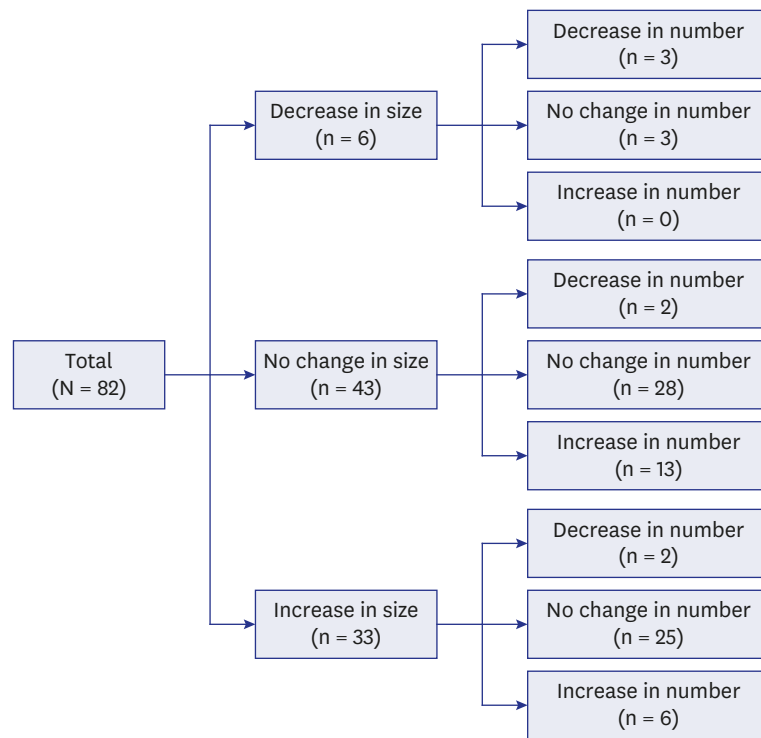


Fig. 2. Natural course of accompanying GGNs. GGN = ground-glass nodule.

Among these 33 patients with increased GGN, three underwent a second surgery for GGNs that increased in size, and all three were diagnosed with adenocarcinoma; however, the type of adenocarcinoma differed from the tumour resected during the first surgery (second primary adenocarcinoma) (Table 3). Five patients could not undergo a second surgery due to tumour recurrence. Six patients are now under consideration for a second surgery (including two patients who refuse second surgery), and the remaining 19 patients are continuing follow-up because their GGNs remain < 2 cm.

Univariate analysis indicated that male sex, larger GGN size, part-solid GGN and smoking history were significant risk factors (Table 4). Of these, larger GGN size, part-solid GGN and smoking history remained independent prognostic factors in the multivariate analysis (Table 5). We performed a receiver operating characteristic curve analysis to determine the cut-off value of the GGN size and to predict the growth of GGNs. A cut-off value of ≥ 8 mm was optimal, with an area under the receiver operating characteristic curve of 0.74. The respective sensitivity and specificity were 72.7% and 65.3% with a cut-off value of 8 mm and 93.9% and 40.8% with a cut-off value of 6 mm (Fig. 3).

Table 3. Pathological outcomes of the second surgery

Patient	Operation interval	Operation content and pathology of first surgery	Operation content and pathology of second surgery
#1	12 months	VATS lobectomy - Lepidic 100%	VATS wedge resection - Papillary 100%
#2	14 months	VATS lobectomy - #1. Acinar 60%, papillary 40% - #2. Papillary 90%, lepidic 10%	VATS segmentectomy - Lepidic 100%
#3	21 months	VATS wedge resection - Lepidic 60%, acinar 40%	VATS wedge resection - Papillary 50%, acinar 30%, lepidic 20%

Follow-up duration from the first surgery.  
VATS = video-assisted thoracic surgery.

**Table 4.** Univariate analysis of GGN growth

Variables	No. size change (n = 49)	Increased in size (n = 33)	P value
Age, yr	59.7 ± 9.0	63.0 ± 7.9	0.089 <sup>a</sup>
Sex			0.013 <sup>b</sup>
Female	30	11	
Male	19	22	
GGN size on initial CT scan, mm	7.2 ± 3.9	10.7 ± 5.2	0.001 <sup>a</sup>
GGN type			0.015 <sup>c</sup>
Pure GGN	45	23	
Part-solid GGN	4	10	
No. of GGNs			0.803 <sup>b</sup>
1-2	39	27	
≥ 3	10	6	
Smoking			0.007 <sup>b</sup>
< 10 pack-years	39	17	
≥ 10 pack-years	10	16	
History of other cancer			0.122 <sup>b</sup>
No	40	22	
Yes	9	11	
Multiple GGNs in one lobe	43	32	0.143 <sup>b</sup>
	6	1	

Values are expressed as mean ± standard deviation or number.

GGN = ground-glass nodule.

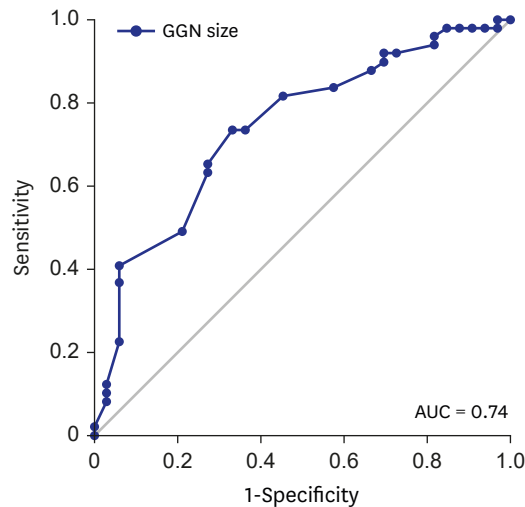
<sup>a</sup>Student's *t*-test; <sup>b</sup>χ<sup>2</sup> test; <sup>c</sup>Fisher's exact test.

**Table 5.** Multivariate binary logistic analysis of GGN growth

Variables	HR	CI	P value
Male sex	1.50	0.37-6.19	0.570
Part-solid GGN	4.96	1.21-20.37	0.026
GGN Size on initial CT scan	1.16	1.02-1.30	0.019
Smoking <sup>a</sup>	3.94	1.34-11.61	0.013

GGN = ground-glass nodule, HR = hazard ratio, CI = confidence interval.

<sup>a</sup>Smoking history more than 10 pack-years.



**Fig. 3.** Receiver operating characteristic curve analysis. GGN = ground-glass nodule, AUC = area under the curve.

## DISCUSSION

It is highly expected that lung cancer screening using low-dose CT will be a new standard healthcare strategy because of the positive results in clinical trials. This is because detection

of multiple primary lung cancers or the dominant tumour with accompanying GGNs will increase. Given a previous genetic study concerning lepidic-type adenocarcinoma, accompanying GGNs are highly expected to be multifocal, independent tumours.<sup>17</sup>

However, it is not technically feasible to resect all accompanying GGNs simultaneously, particularly when multiple small GGNs are scattered in bilateral lungs or when a GGN is centrally located on the contralateral side. Because resecting the dominant tumour with multiple accompanying GGNs has comparable survival outcomes, surgical resection maintains its role in primary treatment.<sup>18,19</sup> The reported mean volume-doubling time of GGNs is 769–1,005 days<sup>6,20</sup>; thus, follow-up without resection of accompanying GGNs is a reasonable approach. Lee et al.<sup>21</sup> reported that 9% of part-solid GGNs were upstaged from T1a to T1b (classified by the 7th American Joint Committee on Cancer staging system) during the follow-up period, but no significant decreases in disease-free or overall survival were observed.

Several studies have attempted to identify clinical factors or radiological findings related to the prognosis of synchronous or metachronous GGNs.<sup>9,22-24</sup> However, the results of those studies were inconsistent, potentially because of differences in study design, the characteristics of the study population, management strategy, or the definitions of variables and outcomes. Our study was a person-based study<sup>9</sup> confined to accompanying GGNs,<sup>23</sup> and focused on GGN size changes. In clinical practice, it is important to identify patients at greater risk of second surgery. Therefore, we presumed that GGN growth is clinically more significant (for determining second-surgery status) than an increase in GGN number (i.e., newly emerged small metachronous GGNs).

In our study, larger GGN size was a risk factor for GGN growth, as in previous studies.<sup>9,23</sup> The cut-off value of our study (8 mm) was similar to the findings of previous studies. Also, the presence of a part-solid GGN yielded results consistent with those reported in previous studies.<sup>9,24</sup> Smoking was an independent risk factor for GGN growth in our study. Most of our patients were diagnosed with adenocarcinoma in primary tumours (95.1%). Adenocarcinoma with a GGN pattern generally exhibits a weak association with smoking. However, several studies have reported paradoxical effects of smoking on GGN growth, which is consistent with our results.<sup>25</sup>

Some limitations of our study should be discussed. First, this person-based retrospective study focused on the largest GGN and the change in its size, which created difficulty when comparing outcomes directly with other studies. Second, the small sample size and heterogeneity of the patient population might have affected the study outcomes. Third, the follow-up duration was short, which may have influenced patient outcomes. Fourth, because of the short follow-up duration, small numbers of patients underwent a second surgery, resulting in a smaller number of pathologically confirmed GGNs that increased in size.

In conclusion, among patients who underwent curative resection for lung cancer, 6.0% had accompanying GGNs that could not be resected simultaneously. Growth of the accompanying GGNs was observed in 40.2% of patients, and the pathological results for the three resected GGNs differed from those of the primary tumours in those patients. The GGN size, part-solid GGN and smoking history were independent risk factors that influenced GGN growth. Careful follow-up is needed in patients with these characteristics after resection of the primary tumour.

## REFERENCES

1. National Lung Screening Trial Research Team, Aberle DR, Adams AM, Berg CD, Black WC, Clapp JD, et al. Reduced lung-cancer mortality with low-dose computed tomographic screening. *N Engl J Med* 2011;365(5):395-409.  
[PUBMED](#) | [CROSSREF](#)
2. Pastorino U, Silva M, Sestini S, Sabia F, Boeri M, Cantarutti A, et al. Prolonged lung cancer screening reduced 10-year mortality in the MILD trial: new confirmation of lung cancer screening efficacy. *Ann Oncol* 2019;30(10):1672.  
[PUBMED](#) | [CROSSREF](#)
3. De Koning H, Van Der Aalst C, Ten Haaf K, Oudker M. PL02.05 Effects of volume CT lung cancer screening: mortality results of the NELSON randomised-controlled population based trial. *J Thorac Oncol* 2018;13(10):S185.  
[CROSSREF](#)
4. Henschke CI, Lee IJ, Wu N, Farooqi A, Khan A, Yankelevitz D, et al. CT screening for lung cancer: prevalence and incidence of mediastinal masses. *Radiology* 2006;239(2):586-90.  
[PUBMED](#) | [CROSSREF](#)
5. Takx RA, Išgum I, Willemink MJ, van der Graaf Y, de Koning HJ, Vliegenthart R, et al. Quantification of coronary artery calcium in nongated CT to predict cardiovascular events in male lung cancer screening participants: results of the NELSON study. *J Cardiovasc Comput Tomogr* 2015;9(1):50-7.  
[PUBMED](#) | [CROSSREF](#)
6. Park CM, Goo JM, Lee HJ, Lee CH, Chun EJ, Im JG. Nodular ground-glass opacity at thin-section CT: histologic correlation and evaluation of change at follow-up. *Radiographics* 2007;27(2):391-408.  
[PUBMED](#) | [CROSSREF](#)
7. Nakata M, Saeki H, Takata I, Segawa Y, Mogami H, Mandai K, et al. Focal ground-glass opacity detected by low-dose helical CT. *Chest* 2002;121(5):1464-7.  
[PUBMED](#) | [CROSSREF](#)
8. Sone S, Takashima S, Li F, Yang Z, Honda T, Maruyama Y, et al. Mass screening for lung cancer with mobile spiral computed tomography scanner. *Lancet* 1998;351(9111):1242-5.  
[PUBMED](#) | [CROSSREF](#)
9. Cho J, Kim ES, Kim SJ, Lee YJ, Park JS, Cho YJ, et al. Long-term follow-up of small pulmonary ground-glass nodules stable for 3 years: implications of the proper follow-up period and risk factors for subsequent growth. *J Thorac Oncol* 2016;11(9):1453-9.  
[PUBMED](#) | [CROSSREF](#)
10. Godoy MC, Naidich DP. Subsolid pulmonary nodules and the spectrum of peripheral adenocarcinomas of the lung: recommended interim guidelines for assessment and management. *Radiology* 2009;253(3):606-22.  
[PUBMED](#) | [CROSSREF](#)
11. Henschke CI, Yankelevitz DE, Mirtcheva R, McGuinness G, McCauley D, Miettinen OS, et al. CT screening for lung cancer: frequency and significance of part-solid and nonsolid nodules. *AJR Am J Roentgenol* 2002;178(5):1053-7.  
[PUBMED](#) | [CROSSREF](#)
12. Kobayashi Y, Mitsudomi T. Management of ground-glass opacities: should all pulmonary lesions with ground-glass opacity be surgically resected? *Transl Lung Cancer Res* 2013;2(5):354-63.  
[PUBMED](#) | [CROSSREF](#)
13. MacMahon H, Naidich DP, Goo JM, Lee KS, Leung AN, Mayo JR, et al. Guidelines for management of incidental pulmonary nodules detected on CT images: from the Fleischner Society 2017. *Radiology* 2017;284(1):228-43.  
[PUBMED](#) | [CROSSREF](#)
14. Hiramatsu M, Inagaki T, Inagaki T, Matsui Y, Satoh Y, Okumura S, et al. Pulmonary ground-glass opacity (GGO) lesions-large size and a history of lung cancer are risk factors for growth. *J Thorac Oncol* 2008;3(11):1245-50.  
[PUBMED](#) | [CROSSREF](#)
15. Goldstraw P, Chansky K, Crowley J, Rami-Porta R, Asamura H, Eberhardt WE, et al. The IASLC Lung Cancer Staging Project: proposals for revision of the TNM stage groupings in the forthcoming (Eighth) edition of the TNM classification for lung cancer. *J Thorac Oncol* 2016;11(1):39-51.  
[PUBMED](#) | [CROSSREF](#)
16. Travis WD, Brambilla E, Nicholson AG, Yatabe Y, Austin JHM, Beasley MB, et al. The 2015 World Health Organization classification of lung tumors: impact of genetic, clinical and radiologic advances since the 2004 classification. *J Thorac Oncol* 2015;10(9):1243-60.  
[PUBMED](#) | [CROSSREF](#)



17. Beasley MB, Brambilla E, Travis WD. The 2004 World Health Organization classification of lung tumors. *Semin Roentgenol* 2005;40(2):90-7.  
[PUBMED](#) | [CROSSREF](#)
18. Gu B, Burt BM, Merritt RE, Stephanie S, Nair V, Hoang CD, et al. A dominant adenocarcinoma with multifocal ground glass lesions does not behave as advanced disease. *Ann Thorac Surg* 2013;96(2):411-8.  
[PUBMED](#) | [CROSSREF](#)
19. Shimada Y, Saji H, Otani K, Maehara S, Maeda J, Yoshida K, et al. Survival of a surgical series of lung cancer patients with synchronous multiple ground-glass opacities, and the management of their residual lesions. *Lung Cancer* 2015;88(2):174-80.  
[PUBMED](#) | [CROSSREF](#)
20. Chang B, Hwang JH, Choi YH, Chung MP, Kim H, Kwon OJ, et al. Natural history of pure ground-glass opacity lung nodules detected by low-dose CT scan. *Chest* 2013;143(1):172-8.  
[PUBMED](#) | [CROSSREF](#)
21. Lee JH, Park CM, Kim H, Hwang EJ, Park J, Goo JM. Persistent part-solid nodules with solid part of 5 mm or smaller: can the 'follow-up and surgical resection after interval growth' policy have a negative effect on patient prognosis? *Eur Radiol* 2017;27(1):195-202.  
[PUBMED](#) | [CROSSREF](#)
22. Kim HK, Choi YS, Kim J, Shim YM, Lee KS, Kim K. Management of multiple pure ground-glass opacity lesions in patients with bronchioloalveolar carcinoma. *J Thorac Oncol* 2010;5(2):206-10.  
[PUBMED](#) | [CROSSREF](#)
23. Kim HK, Choi YS, Kim K, Shim YM, Jeong SY, Lee KS, et al. Management of ground-glass opacity lesions detected in patients with otherwise operable non-small cell lung cancer. *J Thorac Oncol* 2009;4(10):1242-6.  
[PUBMED](#) | [CROSSREF](#)
24. Kim HS, Lee HJ, Jeon JH, Seong YW, Park IK, Kang CH, et al. Natural history of ground-glass nodules detected on the chest computed tomography scan after major lung resection. *Ann Thorac Surg* 2013;96(6):1952-7.  
[PUBMED](#) | [CROSSREF](#)
25. Kobayashi Y, Ambrogio C, Mitsudomi T. Ground-glass nodules of the lung in never-smokers and smokers: clinical and genetic insights. *Transl Lung Cancer Res* 2018;7(4):487-97.  
[PUBMED](#) | [CROSSREF](#)