



Since January 2020 Elsevier has created a COVID-19 resource centre with free information in English and Mandarin on the novel coronavirus COVID-19. The COVID-19 resource centre is hosted on Elsevier Connect, the company's public news and information website.

Elsevier hereby grants permission to make all its COVID-19-related research that is available on the COVID-19 resource centre - including this research content - immediately available in PubMed Central and other publicly funded repositories, such as the WHO COVID database with rights for unrestricted research re-use and analyses in any form or by any means with acknowledgement of the original source. These permissions are granted for free by Elsevier for as long as the COVID-19 resource centre remains active.

Prevalence and Clinical Implications of COVID-19 Myocarditis



Cristina Chimenti, MD, PhD^{a,b,*}, Michele Magnocavallo, MD^a, Federico Ballatore, MD^a, Federico Bernardini, MD^a, Maria Alfarano, MD^a, Domenico G. Della Rocca, MD, PhD^c, Paolo Severino, MD, PhD^a, Carlo Lavallo, MD^a, Fedele Francesco, MD^a, Andrea Frustaci, MD^{a,b}

KEYWORDS

• COVID-19 • Myocarditis • Myocardial damage • Arrhythmias • Vascular damage • SARS-CoV-2

KEY POINTS

- Cardiac involvement is frequent in patients with COVID-19, and myocarditis represents one of the most recurrent clinical manifestations.
- Pathophysiology of myocarditis is still understood; direct viral damage or cell-mediated cytotoxicity are the 2 likely mechanisms.
- Cardiac magnetic resonance (CMR) represents the most important diagnostic tool, and diffuse edema may be considered the only CMR hallmark of COVID-19 myocarditis.
- The management of COVID-19 myocarditis is firstly finalized to provide supportive care for heart failure and prevention of lethal cardiac arrhythmias.

INTRODUCTION

In December 2019 the first case of coronavirus disease 2019 (COVID-19) was described in Wuhan, China, in a patient complaining of flulike symptoms.¹ The pathogen has been recognized as a novel enveloped RNA β -coronavirus, named severe acute respiratory syndrome coronavirus 2 (SARS-CoV-2).

The clinical manifestations of COVID-19 are widely variable ranging from asymptomatic infection to multiorgan failure and death. Although the clinical course of SARS-CoV-2 infection is mostly characterized by respiratory involvement, ranging from mild influenzalike illness to acute respiratory distress syndrome, it soon became evident that COVID-19 affects multiple organ systems, including

the cardiovascular system.²⁻⁴ Overall, up to 30% of hospitalized patients have evidence of myocardial injury, which is associated with a greater need for mechanical ventilatory support and higher in-hospital mortality.^{5,6} Cardiovascular manifestations include acute coronary syndrome, atrial and ventricular arrhythmias, myocarditis, and cardiogenic shock.³ In particular, myocarditis is a well-recognized severe complication of COVID-19 and is associated with fulminant cardiogenic shock and sudden cardiac death.⁷⁻⁹ The pathophysiology of cardiac injury remains poorly understood, and the management and outcomes of myocarditis are not yet clarified. Thus, the authors present a comprehensive review about COVID-19-related myocarditis, describing clinical characteristics, diagnostic workup, and management.

Funded by: CRUI2020.

^a Department of Cardiovascular/Respiratory Diseases, Nephrology, Anesthesiology, and Geriatric Sciences, Policlinico Umberto I, Sapienza University of Rome, Rome, Italy; ^b Cellular and Molecular Cardiology Lab, IRCCS L. Spallanzani, Rome 00149, Italy; ^c Texas Cardiac Arrhythmia Institute, St. David's Medical Center, 3000 North IH-35, Suite 720, Austin, TX 78705, USA

* Corresponding author. Department of Cardiovascular/Respiratory Diseases, Nephrology, Anesthesiology, and Geriatric Sciences, Policlinico Umberto I, Sapienza University of Rome, Rome, Italy.

E-mail address: cristina.chimenti@uniroma1.it

Card Electrophysiol Clin 14 (2022) 53–62

<https://doi.org/10.1016/j.ccep.2021.11.001>

1877-9182/22© 2021 Elsevier Inc. All rights reserved.

EPIDEMIOLOGY OF COVID-19-RELATED MYOCARDITIS

The annual incidence of acute myocarditis from all causes is approximately 22 cases per 100,000 population, with heart failure (HF) occurring in 0.5% to 4.0% of these cases.¹⁰ The true prevalence of myocarditis among patients with COVID-19 is difficult to establish, because the early reports often lacked the specific diagnostic modalities to assess myocarditis, and the circulating biomarkers reflecting myocardial injury can also be related to nonprimary myocardial damage (multiorgan failure, hypoxia, hypoperfusion, and activation of hemostasis).¹¹

Overall, several studies report that myocardial injury occurs in 15% to 27.8% of severe COVID-19 pneumonia cases.^{12–14} In addition, COVID-19-related myocarditis are also described in patients without prior pneumonia, indicating the probability of late onset of cardiovascular complications, even in those with mild symptoms.^{15,16} Otherwise, diffuse myocardial injury was also detected in the early stage of COVID-19-recovered patients who had no active cardiac symptoms.¹⁷

IMMUNOLOGIC AND PATHOPHYSIOLOGICAL MECHANISMS

SARS-CoV-2 is a β -coronavirus whose genome consists of single-stranded RNA with positive polarity that belongs to the Coronaviridae family. The virus invades the human host cell by binding with high affinity to the angiotensin-converting enzyme 2 (ACE-2) receptor. ACE-2 can be found on the ciliated columnar epithelial cells of the respiratory tract, type II pneumocytes, and cardiomyocytes. Therefore, this mechanism seems to be the pathway of SARS-CoV-2 infection of the human heart, especially in case of HF, as ACE-2 is upregulated.¹⁸ After penetration, viral RNA enters the cell nucleus for replication inducing human immunologic response to the virus.¹⁹

The mechanism of heart damage remains poorly understood, and several mechanisms have been proposed to explain the underlying pathophysiology of COVID-19-related acute myocarditis.²⁰ Among them, the main theories are the following (Fig. 1):

a. *Myocardial damage due to the direct viral action:* SARS-CoV-2 invades cells by binding to ACE-2 receptors, which are expressed in human myocardium.²¹ Despite that nowadays it is still unclear if SARS-CoV-2 is directly associated to cardiomyocyte infection and damage.

Indeed, although myocarditis has been clearly recognized at endomyocardial biopsy (EMB) or autopsy, there is no current evidence of myocarditis directly produced by cardiomyocyte infection due to the SARS-CoV-2 in humans,^{8,22–24} and the associated lymphocytic myocarditis may be related to the inflammatory reaction induced by cytokines²⁵ or by extrapulmonary migration of infected alveolar macrophages.

- b. *Via cell-mediated cytotoxicity:* activated CD8 T lymphocytes migrate to the heart and cause myocardial inflammation, inducing the cytokine release syndrome, a severe inflammatory response resulting in hypoxia and apoptosis of cardiomyocytes. This cytokine storm is proposed as the main mechanism underlying COVID-19-induced acute fulminant myocarditis.^{21,26} Substantial evidence suggest that elevated serum level of interleukin (IL)-6 is present in patients with COVID-19, especially in those with severe presentations.²⁷ As a matter of fact, IL-6 seems to be the central mediator of cytokine storm, in which it coordinates the proinflammatory responses from immune cells, including the T-lymphocytes.²⁸ This process causes T-lymphocyte activation and a further release of inflammatory cytokines, which stimulate more T-lymphocytes, leading to a positive feedback loop of immune activation and myocardial damage.²⁹ Furthermore, IL-6 might cause a displacement of plakoglobin, a desmosomal protein, that could be arrhythmogenic due to the deposition of fibrous tissue.³⁰
- c. *Interferon-mediated hyperactivation* of the innate and adaptive immune system has also been proposed, especially in pediatric myocarditis COVID-19 related.³¹

Most probably, as proposed by Esfandiarei and colleagues, the pathophysiology of viral myocarditis is a miscellaneous of direct viral cell injury and T-lymphocyte-mediated cytotoxicity, which can be augmented by the cytokine storm syndrome.³² Furthermore, cardiotoxic antiviral therapies may play a role in the genesis of myocardial inflammation, and a drug-induced myocarditis should also be considered.^{33,34}

CLINICAL PRESENTATION

Clinical presentation of SARS-CoV-2 myocarditis could be very different: some patients may present relatively mild symptoms, such as fatigue and dyspnea, whereas others may complain of chest pain or chest tightness.^{15,20} Otherwise, many patients show symptoms of tachycardia and acute-onset

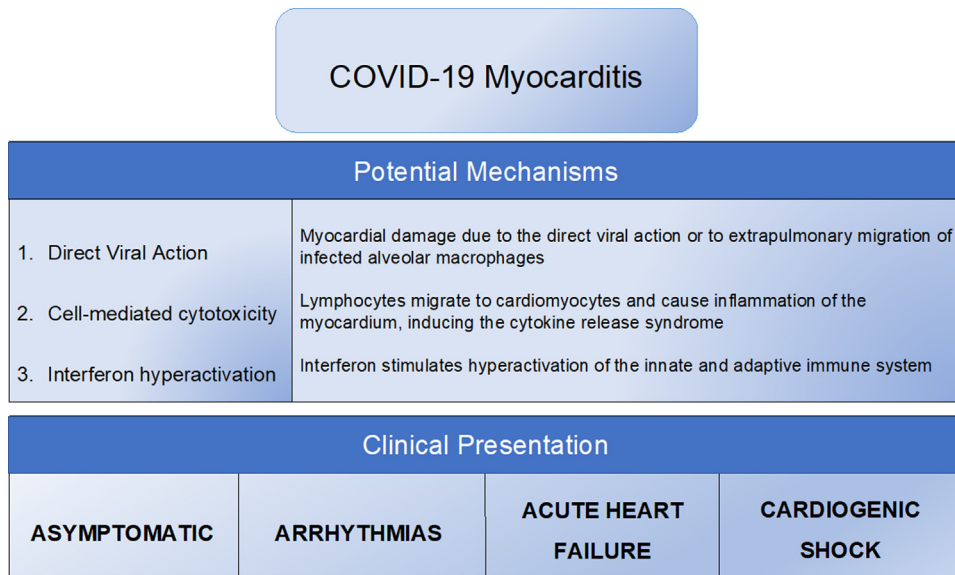


Fig. 1. Physiopathogenesis and clinical presentation of COVID-19 myocarditis.

HF until to cardiogenic shock or sudden cardiac death.^{35–38} The early signs of fulminant myocarditis usually look similar to those of sepsis: hyperpnea with low pulse pressure, cold or mottled extremities, and sinus tachycardia. Fulminant myocarditis is also frequently associated with ventricular arrhythmias because massive myocardial necrosis may generate some micro-reentry circuits and induce an electrolyte imbalance that triggers malignant tachycardia.^{39–41} Overall, cardiac arrhythmias are frequently seen in patients with COVID-19 affected by myocarditis: several studies reported an incidence of cardiac arrhythmias between 15% and 20%.^{42,43} The exact nature of the arrhythmias was not clearly reported but it has been speculated that their possible pathophysiology could include direct injury to cardiomyocytes and conduction system, ischemia from microvascular disease, reentrant arrhythmias due to myocardial fibrosis or scars, and proinflammatory cytokines predisposing to arrhythmogenicity (Fig. 2).^{19,41,44}

DIAGNOSIS

In patients with COVID-19, the criteria for the diagnosis of myocarditis are the same as in other patients. However, the diagnostic pathway may be different because it is conditioned, first of all, by the need to protect all health care operators from the risk of SARS-CoV-2 infection.⁴⁵ In Fig. 3 we provide a flow-chart for the diagnosis of COVID-19 myocarditis, considering troponin assessment as the first step in the diagnostic work up, because

it can be easily performed and its level is usually elevated in COVID-19-related myocarditis.^{6,15} However, even in the presence of normal troponin if clinical suspicion of myocarditis is strong, cardiologic examinations should be performed. A fundamental step in the diagnostic process is the exclusion of obstructive coronary artery disease because high troponin level could be the result of exacerbation of patient's subclinical coronary artery disease due to inflammatory state, which increases cardiac oxygen demand. The oxygen supply-demand mismatch could in turn precipitate ischemia, resulting in type 2 myocardial infarction.^{38,46,47}

Electrocardiographic (ECG) changes are not pathognomonic in myocarditis, because a variety of ECG patterns from sinus tachycardia and ectopic beats to ST elevation and T-wave inversion have been described.^{48–50} Other ECG abnormalities, including new-onset bundle branch block, QT prolongation, pseudoinfarct pattern, and bradyarrhythmia with advanced atrioventricular nodal block, can be observed in myocarditis.

Transthoracic echocardiography is the first imaging technique performed and can be coupled with pulmonary ultrasound evaluation.⁵¹ Global and regional ventricular systolic dysfunctions are not specific markers of acute myocarditis: ventricular dysfunction could be due to several other cardiac diseases, and, on the other hand, patients with myocarditis may have a normal left ventricular function. In addition, the possibility of a preexisting ventricular dysfunction should be always taken into consideration, especially if the patient has

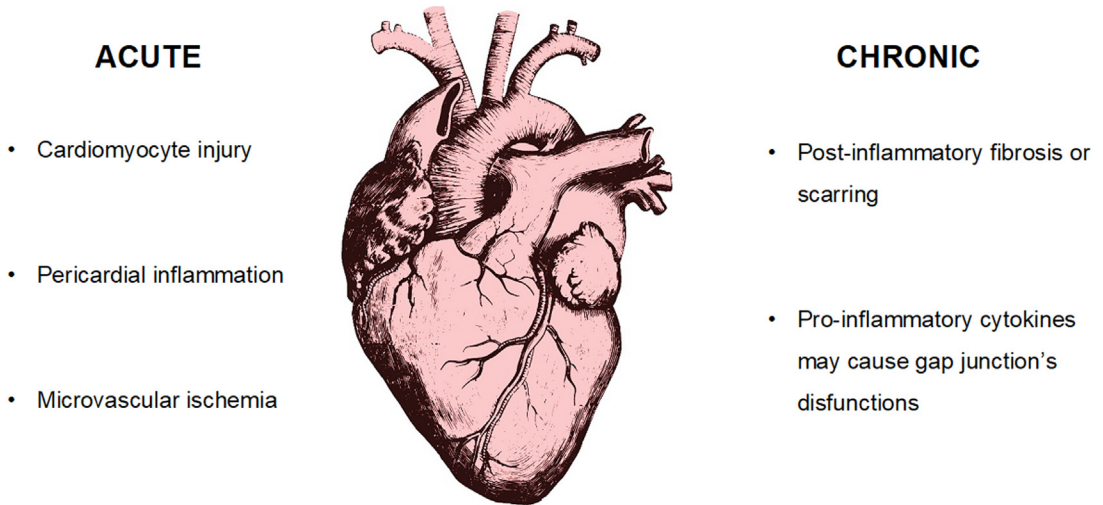


Fig. 2. Possible mechanism of arrhythmogenesis in COVID-19 myocarditis.

known cardiovascular risk factors. Echocardiography also has prognostic implications; patients with marked reduction in right ventricular function have an increased risk of death.⁵²

Thus, in patients with elevated troponin the presence of normal ECG and echocardiogram cannot exclude completely a COVID-19 myocarditis, and a close cardiologic follow-up should be performed.

Cardiac magnetic resonance (CMR) should be always performed in case of abnormal ECG and/or echocardiogram, and the findings should be interpreted according to the revised Lake Louise consensus criteria.^{53,54} In clinically stable patients, both CMR and coronary computed tomography could be theoretically performed for myocarditis diagnosis in a radiology section dedicated to patients with COVID-19. CMR is used in patients

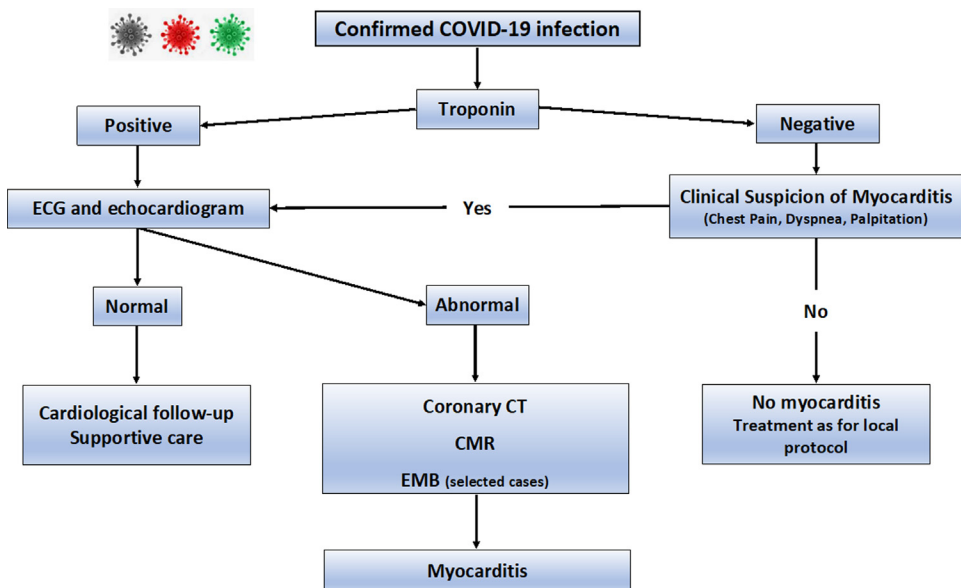


Fig. 3. Proposed flow-chart for the diagnosis of COVID-19 myocarditis. CAD, coronary artery disease; CMR, cardiac magnetic resonance; COVID-19, coronavirus disease 2019; CTA, computed tomography angiography; EMB, endomyocardial biopsy; PCI, percutaneous coronary intervention.

with COVID-19 to assess biventricular function, the pattern of edema and inflammation within the myocardium, and the presence of pericardial involvement. The common imaging findings on CMR included increased T1 and T2 mapping values and edema on T2/STIR sequences.⁵⁵ Diffuse edema may be considered the only CMR hallmark of COVID-19 myocarditis because late gadolinium enhancement (LGE) may be completely absent or minimal, revealing unremarkable myocyte necrosis.⁵⁶ LGE was seen in less than half of the patients, and if present, LGE was detected in the subepicardial location.⁵⁵ The presence of biventricular dysfunction; the detection of patchy, midwall, septal, or inferior LGE enhancement; and its persistence over 3 months have been associated with adverse cardiac events including sudden cardiac death and heart transplantation.^{57–59}

In selected cases with CMR that suggest myocarditis, an EMB may be performed. The consensus paper from the American Heart Association/American College of Cardiology recommended EMB preferably in new-onset HF with hemodynamic instability or in life-threatening arrhythmias to establish the specific therapy.^{60,61} Although EMB is definitive for the diagnosis, it is rarely used in patients with COVID-19 probably to limit spread of the infection to medical workers. When performed, the EMB showed scattered myocyte necrosis and CD4 and CD8 lymphocytes near vascular structures in patients with mild troponin elevation,^{55,62} whereas patients with more severe clinical presentations had interstitial inflammation and vasculitis of intramural vessels represented by T-lymphocytes and CD68+ macrophages, associated to foci of necrosis (Fig. 4). The macrophage infiltration was seen to correlate with the elevated systemic levels of proinflammatory cytokines. Although coronary involvement was uncommon, endotheliitis was commonly encountered because virus showed tropism for endothelial cells.^{36,63}

TREATMENT

The management of COVID-19 myocarditis is firstly finalized to provide a comprehensive management of HF.⁶⁴ However, a prompt treatment of respiratory symptoms aiming to promote viral clearance may have an additional benefit of reducing subsequent cardiovascular complications.

Management of Heart Failure

Patients who develop HF from COVID-19 myocarditis should be treated with guideline-

directed medical therapy, including ACE inhibitors, angiotensin receptor blockers (ARBs), or angiotensin receptor-neprilysin inhibitors (ARNi), β -blockers and diuretics.⁶⁵ Because of their mechanism of action, there was initial concern that treating patients with COVID-19 with ACEi, ARB, and ARNi would worsen clinical outcomes. Thus, several recent observational studies showed that there was no significant difference between patients treated with ACEi or ARB and those who discontinue these medications and, therefore, is generally recommended to initiate or continue these drugs during and beyond the disease.^{66,67}

In patients with fulminant myocarditis and cardiogenic shock, the administration of inotropes and/or vasopressors is recommended in the acute phase and mechanical circulatory support in the longer term.⁶⁸

Appropriate management of cardiac arrhythmias related to COVID-19 myocarditis is crucial in mitigating patient's adverse health outcomes. Bradyarrhythmia may require temporary cardiac pacing, whereas tachyarrhythmias may respond to antiarrhythmic drugs. β -blockers may be considered for hemodynamically stable patients, whereas amiodarone is typically administered in the critically ill, although it can prompt QTc prolongation, especially when combined with azithromycin or hydroxychloroquine.^{69–71} Alternatively, lidocaine infusion or oral flecainide may be considered.^{72–74}

SARS-CoV-2 Viral Therapies

Therapies for SARS-CoV-2 have focused primarily on restoration of respiratory function, and there are little data to define therapeutic options in COVID-19 myocarditis. Different antiviral therapies were expected to be effective in hospitalized patients with COVID-19: remdesivir, hydroxychloroquine, and interferon beta-1a. Unfortunately, all these drugs had little or no effect on overall mortality, initiation of ventilation, and duration of hospital stay.^{75,76} Moreover, many pharmacologic agents used empirically to treat COVID-19, especially hydroxychloroquine, may expose patients to an increased risk of cardiac arrhythmias: indeed, hydroxychloroquine may cause QTc interval prolongation, and its combination therapy with macrolides should be accompanied by QTc interval monitoring.⁷⁷

Nonsteroidal antiinflammatory drugs are generally not indicated in myocarditis patients because they are the known cause of renal impairment and sodium retention, which could exacerbate acute ventricular dysfunction.⁶⁸

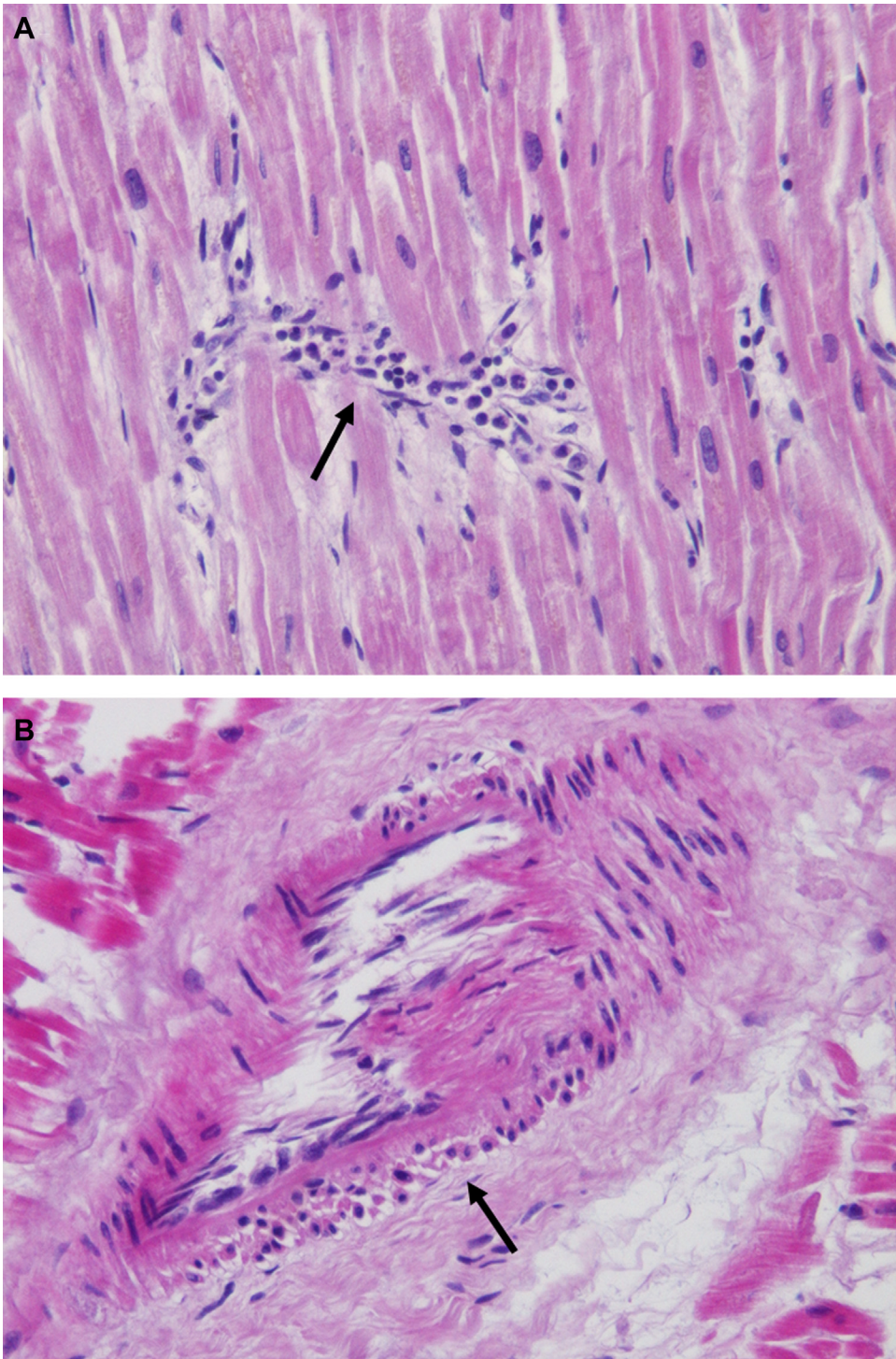


Fig. 4. Left ventricular endomyocardial biopsy of a patient with COVID-19 myocarditis. (A) Focal active myocarditis depicted by lymphomononuclear infiltrated (*arrows*) with necrosis of the adjacent cardiomyocytes (hematoxylin and eosin 10X magnification). (B) Myocarditis was associated with vasculitis of intramural vessels (hematoxylin and eosin 20X magnification).

Because cytokine release syndrome is a probable mechanism of injury in COVID-19 myocarditis, some investigators suggested to use antiinflammatory and anticytokine drugs such as high-dose steroids and intravenous immunoglobulins (IVIG).⁷⁸ However, the use of high-dose steroids in patients with COVID-19 has given conflicting results: if in a retrospective study there was an improvement of survival, another trial showed a reduction in viral clearance, increased risk of over infection, and mortality for all causes.^{79–81} Overall, in patients hospitalized with COVID-19 the use of corticosteroid resulted in a clinical benefit only in those who were receiving invasive mechanical ventilation and oxygen therapy.⁸²

Regarding purified IVIG, they gave encouraging result in a small group of 5 critical patients with COVID-19 without clinically suspected myocarditis but no additional evidence exists in patients with COVID-19–established myocarditis.⁸³ The immunomodulatory effects of IVIG are multifactorial, showing not only antiviral effects but also anti-inflammatory effects by suppressing inflammatory cytokines.⁸⁴ Currently, the evidence does not support the routine use of IVIGs alone.

Several immune therapies have also been investigated, and agents targeting IL-6, such as tocilizumab, have also been evaluated in the REMAP-CAP study, showing promising results in critically ill patients.⁸⁵

In summary, in patients with isolated SARS-CoV-2 myocarditis who are hospitalized, or hypoxemic, high-dose steroids may be reasonable, whereas it should be avoided in patients with less severe illness. Regarding targeted immunomodulatory therapy with IL-6 antagonists, additional data are needed to establish whether it can be recommended for SARS-CoV-2 myocarditis.

PROGNOSIS

Although there are very limited data about the clinical outcomes of COVID-19 myocarditis, it seems that most patients have a favorable prognosis.^{56,86} The complexity of COVID-19 and the possibility to die of other reasons than cardiac involvement (acute severe respiratory distress, systemic embolism, multiorgan failure) should also be underlined. Overall, Shi and colleagues reported that patients with myocardial injury presented higher mortality rate than those without myocardial injury (51.2% vs 4.5%; $P < .001$), being an independent risk factor for mortality.¹² In addition, myocardial injury was associated with a higher incidence of severe respiratory distress (58.5% vs 14.7%), need of noninvasive (46.3% vs 3.9%) or invasive

ventilation (22.0% vs 4.2%), and complications such as acute kidney injury (8.5% vs 0.3%) and coagulopathy (7.3% vs 1.8%).¹² Also, patients with an increase of troponin present higher levels of leukocytes, D-dimer, ferritin, and IL-6, portraying an important correlation between myocardial injury and inflammatory hyperactivity triggered by the viral infection. Raised troponin levels in COVID-19 are associated with worse outcome, but the specific prognostic role of myocarditis is unknown.⁸⁷

In general, myocardial involvement in COVID-19 is associated with an increased mortality, but isolated myocarditis is not necessarily a marker of poor prognosis. However, given the paucity of published data and the inhomogeneity of the cases, conclusive assertion on prognosis cannot be made.

SUMMARY

Myocarditis is a common complication of COVID-19 infection. Direct viral damage or cell-mediated cytotoxicity are the 2 likely pathophysiological mechanisms. Although CMR represents the most important diagnostic tool because diffuse edema may be considered the only CMR hallmark of COVID-19 myocarditis, the definitive diagnosis of myocarditis is obtained via EMB. Treatment of myocarditis should be based on therapy for ventricular dysfunction and clinical status, including arrhythmias and HF, whereas high-dose steroids should be reserved to more compromised patients. Myocardial involvement in COVID-19 is associated with an increased mortality, but isolated myocarditis is not necessarily a marker of poor prognosis.

CLINICS CARE POINTS

- Myocarditis are very frequent among COVID-19 patients.
- A comprehensive diagnostic approach should be pursued in these patients.
- Endomyocardial biopsy is necessary to exclude other form of myocarditis.

DISCLOSURE

All authors have reported that they have no relationships relevant to the contents of this article to disclose.

REFERENCES

1. Zhu N, Zhang D, Wang W, et al. A novel coronavirus from patients with pneumonia in China, 2019. *N Engl J Med* 2020;382:727–33.
2. Chen N, Zhou M, Dong X, et al. Epidemiological and clinical characteristics of 99 cases of 2019 novel coronavirus pneumonia in Wuhan, China: a Descriptive study. *Lancet* 2020;395:507–13.
3. Madjid M, Safavi-Naeini P, Solomon SD, et al. Potential effects of coronaviruses on the cardiovascular system: a review. *JAMA Cardiol* 2020;5:831.
4. Della Rocca DG, Magnocavallo M, Lavallo C, et al. Evidence of systemic endothelial injury and microthrombosis in hospitalized COVID-19 patients at different stages of the disease. *J Thromb Thrombolysis* 2020. <https://doi.org/10.1007/s11239-020-02330-1>.
5. Lala A, Johnson KW, Januzzi JL, et al. Prevalence and impact of myocardial injury in patients hospitalized with COVID-19 infection. *J Am Coll Cardiol* 2020;76:533–46.
6. Richardson S, Hirsch JS, Narasimhan M, Crawford JM, McGinn T, Davidson KW, the Northwell COVID-19 Research Consortium, Barnaby DP, Becker LB, Chelico JD, et al. Presenting characteristics, comorbidities, and outcomes among 5700 patients hospitalized with COVID-19 in the New York city Area. *JAMA* 2020;323:2052.
7. Kesici S, Aykan HH, Orhan D, et al. Fulminant COVID-19-related myocarditis in an infant. *Eur Heart J* 2020;41:3021.
8. del Nonno F, Frustaci A, Verardo R, et al. Virus-negative myopericarditis in human coronavirus infection: report from an autopsy Series. *Circ Heart Fail* 2020;13. <https://doi.org/10.1161/CIRCHEARTFAILURE.120.007636>.
9. Daniels CJ, Rajpal S, Greenshields JT, et al. Prevalence of clinical and subclinical myocarditis in Competitive Athletes with recent SARS-CoV-2 infection: results from the big ten COVID-19 cardiac registry. *JAMA Cardiol* 2021. <https://doi.org/10.1001/jamacardio.2021.2065>.
10. Vos T, Barber RM, Bell B, et al. Global, regional, and National incidence, prevalence, and years lived with disability for 301 acute and chronic diseases and injuries in 188 countries, 1990–2013: a systematic analysis for the global burden of disease study 2013. *Lancet* 2015;386:743–800.
11. Siripanthong B, Nazarian S, Muser D, et al. Recognizing COVID-19-related myocarditis: the possible pathophysiology and proposed guideline for diagnosis and management. *Heart Rhythm* 2020;17:1463–71.
12. Shi S, Qin M, Shen B, et al. Association of cardiac injury with mortality in hospitalized patients with COVID-19 in Wuhan, China. *JAMA Cardiol* 2020;5:802. <https://doi.org/10.1001/jamacardio.2020.0950>.
13. Guo T, Fan Y, Chen M, et al. Cardiovascular implications of fatal outcomes of patients with coronavirus disease 2019 (COVID-19). *JAMA Cardiol* 2020;5:811. <https://doi.org/10.1001/jamacardio.2020.1017>.
14. Maestrini V, Birtolo LI, Francone M, et al. Cardiac involvement in consecutive unselected hospitalized COVID-19 population: in-hospital evaluation and one-Year follow-up. *Int J Cardiol* 2021;339:235–42.
15. Inciardi RM, Lupi L, Zaccone G, et al. Cardiac involvement in a patient with coronavirus disease 2019 (COVID-19). *JAMA Cardiol* 2020;5:819. <https://doi.org/10.1001/jamacardio.2020.1096>.
16. Kim I-C, Kim JY, Kim HA, et al. COVID-19-Related myocarditis in a 21-year-old female patient. *Eur Heart J* 2020;41:1859.
17. Puntmann VO, Carerj ML, Wieters I, et al. Outcomes of cardiovascular magnetic resonance imaging in patients recently recovered from coronavirus disease 2019 (COVID-19). *JAMA Cardiol* 2020;5:1265.
18. Kawakami R, Sakamoto A, Kawai K, et al. Pathological evidence for SARS-CoV-2 as a cause of myocarditis. *J Am Coll Cardiol* 2021;77:314–25.
19. Bhatla A, Mayer MM, Adusumalli S, et al. COVID-19 and cardiac arrhythmias. *Heart Rhythm* 2020;17:1439–44.
20. Carretta DM, Silva AM, D'Agostino D, et al. Cardiac involvement in COVID-19 patients: a contemporary review. *Infect Dis Rep* 2021;13:494–517.
21. Ranard LS, Fried JA, Abdalla M, et al. Approach to acute cardiovascular complications in COVID-19 infection. *Circ Heart Fail* 2020;13. <https://doi.org/10.1161/CIRCHEARTFAILURE.120.007220>.
22. Escher F, Pietsch H, Aleshcheva G, et al. Detection of viral SARS-CoV-2 genomes and histopathological changes in endomyocardial Biopsies. *ESC Heart Fail* 2020;7:2440–7.
23. Lindner D, Fitzek A, Bräuninger H, et al. Association of cardiac infection with SARS-CoV-2 in confirmed COVID-19 autopsy cases. *JAMA Cardiol* 2020;5:1281.
24. Basso C, Leone O, Rizzo S, et al. Pathological features of COVID-19-associated myocardial injury: a multicentre cardiovascular pathology study. *Eur Heart J* 2020;41:3827–35.
25. Sala S, Peretto G, Gramegna M, et al. Acute myocarditis presenting as a reverse tako-tsubo syndrome in a patient with SARS-CoV-2 respiratory infection. *Eur Heart J* 2020;41:1861–2.
26. Gralinski LE, Baric RS. Molecular pathology of emerging coronavirus infections. *J Pathol* 2015;235:185–95.
27. Coomes EA, Haghbayan H. Interleukin-6 in Covid-19: a Systematic review and meta-analysis. *Rev Med Virol* 2020;30:1–9.
28. Lee DW, Gardner R, Porter DL, et al. Current concepts in the diagnosis and management of cytokine release syndrome. *Blood* 2014;124:188–95.
29. Fox SE, Akmatbekov A, Harbert JL, et al. Pulmonary and cardiac Pathology in African American patients with COVID-19: an autopsy Series from new Orleans. *Lancet Respir Med* 2020;8:681–6.

30. Asimaki A, Tandri H, Duffy ER, et al. Altered desmosomal proteins in granulomatous myocarditis and potential pathogenic links to arrhythmogenic right ventricular cardiomyopathy. *Circ Arrhythm Electrophysiol* 2011;4:743–52.
31. McMurray JC, May JW, Cunningham MW, et al. Multisystem inflammatory syndrome in Children (MIS-C), a Post-viral myocarditis and systemic vasculitis—a critical review of its pathogenesis and treatment. *Front Pediatr* 2020;8:626182.
32. Esfandiari M, McManus BM. Molecular biology and pathogenesis of viral myocarditis. *Annu Rev Pathol Mech Dis* 2008;3:127–55.
33. Alijotas-Reig J, Esteve-Valverde E, Belizna C, et al. Immunomodulatory therapy for the management of severe COVID-19. Beyond the anti-viral therapy: a comprehensive review. *Autoimmun Rev* 2020;19:102569. <https://doi.org/10.1016/j.autrev.2020.102569>.
34. Russell K, Eriksen M, Aaberge L, et al. A novel clinical method for quantification of regional left ventricular pressure–strain loop area: a non-invasive Index of myocardial work. *Eur Heart J* 2012;33:724–33.
35. Zeng J-H, Liu Y-X, Yuan J, et al. First case of COVID-19 complicated with fulminant myocarditis: a case report and insights. *Infection* 2020;48:773–7.
36. Frustaci A, Francone M, Verardo R, et al. Virus-negative necrotizing coronary vasculitis with aneurysm formation in human SARS-CoV-2 infection. *Infect Dis Rep* 2021;13:597–601.
37. Lavalle C, Ricci RP, Santini M. Atrial tachyarrhythmias and cardiac resynchronisation therapy: clinical and therapeutic implications. *Heart* 2010;96:1174–8.
38. Di Biase L, Romero J, Du X, et al. Catheter ablation of ventricular tachycardia in ischemic cardiomyopathy: impact of concomitant amiodarone therapy on short- and long-term clinical outcomes. *Heart Rhythm* 2021;18:885–93.
39. Di Biase L, Romero J, Zado ES, et al. Variant of ventricular outflow tract ventricular arrhythmias requiring ablation from multiple sites: intramural origin. *Heart Rhythm* 2019;16:724–32.
40. Lakkireddy DR, Chung MK, Gopinathannair R, et al. Guidance for cardiac Electrophysiology during the COVID-19 Pandemic from the heart Rhythm Society COVID-19 Task Force; Electrophysiology section of the American College of Cardiology; and the Electrocardiography and arrhythmias Committee of the Council on clinical Cardiology, American heart association. *Heart Rhythm* 2020;17:e233–41.
41. Wu C-I, Postema PG, Arbelo E, et al. SARS-CoV-2, COVID-19, and Inherited arrhythmia syndromes. *Heart Rhythm* 2020;17:1456–62.
42. Coromilas EJ, Kochav S, Goldenthal I, et al. Worldwide Survey of COVID-19-associated arrhythmias. *Circ Arrhythmia Electrophysiol* 2021;14. <https://doi.org/10.1161/CIRCEP.120.009458>.
43. Liu K, Fang Y-Y, Deng Y, et al. Clinical characteristics of novel coronavirus cases in Tertiary hospitals in Hubei Province. *Chin Med J* 2020;133:1025–31.
44. Della Rocca DG, Pepine CJ. Endothelium as a Predictor of adverse outcomes: Endothelium as a Predictor of adverse outcomes. *Clin Cardiol* 2010;33:730–2.
45. Mele D, Flamigni F, Rapezzi C, et al. Myocarditis in COVID-19 patients: current Problems. *Intern Emerg Med* 2021;16:1123–9.
46. Clerkin KJ, Fried JA, Raikhelkar J, et al. COVID-19 and cardiovascular disease. *Circulation* 2020;141:1648–55.
47. Chimenti C, Scopelliti F, Vulpis E, et al. Increased Oxidative stress Contributes to cardiomyocyte dysfunction and death in patients with Fabry disease Cardiomyopathy. *Hum Pathol* 2015;46:1760–8.
48. Forleo GB, Della Rocca DG, Papavasileiou LP, et al. Predictive value of Fragmented QRS in primary prevention Implantable Cardioverter Defibrillator Recipients with left ventricular dysfunction. *J Cardiovasc Med* 2011;12:779–84.
49. Romero J, Alviz I, Parides M, et al. T-wave inversion as a manifestation of COVID-19 infection: a case Series. *J Interv Card Electrophysiol* 2020;59:485–93.
50. Chen Q, Xu J, Gianni C, et al. Simple Electrocardiographic criteria for Rapid Identification of Wide QRS Complex tachycardia: the new Limb Lead Algorithm. *Heart Rhythm* 2020;17:431–8.
51. D'Andrea Antonello, Di Giannuario Giovanna, Marrazzo Gemma, et al. L'imaging integrato nel percorso del paziente con COVID-19: dalla diagnosi, al monitoraggio clinico, alla prognosi. *Giornale Italiano di Cardiologia* 2020. <https://doi.org/10.1714/3343.33132>.
52. Szekeley Y, Lichter Y, Taieb P, et al. Spectrum of cardiac manifestations in COVID-19: a Systematic echocardiographic study. *Circulation* 2020;142:342–53.
53. Friedrich MG, Sechtem U, Schulz-Menger J, et al. Cardiovascular magnetic resonance in myocarditis: a JACC white paper. *J Am Coll Cardiol* 2009;53:1475–87. <https://doi.org/10.1016/j.jacc.2009.02.007>.
54. Ferreira VM, Schulz-Menger J, Holmvang G, et al. Cardiovascular magnetic resonance in Nonischemic myocardial inflammation. *J Am Coll Cardiol* 2018;72:3158–76.
55. Ojha V, Verma M, Pandey NN, et al. Cardiac magnetic resonance imaging in coronavirus disease 2019 (COVID-19): a Systematic review of cardiac magnetic resonance imaging findings in 199 patients. *J Thorac Imaging* 2021;36:73–83.
56. Esposito A, Palmisano A, Natale L, et al. Cardiac magnetic resonance Characterization of myocarditis-like acute cardiac syndrome in COVID-19. *JACC: Cardiovasc Imaging* 2020;13:2462–5.
57. Caforio ALP, Calabrese F, Angelini A, et al. A Prospective study of biopsy-Proven myocarditis:

- prognostic relevance of clinical and Aetiopathogenetic Features at diagnosis. *Eur Heart J* 2007;28:1326–33.
58. Grün S, Schumm J, Greulich S, et al. Long-term follow-up of biopsy-Proven viral myocarditis. *J Am Coll Cardiol* 2012;59:1604–15.
 59. Gräni C, Eichhorn C, Bière L, et al. Prognostic value of cardiac magnetic resonance tissue Characterization in risk Stratifying patients with suspected myocarditis. *J Am Coll Cardiol* 2017;70:1964–76.
 60. Cooper LT, Baughman KL, Feldman AM, et al. The role of endomyocardial biopsy in the management of cardiovascular disease: a scientific statement from the American heart association, the American College of Cardiology, and the European society of Cardiology. *Circulation* 2007;116:2216–33.
 61. Tarantino N, Della Rocca DG, De Leon De La Cruz NS, et al. Catheter ablation of life-threatening ventricular arrhythmias in Athletes. *Medicina* 2021;57:205.
 62. Fox SE, Li G, Akmatbekov A, et al. Unexpected features of cardiac pathology in COVID-19 infection. *Circulation* 2020;142:1123–5.
 63. Fox SE, Lameira FS, Rinker EB, et al. Cardiac endotheliitis and multisystem inflammatory syndrome after COVID-19. *Ann Intern Med* 2020;173:1025–7.
 64. Agdamag ACC, Edmiston JB, Charpentier V, et al. Update on COVID-19 myocarditis. *Medicina (Kauņas)* 2020;56:E678.
 65. McDonagh TA, Metra M, Adamo M, et al. 2021 ESC guidelines for the diagnosis and treatment of acute and chronic heart failure. *Eur Heart J* 2021;42:3599–726.
 66. Lopes RD, Macedo AVS, de Barros E Silva PGM, et al. Effect of discontinuing vs continuing angiotensin-converting enzyme inhibitors and angiotensin II receptor blockers on days alive and out of the hospital in patients admitted with COVID-19: a randomized clinical trial. *JAMA* 2021;325:254.
 67. Mehra MR, Desai SS, Kuy S, et al. Retraction: cardiovascular disease, drug therapy, and mortality in covid-19. *N Engl J Med* 2020;382:2582.
 68. Kociol RD, Cooper LT, Fang JC, et al. Recognition and initial management of fulminant myocarditis: a scientific statement from the American heart association. *Circulation* 2020;141. <https://doi.org/10.1161/CIR.0000000000000745>.
 69. Mercurio NJ, Yen CF, Shim DJ, et al. Risk of QT interval prolongation associated with use of hydroxychloroquine with or without concomitant azithromycin among hospitalized patients Testing positive for coronavirus disease 2019 (COVID-19). *JAMA Cardiol* 2020;5:1036.
 70. Gasperetti A, Biffi M, Duru F, et al. Arrhythmic safety of hydroxychloroquine in COVID-19 patients from different clinical Settings. *EP Europace* 2020;22:1855–63.
 71. Frustaci A, Morgante E, Antuzzi D, et al. Inhibition of cardiomyocyte lysosomal activity in hydroxychloroquine cardiomyopathy. *Int J Cardiol* 2012;157:117–9.
 72. Lavalley C, Magnocavallo M, Straito M, et al. Flecaïnide how and when: a practical guide in supraventricular arrhythmias. *JCM* 2021;10:1456.
 73. Lavalley C, Trivigno S, Vetta G, et al. Flecaïnide in ventricular arrhythmias: from old myths to new perspectives. *JCM* 2021;10:3696.
 74. Della Rocca DG, Tarantino N, Trivedi C, et al. Non-pulmonary vein triggers in nonparoxysmal atrial fibrillation: implications of pathophysiology for Catheter Ablation. *J Cardiovasc Electrophysiol* 2020;31:2154–67.
 75. WHO Solidarity trial Consortium Repurposed Antiviral drugs for Covid-19 — Interim WHO Solidarity trial results. *N Engl J Med* 2021;384:497–511.
 76. The RECOVERY Collaborative group effect of hydroxychloroquine in hospitalized patients with Covid-19. *N Engl J Med* 2020;383:2030–40.
 77. Piro A, Magnocavallo M, Della Rocca DG, et al. Management of cardiac Implantable Electronic Device follow-up in COVID-19 Pandemic: Lessons Learned during Italian Lockdown. *J Cardiovasc Electrophysiol* 2020;14755. jce.
 78. Mehta P, McAuley DF, Brown M, et al. COVID-19: Consider cytokine storm syndromes and Immunosuppression. *Lancet* 2020;395:1033–4.
 79. Wu C, Chen X, Cai Y, et al. Risk factors associated with acute respiratory distress syndrome and death in patients with coronavirus disease 2019 pneumonia in Wuhan, China. *JAMA Intern Med* 2020;180:934.
 80. Russell CD, Millar JE, Baillie JK. Clinical evidence does not support corticosteroid treatment for 2019-NCoV Lung injury. *Lancet* 2020;395:473–5.
 81. Frustaci A, Chimenti C. Immunosuppressive therapy in myocarditis. *Circ J* 2014;79:4–7.
 82. The RECOVERY Collaborative group Dexamethasone in hospitalized patients with Covid-19. *N Engl J Med* 2021;384:693–704.
 83. Shen C, Wang Z, Zhao F, et al. Treatment of 5 critically ill patients with COVID-19 with Convalescent Plasma. *JAMA* 2020;323:1582.
 84. Kow CS, Hasan SS. Glucocorticoid versus immunoglobulin in the treatment of COVID-19-associated fulminant myocarditis. *Infection* 2020;48:805–6.
 85. The REMAP-CAP Investigators interleukin-6 receptor antagonists in critically ill patients with Covid-19. *N Engl J Med* 2021;384:1491–502.
 86. Sawalha K, Abozenah M, Kadado AJ, et al. Systematic review of COVID-19 related myocarditis: Insights on management and outcome. *Cardiovasc Revascularization Med* 2021;23:107–13.
 87. Castiello T, Georgiopoulos G, Finocchiaro G, et al. COVID-19 and myocarditis: a systematic review and overview of current challenges. *Heart Fail Rev* 2021. <https://doi.org/10.1007/s10741-021-10087-9>.