



Effect of the Recombinant Human Epidermal Growth Factor Ointment on Cutaneous Surgical Wounds Compared to Antibiotic Ointment

Sook In Ryu, Ko Eun Kim, Jae Yeong Jeong, Jong heon Park, Hye-Rim Moon¹, Il-Hwan Kim

Department of Dermatology, Korea University Ansan Hospital, Korea University College of Medicine, Seoul, ¹Beautiful Skin Clinic, Gunpo, Korea

Received July 2, 2020

Revised May 6, 2021

Accepted May 14, 2021

Corresponding Author

Il-Hwan Kim

Department of Dermatology, Korea University Ansan Hospital, Korea University College of Medicine, 123 Jeokgeum-ro, Danwon-gu, Ansan 15355, Korea
Tel: +82-31-412-5180
Fax: +82-31-412-4208
E-mail: kumcihk@korea.ac.kr
<https://orcid.org/0000-0002-4225-002X>

Background: Applying antibiotic ointment after skin surgery can decrease infection and improve scar. Epidermal growth factor (EGF) is known to be able to promote the growth and movement of epidermal cells to stimulate wound healing. Recombinant human EGF (rhEGF) ointment can be used in wet closed dressing to promote wound healing and prevent complications by maintaining a wet environment.

Objective: To compare the efficacy of rhEGF ointment and conventional antibiotic ointment after cutaneous resection.

Methods: Patients who had excision procedures in two or more sites were enrolled. Each wound was assigned to the rhEGF group or the antibiotic ointment group. Wounds were subjected to Physician Global Assessment (PhGA), Patient Global Assessment (PGA), and Patient satisfaction assessment (PSA). The length and area of wounds, and melanin and erythema index (MI and EI) were also assessed for these wounds.

Results: Among 11 patients with a total of 20 pairs of resection sites, PhGA, PGA, MI, and EI showed no significant difference between rhEGF and antibiotic ointment groups. However, changes in length and area of wounds showed significant differences between the two groups.

Conclusion: RhEGF ointment showed similar short-term cosmetic results with antibiotic ointment, and improved surgical results in regards of the wound size. Applying rhEGF could reduce the use of antibiotic ointments for cutaneous clean (class I) wound surgery.

Keywords: Epidermal growth factor, Surgical wound

INTRODUCTION

Wound dressing using antibiotics after cutaneous resection is a widely used method. Applying antibiotic ointment after skin surgery is expected to achieve cosmetic improvement of scar and decreased infection rate^{1,2}. However, resistance to antibiotics is increasing, and there is insufficient evidence of the prophylactic use of topical antibiotics in clean cutaneous resection^{3,4}. This study aimed to compare efficacies of recombinant human epidermal growth factor (rhEGF) and antibiotic ointment.

MATERIALS AND METHODS

Patients

Patients with benign neoplasm who underwent two or more excision operations at the Department of Dermatology, Korea University Ansan Hospital between 2017 and 2019 were enrolled. This study was approved by the Institutional Review Board of Korea University Ansan Hospital (IRB no.2017AS0114). The patient consent was obtained before enrollment.



Inclusion and exclusion criteria

Patients aged 20 to 65 years who had more than two sites of excision procedures were enrolled. To compare the efficacies, each site was divided into the treatment and control group in each patient. Exclusion criteria are described in Supplementary Table 1.

Procedure

This was a randomized, double-blind study and excision sites were assigned according to a random table based on anatomical location. The site applied with a rhEGF ointment (Easyef®; Daewoong Pharmaceutical, Seoul, Korea) and mupirocin ointment (Bearoban®; Hanall biopharma, Seoul, Korea) were labeled A and B, respectively. Patients were educated on which lesion A or B ointment should be applied, and also informed to change the dressing daily. The wound was covered with hydrocolloid material. The application period was from the day of resection to 3 days after stitch removal—the stitches were

removed at 1 week after resection for face and 2 weeks for other body parts.

Evaluation of clinical effect

Clinical photographs were taken at each follow-up visit. Wounds were analyzed at 4 weeks and 8 weeks after stitch removal for Physician Global Assessment (PhGA), Patient Global Assessment (PGA), and Patient satisfaction assessment (PSA). The length and area of wounds, melanin index (MI), and erythema index (EI) were also assessed. PhGA and PGA scores were rated between 0 and 100 by the physician and patient (0 representing normal skin and 100 representing severe scar), PSA scores by the patient (0 being completely unsatisfied and 100 being completely satisfied). EI and MI of resection sites and periphery were obtained using the DermaLab Combo® (Cortex Technologies, Hadsund, Denmark) by measuring skin color with a narrow-band spectrophotometer. The length was defined as the longest axis of excision wound, and the area of

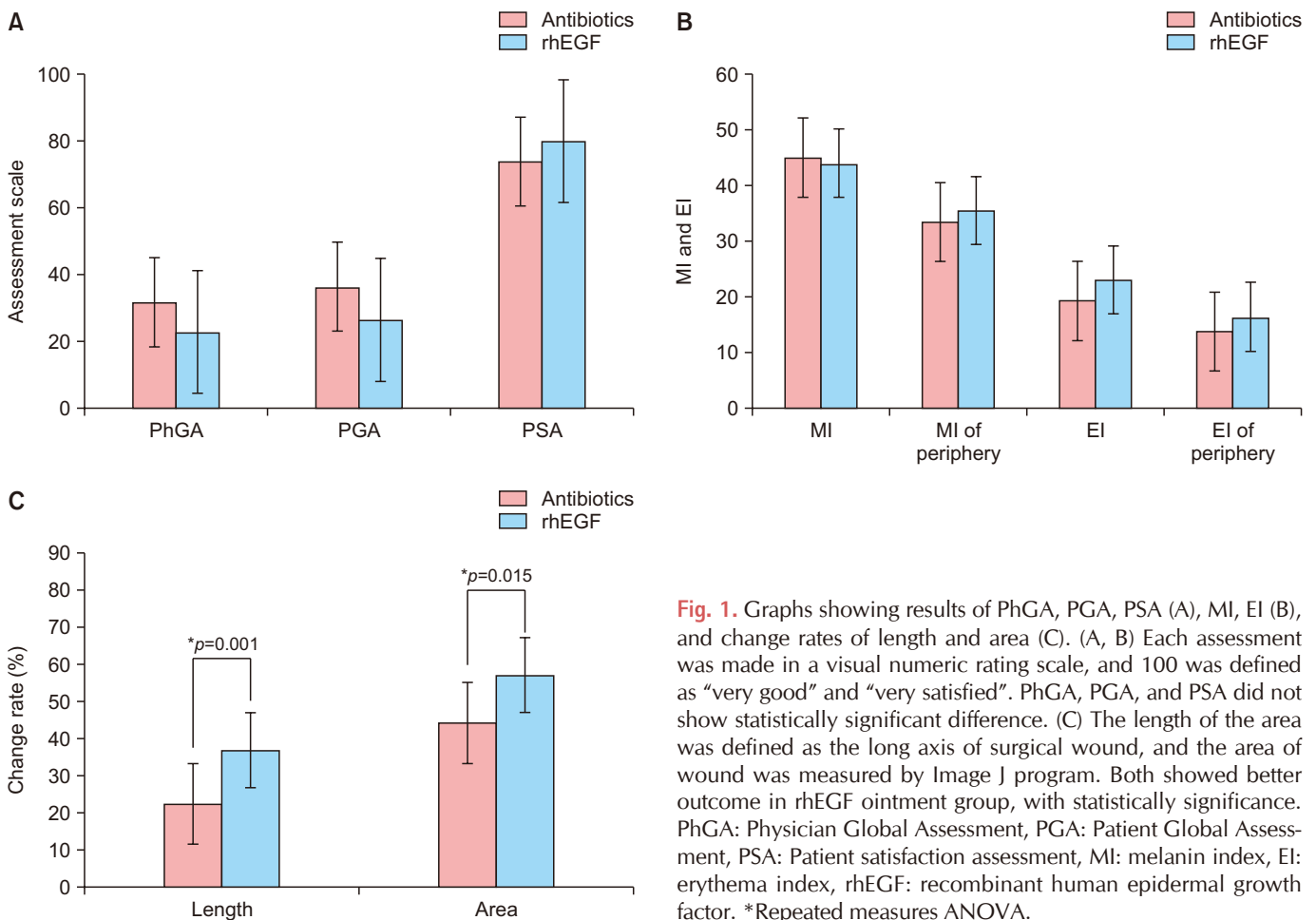


Fig. 1. Graphs showing results of PhGA, PGA, PSA (A), MI, EI (B), and change rates of length and area (C). (A, B) Each assessment was made in a visual numeric rating scale, and 100 was defined as “very good” and “very satisfied”. PhGA, PGA, and PSA did not show statistically significant difference. (C) The length of the area was defined as the long axis of surgical wound, and the area of wound was measured by Image J program. Both showed better outcome in rhEGF ointment group, with statistically significance. PhGA: Physician Global Assessment, PGA: Patient Global Assessment, PSA: Patient satisfaction assessment, MI: melanin index, EI: erythema index, rhEGF: recombinant human epidermal growth factor. *Repeated measures ANOVA.

each scar were estimated using an image processing software (ImageJ; National Institutes of Health, Bethesda, MD, USA). The area was selected by freehand according to the erythema or hyperpigmentation compared to surrounding normal skin, three times repetitively, and then the average area was assessed. All data were analyzed using IBM SPSS Statistics ver. 22.0 (IBM Corp., Armonk, NY, USA). *p*-values of less than 0.05 were considered significant.

RESULTS

Sixteen patients with a total of twenty-seven pairs of resection sites were enrolled in this study. Five patients with seven pairs of resection sites were excluded due to non-compliance with follow-up visits. (age range, 24–57 years). The resection sites and pathologic diagnosis of each lesion are described in Supplementary Table 2.

All assessments were measured at 4 and 8 weeks after stitch removal. PhGA ($p=0.054$), PGA ($p=0.062$), PSA ($p=0.153$), MI ($p=0.603$), MI of periphery ($p=0.495$), EI ($p=0.457$), and EI of

periphery ($p=0.429$) showed no statistically significant difference between rhEGF and antibiotic ointment groups (Fig. 1A, B).

However, change rates of length and area of wounds from the initial size showed significant differences (length: $p=0.001$, area: $p=0.015$) (Fig. 1C, 2). Decrements of length and area were higher in the rhEGF group than in the antibiotics group.

All surgical wound sites healed without any serious complications.

DISCUSSION

Growth factors are involved in wound healing steps, and among them, EGF can promote the regeneration of epidermal cells and stimulate proliferation and migration of keratinocytes⁵. To speed up the wound healing process and to facilitate the recovery of non-healing wounds, administration of growth factors to lesions has been studied⁶.

Esquirol-Causa and Herrero-Vila⁷ have reported 77 cases of ulcers treated with topical rhEGF, showing wound surface were decreased by 66.07% after topical rhEGF treatment. Shin et al.⁸ have used rhEGF on thyroidectomy wounds, finding that scar pliability and thickness showed significant differences between the rhEGF and the control group. In our study, using rhEGF ointment decreased the length and area of excision scars.

Moist wound dressing with prophylactic use of topical antibiotics has been a standard management of excisions¹. However, evidence of using topical antibiotics for infection prevention is lacking in minor surgical procedures^{1,4}. Dixon et al.⁹ have conducted a blinded randomized controlled study of patients with non-contaminated surgical wounds. The results showed no significant difference in infection among the mupirocin group and no ointment groups. Most of excision carried out by dermatologist in a sterile operating room can be classified as clean (class I), which does not require mandatory antibiotic use. Although the incidence of antimicrobial resistance of topical antibiotics is lower than that of systemic antibiotics, the resistance rate is continuously increasing¹⁰. In the report of Simor et al.⁴, percentage of MRSA with high-level resistance to mupirocin has increased from 1.6% to 7.0%, and low-level mupirocin resistance has increased from 6.4% to 10.0% recently. This study is a randomized double-blind analysis comparing effects of rhEGF and antibiotic ointment. Our results showed that applying rhEGF ointment can decrease the length and area

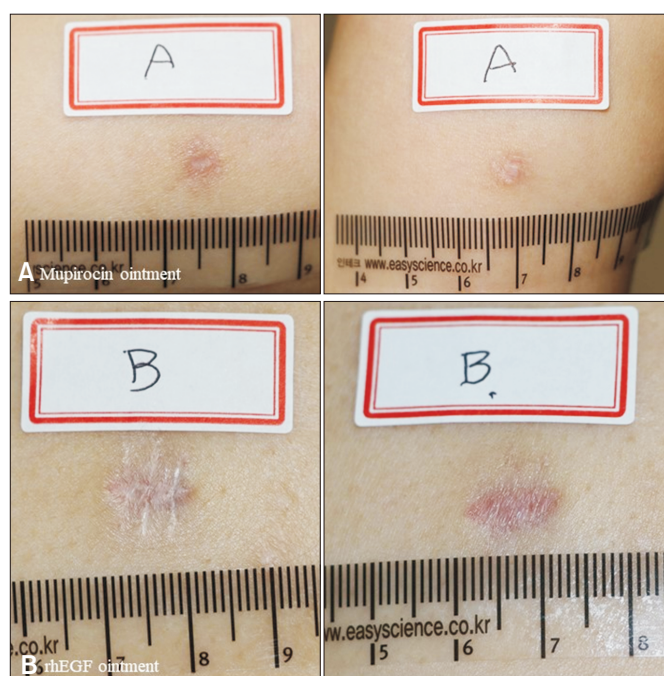


Fig. 2. Clinical photographs of a female patient. Photograph (A) shows the excision sites where applied mupirocin ointment (left: 4 weeks after resection, right: 8 weeks after resection) and photograph (B) shows excision sites where applied rhEGF ointment (left: 4 weeks after resection, right: 8 weeks after resection). rhEGF: recombinant human epidermal growth factor.

of scars without having serious adverse effects. The MI, EI, and PGA showed that rhEGF ointment was not inferior to antibiotic agent, without statistical significance. By applying rhEGF ointment, it is possible to reduce antibiotic resistance by reducing the use of topical antibiotics after clean cutaneous excision and decrease the area of wound.

However, this study has some limitations. First, the number of patients enrolled was small and the follow-up period was short. Moreover, enrolled patients had different diagnosis, incision lines, and locations.

In conclusion, by applying rhEGF ointment, it is possible to achieve improved cosmetic results and reduce the use of antibiotic ointment for clean wounds surgeries.

We received the patient's consent form about publishing all photographic materials.

SUPPLEMENTARY MATERIALS

Supplementary data can be found via <http://anndermatol.org/src/sm/ad-33-549-s001.pdf>.

CONFLICTS OF INTEREST

The authors have nothing to disclose.

FUNDING SOURCE

This study was supported by grants from Daewoong Pharmaceutical Company, Korea.

DATA SHARING STATEMENT

Research data are not shared.

ORCID

Sook In Ryu, <https://orcid.org/0000-0002-9880-4837>

Ko Eun Kim, <https://orcid.org/0000-0002-4141-204X>

Jae Yeong Jeong, <https://orcid.org/0000-0003-0272-3563>

Jong heon Park, <https://orcid.org/0000-0002-3162-8509>

Hye-Rim Moon, <https://orcid.org/0000-0002-6618-8881>

Il-Hwan Kim, <https://orcid.org/0000-0002-4225-002X>

REFERENCES

1. Drucker CR. Update on topical antibiotics in dermatology. *Dermatol Ther* 2012;25:6-11.
2. Eaglstein WH. Moist wound healing with occlusive dressings: a clinical focus. *Dermatol Surg* 2001;27:175-181.
3. Saco M, Howe N, Nathoo R, Cherpelis B. Topical antibiotic prophylaxis for prevention of surgical wound infections from dermatologic procedures: a systematic review and meta-analysis. *J Dermatolog Treat* 2015;26:151-158.
4. Simor AE, Stuart TL, Louie L, Watt C, Ofner-Agostini M, Gravel D, et al. Mupirocin-resistant, methicillin-resistant *Staphylococcus aureus* strains in Canadian hospitals. *Antimicrob Agents Chemother* 2007;51:3880-3886.
5. Greenhalgh DG. The role of growth factors in wound healing. *J Trauma* 1996;41:159-167.
6. Yamakawa S, Hayashida K. Advances in surgical applications of growth factors for wound healing. *Burns Trauma* 2019;7:10.
7. Esquirol-Caussa J, Herrero-Vila E. Human recombinant epidermal growth factor in skin lesions: 77 cases in EPItelizando project. *J Dermatolog Treat* 2019;30:96-101.
8. Shin JU, Kang SW, Jeong JJ, Nam KH, Chung WY, Lee JH. Effect of recombinant human epidermal growth factor on cutaneous scar quality in thyroidectomy patients. *J Dermatolog Treat* 2015;26:159-164.
9. Dixon AJ, Dixon MP, Dixon JB. Randomized clinical trial of the effect of applying ointment to surgical wounds before occlusive dressing. *Br J Surg* 2006;93:937-943.
10. Punjataewakupt A, Napavichayanun S, Aramwit P. The downside of antimicrobial agents for wound healing. *Eur J Clin Microbiol Infect Dis* 2019;38:39-54.