

Nicolau Syndrome After Glatiramer Acetate Injection in Close Proximity to Administration of SARS-CoV-2 mRNA Vaccine

Michael Yu Sy, MD, PhD, Erin Fromm, RN, Linda Doan, MD, PhD, Nathan Rojek, MD, and Alexander Ulrich Brandt, MD

Correspondence

Dr. Sy
msy@hs.uci.edu

Neurol Neuroimmunol Neuroinflamm 2022;9:e1112. doi:10.1212/NXI.0000000000001112

Nicolau syndrome (synonym: embolia cutis medicamentosa) is a rare complication of subcutaneous and IM drug injections, typically independent of the drug itself.¹ Patients develop painful purpuric and necrotizing lesions at the injection site, often requiring surgical intervention. The pathogenesis of the ischemic skin necrosis is poorly understood. We report 2 cases of skin necrosis associated with injection of glatiramer acetate (GA) in patients with multiple sclerosis (MS), which occurred in close temporal relation to the second dose of a severe acute respiratory syndrome coronavirus 2 (SARS-CoV2) mRNA vaccine.

Case 1

A 62-year-old man with a history of hyperlipidemia, obesity (body mass index of 30.1 kg/m²), and MS received the first dose of the BNT162b2 vaccine in late March 2021.² The patient had been stable on GA 40 mg three times a week (Glatopa) for the past 5 years without new MRI lesions or relapses and no serious injection reactions. An injection of GA given in the lateral abdomen 17 days after the first vaccine dose resulted in retiform purpura surrounding the injection site (Figure, A). The purpura appeared 1 day before the second dose of the BNT162b2 vaccine and subsequently continued to spread (Figure, B). The injection site developed a necrotic black eschar (Figure, C). A punch biopsy obtained 14 days after vaccine dose 2 contained fibrin thrombi in the superficial and deep dermis, along with tissue necrosis indicative of thrombotic vasculopathy (Figure, D). Continued administration of GA after appearance of purpura did not lead to any further injection site reactions.

Case 2

A 59-year-old woman with a history of hypertension and MS received the first dose of the mRNA-1273 vaccine in early March 2021.³ The patient had been stable on GA 40 mg three times a week (Copaxone) for more than 10 years without new MRI lesions or relapses. One week after the first vaccine dose, a large welt developed at the site of a GA injection near her right hip. Over the next few weeks, retiform purpura developed around the injection site. A central necrotic eschar developed when she received the second dose of the mRNA-1273 vaccine 4 weeks later, which enlarged over the next 7 days (Figure, E and F). She developed severe burning pain at the site of the wound, and the wound was debrided. Her local dermatologist diagnosed her with Nicolau syndrome but did not perform a biopsy. GA injections continued at other sites throughout the development of this purpuric skin lesion without further reactions. Roughly 10 years ago, she had experienced 1 skin reaction after GA injection that did not develop into the large ischemic lesion observed in the current case.

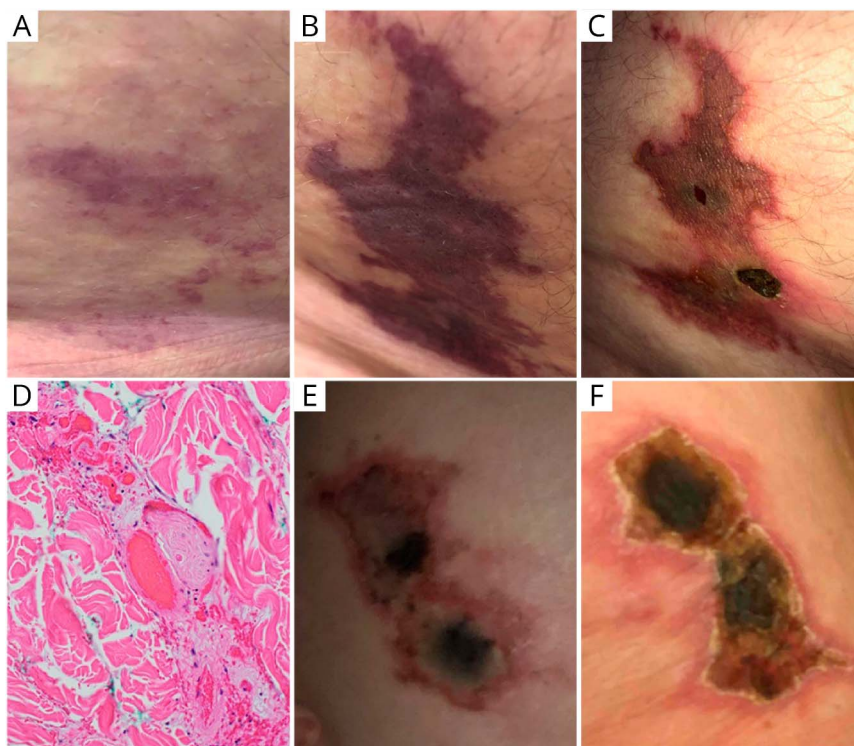
From the Department of Neurology (M.Y.S., E.F., U.B), Department of Pathology (L.D.), and Department of Dermatology (N.R.), University of California, Irvine.

Go to [Neurology.org/NN](https://www.neurology.org/NN) for full disclosures. Funding information is provided at the end of the article.

The Article Processing Charge was funded by the authors.

This is an open access article distributed under the terms of the Creative Commons Attribution-NonCommercial-NoDerivatives License 4.0 (CC BY-NC-ND), which permits downloading and sharing the work provided it is properly cited. The work cannot be changed in any way or used commercially without permission from the journal.

Figure Development of Retiform Purpura With Central Necrosis After Injection of Glatiramer Acetate (GA) in Close Association With Administration of BNT162b2 (A–D) and mRNA-1273 Vaccine (E and F)



(A–C) Days 2 (A), 5 (B), and 14 (C) after injection of GA in close association with the BNT162b2 vaccine. (D) Representative micrograph of punch biopsy of cutaneous lesion revealing intravascular fibrin thrombi at day 14 ($\times 200$). (E and F) Four weeks (E) and 5 weeks (F) after GA injection in close association with the mRNA-1273 vaccine.

Discussion

The COVID-19 pandemic has placed enormous health and economic burden on the worldwide community. The mRNA vaccines from Pfizer (BNT162b2) and Moderna (mRNA-1273) are notable achievements, highly effective in preventing severe COVID-19 syndromes.^{2,3} Our second patient reported typical side effects including fever, fatigue, headache, chills, and muscle pain, whereas the first patient had no side effects. Complications related to drug interactions in specific populations have not been reported.

Nicolau syndrome is an exceedingly rare, adverse event in GA-treated patients with MS.^{1,4} Occurrence of Nicolau syndrome in 2 patients with MS at our MS center in close proximity to SARS-CoV2 vaccination with mRNA vaccines raises the possibility of an association between the 2. No other reports of similar skin lesions were observed in our vaccine program at UC Irvine. Our MS center currently has 224 patients on GA, with an estimated 70%–80% having received a SARS-CoV2 vaccine. Of interest, the joint targets of both interventions are professional antigen-presenting dendritic cells (DCs): mRNA vaccines work via mRNA delivery to DCs at the injection site, which then produce and present mRNA-encoded viral antigen to initiate an immune response.⁵ Although the mechanisms of GA on the immune system are broad, DCs act as the initial target for drug uptake and presentation.⁶ Both patients

have been stable on GA, and both tested positive for antibodies against SARS-CoV2 4 months after vaccination.

We report these cases to make MS centers aware of this potential complication. Although our 2 observations are by no means a proof of causation, they suggest that providers and patients should carefully monitor GA injections in close proximity to SARS-CoV2 vaccinations with mRNA vaccine. A timely response coordinated with dermatology has been reported to prevent necrosis and scar formation, but it is unclear whether this approach may also be successful under these new circumstances.⁷ Of note, our observation may also be of relevance for other injectables, as Nicolau syndrome has also been observed with other substances, and may be attributed to mechanical affection of the tissue rather than to drug-related effects.

Study Funding

No targeted funding reported.

Disclosure

The authors report no disclosures relevant to the manuscript. Go to [Neurology.org/NN](https://www.neurology.org/NN) for full disclosures.

Publication History

Received by *Neurology: Neuroimmunology & Neuroinflammation* April 30, 2021. Accepted in final form August 30, 2021.

Appendix Authors

Name	Location	Contribution
Michael Yu Sy, MD, PhD	Department of Neurology, University of California, Irvine	Drafting/revision of the manuscript for content, including medical writing for content; major role in the acquisition of data; study concept or design; and analysis or interpretation of data
Erin Fromm, RN	Department of Neurology, University of California, Irvine	Major role in the acquisition of data and study concept or design
Linda Doan, MD, PhD	Department of Pathology, University of California, Irvine	Drafting/revision of the manuscript for content, including medical writing for content, and major role in the acquisition of data
Nathan Rojek, MD	Department of Dermatology, University of California, Irvine	Drafting/revision of the manuscript for content, including medical writing for content, and major role in the acquisition of data

Appendix (continued)

Name	Location	Contribution
Alexander Ulrich Brandt, MD	Department of Neurology, University of California, Irvine	Drafting/revision of the manuscript for content, including medical writing for content; major role in the acquisition of data; study concept or design; and analysis or interpretation of data

References

1. Kimbrough DJ, Newsome SD. Case report: two cases of Nicolau syndrome associated with glatiramer acetate. *Int J MS Care*. 2017;19(3):148-150.
2. Polack FP, Thomas SJ, Kitchin N, et al. Safety and efficacy of the BNT162b2 mRNA Covid-19 vaccine. *N Engl J Med*. 2020;383(3):2603-2615.
3. Baden LR, Sahly HME, Essink B, et al. Efficacy and safety of the mRNA-1273 SARS-CoV-2 vaccine. *N Engl J Med*. 2021;384(3):403-416.
4. Bosca I, Bosca M, Belengeur A, et al. Necrotising cutaneous lesions as a side effect of glatiramer acetate. *J Neurol*. 2006;253(3):1370-1371.
5. Pardi N, Hogan MJ, Porter FW, Weissman D. mRNA vaccines—a new era in vaccinology. *Nat Rev Drug Discov*. 2018;17(3):261-279.
6. Prod'homme T, Zamvil SS. The evolving mechanisms of action of glatiramer acetate. *Cold Spring Harb Perspect Med*. 2019;9(3):a029249.
7. Geukens J, Rabe E, Bieber T. Embolias cutis medicamentosa of the foot after sclerotherapy. *Eur J Dermatol*. 1999;9(3):132-133.