




# Imaging in Carcinoma Cervix and Revised 2018 FIGO Staging System: Implications in Radiology Reporting

Ekta Dhamija<sup>1</sup>  Malvika Gulati<sup>1</sup> Smita Manchanda<sup>1</sup> Seema Singhal<sup>2</sup> Dayanand Sharma<sup>3</sup>  
Sunesh Kumar<sup>2</sup> Neerja Bhatla<sup>2</sup>

<sup>1</sup> Department of Radiodiagnosis, Dr B.R.A. IRCH, All India Institute of Medical Sciences, New Delhi, India

<sup>2</sup> Department of Obstetrics & Gynaecology, All India Institute of Medical Sciences, New Delhi, India

<sup>3</sup> Department of Radiation Oncology, All India Institute of Medical Sciences, New Delhi, India

Address for correspondence Dr. Ekta Dhamija, MD, Department of Radiodiagnosis, Dr B.R.A. IRCH, All India Institute of Medical Sciences, Room number 137, First Floor, New Delhi 110029, India (e-mail: drektadhamija.aiims@gmail.com).

Indian J Radiol Imaging 2021;31:623–634.

## Abstract

### Keywords

- ▶ FIGO staging
- ▶ carcinoma cervix
- ▶ diffusion-weighted imaging
- ▶ cervical malignancies

The International Federation of Gynecology and Obstetrics (FIGO) staging system of carcinoma cervix saw a radical change in 2018 with the inclusion of cross-sectional imaging tools for the assessment of disease extent and staging. One of the major revisions is the inclusion of lymph node status, detected either on imaging or pathological evaluation, in the staging system. The changes were based on long-term patient follow-up and survival rates reported in literature. Thus, it becomes imperative for a radiologist to be well versed with the recent staging system, its limitations, and implications on the patient management.

## Introduction

Carcinoma cervix is the second most common malignancy in women in the developing world, which accounted for an estimated 311,365 deaths worldwide in the year 2018.<sup>1</sup> The prognosis and survival depend on the stage of the malignancy: the 5-year survival drops from approximately 92% in stage 1 to just 17% in stage IV disease.<sup>2</sup> The staging system for any cancer aims to define the anatomical extent of the disease, which guides the appropriate management strategy. Uniformity and precision of protocols allow appropriate comparison of data from different centers/hospitals. Until recently, carcinoma cervix was the only gynecological malignancy to be staged clinically, with some basic investigations limited to chest radiography, intravenous urography, barium enema, cystoscopy, proctoscopy, and sigmoidoscopy.<sup>3</sup> However, with the

development of advanced imaging modalities like computed tomography (CT), magnetic resonance imaging (MRI), and positron emission tomography (PET) that are able to delineate the extent of disease preoperatively, the need for incorporation of these into the staging system became evident.<sup>4</sup> Hence, the 2009 version of FIGO (International Federation of Gynecology and Obstetrics) staging for carcinoma cervix has been amended and updated in 2018 with the inclusion of cross-sectional imaging.<sup>5</sup> The recent update does not strictly mandate the use of any given modality, rather it gives various options that could be used according to the resource setting one works in. Hence, it becomes important for radiologists in oncology practices to be aware of the imaging modalities available, with their appropriate role and limitations; and the changes in the staging system to assist in planning the management. ▶ **Table 1** highlights the differences in the 2009

DOI <https://doi.org/10.1055/s-0041-1735502>.  
ISSN 0971-3026.

© 2021. Indian Radiological Association. All rights reserved.  
This is an open access article published by Thieme under the terms of the Creative Commons Attribution-NonDerivative-NonCommercial-License, permitting copying and reproduction so long as the original work is given appropriate credit. Contents may not be used for commercial purposes, or adapted, remixed, transformed or built upon. (<https://creativecommons.org/licenses/by-nc-nd/4.0/>)  
Thieme Medical and Scientific Publishers Pvt. Ltd., A-12, 2nd Floor, Sector 2, Noida-201301 UP, India

**Table 1** Two FIGO staging systems of 2009 and 2018 with modifications<sup>5</sup>

Stage	2009 FIGO staging	2018 (current) FIGO update
I	The carcinoma is strictly confined to the cervix uteri (extension to the corpus should be disregarded).	The carcinoma is strictly confined to the cervix uteri (extension to the corpus should be disregarded) <i>Stage IB has modifications.</i>
IA	Invasive carcinoma that can be diagnosed only by microscopy, with maximum depth of invasion <5 mm.	No change
IA1	Measured stromal invasion $\leq 3$ mm in depth	No change
IA2	Measured stromal invasion >3 mm and <5 mm in depth	No change
IB	Invasive carcinoma with measured deepest invasion >5 mm (greater than stage IA), lesion limited to the cervix uteri, independent of lateral extension.	Invasive carcinoma with measured deepest invasion >5 mm (greater than stage IA), lesion limited to the cervix uteri, independent of lateral extension.
1B1	$\leq 4$ cm	Invasive carcinoma >5 mm depth of stromal invasion and $\leq 2$ cm in greatest dimension
1B2	>4 cm	Invasive carcinoma >2 cm and $\leq 4$ cm in greatest dimension
<b>1B3</b>	–	Invasive carcinoma >4 cm in greatest dimension
II	The carcinoma invades beyond the uterus but has not extended onto the lower third of the vagina or to the pelvic wall.	No change
IIA	Involvement limited to the upper two-thirds of the vagina without parametrial involvement. IIA1 Invasive carcinoma $\leq 4$ cm in greatest dimension. IIA2 Invasive carcinoma $\geq 4$ cm in greatest dimension.	No change
IIB	With parametrial involvement but not up to the pelvic wall.	No change
III	The carcinoma involves the lower third of the vagina and/or extends to the pelvic wall and/or causes hydronephrosis or nonfunctioning Kidney.	The carcinoma involves the lower third of the vagina and/or extends to the pelvic wall and/or causes hydronephrosis or nonfunctioning kidney and/or involves pelvic and/or paraaortic lymph nodes. <i>Stage IIIC has modifications</i>
IIIA	Carcinoma involves the lower third of the vagina, with no extension to the pelvic wall.	No change
IIIB	Extension to the pelvic wall and/or hydronephrosis or nonfunctioning kidney (unless known to be due to another cause).	No change
<i>IIIC</i>	–	<i>Involvement of pelvic and/or paraaortic lymph nodes, irrespective of tumor size and extent (with r and p notations)</i>
<i>IIIC1</i>	–	<i>Pelvic lymph node metastasis only</i>
<i>IIIC2</i>	–	<i>Paraortic lymph node metastasis</i>
IV	The carcinoma has extended beyond the true pelvis or has involved (biopsy proven) the mucosa of the bladder or rectum. A bullous edema, as such, does not permit a case to be allotted to stage IV.	No change
IVA	Spread of the growth to adjacent organs.	No change
IVB	Spread to distant organs	No change

and 2018 FIGO staging of carcinoma cervix. There have been modifications especially for Stage 1 and 3 based on their impact on patient prognosis (–Table 1 highlights the two grading systems).

## Imaging Modalities: Benefits and Limitations

The only diagnostic modalities approved in the 2009 FIGO cervical carcinoma staging system were chest radiography for the assessment of pulmonary metastasis; intravenous urography (IVU) to rule out obstructive uropathy; barium enema, cystoscopy, proctoscopy, and sigmoidoscopy to determine local infiltration into the urinary bladder or rectum.<sup>3</sup> However, with the wide availability of noninvasive cross-sectional techniques of contrast-enhanced CT and MRI, modalities like IVU and barium enema are seldom performed in present times. The imaging modalities often used for evaluation of carcinoma cervix and their limitations are discussed below:

### Transvaginal Ultrasonography

TVUS is the initial imaging modality of choice for evaluation of any gynecological disease due to its ready availability and lack of radiation exposure. Due to its low cost, it can be widely used in resource-constrained settings where cervical malignancies are more common. Needing no specific patient preparation, it is conducted on the patient lying supine on the couch with an empty bladder using the high frequency (5/7.5 MHz) endovaginal USG probe. Visualization of cervix, uterus, parametrium, and ovaries in high resolution is possible with TVUS (–Fig. 1a, b). It is fairly accurate in assessing tumor size as compared with MRI, especially in the setting of early stage disease<sup>6–8</sup> and it has been shown to detect parametrial infiltration with sensitivity and specificity of 77 and 98%, respectively.<sup>6</sup> Studies have shown the results to be comparable to MRI for assessment of local disease staging,<sup>6–8</sup> as described in –Table 2.

TVUS effectively demonstrates the presence of hydro/pyometra, depth of stromal invasion, extension of tumor into uterine corpus; however, it fails to evaluate lymph node involvement due to the limited field of

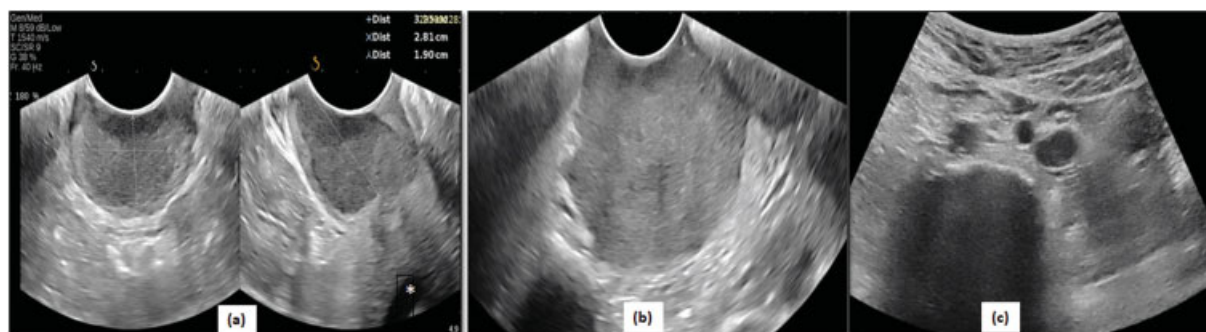
view.<sup>8,10–12</sup> Operator dependency, need of expertise and skill, and small field of view limiting evaluation of lymph node status and rectal infiltration preclude it from becoming the primary imaging modality. TVUS with transabdominal ultrasound may be considered in resource-constrained setting as the latter has better ability to detect lymph nodes (–Fig. 1c), hydronephrosis, and abdominal metastases.<sup>7</sup>

### Transrectal Ultrasonography

TRUS is an excellent alternative for patients who are not comfortable with TVUS due to excessive bleeding from fragile tumor growth and to assess the endophytic (stromal) component of a bulky exophytic tumor. Through the rectal mucosal window, visualization of anterior rectal mucosa, rectal muscular layer, vagina, cervix and paracervical tissue is possible (–Fig. 2). The sensitivity of TRUS in predicting parametrial invasion ranges from 87 to 95%<sup>13,14</sup> with specificity reported to be 100% in some studies<sup>10</sup> and its accuracy in detection of tumor reaches up to 93.6% as compared with gold standard MRI (83.1%).<sup>10,15</sup> It is also superior to CT in correctly depicting the local stage of the disease.<sup>16</sup>

### Computed Tomography

Helical CT with the administration of intravenous contrast and image acquisition in the venous phase is the standard for CT in assessing carcinoma cervix patients. Use of oral contrast to opacify small bowel loops is routinely given at our center, while rectal contrast is only given in the situation of suspicion of rectal infiltration or fistula. Delayed images (approximately 10 minutes) can be acquired in select cases for better characterization of ureteric involvement. Assessment of parametrial extension can be performed on CT with accuracy of 59%.<sup>17</sup> A rapid acquisition using wide field of view in CT enables to detect lymph nodes, hydronephrosis, lateral pelvic wall involvement, and distant metastases as well<sup>18–21</sup> (–Figs. 3,4,5). It has also been shown that negative predictive value of CT in depicting bladder infiltration reaches up to 100% which avoids the need for an invasive procedure like cystoscopy for the evaluation of the urinary bladder.<sup>22</sup> Lymph nodes are considered suspicious based on either the size criteria (>10 mm in short axis) or the presence of necrosis. However, nodal enlargement due to other



**Fig. 1** Transvaginal (TVS) ultrasound in carcinoma cervix—(a) Transverse and longitudinal gray scale TVS images showing a hypoechoic solid cervical mass well demarcated from the surrounding cervical stroma. (b) Gray scale TVS image shows large cervical mass with bilateral parametrial infiltration. (c) Transabdominal ultrasound shows enlarged hypoechoic left para-aortic nodes, thus upgrading the stage-to-stage IIIC for the patient.

**Table 2** Studies comparing TVS and MRI in staging of cervical carcinoma

Author	Year	n	Study design	Modalities compared	Parameters														
					Tumor identification			Vaginal infiltration			Parametrial infiltration			Lymph nodes					
					Sensitivity (%)	FP	Specificity (%)	Agreement (%)	Sensitivity (%)	FP	Agreement (%)	Sensitivity (%)	FP	Agreement (%)	Sensitivity (%)	FP	Agreement (%)		
Testa et al <sup>7</sup>	2009	68	p	TVS + TAS vs. MRI	93 vs. 88	50 vs. 38	NA	88	33 vs. 0	3 vs. 5	94	60 vs. 40	NA	87	11 vs. 11	9 vs. 27	0 vs. 4	91	
Epstein et al <sup>6</sup>	2013	182	p	TVS vs. MRI	90 vs. 67	NA	97 vs. 89	96 vs. 86	NA	NA	NA	77 vs. 69	98 vs. 92	97 vs. 90	NA	NA	NA	NA	NA
Moloney et al <sup>8</sup>	2016	46	p	TVS vs. MRI	NA	NA	NA	NA	NA	NA	NA	20 vs. 40	89 vs. 86	NA	NA	NA	NA	NA	NA
Ma et al <sup>9</sup>	2017	52	p	TVS vs. MRI	NA	NA	NA	NA	NA	NA	NA	18.1 vs. 72.73	71.43 vs. 79.49	NA	NA	NA	NA	NA	NA

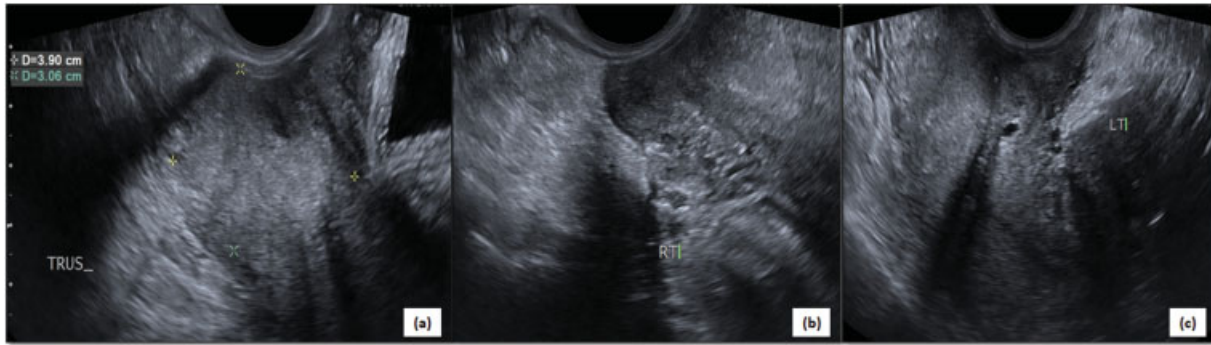
Abbreviations: FP, false positive; n, subjects included; p, prospective; TAS, transabdominal ultrasound; TVS, transvaginal ultrasound.

causes like inflammation or infection remains a problem. In spite of its shortcomings, its ability to provide an overview of the locoregional and distant spread of the disease, justifies its use as a baseline staging modality in resource-constrained settings where MRI is not readily available or is unavailable.<sup>23</sup> ▶ **Table 3** enumerates the studies comparing CT with MRI.

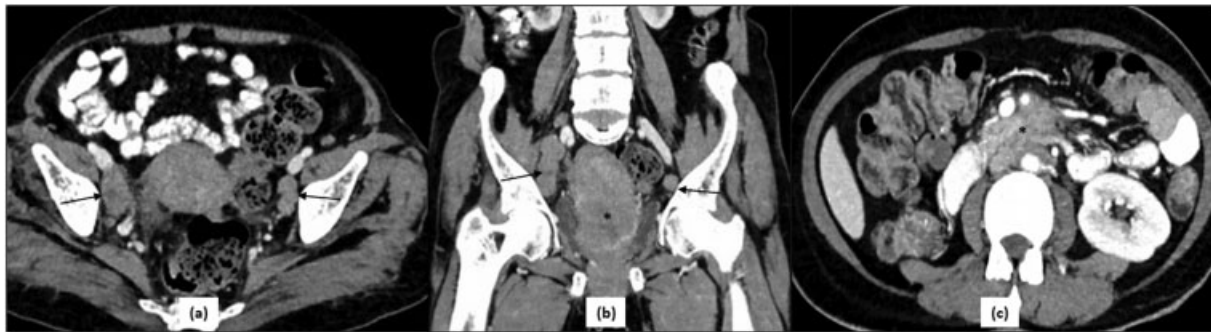### Magnetic Resonance Imaging

Zonal anatomy of the cervix is very well visualized on a T2-weighted MR image as three different layers: the inner hyperintense layer comprises of the mucosa and secretions in the cervical canal; the middle layer is T2 dark due to tightly packed fibroblasts and smooth muscle cells and is continuous with the junctional zone of uterine corpus; the outer stromal layer is intermediate in signal and in continuity with the outer myometrium. This trilaminar appearance can also be appreciated on post-contrast MR images due to differential enhancement of these layers.<sup>25–27</sup> Due to this excellent soft tissue resolution and multiplanar capability, MRI is ideally suited to locally stage the disease.<sup>9,20,28</sup> Axial and sagittal T2WI with acquisition along the plane of the cervix are the main sequences to assess the tumor, which appears as bright or intermediate signal intensity against the T2 dark cervical stroma. Extension into the parametrium is seen as a disruption of the T2 dark stromal ring around the cervix, with MRI having higher sensitivity and specificity for the same when compared with USG<sup>8,9</sup> (▶ **Fig. 6**). Distention of the vaginal canal with jelly aids in the assessment of vaginal infiltration, particularly in the region of posterior fornix.<sup>29</sup> Larger field of view facilitates detection of lymph nodes in the pelvic and para-aortic region with accuracy of 97 and 67%, respectively.<sup>28</sup> Sensitivity up to 87% and specificity of 79% in demonstrating vaginal involvement make MRI an important part of preoperative staging of these masses.<sup>28</sup> By virtue of its superior soft tissue resolution, MRI is the modality of choice for planning of brachytherapy for patients with locally advanced disease,<sup>30</sup> wherever possible.

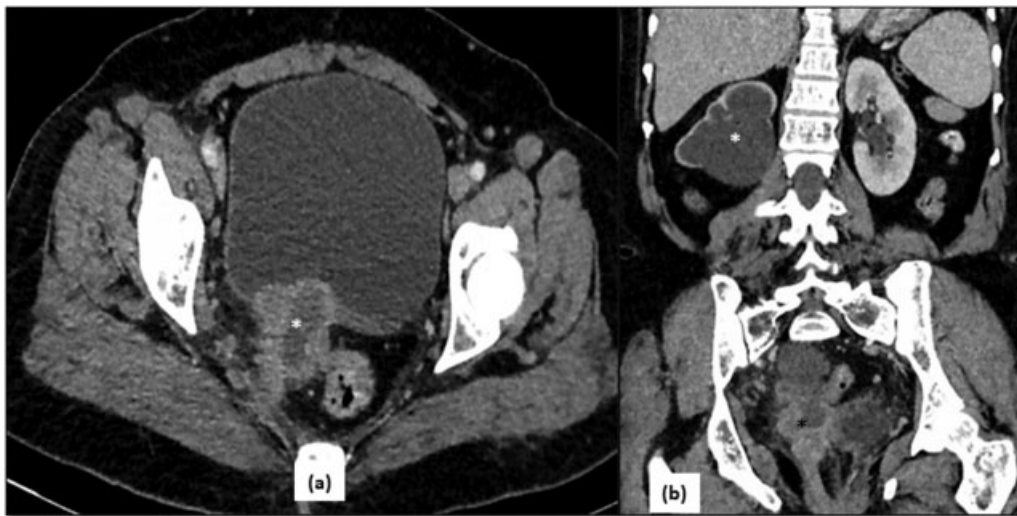
Functional MRI techniques like diffusion-weighted image (DWI), routinely used in neuroimaging, is based on the concept of Brownian motion. That means that the tightly packed malignant cells show high signal or restriction of movement on DWI as compared with normal tissue, which enables prompt detection of the tumor growth (▶ **Fig. 7**). The corresponding ADC (apparent diffusion coefficient) maps of the tumor, derived from DWI at various “b” values (0–1,000 second mm<sup>2</sup>) show low signal. Studies have shown that quantitative assessment of these ADC maps in serial scans has a role in the assessment of treatment response in these tumors. Higher ADC values after radiotherapy predict a favorable response.<sup>27,31–33</sup> Similarly, dynamic contrast-enhanced MRI (DCE-MRI) assesses perfusion characteristics of the tissues which can assist in response evaluation during follow-up of patients. Rapid decrease in perfusion characteristics after radiation denotes a good response. Detection of rapidly enhancing tissue in the operative or radiation bed could detect early recurrence.<sup>34–36</sup> Contrast-enhanced MRI is rarely needed in baseline imaging as it does not improve



**Fig. 2** Transrectal ultrasound of carcinoma cervix—(a–c) Images of transrectal ultrasound of a lady with proven cervical malignancy show an irregular isoechoic mass replacing the normal stroma of posterior lip of cervix (callipers in a). The mass is infiltrating bilateral parametrium (b, c).



**Fig. 3** CT in stage IIIC of carcinoma cervix—(a) Axial and (b) coronal reformatted images of a patient with carcinoma cervix reveal a large irregular heterogeneous mass (*asterisk* in b) replacing the normal cervix and extending into the uterine body. In addition to the primary mass, there are enlarged lymph nodes along bilateral iliac vessels (*black arrows*) with few showing necrosis within; and conglomerate nodal mass (*asterisk*) in the preaortic location (c) representing stage IIIC according to 2018 FIGO staging system.



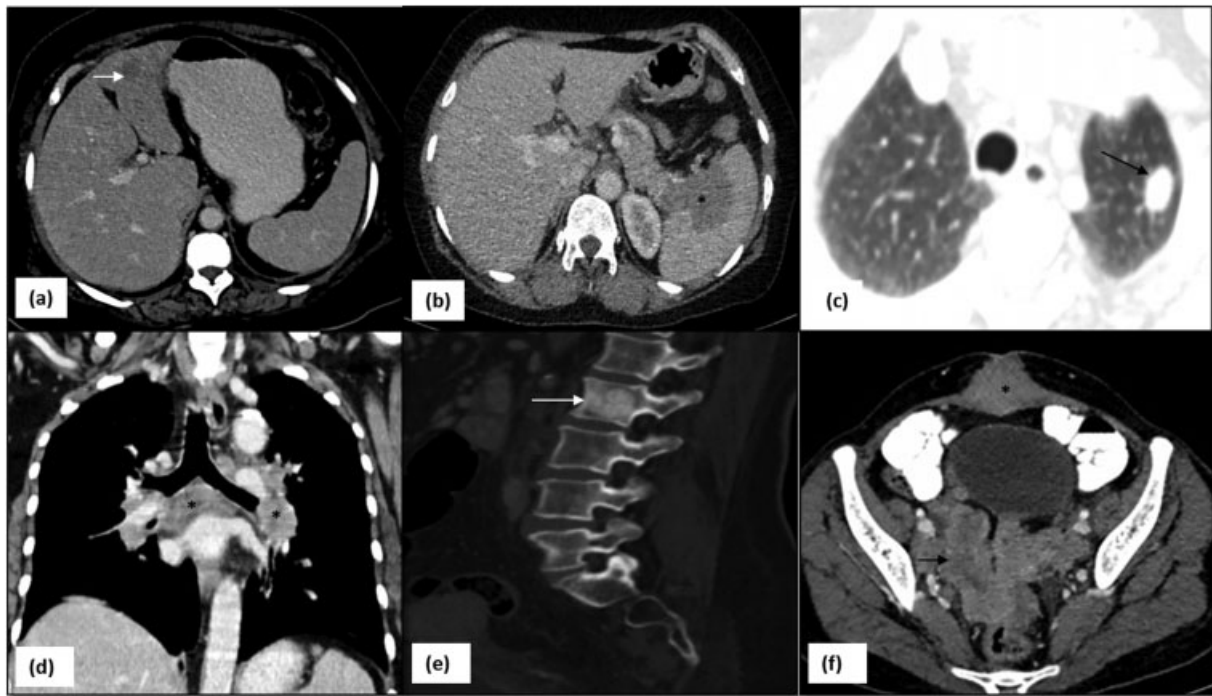**Fig. 4** CT in stage IVA of carcinoma cervix—(a) Axial CT image shows an irregular heterogeneous mass in the cervix with central necrosis (*asterisk* in a) infiltrating the urinary bladder anteriorly and reaching up to the lateral pelvic wall posterolaterally on the right side. (b) There is upstream right hydronephrosis (*white asterisk*) due to encasement of lower ureter by the mass (*black asterisk*).

staging accuracy, in addition to the scanning time and cost constraints.<sup>37</sup>

In spite of MRI being the ideal modality to stage the disease, its limited availability in the low- and middle-income group regions, makes it an underutilized modality.

**PET**

18 FDG PET-CT has a limited role in local staging of the early disease; however, it has the highest sensitivity and specificity in the detection of nodal and distant metastasis measuring >10 mm.<sup>38</sup> Smaller nodes harboring metastasis though not fulfilling the morphological criteria can be detected on PET-



**Fig. 5** CT images showing various sites of metastatic disease in carcinoma cervix: (a) liver (arrow), (b) spleen (asterisk), (c) lung (arrow), (d) mediastinal lymph nodes (asterisk), (e) sclerotic metastasis in vertebrae (arrow), (f) abdominal wall (asterisk), serosal deposits (arrow).

CT. False positives are seen due to inflammatory or infective causes which have to be resolved by fine needle aspiration cytology (FNAC) or surgical dissection. The risk of lymph nodal metastasis considerably increases with larger tumors.<sup>39</sup> Thus the sensitivity of PET-CT also improves with increasing tumor sizes. Recurrent disease in the pelvis can be detected early in post treatment surveillance due to uptake in the cancerous cells.

#### Choice of Imaging Modality

The current staging system strives to adapt to all types of resource settings and does not mandate the use of a specific modality for staging. In fact, clinical staging may continue to be used where other techniques are not available.<sup>5</sup> With the wide gamut of choices available, MRI definitely scores over other cross-sectional modalities in assessing the loco regional extent of disease,<sup>18</sup> while PET-CT performs better in the detection of lymph nodes and small distant metastasis.<sup>39</sup> In the event of nonavailability of MRI, PET-CT and pathology services, CT is a good modality for obtaining an overview of the local disease, distant metastasis,<sup>23</sup> and detection of recurrence (→ Fig. 8). TVS/TRUS can suffice in the case of small cervical masses. → Table 4 describes the advantages and disadvantages of each modality.

#### Revised Staging System FIGO 2018

The 2009 FIGO staging system of carcinoma cervix was based on clinical assessment and allowed only few supportive techniques as enumerated above. It performed suboptimally with understaging of 20 to 40% stage IB–IIIB cancers

and overstaging of up to 64% stage IIIB cancers<sup>40–42</sup> that led a proportion of patients to undergo a toxic trimodality management regimen without any added survival benefit and significantly increased morbidity.<sup>43</sup> This also led to the wastage of resources in already resource-constrained setups.

Five-year survival rates were lower in patients having pelvic or para-aortic nodes for comparable tumor sizes.<sup>44–46</sup> A study showed that the 3-year disease-free survival (DFS) was 73.2% for stage IB2, 63.7% for IIA, 66.7% for IIB, 64.7% for IIIA, and 59.6% for IIIB when staged with 2009 FIGO system. However, the same patient group had 3-year DFS rates of 79.9% for stage IIIA, 70.4% for stage IIIB, 66.3% for stage IIIC1, and 29.8% for stage IIIC2, when staged according to the 2018 classification.<sup>45</sup>

Since cross-sectional imaging techniques have become more readily available and allow better depiction of local extent of disease, recommendations formulated by societies in the developed world recognized the importance of using these modalities for the assessment of lymph node metastasis.<sup>47,48</sup> Thus, the FIGO Gynaecologic Oncology Committee revised the FIGO staging system in 2018.

#### Modifications and Implications of 2018 FIGO Staging System

##### Stage I

Stage I comprises disease limited to the cervix. It is further classified into substages based on the disease prognosis and management. According to the 2018 staging, Stage IB is now subcategorized into three substages based on the tumor size as detailed below.

**Table 3** Characteristics of various studies comparing CT and MRI in staging of cervical carcinoma

Author	Year	n	Study design	Modalities compared	Parameters				Lymph nodes				Staging Accuracy
					Parametrial infiltration				Accuracy				
					Sensitivity (%)	Specificity (%)	PPV	NPV	Sensitivity (%)	Specificity (%)	PPV	NPV	
Özarlak et al <sup>20</sup>	2003	CT 32 MRI 29	R	CT vs. MRI	NA	NA	NA	NA	NA	NA	NA	NA	53 vs. 86
					NA	NA	NA	NA	NA	NA	NA	NA	NA
Bellomi et al <sup>24</sup>	2005	62	R	CT vs. MRI	NA	NA	NA	NA	Upper iliac	97.9 vs. 97.5	42.8 vs. 33.3	99.1 vs. 98.3	NA
									Lower iliac	88 vs. 88	61.5 vs. 62.9	95.9 vs. 96.9	
									Both	93.3 vs. 93.1	57.6 vs. 57.6	97.7 vs. 97.7	
Hancke et al <sup>17</sup>	2008	255	R	Clinical vs. CT vs. MRI	43 vs. 52	71 vs. 63	53 vs. 55	62 vs. 61	35 vs. 36	84 vs. 84	61 vs. 68	64 vs. 57	NA

Abbreviations: N, subjects included; NPV, negative predictive value; PPV, positive predictive value; r, retrospective.

Stage IA1, IA2—These comprise microscopic disease and hence cannot be detected on imaging. Treatment options include cone biopsy, trachelectomy, extrafascial hysterectomy with or without lymph node dissection depending on the presence of lymphovascular infiltration.<sup>49</sup>

Stage IB1,2—This has changed with an additional size bracket of 2 to 4 cm, since lesions >2cm have higher recurrence rates and lower 5-year survival figures than those <2 cm.<sup>44,50</sup> Use of imaging or pathology can now be used to measure the exact size of the tumor. TVS and MRI have comparable sensitivity and specificity for the same.<sup>7,8,10–12</sup> Masses smaller than 1 cm may be undetectable on conventional MR sequences due to poor tumor-stromal inherent contrast. This pitfall can be overcome by using DWI and DCE MR which improve the tissue contrast considerably.<sup>51,52</sup> CT, often more widely available in low resource setting than MRI, has a low sensitivity in detecting small masses. Although the involvement of the uterine corpus does not change the stage of the disease, its presence makes the candidate unsuitable for fertility-preserving vaginal or abdominal trachelectomy. For stage IB1, a radical hysterectomy is offered to the patient. For stage IB2, treatment options vary from neoadjuvant chemotherapy, radiotherapy, and hysterectomy according to the resource setting.<sup>4</sup> However, females wanting to retain their fertility have the option of a radical trachelectomy procedure.

Stage IB3—This category encompasses tumors >4 cm in size which have poor outcome and high requirement of adjuvant radiotherapy with up-front surgery, and hence they should be treated with chemoradiation.

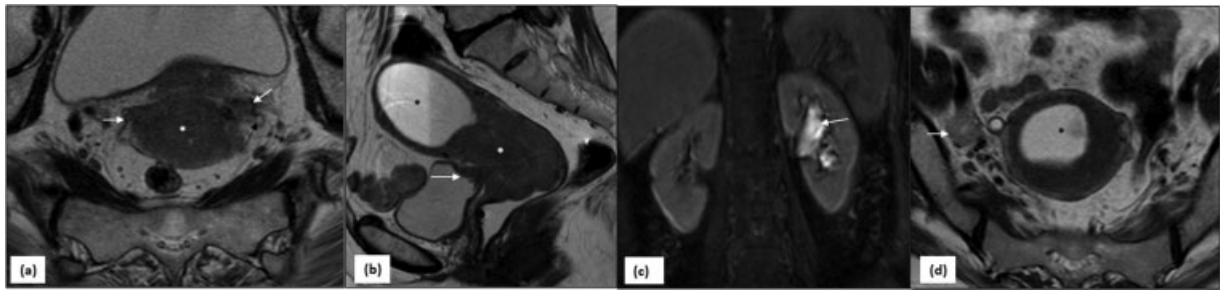
**Stage II: Remains Unchanged in Definition**

Although the definition of stage II is the same as in the FIGO 2009 classification, the allocation can be changed based on imaging findings.

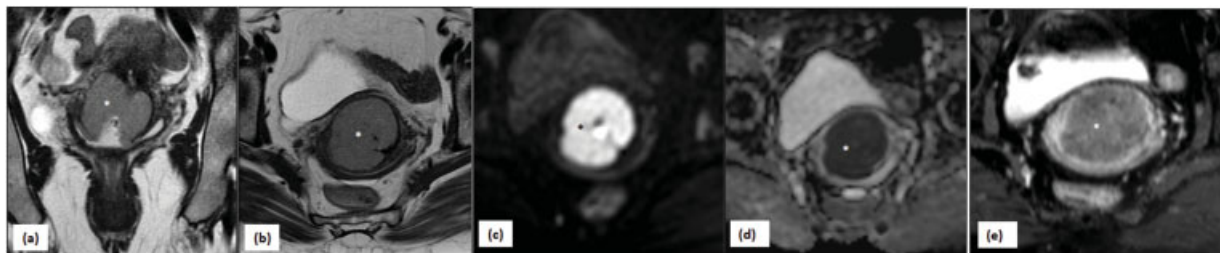
Stage IIA—Involvement of upper two-thirds of the vagina by the tumor without spread to parametrial tissue defines this stage. MRI is the imaging modality of choice for the assessment of vagina and distension of the vaginal canal with jelly increases the diagnostic confidence and accuracy for the detection of vaginal infiltration especially in the region of the posterior fornix.<sup>29</sup> This stage also has varying management options similar to stage IB2.

Large masses bulging into the fornix or presence of surrounding edema owing to recent cervical biopsy can pose challenges to MRI during staging. In such scenarios, erroneous over-staging of IB tumors to stage II and stage IIA to IIB is encountered.<sup>53–55</sup> Knowledge of interval from biopsy, distention of the vaginal canal by jelly for MRI acquisition, and DWI and DCE-MR can help avoid these pitfalls.<sup>29</sup>

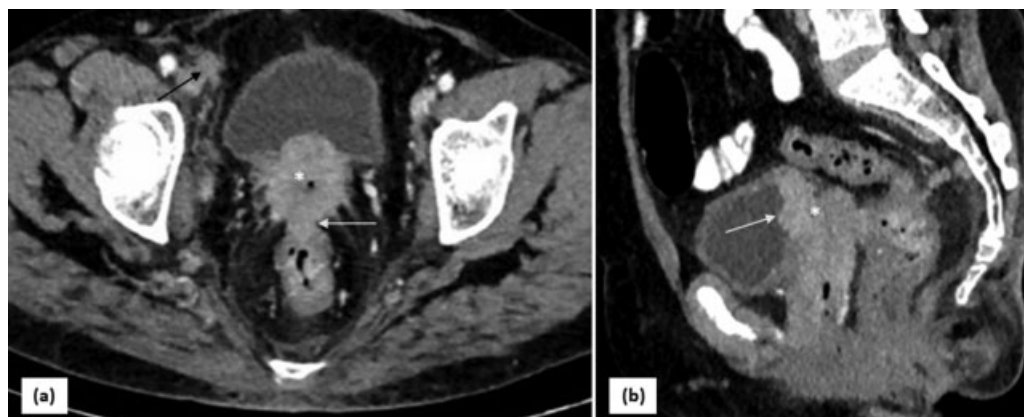
Stage IIB—Extension of tumor into the parametrium makes these patients unsuitable for curative surgical procedures. It is seen as a disruption of the T2 dark stromal ring around the cervix on MRI.



**Fig. 6** MRI in stage IVA of carcinoma cervix—(a) Axial and (b) sagittal T2W MRI images show infiltrative mass (*asterisk*) replacing the cervix with bilateral parametrial and posterior urinary bladder wall infiltration (*arrows*). Obstruction of cervical canal causes upstream hydrometra (*black asterisk*) with fluid debris within. (c) Encasement of left ureter (*black arrow* in a) has caused left hydronephrosis (*arrow* in c). (d) Axial section through the level of uterus in a different patient shows hydrometra with enlarged heterogeneous lymph node along the iliac vessels (*arrow*).



**Fig. 7** MRI in stage IIA of carcinoma cervix—(a) T2-weighted coronal and (b) axial images show a well-defined hyperintense mass (*asterisk*) involving cervix extending into the fornices. The peripheral hypointense stromal ring is well seen with no parametrial extension. Although the tumor to cervix contrast is well appreciated on T2 WI; the (c) DWI, (d) ADC, and (e) post-contrast sequences delineate the tumor better with confirmation of no parametrial infiltration. ADC, apparent diffusion coefficient; DWI, diffusion-weighted image.



**Fig. 8** CT in recurrent carcinoma cervix—(a) Postoperative follow-up axial CT image shows an irregular recurrent growth in the vault (*asterisk*) which is infiltrating the rectum posteriorly (*arrow*). (b) Sagittal reformatted image shows infiltration of the posterior wall of urinary bladder (*arrow*) by the mass. Enlarged lymph node with irregular margins is seen along right external iliac vessels (*black arrow* in a).

### Stage III: Major Modification with Addition of Stage IIIC

Stage IIIA—Involvement of lower one-third of vagina upgrades the tumor to stage IIIA. Clinical examination is fairly accurate for assessment, and MRI may compliment the examination findings.

Stage IIIB—Extension of the tumor involving the lateral pelvic wall denotes stage IIIB of disease. Tumor tissue within 3 mm of lateral pelvic walls or involvement of pyriformis muscle, levator ani, obturator muscle, or internal iliac vessels suggests lateral pelvic wall involvement.<sup>56</sup>

Obstructive hydronephrosis due to involvement of ureter is a sign of stage IIIB. Various modalities such as ultrasonography, CT, or MRI can aid in this assessment.

Stage IIIC—Recognition of metastatic nodes in the pelvis or para-aortic region by imaging or pathology upstages the disease to stage IIIC unlike the previous staging system. It was found that for similar tumor sizes and local infiltration, the presence of metastatic nodes decreased the survival rates and worsened the prognosis.<sup>46</sup> Even in the event of locally resectable disease, the presence of metastatic lymph nodes did not justify the local surgery. Various validation studies published recently have



**Table 4** Imaging modalities for carcinoma cervix

Modality	Advantages	Disadvantages
TVS	Affordable and readily available Comparable with MRI for: Size estimation Depth of stromal invasion Parametrial infiltration.	Require skill and expertise Operator dependent Discomfort if fragile or large exophytic tumors Limited evaluation for: Lateral pelvic wall involvement Lymph nodes
TRUS	Similar to TVS, more comfortable in patients with heavy bleeding from fragile tumors.	Same technical limitations as TVS due to small FOV
CECT	Advanced tumors staging better, Lateral pelvic wall involvement Excellent NPV to rule out bladder involvement Lymph nodes Distant metastasis	Missing of small tumors Unable to differentiate metastatic from inflammatory nodes
MRI	Detection and accurate measurement of small tumors Parametrial and lateral pelvic wall involvement	Time consuming Difficult to perform in claustrophobic patients Costly Difficult to differentiate metastatic from inflammatory nodes
PET CT	Lymph nodes Distant metastasis Response assessment	Inaccurate size estimation, parametrial infiltration

Abbreviations: CECT, contrast-enhanced computed tomography.; MRI, magnetic resonance imaging; NPV, negative predicted value; PET, positron emission tomography; TRUS, transrectal ultrasonography; TVS, transvaginal sonography.

showed better prognostic stratification of patients when staged according to the new staging system.<sup>44,45</sup>

Lymphatic drainage of the cervix is via three pathways namely: the lateral, hypogastric (internal iliac), and presacral routes. The lateral route is along the external iliac vessels and drains into the external iliac nodes and finally into the common iliac nodes, which also receive drainage from the deep inguinal nodes. The internal iliac group is the other pathway and also includes nodes at the bifurcation of common iliac vessels. The presacral group also drains to the common iliac lymph node chains. All chains ultimately drain into paraaortic lymph nodes.<sup>24,57</sup> PET-CT has the highest sensitivity and specificity in detecting lymph nodal metastasis.<sup>28,38</sup> CT and MRI can predict metastatic nodes usually by size criteria or presence of necrosis; however, MRI has higher sensitivity (60%) than CT (43%) and comparable specificity.<sup>18</sup>

Due to false positives and negatives, pathology correlation may be needed in certain circumstances. Options available include image-guided FNAC, surgical dissection, or sentinel lymph node biopsy. Sentinel lymph node biopsy technique comprises the injection of a dye into the tumor and sampling the first lymph nodal bed draining it. It is an established technique for axillary nodal metastasis in cases of breast and vulval carcinoma. Its use in cervical cancer is still under evaluation.<sup>58,59</sup>

#### Stage IV—Remains Unchanged in Definition

Stage IVA: MRI is fairly good in predicting the extension of the tumor into the rectum or bladder. CT has lower

sensitivity and specificity as compared with MRI (71 vs. 75% and 73 vs. 91%, respectively).<sup>18</sup> Cystoscopy and proctoscopy with guided biopsy is warranted in select cases to see for local infiltration of cervical cancer.

Stage IVB: About 13% of patients are diagnosed with advanced-stage disease having distant metastasis. Five-year survival in such patients drop to 16.5% compared with 91.5% for localized cervical cancer.<sup>60</sup> Imaging can visualize sites and burden of distant metastatic disease.

In brief, the new FIGO 2018 staging system:

- Allows the use of imaging and/or pathology in designating the stage of the disease. The notation p (pathology) and r (imaging) should be recorded as used for staging.
- Divides stage IB1 into categories to stratify disease limited to the cervix according to sizes <2 cm, 2 to 4 cm and >4 cm, recognizing the higher mortality in patients having masses >2 cm, and distinguishes lesions suitable for the fertility-preserving procedure of radical trachelectomy.
- Includes lymph nodes in the classification: earlier, lymph nodal disease, even if recognized and confirmed on pathology, did not upgrade the tumor, although it reduced the survival substantially with not much benefit from surgery. According to the FIGO 2018 staging, the presence of metastatic pelvic or para-aortic nodes detected by cross-sectional imaging or pathology, upstages disease of any size to stage IIIC. Recognizing metastatic lymph nodal disease as stage IIIC has treatment and prognostic implications. Nodal metastases render the disease

inoperable with a curative intent and emphasizes on expanding the radiation field to include the area.<sup>61</sup>

- It takes into account imaging and pathological analysis: there are no strict recommendations as to the type and use of imaging and pathology to stage the disease, which can be used according to the choice and resource availability with the gynecologic oncologist. In resource poor settings, clinical staging may continue to be practiced.<sup>5</sup>

## Treatment Response and Recurrence

Imaging is used in post-treatment surveillance to assess the response of cervical cancer to radiotherapy and/or chemotherapy-based regimens. Reduction in size and extent can be recorded by modalities such as TVS and MRI. Functional MR can document response by increasing ADC values or decreased perfusion in the tumor.

Recurrent disease can be found in the vaginal stump, anastomotic sites, parametrium, or lymph nodes. Functional MR imaging such as DWI and DCE-MR can aid in differentiation of residual or recurrent disease from post radiation fibrosis.<sup>31</sup> PET-CT can be beneficial in the post-therapy setup if care is taken to maintain optimum interval from the radiation therapy.

## Limitations and Status of the Current System in Low- and Middle-Income Group Nations

The new staging system offers a significant advancement over the previous one. However, some drawbacks plague the current staging. Analyses have shown large heterogeneity in the survival and recurrence rates across patients in stage IIIC, depending on the size and extent of the primary tumor.<sup>45</sup> Also the number of lymph node positivity may affect the final survival.<sup>62</sup> Due to large burden of infections like tuberculosis and HIV in India and other low- and middle-income countries, lymph nodes detected by imaging may have a higher rate of false positivity for malignancy.<sup>63</sup>

Surgical prognostic factors with inadequate data information like lymphovascular spread have no place in the current staging system but have been shown to affect the patient prognosis. Also spread to the ovary does not change the stage, however, is seen to have a prognostic value.<sup>63</sup> A standardized imaging protocol is lacking and needs to be laid down by various radiological and imaging societies in collaboration with gynecologists with a multidisciplinary team approach.

## Conclusion

Oncology is an ever-evolving field and the recent 2018 FIGO staging of cervical cancer allows the use of cross-sectional imaging and pathology to supplement the staging process. The recognition and inclusion of pelvic and para-aortic lymph nodes in the FIGO staging system is a major change. This makes it imperative for the radiologist to be conversant with the various aspects of the imaging modalities to be an effective part of the multidisciplinary team in the management of cervical carcinoma.

## Source(s) of Support

None.

## Presentation at a Meeting

None.

## Conflict of Interest

None declared.

## Acknowledgment

None.

## References

- 1 Bray F, Ferlay J, Soerjomataram I, Siegel RL, Torre LA, Jemal A. Global cancer statistics 2018: GLOBOCAN estimates of incidence and mortality worldwide for 36 cancers in 185 countries. *CA Cancer J Clin* 2018;68(06):394–424
- 2 Jemal A, Siegel R, Ward E, et al. Cancer statistics, 2006. *CA Cancer J Clin* 2006;56(02):106–130
- 3 Pecorelli S, Zigliani L, Odicino F. Revised FIGO staging for carcinoma of the cervix. *Int J Gynaecol Obstet* 2009;105(02):107–108
- 4 Chuang LT, Temin S, Camacho R, et al. Management and care of women with invasive cervical cancer: American Society of Clinical Oncology Resource-Stratified Clinical Practice Guideline. *J Glob Oncol* 2016;2(05):311–340
- 5 Bhatla N, Berek JS, Cuello Fredes M, et al. Revised FIGO staging for carcinoma of the cervix uteri. *Int J Gynaecol Obstet* 2019;145(01):129–135
- 6 Epstein E, Testa A, Gaurilcik A, et al. Early-stage cervical cancer: tumor delineation by magnetic resonance imaging and ultrasound—a European multicenter trial. *Gynecol Oncol* 2013;128(03):449–453
- 7 Testa AC, Ludovisi M, Manfredi R, et al. Transvaginal ultrasonography and magnetic resonance imaging for assessment of presence, size and extent of invasive cervical cancer. *Ultrasound Obstet Gynecol* 2009;34(03):335–344
- 8 Moloney F, Ryan D, Twomey M, Hewitt M, Barry J. Comparison of MRI and high-resolution transvaginal sonography for the local staging of cervical cancer. *J Clin Ultrasound* 2016;44(02):78–84
- 9 Ma X, Li Q, Wang JL, et al. Comparison of elastography based on transvaginal ultrasound and MRI in assessing parametrial invasion of cervical cancer. *Clin Hemorheol Microcirc* 2017;66(01):27–35
- 10 Fischerova D, Cibula D, Stenhova H, et al. Transrectal ultrasound and magnetic resonance imaging in staging of early cervical cancer. *Int J Gynecol Cancer* 2008;18(04):766–772
- 11 Alcázar JL, Arribas S, Mínguez JA, Jurado M. The role of ultrasound in the assessment of uterine cervical cancer. *J Obstet Gynaecol India* 2014;64(05):311–316
- 12 Alcazar JL, Garcia E, Machuca M, et al. Magnetic resonance imaging and ultrasound for assessing parametrial infiltration in cervical cancer. A systematic review and meta-analysis. *Med Ultrason* 2020;22(01):85–91
- 13 Innocenti P, Pulli F, Savino L, et al. Staging of cervical cancer: reliability of transrectal US. *Radiology* 1992;185(01):201–205
- 14 Aoki S, Hata T, Senoh D, et al. Parametrial invasion of uterine cervical cancer assessed by transrectal ultrasonography: preliminary report. *Gynecol Oncol* 1990;36(01):82–89
- 15 Csutak C, Badea R, Bolboacă SD, et al. Multimodal endocavitary ultrasound versus MRI and clinical findings in pre- and post-treatment advanced cervical cancer. Preliminary report. *Med Ultrason* 2016;18(01):75–81
- 16 Yang WT, Walkden SB, Ho S, et al. Transrectal ultrasound in the evaluation of cervical carcinoma and comparison with spiral

- computed tomography and magnetic resonance imaging. *Br J Radiol* 1996;69(823):610–616
- 17 Hancke K, Heilmann V, Straka P, Kreienberg R, Kurzeder C. Pretreatment staging of cervical cancer: is imaging better than palpation? Role of CT and MRI in preoperative staging of cervical cancer: single institution results for 255 patients. *Ann Surg Oncol* 2008;15(10):2856–2861
  - 18 Bipat S, Glas AS, van der Velden J, Zwinderman AH, Bossuyt PMM, Stoker J. Computed tomography and magnetic resonance imaging in staging of uterine cervical carcinoma: a systematic review. *Gynecol Oncol* 2003;91(01):59–66
  - 19 Mitchell DG, Snyder B, Coakley F, et al. Early invasive cervical cancer: tumor delineation by magnetic resonance imaging, computed tomography, and clinical examination, verified by pathologic results, in the ACRIN 6651/GOG 183 Intergroup Study. *J Clin Oncol* 2006;24(36):5687–5694
  - 20 Özsarlak O, Tjalma W, Schepens E, et al. The correlation of preoperative CT, MR imaging, and clinical staging (FIGO) with histopathology findings in primary cervical carcinoma. *Eur Radiol* 2003;13(10):2338–2345
  - 21 Massad LS, Calvillo C, Gilkey SH, Abu-Rustum NR. Assessing disease extent in women with bulky or clinically evident metastatic cervical cancer: yield of pretreatment studies. *Gynecol Oncol* 2000;76(03):383–387
  - 22 Sharma DN, Thulkar S, Goyal S, et al. Revisiting the role of computerized tomographic scan and cystoscopy for detecting bladder invasion in the revised FIGO staging system for carcinoma of the uterine cervix. *Int J Gynecol Cancer* 2010;20(03):368–372
  - 23 Olpin J, Chuang L, Berek J, Gaffney D. Imaging and cancer of the cervix in low- and middle-income countries. *Gynecol Oncol Rep* 2018;25:115–121
  - 24 Bellomi M, Bonomo G, Landoni F, et al. Accuracy of computed tomography and magnetic resonance imaging in the detection of lymph node involvement in cervix carcinoma. *Eur Radiol* 2005;15(12):2469–2474
  - 25 Scoutt LM, McCauley TR, Flynn SD, Luthringer DJ, McCarthy SM. Zonal anatomy of the cervix: correlation of MR imaging and histologic examination of hysterectomy specimens. *Radiology* 1993;186(01):159–162
  - 26 Yitta S, Hecht EM, Mausner EV, Bennett GL. Normal or abnormal? Demystifying uterine and cervical contrast enhancement at multidetector CT. *Radiographics* 2011;31(03):647–661
  - 27 deSouza NM, Rockall A, Freeman S. Functional MR imaging in gynecologic cancer. *Magn Reson Imaging Clin N Am* 2016;24(01):205–222
  - 28 Choi SH, Kim SH, Choi HJ, Park BK, Lee HJ. Preoperative magnetic resonance imaging staging of uterine cervical carcinoma: results of prospective study. *J Comput Assist Tomogr* 2004;28(05):620–627
  - 29 Young P, Daniel B, Sommer G, Kim B, Herfkens R. Intravaginal gel for staging of female pelvic cancers—preliminary report of safety, distention, and gel-mucosal contrast during magnetic resonance examination. *J Comput Assist Tomogr* 2012;36(02):253–256
  - 30 Pötter R, Georg P, Dimopoulos JCA, et al. Clinical outcome of protocol based image (MRI) guided adaptive brachytherapy combined with 3D conformal radiotherapy with or without chemotherapy in patients with locally advanced cervical cancer. *Radiother Oncol* 2011;100(01):116–123
  - 31 Addley H, Moyle P, Freeman S. Diffusion-weighted imaging in gynaecological malignancy. *Clin Radiol* 2017;72(11):981–990
  - 32 Hameeduddin A, Sahdev A. Diffusion-weighted imaging and dynamic contrast-enhanced MRI in assessing response and recurrent disease in gynaecological malignancies. *Cancer Imaging* 2015;15:3
  - 33 Fu C, Bian D, Liu F, Feng X, Du W, Wang X. The value of diffusion-weighted magnetic resonance imaging in assessing the response of locally advanced cervical cancer to neoadjuvant chemotherapy. *Int J Gynecol Cancer* 2012;22(06):1037–1043
  - 34 Donaldson SB, Buckley DL, O'Connor JP, et al. Enhancing fraction measured using dynamic contrast-enhanced MRI predicts disease-free survival in patients with carcinoma of the cervix. *Br J Cancer* 2010;102(01):23–26
  - 35 Andersen EKF, Hole KH, Lund KV, et al. Dynamic contrast-enhanced MRI of cervical cancers: temporal percentile screening of contrast enhancement identifies parameters for prediction of chemoradioresistance. *Int J Radiat Oncol Biol Phys* 2012;82(03):e485–e492
  - 36 Zahra MA, Tan LT, Priest AN, et al. Semiquantitative and quantitative dynamic contrast-enhanced magnetic resonance imaging measurements predict radiation response in cervix cancer. *Int J Radiat Oncol Biol Phys* 2009;74(03):766–773
  - 37 Van Vierzen PBJ, Massuger LFA, Ruys SHJ, Barentsz JO. Fast dynamic contrast enhanced MR imaging of cervical carcinoma. *Clin Radiol* 1998;53(03):183–192
  - 38 Atri M, Zhang Z, Dehdashti F, et al. Utility of PET-CT to evaluate retroperitoneal lymph node metastasis in advanced cervical cancer: Results of ACRIN6671/GOG0233 trial. *Gynecol Oncol* 2016;142(03):413–419
  - 39 Paño B, Sebastià C, Ripoll E, et al. Pathways of lymphatic spread in gynecologic malignancies. *Radiographics* 2015;35(03):916–945
  - 40 Amendola MA, Hricak H, Mitchell DG, et al. Utilization of diagnostic studies in the pretreatment evaluation of invasive cervical cancer in the United States: results of intergroup protocol ACRIN 6651/GOG 183. *J Clin Oncol* 2005;23(30):7454–7459
  - 41 Mayr NA, Yuh WTC, Zheng J, et al. Tumor size evaluated by pelvic examination compared with 3-D quantitative analysis in the prediction of outcome for cervical cancer. *Int J Radiat Oncol Biol Phys* 1997;39(02):395–404
  - 42 Van Nagell JR Jr, Roddick JW Jr, Lowin DM. The staging of cervical cancer: inevitable discrepancies between clinical staging and pathologic findings. *Am J Obstet Gynecol* 1971;110(07):973–978
  - 43 Pandharipande PV, Choy G, del Carmen MG, Zabelle GS, Russell AH, Lee SI. MRI and PET/CT for triaging stage IB clinically operable cervical cancer to appropriate therapy: decision analysis to assess patient outcomes. *AJR Am J Roentgenol* 2009;192(03):802–814
  - 44 Matsuo K, Machida H, Mandelbaum RS, Konishi I, Mikami M. Validation of the 2018 FIGO cervical cancer staging system. *Gynecol Oncol* 2019;152(01):87–93
  - 45 Liu X, Wang J, Hu K, et al. Validation of the 2018 FIGO staging system of cervical cancer for stage III patients with a cohort from China. *Cancer Manag Res* 2020;12:1405–1410
  - 46 Cheng X, Cai S, Li Z, Tang M, Xue M, Zang R. The prognosis of women with stage IB1–IB node-positive cervical carcinoma after radical surgery. *World J Surg Oncol* 2004;2:47
  - 47 Koh W-J, Abu-Rustum NR, Bean S, et al. Cervical cancer, Version 3.2019, NCCN Clinical Practice Guidelines in Oncology. *J Natl Compr Canc Netw* 2019;17(01):64–84
  - 48 Siegel CL, Andreotti RF, Cardenas HR, et al; American College of Radiology. ACR Appropriateness Criteria® pretreatment planning of invasive cancer of the cervix. *J Am Coll Radiol* 2012;9(06):395–402
  - 49 Bhatla N, Aoki D, Sharma DN, Sankaranarayanan R. Cancer of the cervix uteri. *Int J Gynaecol Obstet* 2018;143(Suppl 2):22–36
  - 50 Jolly S, Uppal S, Bhatla N, Johnston C, Maturen K. Improving global outcomes in cervical cancer: the time has come for international federation of gynecology and obstetrics staging to formally incorporate advanced imaging. *J Glob Oncol* 2018;4:1–6
  - 51 Sala E, Rockall AG, Freeman SJ, Mitchell DG, Reinhold C. The added role of MR imaging in treatment stratification of patients with gynecologic malignancies: what the radiologist needs to know. *Radiology* 2013;266(03):717–740
  - 52 Wakefield JC, Downey K, Kyriazi S, deSouza NM. New MR techniques in gynecologic cancer. *AJR Am J Roentgenol* 2013;200(02):249–260
  - 53 Patel-Lippmann K, Robbins JB, Barroilhet L, Anderson B, Sadowski EA, Boyum J. MR imaging of cervical cancer. *Magn Reson Imaging Clin N Am* 2017;25(03):635–649

- 54 Bourgioti C, Chatoupis K, Mouloupoulos LA. Current imaging strategies for the evaluation of uterine cervical cancer. *World J Radiol* 2016;8(04):342–354
- 55 Devine C, Gardner C, Sagebiel T, Bhosale P. Magnetic resonance imaging in the diagnosis, staging, and surveillance of cervical carcinoma. *Semin Ultrasound CT MR* 2015;36(04):361–368
- 56 Akin O, Mironov S, Pandit-Taskar N, Hann LE. Imaging of uterine cancer. *Radiol Clin North Am* 2007;45(01):167–182
- 57 McMahon CJ, Rofsky NM, Pedrosa I. Lymphatic metastases from pelvic tumors: anatomic classification, characterization, and staging. *Radiology* 2010;254(01):31–46
- 58 Cibula D, Pötter R, Planchamp F, et al. The European Society of Gynaecological Oncology/European Society for Radiotherapy and Oncology/European Society of Pathology Guidelines for the Management of Patients with Cervical Cancer. *Virchows Arch* 2018; 472(06):919–936
- 59 Marth C, Landoni F, Mahner S, McCormack M, Gonzalez-Martin A, Colombo NESMO Guidelines Committee. Cervical cancer: ESMO Clinical Practice Guidelines for diagnosis, treatment and follow-up. *Ann Oncol* 2017;28(Suppl 4):iv72–iv83
- 60 Ferlay J, Steliarova-Foucher E, Lortet-Tieulent J, et al. Cancer incidence and mortality patterns in Europe: estimates for 40 countries in 2012. *Eur J Cancer* 2013;49(06):1374–1403
- 61 Lee SI, Atri M. 2018 FIGO staging system for uterine cervical cancer: enter cross-sectional imaging. *Radiology* 2019;292(01): 15–24
- 62 Yan D-D, Tang Q, Chen J-H, Tu Y-Q, Lv X-J. Prognostic value of the 2018 FIGO staging system for cervical cancer patients with surgical risk factors. *Cancer Manag Res* 2019;11:5473–5480
- 63 Bhatla N, Rajaram S, Maheshwari A. The revised FIGO staging of cervical cancer (2018): implications for India and the LMICs. *Indian J Gynecol Oncol* 2019;17:92