

Received: 2021.06.04

Accepted: 2021.10.12

Available online: 2021.10.18

Published: 2021.11.17

## Zoster Cranial Polyneuropathy in a COVID-19 Patient

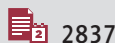## Authors' Contribution:

Study Design A  
Data Collection B  
Statistical Analysis C  
Data Interpretation D  
Manuscript Preparation E  
Literature Search F  
Funds Collection GADEF 1,2 **Florian Antonescu**  
ABCDEF 1 **Ioana Butnariu**  
ABCDEF 1 **Florentina Melania Cojocaru**  
ABCDEF 1 **Daniela Nicoleta Anghel**  
EFG 3 **Eliza Damaris Mihai**  
ABCDEF 1,2 **Sorin Tuță**

1 Department of Neurology, National Institute of Neurology and Neurovascular Diseases, University of Medicine and Pharmacy "Carol Davila", Bucharest, Romania

2 Department of Neurology, "Carol Davila" University of Medicine and Pharmacy, Bucharest, Romania

3 Department of Neurology, Ponderas Academic Hospital, Bucharest, Romania

**Corresponding Author:** Ioana Butnariu, e-mail: [ioanalbutnariu@gmail.com](mailto:ioanalbutnariu@gmail.com)**Financial support:** None declared**Conflict of interest:** None declared**Patient:** Female, 54-year-old  
**Final Diagnosis:** Zoster cranial polyneuropathy  
**Symptoms:** Diplopia • facial palsy • hypoacusis • nausea • nystagmus • tinnitus • vertigo • vomiting • zoster rash  
**Medication:** —  
**Clinical Procedure:** —  
**Specialty:** Infectious Diseases • Neurology**Objective:** Rare disease**Background:** Ramsay Hunt syndrome is a rare form of herpes zoster caused by the reactivation of the varicella-zoster virus in the geniculate ganglion. The main clinical manifestations are peripheral facial palsy, vesicular rash in the ear, and ipsilateral auricular pain, and sometimes vertigo. COVID-19 is a new multisystemic infectious disease that, in addition to common respiratory manifestations, it is known to affect the immune system, primarily depressing cellular immunity.**Case Report:** A 54-year-old woman was admitted to our hospital with an acute vestibular syndrome and diplopia. She had been diagnosed 3 years prior with interstitial lung disease for which she was taking methylprednisolone. At admission, she tested positive for SARS-CoV-2. In the following days, she developed a sixth nerve palsy on the left side and a right peripheral facial palsy on the right side, followed by a typical zoster rash on the ipsilateral ear. One month later, she developed acute severe hearing loss on the right side. There were no COVID-19 symptoms during her stay in our hospital. The MRI showed Gd enhancement of both facial nerves. Under antiviral and corticoid treatment, the evolution was favorable, with marked improvement at 6 months.**Conclusions:** COVID-19 increases the risk for herpes zoster infection, probably through induced depression of the cellular immunity. Our case suggests Ramsay Hunt syndrome can be the presenting symptom and sometimes the only symptom of COVID-19. This also seems to be true for other cranial neuropathies, and we recommend testing these patients even if there are no other manifestations.**Keywords:** COVID-19 • Hunt's Syndrome • Severe Acute Respiratory Syndrome Coronavirus 2Full-text PDF: <https://www.amjcaserep.com/abstract/index/idArt/934658>


2837



—



2



36



## Background

Coronavirus disease 2019 (COVID-19) is a new infectious disease, with very high transmission potential. Its etiological agent is the SARS-CoV2 virus [1,2]. Although the respiratory system is the site first and most affected, neurological, neuro-psychiatric, hematological, immunological, dermatological, and digestive complications are increasingly common, which is why COVID-19 is now considered a multisystemic disease [3-6].

The varicella-zoster virus (VZV) is a human herpetic virus that after the first infection, which produces varicella (chickenpox), remains dormant in the sensory ganglia of peripheral nerves [7]. Herpes zoster is an acute localized reactivation of the dormant virus. It is clinically manifested by a painful erythematous vesicular rash with a dermatomal distribution. The most common affected segments are thoracic (49-59%), head and neck (15-25%), and lumbosacral (11%) [8-10]. At the cranial level, the affected nerves are, in descending order of the number of reported cases, V, VII, VIII, IX, X, III, IV, and VI [11].

When reactivation involves the geniculate ganglion, it constitutes Ramsay Hunt syndrome (RHS), typically characterized by the triad of auricular pain, ear vesicular rash, and peripheral facial palsy (PFP) [12]. Old age, immunodepression, and stress are the main factors favoring VZV reactivation [7,13].

The literature presents many cases of COVID-19 associated with herpes zoster, but Ramsay Hunt syndrome reports are rare. So far it has not been established with certainty whether SARS-CoV2 directly favors VZV reactivation, but possible mechanisms have been put forward, especially involving decreased cellular immunity [14].

We present a case of cranial polyneuropathy, with a severe instance of RHS, in a patient with a subclinical form of COVID-19. To the best of our knowledge, this is the first reported case of zoster cranial polyneuropathy in a COVID-19 patient. While COVID-19 seems to be able in itself to induce cranial polyneuropathies, in our case the clinical presentation of a typical RHS case suggests the VZV as the most probable culprit [15,16].

## Case Report

A 54-year-old woman was admitted to our clinic with an acute vestibular syndrome with incoercible vomiting that had started 4 days earlier. In the 24 h prior to admission, she also developed horizontal diplopia with maximum intensity in the left-sided gaze.

On the same day she had been seen by an ophthalmologist, who only noted conjunctival hyperemia and myopia in both

eyes. She also had a brain CT scan, which was normal except for right chronic mastoiditis and right sphenoid sinusitis.

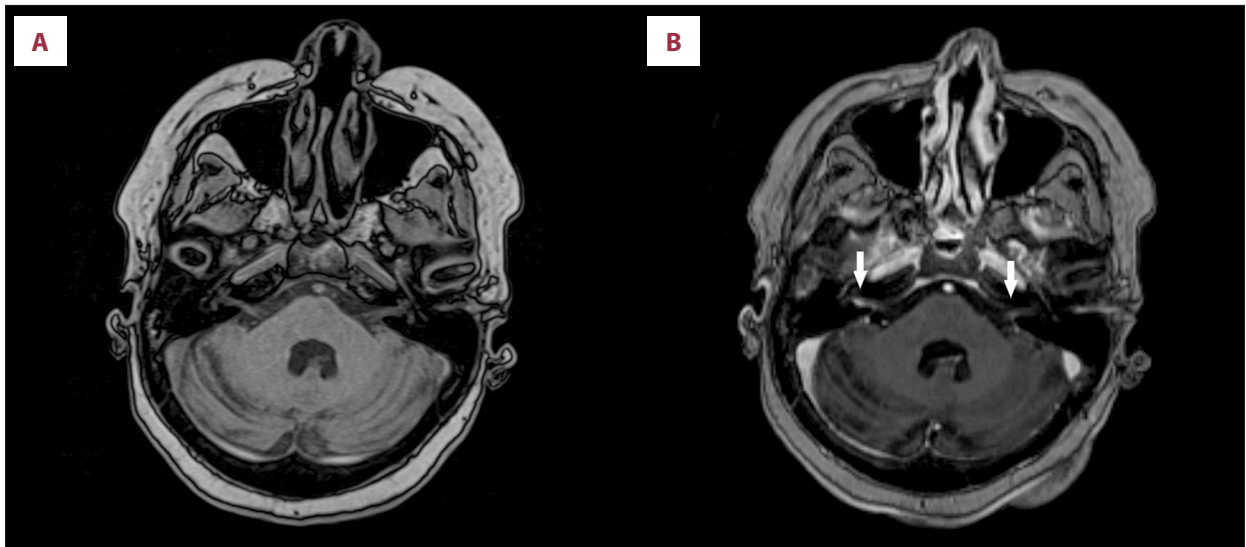
The patient was overweight with a BMI of 33.3, a non-smoker, without any history of alcohol or substance abuse, but with prolonged professional exposure to organic solvents. She had been diagnosed with interstitial lung disease (ILD) in 2018 and subsequently had received methylprednisolone 16 mg/day. She had high blood pressure, mild chronic kidney disease, and a history of deep vein thrombosis (many years prior, while using contraceptive drugs). Besides corticotherapy, she was receiving long-term treatment with beta-blockers, ACE inhibitors, proton pump inhibitors, betahistine, and bioflavonoids. She had not received a vaccine because they were not yet available.

On the initial examination we noted a rounded face, purple abdominal stretch marks, and central body obesity, consistent with Cushing syndrome. Peripheral blood oxygen saturation was 91%, without any respiratory difficulties, a slight posterior basal bilateral pleural friction rub was present, with an otherwise normal auscultation. The patient reported chronic low oxygen saturation in the last 10-12 months as measured by pulse oximetry, usually above 90%.

The neurologic examination showed a slight convergent strabismus of the left eye, horizontal diplopia, with a maximum intensity when gazing toward the left side, horizontal nystagmus in central gaze, with the fast phase to left, which increased intensity when gazing to the left, normal hearing, and slightly increased deep tendon reflexes. Walking was almost impossible, with a strong pull to the right while standing. Otherwise, she was normal from a neurological standpoint.

Laboratory tests showed an increased WBC count (18 360/mcl) with 72% neutrophils and 18.8% lymphocytes, probably secondary to long-term corticoid treatment. The leukocytosis persisted over the next months, fluctuating between 13 000 and 19 000/mcl. The RBC and hemoglobin were elevated (6 500 000/mcl and 17.3 g/dl, respectively). AST, ALT, blood glucose, serum creatinine, BUN, and urinalysis were normal. Serological markers for HIV, hepatitis B and C, and syphilis were negative. Dosing of the CSF VZV antibodies would have been useful, but was not performed. This patient presented to our hospital when the number of COVID-19 cases soared in our country and the laboratory test of CSF for infections was unavailable. Also, after the first spinal tap, the patient refused to consider another one.

The patient had no general or respiratory symptoms suggesting COVID-19; however, in the current epidemiologic context, screening testing is done for all patients before admission to our ward. The patient tested positive on the RT-PCR examination for severe acute respiratory syndrome- Coronavirus-2



**Figure 1.** Cerebral MRI on hospital day 12 showing contrast enhancement of the acustico-vestibular bundles. **A and B** show the same coordinates before and after contrast, respectively. Arrows point to the zones of contrast enhancement.

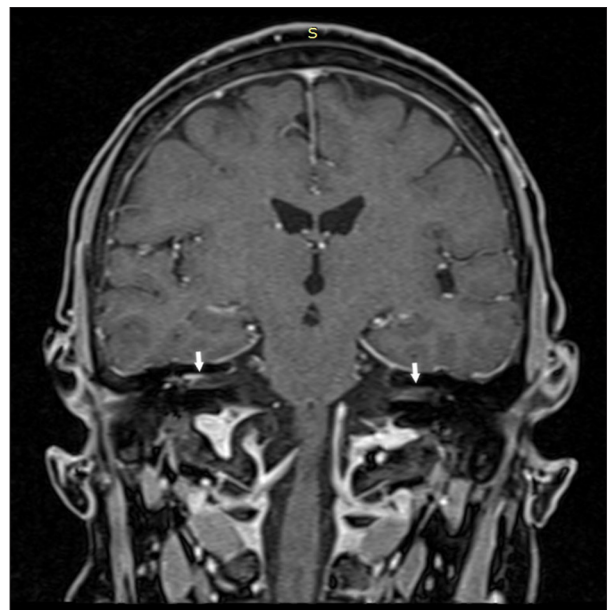
(SARS-CoV-2), but C reactive protein levels were normal, with a slightly increased level of ferritin of 169 ng/ml.

On admission, she underwent a native brain MRI scan, which described only a few chronic white-matter demyelinating lesions with a microangiopathic pattern. The angiography was normal.

She was switched from methylprednisolone to dexamethasone 8 mg/day i.v. and nadroparin 3800 UI per day, and meclizine and simvastatin were added. The vestibular syndrome persisted, albeit with a significant reduction of the vomiting and, progressively, a sixth nerve palsy on the left side became evident.

On hospital day 3, she developed severe right-side PFP, corresponding to grade V on the House-Brackmann Scale (HB). Considering that the cerebral MRI was unremarkable, a spinal tap was performed. The opening pressure was within normal parameters, but the CSF was abnormal with positive Pandy's reaction, increased protein levels (1100 mg/dl), albumin (0.73 g/dl), and slight pleocytosis (55 cells/mcl). Two days later, an intensely painful vesicular rash appeared on the chonca and in the external auditory canal on the same side, establishing the diagnosis of RHS. Acyclovir was initiated (4 g/day p.o.) and continued for 7 days. Artificial tears were prescribed for ocular protection.

There were no apparent respiratory or general COVID-19 symptoms during her stay in our hospital, with no myalgia or arthralgia, no fever, coughing, or shortness of breath, and respiratory frequency was normal. Arterial O<sub>2</sub> saturation was stable at between 90% and 94% and no oxygen supplementation was needed. As her COVID-19 was without significant respiratory involvement, no treatment was administered except for dexamethasone and LMWH.



**Figure 2.** Persistent enhancement on both facial nerves, more evident on the right side, at 6 months.

On hospital day 10, a thoracic CT scan showed discreet interstitial inflammation situated in the anterior segment of the superior left lobe and fibrosis bands and bronchiectasis in the middle lobe, without typical images for COVID-19.

The PCR tests turned negative on hospital day 11, and on hospital day 16 she underwent a second cerebral MRI scan, which revealed micronodular and linear enhancement in the intracanalicular segment of the right VII and VIII nerve bundle and slight enhancement of the intra-temporal segment of the left facial nerve (**Figure 1A, 1B**).

The patient was discharged, and the symptoms continued to improve slowly, with the abducens palsy being the first to remit. Four weeks from discharge, the patient's diplopia had resolved, but at about the same time she suddenly developed tinnitus in her right ear, with almost complete loss of hearing on that side the very next day. An ENT examination diagnosed a sensorineural hearing loss.

At the 6-month checkup she was significantly improved. The facial palsy was gradable as stage III HB, the vestibular syndrome was completely remitted, and ocular motricity was normal, with no problems reported other than the facial asymmetry and severe hearing loss in the affected ear. We repeated a cerebral MRI scan, which was unmodified, including persistent enhancement of the facial nerves, more pronounced on the right side (**Figure 2**).

## Discussion

COVID-19 was initially described as interstitial pneumonia, but the large number of cases has shown that the clinical picture is very diverse. About 40% to 50% of patients who test positive are asymptomatic. Some patients present with mild forms resembling the common cold, while others develop severe forms of pneumonia with high fever, severe cough, and dyspnea, often escalating to ARDS, MODS, and death [2,17]. Although the main symptoms are generally respiratory, manifestations involving other organs and systems, such as the nervous system and the skin, have been reported with increasing frequency. Neurologically, COVID-19 patients present with ageusia, anosmia, confusion, headache, neuroinflammatory syndromes, encephalitis, strokes, and gait disorders [3,17]. Dermatologic manifestations include COVID toes, erythematous rash, wide-spread urticaria, chickenpox-like lesions, shingles, maculopapular eruptions, pityriasis rosea, petechiae, and androgenic alopecia [13,18-20].

RHS is a rare form of herpes zoster. Three types were described, depending on the complexity of the clinical manifestations. Type I, the simplest form, is associated with otalgia and herpeticiform rash. Type II adds ipsilateral PFP to type I. Type III, the most severe form, affects the ipsilateral vestibulocochlear nerve in addition to type II manifestations [21]. Involvement of other cranial nerves in RHS has been reported, but it is much rarer (1.8%) [22]. Zoster cranial polyneuritis is still incompletely studied, but several theories have been stated that could explain the extent of the inflammatory process. Ramsay Hunt suggested that the Gasser, geniculate, petrosus, accessor, jugular, plexiform ganglia, and the ganglia on the dorsal root of the cervical nerves II and III constitute an anatomical chain that allows inflammation of any of them to extend to others [21]. Other hypotheses propose hematogenous

extension as a pathophysiological mechanism, considering that many cranial sensitive ganglia have common sources of vascularization, and the vessels are known to have significant vulnerability to VZV. Another hypothesis is the trans-axonal extension from the afferent fibers of 1 or more cranial nerves to the vasa nervorum of other nerves [23,24]. In RHS type III, the association of PFP and vestibulocochlear neuritis is favored by the common nerve sheath and trajectory through the internal auditory canal of nerves VII and VIII [21]. In the case of our patient, the right VIII nerve, vestibular branch, the right facial nerve, the left abducens nerve and, at a distance, the cochlear branch of the right VIII nerve were affected in succession.

Inflammation of the cranial nerves can be investigated through contrast-enhanced MRI. Gadolinium-DTPA (Gd) crosses the altered blood-brain barrier in inflamed areas, allowing visualization of specific lesions [25]. In RHS, Gd enhancement of the affected nerve bundle is a negative prognostic factor [25-27].

The only manifestation on the left side was an abducens nerve palsy. Damage to the VI nerve is very rare and can be explained by the proximity of the abducens nerve to that of the VII or VIII nerve [22,24]. In our patient, the contrast enhancement was observed on both nerve VII-VIII bundles, predominantly on the right side. While only the right VII and VIII nerves were symptomatic, subclinical involvement of the left facial could explain how the inflammation extended to the left sixth nerve.

The differential diagnosis included sarcoidosis, which can be associated with multiple cranial nerves palsies derived from granulomatous infiltration of the cranial nerves, increased intracranial pressure from CSF obstruction, or involvement of the nerve by granulomatous basal meningitis. In our patient, the contrast MRI examination did not indicate any brainstem or meningeal enhancement or lesions, so only direct inflammation of the nerves remained as a possible mechanism. The most frequent cranial nerves affected in isolated neurosarcoidosis are the facial and optical nerves. In our patient, optic nerves were not affected clinically or on MRI imaging, and the facial nerve palsy had a strict chronological connection with the zoster eruption, giving an overall impression that zoster infection was the most plausible culprit. The thoracic CT scan did not suggest a systemic form of sarcoidosis which could be associated with CNS involvement. Because of the prolonged corticoid treatment, as well as the ACEI treatment, we did not assess ACE levels since our lab only tests for ACE activity rather than ACE protein level.

Regarding the possibility of a CNS lymphoma with cranial nerve palsies, no suspicious cytology was reported by the CSF analysis, and aside from the nerve roots contrast the MRI did not find any other meningeal or parenchymal involvement. Also, the continual clinical improvement does not support a malignant pathology.

Most cases of zoster cranial polyneuropathy have been described in immunocompromised patients or in people over 50 years of age [12,22,28]. While it has been shown that the COVID-19 pandemic is associated with an increase in zoster cases, Ramsay Hunt syndrome reports are very sparse [29]. The underlying mechanism is still uncertain, but probably involves decreased cellular immunity, with some theories postulating lymphopenia or lymphocytic exhaustion [30] and others suggesting defective cellular signaling, especially involving IL-17 [17], or pointing to increased stress as a risk factor [31]. SARS-CoV-2 causes lymphopenia by affecting lymphopoiesis, stimulating lymphocytic apoptosis, and depleting lymphocytes. The association is variable, with many zoster cases appearing in asymptomatic patients, while others appear in serious forms of COVID-19 and are themselves severe. Some authors recommend testing for subclinical COVID-19 in all zoster patients [30].

Our patient was 54 years old, was undergoing long-term immunosuppressive treatment (corticotherapy) for interstitial lung disease, and had a very mild form of COVID-19. She did not show lymphocyte values below 1200/mcl, nor significantly increased inflammation markers. Antiviral treatment was initiated in the first 24 h after the onset of the zoster rash (acyclovir 200 mg 4 tablets 5 times a day p.o.) and corticotherapy was continued as dexamethasone 8 mg i.v. once per day.

While multiple cases of cranial polyneuropathy associated with COVID-19 have been published over the last 18 months, to the best of our knowledge this is the first reported case of zoster cranial polyneuropathy in a COVID-19 patient [15,16]. As the possibility of subclinical shingles has not been investigated in the published cases, this raises the possibility that at least some of those cases could have been due to VZV reactivation. The situation is further complicated by the severe respiratory symptoms of some of these patients and the fact that COVID-19 can in itself present with various cutaneous and mucosal manifestations [32].

Our case is unique not only for the extent of cranial nerves involvement (right facial and vestibular, left abducens), but also for subclinical evidence of the involvement of the contralateral facial nerve, as bilateral RHS is extremely rare. Given this and the fact that SARS-CoV-2 is known to cause multiple cranial neuropathies on its own, we found it difficult to establish if SARS-CoV-2 had a more direct role in the development of multiple cranial neuropathies in this patient or was rather a contributor to the reactivation of VZV due to its added immunosuppressive effect.

Also, the delayed involvement of the right cochlear nerve is very interesting, as it developed almost 7 weeks after the onset and at a time when the vestibular symptoms were improving. This

suggests a prolonged viral activation (or possibly a second reactivation) of the VZV long after the SARS-CoV-2 infection (5 weeks after testing negative). The patient had not experienced any recurring zoster rashes, but zoster sine herpete is always a possibility. It is possible that the immunosuppressed status of our patient may have played a role and delayed bringing the infection under control. Also, recent data show that COVID-19 can induce prolonged activation of the immune system, so delayed inflammatory neuritis should be kept in mind for further study as a possible long COVID symptom [33].

The enhancement still present at the 6-month checkup is somewhat baffling, but there have been previous reports of prolonged nerve enhancement in RHS patients, sometimes posing diagnostic difficulties in differentiating it from an acoustic neuroma [34,35]. The significance of prolonged enhancement remains unclear, especially when symptoms are remitting or significantly improving.

## Conclusions

Neurological complications in COVID-19 are much more frequent than previously thought and can pose a serious diagnostic and therapeutic problem.

VZV reactivation is a known complication in immunocompromised patients, but as the data accumulates it also seems to be a frequent comorbidity in COVID-19 patients. This is also true for mild or asymptomatic cases of COVID-19 and clinicians should have a high degree of suspicion in the current epidemiological context when seeing cases of shingles. Even if RHS is very rare in the reports, our opinion is that the same applies to it. Our case also demonstrates that RHS can begin as an acute vestibular neuritis, and since SARS-CoV-2 can induce vestibular neuritis by itself, we consider testing all such patients for subclinical COVID-19 useful [36]. Although the correlations between SARS-CoV-2 infection, VZV reactivation, and cranial neuropathies are difficult to interpret, we have seen in our clinic various other cranial neuropathies associated with subclinical or mild COVID-19 since the pandemic began, and we now think testing should be recommended for all these patients, even in the absence of other symptoms. Also, as our understanding of long COVID increases, we should consider delayed neuropathies a possibility and a target for further studies.

## Declaration of Figures' Authenticity

All figures submitted have been created by the authors who confirm that the images are original with no duplication and have not been previously published in whole or in part.

## References:

1. Patel P, Undavia A, Choudry R, et al. COVID-19 associated with concomitant Varicella Zoster Viral Encephalitis. *Neurol Clin Pract.* 2020;11(2):219-21
2. Maldonado MD, Romero-Aibar J, Rerez-San-Gregorio MA. COVID-19 pandemic as a risk factor for the reactivation of herpes viruses. *Epidemiol Infect.* 2021;149:1-5
3. Paterson RW, Brown RL, Benjamin L, et al. The emerging spectrum of COVID-19 neurology: Clinical, radiological and laboratory findings. *Brain.* 2020;3104-20
4. Tian W, Zhang N, Jin R, et al. Immune suppression in the early stage of COVID-19 disease. *Nat Commun.* 2020;11(5859):1-8
5. da Rosa Mesquita R, Carlos Francelino Silva Junior L, Santos Santana FM, et al. Clinical manifestations of COVID-19 in the general population: systematic review. *Wien Klin Wochenschr.* 2020;133:377-82
6. Ghosh B, Gajjar RA, Modi VK, Jadeja DM. A rare case of herpes zoster in an adult patient recovered from symptomatic reinfection of COVID-19. *Cureus.* 2021;13(7):1-3
7. Letchuman V, Donohoe CD. Brainstem and cerebellar involvement in Ramsay Hunt syndrome. *Case Rep Otolaryngol.* 2019;2019:7605056
8. Wagner G, Klinge H, Sachse MM. Ramsay Hunt syndrome. *J Ger Soc Dermatology.* 2012;10(4):238-43
9. Psychogiou M, Samarkos M, Mikos N, Hatzakis A. Reactivation of varicella zoster Virus after vaccination for SARS-CoV-2. *Vaccines.* 2021;9(572):1-8
10. Jeon Y, Lee H. Ramsay Hunt syndrome. *J Dent Anesth Pan Med.* 2018;18(6):333-37
11. Tsau P-W, Liao M-F, Hsu J-L, et al. Clinical presentations and outcome studies of cranial nerve involvement in herpes zoster infection: A retrospective Single-Center Analysis. *J Clin Med.* 2020;9(946):1-9
12. Arya D, Bajaj T, Gonzalez J, Elkin R. Ramsay Hunt syndrome with multiple cranial neuropathy in an Human Immunodeficiency Virus (HIV) patient. *Am J Case Rep.* 2018;19:68-71
13. Desai HD, Sharma K, Patoliya J V, et al. A rare case of varicella-zoster virus reactivation following recovery from COVID-19. *Cureus.* 2021;13(1):1-4
14. Diez-Domingo J, Parikh R, Bhavsar AB, et al. Can COVID-19 increase the risk of herpes zoster? A narrative review. *Dermatol Ther (Heidelb).* 2021;11:1119-26
15. Gogia B, Guevara AG, Rai PK, Fang X. A case of COVID-19 with multiple cranial neuropathies. *Int J Neurosci.* 2020 [Online ahead of print]
16. Roussel A, Germanaud D, Bouchoucha Y, et al. Cranial polyneuropathy as the first manifestation of a severe COVID-19 in a child. *Pediatr Blood Cancer.* 2020;68(3):1-5
17. Yu X, Li L, Chan MT V, Wu WKK. Bioinformatic analyses suggest augmented interleukin-17 signaling as the mechanism of COVID-19-associated herpes zoster. *Environ Sci Pollut Res.* 2021 [Online ahead of print]
18. Katz J, Yue S, Xue W. Herpes simplex and herpes zoster viruses in COVID-19 patients. *Irish J Med Sci.* 2021 [Online ahead of print]
19. Muller Ramos P, Ianhez M, Miot HA. Alopecia and grey hair are associated with COVID-19 severity. *Exp Dermatol.* 2020;29:1250-52
20. Moravvej H, Pourani MR, Baghani M, Abdollahimajd F. Androgenetic alopecia and COVID-19: A review of the hypothetical role of androgens. *Dermatol Ther.* 2021;34(4):e15004
21. Hunt JR. On herpetic inflammation of the geniculate ganglion. A new syndrome and its complications. *Nerv Ment Dis.* 1907;34(2):73-96
22. Yang S, Zhang J-F, Zhang L, Zhu M. Ramsay Hunt syndrome presenting with abducens nerve palsy followed by V, VII, VIII, IX, and X nerve palsies. *Neurol Asia.* 2018;23(4):353-56
23. Sweeney J, Gilden DH. Ramsay Hunt syndrome. *J Neurol Neurosurg Psychiatry.* 2001;71:149-54
24. Kim C, Kang S il, Kim YH. A case of Ramsay Hunt syndrome with cranial polyneuropathy. *Korean Audiol Soc.* 2012;16:80-82
25. Iwasaki H, Toda N, Takahashi M, et al. Vestibular and cochlear neuritis in patients with Ramsay Hunt syndrome: A Gd-enhanced MRI study. *Acta Otolaryngol.* 2013;133:373-77
26. Kim IS, Shin S, Kim J, et al. Correlation between MRI and operative findings in Bell 's palsy and Ramsay Hunt syndrome. *Yonsei Med J.* 2007;48(6):963-68
27. Minakata T, Inagaki A, Sekiya S, Murakami S. Contrast-enhanced magnetic resonance imaging of facial nerve swelling in patients with severe Ramsay Hunt syndrome. *Auris Nasus Larynx.* 2019;46(5):687-95
28. Kim YH, Chang MY, Jung HH, et al. Prognosis of Ramsay Hunt syndrome presenting as cranial polyneuropathy. *Laryngoscope.* 2010;120:2270-76
29. López-Blanco R, Barbero-Bordallo N, Cazorla-García R, Fernández-Ferro J. Neuroinfecciones en tiempos de COVID-19. *Neurología.* 2020;35(January):273-74
30. Elsaie ML, Youssef EA, Nada HA. Herpes zoster might be an indicator for latent COVID 19 infection. *Dermatol Ther.* 2020;33(4):e13666
31. Ertugrul G, Aktas H. Herpes zoster cases increased during COVID-19 outbreak. Is it possible a relation? *J Dermatolog Treat.* 2020 [Online ahead of print]
32. Andalib S, Biller J, Napoli M Di, et al. Peripheral nervous system manifestations associated with COVID-19. *Curr Neurol Neurosci Rep.* 2021;21(9):1-14
33. Ong SWX, Fong S-W, Young BE, et al. Persistent symptoms and association with inflammatory cytokine signatures in recovered coronavirus disease 2019 patients. *Open Forum Infect Dis.* 2021;8(6):1-9
34. Finsterer J, Scorza FA, Scorza CA, Fiorini AC. COVID-19 associated cranial nerve neuropathy: A systematic review. *Bosn J Basic Med Sci.* 2021;8601:1-16
35. Cruz Tapia RO, Peraza Labrador AJ, Guimaraes DM, Matos Valdez LH. Oral mucosal lesions in patients with SARS-CoV-2 infection. Report of four cases. Are they a true sign of COVID-19 disease ? *Spec Care Dent.* 2020;40(6):555-60
36. Downie AC, Howlett DC, Koefman RJ, et al. Case report: prolonged contrast enhancement of the inner ear on magnetic resonance imaging in Ramsay Hunt syndrome. *Br J Radiol.* 1994;67(800):819-21