






## CASE REPORT

# **REVISED** Case Report: Portal cavernoma related to multiple liver hydatidosis: A rare case of fatal cataclysmic haemorrhage [version 2; peer review: 2 approved]

Previous title: Case Report: Portal cavernoma secondary to multiple liver hydatidosis: A rare cause of cataclysmic haemorrhage in a young adult

Alia Zouaghi<sup>1</sup>, Nawel Bellil<sup>2</sup>, Khalaf Ben Abdallah <sup>1</sup>, Dhafer Hadded <sup>1</sup>, Haithem Zaafouri <sup>1</sup>, Mona Cherif<sup>1</sup>, Anis Ben Maamer<sup>1</sup>

<sup>1</sup>Department of General Surgery, Habib Thameur Hospital, Tunis, 1008, Tunisia

<sup>2</sup>Department of Gastroenterology, Habib Thameur Hospital, Tunis, 1008, Tunisia

**v2** First published: 29 Oct 2021, 10:1097  
<https://doi.org/10.12688/f1000research.74012.1>  
 Latest published: 25 Nov 2021, 10:1097  
<https://doi.org/10.12688/f1000research.74012.2>

## Abstract

Clinical presentation of liver hydatidosis can vary from asymptomatic forms to lethal complications. We report herein a rare case of a 27-year-old male from a rural Tunisian region who presented with large-abundance haematemeses, haemodynamic instability, and marked biological data of hypersplenism. Endoscopy showed bleeding esophageal varicose veins that were ligated. Abdominal ultrasound concluded the presence of three type CE2 hydatid liver cysts causing portal cavernoma with signs of portal hypertension. Despite resuscitation, the patient died of massive rebleeding leading to haemorrhagic shock. Hepatic hydatid cyst should be considered as an indirect cause of gastrointestinal bleeding in endemic countries. Early abdominal ultrasound in varicose haemorrhage is essential in orienting the diagnosis.



## Keywords

Case report, portal cavernoma, variceal bleeding, hydatidosis

## Open Peer Review

Reviewer Status  

	Invited Reviewers	
	1	2
<b>version 2</b> (revision) 25 Nov 2021	 report	
<b>version 1</b> 29 Oct 2021	 report	 report

1. **Souheil Zayet** , Nord Franche-Comté Hospital, Trévenans, France
2. **Khaoula Chabbouh** , University Tunis-El-Manar, Tunis, Tunisia

Any reports and responses or comments on the article can be found at the end of the article.

**Corresponding author:** Khalaf Ben Abdallah ([khalaf.benabdallah14@gmail.com](mailto:khalaf.benabdallah14@gmail.com))

**Author roles:** **Zouaghi A:** Supervision, Validation, Writing – Original Draft Preparation, Writing – Review & Editing; **Bellil N:** Validation; **Ben Abdallah K:** Writing – Original Draft Preparation, Writing – Review & Editing; **Hadded D:** Supervision, Validation; **Zaafouri H:** Validation; **Cherif M:** Validation; **Ben Maamer A:** Resources, Supervision, Validation

**Competing interests:** No competing interests were disclosed.

**Grant information:** The author(s) declared that no grants were involved in supporting this work.

**Copyright:** © 2021 Zouaghi A *et al.* This is an open access article distributed under the terms of the [Creative Commons Attribution License](#), which permits unrestricted use, distribution, and reproduction in any medium, provided the original work is properly cited.

**How to cite this article:** Zouaghi A, Bellil N, Ben Abdallah K *et al.* **Case Report: Portal cavernoma related to multiple liver hydatidosis: A rare case of fatal cataclysmic haemorrhage [version 2; peer review: 2 approved]** F1000Research 2021, 10:1097 <https://doi.org/10.12688/f1000research.74012.2>

**First published:** 29 Oct 2021, 10:1097 <https://doi.org/10.12688/f1000research.74012.1>

**REVISED Amendments from Version 1**

Changes consisted mainly in adding two more references in the introduction and discussion parts. Grammatical changes were also made in some parts. Additionally, the title and abstract were amended.

**Any further responses from the reviewers can be found at the end of the article**

**Introduction**

Echinococcosis liver hydatidosis is endemic in the Maghreb countries.<sup>1</sup> Vascular complications are exceedingly rare,<sup>2</sup> however, its manifestations can be critical. The clinical presentation depends on the cyst's segment localization. Compression or invasion of the hydatid cyst in the portal vein can lead to portal vein thrombosis or extrahepatic portal vein obstruction (EPVHO).<sup>3</sup> This can rarely lead to cavernous transformation and portal hypertension explaining the origin of symptoms. Prognosis is generally good. Cataclysmic presentations have not been described in the literature.

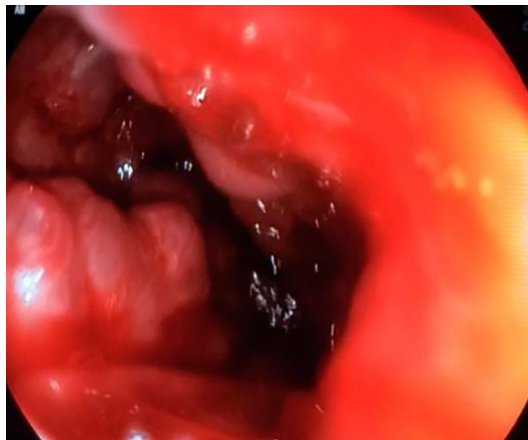
**Case presentation**

A 27-year-old male patient, from Mornag, a rural area of Tunisia, without any medical history, presented to the Habib Thameur Hospital emergency room with massive upper gastrointestinal bleeding. On admission (day one) in August 2020, physical examination revealed diffuse mucocutaneous pallor, lesions of old scarifications in the left upper limb, a Glasgow Coma Score (GCS) of 15/15, tachycardia of 105 beats per minute, hypotension of 80/50 mmHg without signs of peripheral hypoperfusion. Abdominal examination revealed slight epigastric tenderness and enlarged spleen without hepatomegaly or skin signs of hepatocellular failure. The rectal digital examination came back stained with melena.

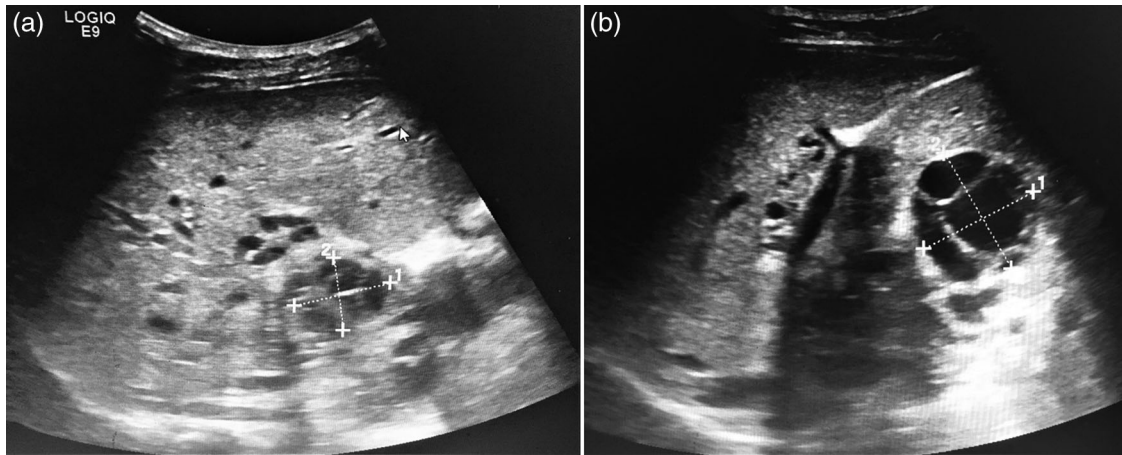
Laboratory investigation showed signs of hypersplenism including decreased count of white blood count of 2870 cells/mm<sup>3</sup>, thrombocytopenia of 46,000 cells/mm<sup>3</sup>, and normochromic normocytic anemia of 5.6 g/dL. Minor signs of hepatocellular insufficiency were also displayed including a low rate of prothrombin ratio of 60% and hypocholesterolemia of 2.87 mmol/L. He had neither cholestasis nor cytolysis. Albuminemia was normal at the value of 36 g/L. Acute kidney failure was noted (urea of 11.6 mmol/L) with a normal blood electrolytes. Anti-hepatitis C virus antibody, hepatitis B surface antigen and hepatitis B core antibody were all negative.

On day two, the patient was stabilized following fluid resuscitation and blood transfusion of two red blood cell concentrates. The patient was treated with a proton-pump inhibitor (omeprazole) and octreotide. Upper gastroduodenoscopy showed the presence of oesophageal varices with massive active bleeding, moderate hypertensive gastropathy and gastric varicose veins (Figure 1). Four elastics with a first kit of ligature were put in place but did not allow the control of bleeding. Five supplementary elastics in a second ligature kit allowed a reduction in bleeding but without total control of the haemorrhage.

An abdominal ultrasound (US) concluded the presence of multiple multiloculated cystic formations evoking hydatid cysts type CE2 of the WHO classification of segments I, IV, and V with the largest cyst measuring 40 mm (Figures 2a and 2b).



**Figure 1.** An upper gastroduodenoscopy demonstrating the presence of esophageal varices complicated by massive active bleeding, and gastric varicose veins.



**Figure 2. a and b: An abdominal ultrasound showing the presence of multiple multiloculated cystic formations evoking hydatid cysts type CE2 of the WHO classification of segments I, IV, and V.**

A portal cavernoma with a dilated splenic vein and splenomegaly of 22 cm was described. Hepatic veins were permeable with a normal caliber. Diagnosis of multiple liver hydatidosis was retained based on the epidemiological context and the typical aspect in abdominal US.

After a week, the patient had a cataclysmic re-bleeding causing refractory hemorrhagic shock and disseminated intravenous coagulation leading to death.

**Discussion**

Hepatic hydatid cyst can invade or compress the portal vein and results in EPVHO. Portal cavernoma is the outcome of chronic portal vein obstruction. It results in the creation of collateral circulation.

As soon as portal hypertension is established, blood can run hepatopetal or hepatofugal from the liver through portosystemic collaterals. This leads to the development of gastroesophageal or ectopic rectal variceal bleeding which represents the most typical clinical feature as in our case.<sup>5</sup> According to a prospective study by Noronha *et al.*, (2016), 71% of patients with chronic EPVHO showed gastroesophageal varices in endoscopy.<sup>5</sup>

EPVHO is an uncommon entity in adults. Indeed, the incidence of having EPVHO for the general population does not exceed 1% with a very low mortality rate.<sup>6</sup> Hepatic hydatid cyst can result in EPVHO whether by compressing or directly invading the portal vein.<sup>2,7</sup> Computerized tomography can help indicate the mechanism of thrombosis. Venous compressions are among the rarest complications of hydatid liver cysts even in endemic countries as shown in [Table 1](#). Size and perivascular topography are two essential elements for its occurrence ([tunisiechirurgicale.com](http://tunisiechirurgicale.com)).

From a pathophysiological point of view, EPVHO is the consequence of the ‘Virchow’s Triad’: the extrinsic chronic compression of the vascular wall by the hydatid cysts decreases the blood flow rate thus creating endothelial injuries. This can lead to the formation of a bland thrombus.<sup>11</sup>

To our knowledge, few cases of hepatic hydatidosis revealed by portal hypertension have been reported in the medical literature since the publication of the first case in 1990.<sup>8-10</sup> In a large Spanish cohort of 506 patients followed over 20 years, only two patients presented portal hypertension and variceal haemorrhage.<sup>12</sup> This demonstrates how seldomly described is this complication in the literature.

**Table 1. Incidence of vascular complications in liver hydatidosis in the literature.**

Series	Saleh <i>et al.</i> , <sup>8</sup>	Eddeghai <i>et al.</i> , <sup>9</sup>	Hafi <i>et al.</i> , <sup>10</sup>	Ben Ameer <i>et al.</i> , <a href="http://tunisiechirurgicale.com">[tunisiechirurgicale.com]</a>
Incidence	0.8 %	1 %	0.8%	1.8%

**Table 2.** Cases of hepatic hydatid cyst causing portal cavernoma.

Case	Age	Clinical presentation	Endoscopy	Mechanism of thrombosis	Prognosis	Treatment
<b>Ertan et al.,</b> <sup>14</sup>	77	Fever and generalized weakness	Not done	Direct communication with the portal vein	On follow-up	Albendazole
<b>Kirmizi et al.,</b> <sup>15</sup>	33	Abdominal distension after meals	Oesophageal and gastric fundal varices with no bleeding	Compression of the hepatic hilum	Preserved	Surgery
<b>Moisan et al.,</b> <sup>16</sup>	62	Abdominal pain Hepatomegaly	Grade I oesophageal varices	Invasion of the portal vein by daughter vesicles	Preserved	Albendazole + Propranolol
<b>Colovic et al.,</b> <sup>17</sup>	56	Right upper quadrant abdominal pain	Normal	Compression of the hepatoduodenal ligament	Preserved	Surgery
<b>Kayecetin et al.,</b> <sup>18</sup>	63	Fever, anorexia, jaundice and epigastric mass	Not done	Abdominal sepsis after the rupture of the liver cyst	Preserved	Surgery, Albendazole

Our case highlighted an unusual presentation. The portal vein thrombosis and the cavernous transformation remained undiagnosed until hematemesis due to varices rupture. Our young patient had no history of inflammatory bowel diseases, pancreatitis, cirrhosis, neoplastic condition or coagulopathy to explain the cavernoma. The only convincing cause was the compression of the hydatid cysts respectively in segments I, IV, and V of the portal vein leading to chronic thrombosis. The minor biological signs of hepatocellular insufficiency were probably secondary to the chronic evolution of the cavernoma, but the ultrasound did not show any signs of chronic hepatopathy. Ultrasound was an indispensable tool to orienting diagnosis as proved in the literature.<sup>13</sup> In this particular case, our patient's prognosis was poor, unlike previous ones.

We summarize in [Table 2](#) different cases of hepatic hydatid cyst causing portal cavernoma. The mean age was 58.2 years old. No signs of gastrointestinal bleeding were reported before diagnosis. Portal thromboses were mainly secondary to direct compression or invasion of the portal vein. The outcome was generally positive except in our case. Treatment was generally based on surgery and the drug albendazole.

Our case illustrates the importance of considering non-cirrhotic portal hypertension secondary to liver hydatidosis especially in young patients in endemic countries. Urgent therapy and diagnostic investigations should be pursued simultaneously to ensure on-time intervention. Our case lacks abdominal computed tomography or magnetic resonance imaging which could have given a more accurate demonstration of the thrombosis mechanism. Our patient could have been a candidate for transjugular intrahepatic portosystemic shunt.

## Conclusion

Liver hydatidosis remains a public health issue in Tunisia because of its high morbidity and, exceptionally, possible mortality. Our case highlights an unusual presentation due to the young age, symptomatic portal cavernoma, and fatal death of the patient. It shows the importance of considering hepatic hydatid cyst as a cause of portal hypertension and portal cavernoma on presentation of gastrointestinal bleeding. Early abdominal ultrasound has a valuable contribution to orienting diagnosis, especially in endemic low-middle income countries.

## Data availability

All data underlying the results are available as part of the article and no additional source data are required.

## Consent

Written informed consent for publication of their clinical details and clinical images was obtained from the patient's family.

## References

1. Sadjjadi SM: **Present situation of echinococcosis in the Middle East and Arabic North Africa.** *Parasitol Inter.* 2006; **55**: S197–S202.
2. Grosso G, Gruttadauria S, Biondi A, *et al.*: **Worldwide epidemiology of liver hydatidosis including the Mediterranean area.** *World J. Gastroenterol.* 2012; **18**: 1425–37. Baishideng Publishing Group Inc. [Publisher Full Text](#)
3. Macpherson CNL, Vuitton DA, Gharbi HA, *et al.*: **International classification of ultrasound images in cystic echinococcosis for application in clinical and field epidemiological settings.** *Acta Tropica.* Elsevier; 2003; p. 253–61
4. Herek D, Sungurtekin U: **Magnetic Resonance Imaging of a Liver Hydatid Cyst Invading the Portal Vein and Causing Portal Cavernomatosis.** *Ochsner J.* 2015; **15**(4): 479–80. [Free Full Text](#) | [PubMed Abstract](#)
5. Noronha Ferreira C, Seijo S, Plessier A, *et al.*: **Natural history and management of esophagogastric varices in chronic noncirrhotic, nontumoral portal vein thrombosis.** *Hepatology.* 2016 May 1 [cited 2021 Jan 17]; **63**(5): 1640–50. [PubMed Abstract](#) | [Publisher Full Text](#)
6. Ageno W, Dentali F, Pomero F, *et al.*: **Incidence rates and case fatality rates of portal vein thrombosis and Budd-Chiari syndrome.** *Thromb. Haemost.* 2017 Apr 3 [cited 2021 Jan 17]; **117**(4): 794–800. [PubMed Abstract](#) | [Publisher Full Text](#)
7. Greco S, Cannella R, Giambelluca D, *et al.*: **Complications of hepatic echinococcosis: multimodality imaging approach.** *Insights Imaging.* Springer; 2019; Vol. **10**: p. 1–12
8. Salah JM, Habib BHKM, Radhouane T, *et al.*: **Sténose digestive haute due à un kyste hydatique du foie.** *La tunisie medicale.* 2015; **93**(3): 129–130.
9. Eddeghai S, Eddoukani I, Diffaa A, *et al.*: **Kyste hydatique du foie: À propos d'un mode de révélation exceptionnel.** *Pan Afr. Med. J.* 2014 [cited 2021 Jan 17]; **18**: 1937–8688. [Publisher Full Text](#)
10. Hafi Z: **Les complications vasculaires du kyste hydatique du foie à propos de 10 cas.** Thèse, faculté de médecine de Tunis. 1996.
11. Samant H, Asafo-Agyei KO, Karen G, *et al.*: **Portal vein thrombosis.** *StatPearls [Internet].* 2021.
12. Papadimitriou J, Kannas D, Papadimitriou L: **Portal hypertension due to hydatid disease of the liver.** *J. R. Soc. Med.* 1990; **83**: 120–121. [Publisher Full Text](#)
13. Botezatu C, Mastalier B, Patrascu T: **Hepatic hydatid cyst - diagnose and treatment algorithm.** *J Med Life.* 2018 Jul 1 [cited 2021 Jan 17]; **11**(3): 203–9. [PubMed Abstract](#) | [Publisher Full Text](#) | [Free Full Text](#)
14. Ertan G, Ulus S, Kilicarslan R, *et al.*: **Hydatid disease of the liver with portal vein invasion mimicking portal vein thrombosis.** *Arab J Gastroenterol.* 2019; **20**(1): 50–2. [PubMed Abstract](#) | [Publisher Full Text](#)
15. Kirmizi S, Kayaalp C, Yilmaz S: **Hydatid liver cyst causing portal vein thrombosis and cavernous transformation: A case report and literature review.** *Gastroenterol Hepatol from Bed to Bench.* 2016 Sep 1 [cited 2021 Jan 17]; **9**(4): 331–4. [PubMed Abstract](#) | [Free Full Text](#)
16. Moisan FR, Galindo JL, Jarufe NP: **An unusual cause of portal cavernomatosis IMAGES IN HEPATOLOGY CASE REPORT.** 2012; Vol. **11**.
17. Colovic RB, Grubor NM, Colic MU, *et al.*: **Portal cavernoma caused by a calcified hydatid cyst of the liver (case report).** *Eur. J. Gastroenterol. Hepatol.* 2008 Mar [cited 2021 Jan 17]; **20**(3): 237–9. [PubMed Abstract](#) | [Publisher Full Text](#)
18. Kayacetin E, Hidayetoglu T: **Hydatid cyst of the liver causing a cavernous transformation in the portal vein and complicated by intrabiliary and intraperitoneal rupture.** *J. Gastroenterol. Hepatol.* 2004 Oct 1 [cited 2021 Jan 17]; **19**(10): 1223–4. [Publisher Full Text](#) | [PubMed Abstract](#)

# Open Peer Review

Current Peer Review Status:  

---

## Version 2

Reviewer Report 26 November 2021

<https://doi.org/10.5256/f1000research.79569.r101158>

© 2021 Zayet S. This is an open access peer review report distributed under the terms of the [Creative Commons Attribution License](#), which permits unrestricted use, distribution, and reproduction in any medium, provided the original work is properly cited.



**Souheil Zayet** 

Infectious Disease Department, Nord Franche-Comté Hospital, Trévenans, France

The authors responded to all reviewer's comments.

**Competing Interests:** No competing interests were disclosed.

**Reviewer Expertise:** Specialist in Infectious Diseases

**I confirm that I have read this submission and believe that I have an appropriate level of expertise to confirm that it is of an acceptable scientific standard.**

---

## Version 1

Reviewer Report 16 November 2021

<https://doi.org/10.5256/f1000research.77717.r98517>

© 2021 Chabbouh K. This is an open access peer review report distributed under the terms of the [Creative Commons Attribution License](#), which permits unrestricted use, distribution, and reproduction in any medium, provided the original work is properly cited.



**Khaoula Chabbouh** 

Gastroenterology B department, Faculty of Medicine, La Rabta Hospital, University Tunis-El-Manar, Tunis, Tunisia

This is an interesting case as it illustrates a rare complication of Echinococcosis liver hydatidosis which is still endemic in the Maghreb countries.

However, some remarks should be mentioned:

1. The diagnosis was based on abdominal ultrasound findings only. Authors did not perform abdominal computed tomography or magnetic resonance imaging.
2. Given the young age of the patient, a thrombophilia assessment could have been requested.

**Is the background of the case's history and progression described in sufficient detail?**

Yes

**Are enough details provided of any physical examination and diagnostic tests, treatment given and outcomes?**

Yes

**Is sufficient discussion included of the importance of the findings and their relevance to future understanding of disease processes, diagnosis or treatment?**

Yes

**Is the case presented with sufficient detail to be useful for other practitioners?**

Yes

**Competing Interests:** No competing interests were disclosed.

**Reviewer Expertise:** Gastro-enterology

**I confirm that I have read this submission and believe that I have an appropriate level of expertise to confirm that it is of an acceptable scientific standard.**

Reviewer Report 03 November 2021

<https://doi.org/10.5256/f1000research.77717.r98522>

© 2021 Zayet S. This is an open access peer review report distributed under the terms of the [Creative Commons Attribution License](#), which permits unrestricted use, distribution, and reproduction in any medium, provided the original work is properly cited.



**Souheil Zayet** 

Infectious Disease Department, Nord Franche-Comté Hospital, Trévenans, France

**This submission is an observation of a patient with a rare presentation of portal cavernoma related to multiple liver hydatidosis.**

This original document is well treated in its entirety and is of academic and scientific interest, although limited due to the incidence of the disease, but both necessary and useful to understand the infectious mechanisms and the care options. Personally, I find very enriching the approach of the authors and the way they described this case, associated with quality references.



I believe the content is substantially acceptable. However as the article is intended for surgery/infectious diseases specialists and needed some minor revisions:

In the title:

**'Portal cavernoma related to multiple liver hydatidosis: A rare case of fatal cataclysmic haemorrhage'** is more appropriate.

In the Abstract:

Correct 'We report herein a rare case of a 27-year-old Tunisian male a rural region'.  
'Biological data' instead signs.

In the Introduction:

Add a reference with the Echinococcosis liver hydatidosis' prevalence in the Maghreb countries. Please check the English of this sentence 'Prognosis is generally good'. Please avoid jargon and relaxed language.

In the Observation:

You can define gastrointestinal as 'GI' and used it in the whole text.  
Please precise the native region 'rural area' of patient to emphasize epidemiological link.  
Delete the name of your affiliation or institution in the text.  
Correct beats per minute; avoid abbreviations.  
Use 'enlarged spleen' instead splenomegaly.  
Define all normal ranges in laboratory investigations in the text.  
Replaced normal ionogram with 'normal electrolytes'.  
What is 'Viral hepatitis screening'; it means serology; if yes, precise all serology and rt-PCR included.  
He was put on a proton-pump inhibitor?? Please changed it (the patient was treated or a treatment was started/began).  
To retain the diagnosis, hydatidosis serology (or other microbiological testing) was done ? If not, precise it and discuss this point in the discussion part).

In the Discussion:

Replace symptomatic presentation with 'clinical feature'.  
Replace 'offer' with highlighted.  
Deleted CT as abbreviation, used once in the text.  
Please add a reference when you explain pathophysiology of EPVHO.  
Please check this sentence 'The outcome was generally positive in all cases unlike ours'.  
Surgery technique was not detailed; (you can do it in 1-2 sentences.

In the conclusion:

Avoid unfortunate; change it (lethal or fatal form).  
Add 'in endemic low-middle income countries'.

**Is the background of the case's history and progression described in sufficient detail?**

Yes

**Are enough details provided of any physical examination and diagnostic tests, treatment given and outcomes?**

Yes

**Is sufficient discussion included of the importance of the findings and their relevance to future understanding of disease processes, diagnosis or treatment?**

Partly

**Is the case presented with sufficient detail to be useful for other practitioners?**

Yes

**Competing Interests:** No competing interests were disclosed.

**Reviewer Expertise:** Specialist in Infectious Diseases

**I confirm that I have read this submission and believe that I have an appropriate level of expertise to confirm that it is of an acceptable scientific standard, however I have significant reservations, as outlined above.**

---

The benefits of publishing with F1000Research:

- Your article is published within days, with no editorial bias
- You can publish traditional articles, null/negative results, case reports, data notes and more
- The peer review process is transparent and collaborative
- Your article is indexed in PubMed after passing peer review
- Dedicated customer support at every stage

For pre-submission enquiries, contact [research@f1000.com](mailto:research@f1000.com)

**F1000Research**