

LETTER

Bullous pemphigoid triggered by COVID-19 vaccine: Rapid resolution with corticosteroid therapy

Dear Editor,

Bullous pemphigoid (BP) is an acquired autoimmune blistering disease characterized by autoantibodies against basement membrane zone antigens. Several trigger factors have been identified for this disorder, such drugs, ultraviolet radiation, trauma and burns. Pemphigoid cases have been reported in association with vaccination, including rabies,¹ influenza, pneumococcus, tetanus, diphtheria,² pertussis, poliomyelitis, *Haemophilus influenzae* B, hepatitis B and Meningococcus C³ vaccine, indicating that vaccination can trigger pemphigoid.

We report here a case of a 83-year-old man with a 30 days history of multiple erythemas and blisters with itching. The patient has been affected with hypertension for 20 years, for which he was in treatment with perindopril 10 mg DIE and amlodipine 5 mg DIE. He was otherwise in quite good health with no other significant medical conditions. His family history was negative for significant diseases and skin disorders. The patient developed the first bullous lesions 1 week after the first dose of Comirnaty (Pfizer-BioNTech COVID-19 vaccine). Blisters were few and located only on his legs and they were initially

misdiagnosed as post-traumatic lesions by his general practitioner. Three days after the second dose of vaccine, which was administered 1 month after the first, the patient started developing new blisters on his limbs and trunk. When he was eventually admitted to our department he presented several erosions and tense bullae on erythematous base measuring 4–11 cm in diameter on trunk and limbs (Figure 1A). Nikolsky sign was absent and the remainder of the physical examination was normal. Blood exams were carried out, including routine clinical chemistry, neoplastic markers, viral hepatitis markers, autoimmunity panel and quantiferon test. All were within normal limits. Tzank test performed from a fresh bulla showed eosinophils. Histopathology from a bullous lesion demonstrated subepidermal blister with occasional lymphocytes and eosinophils. Direct immunofluorescence revealed a linear band of C3 along the basement membrane. A diagnosis of bullous pemphigoid was made and the patient treated with topical steroids and prednisone 30 mg daily (0.5 mg/kg daily⁴) for 4 weeks, then reduced by 5 mg every week, then stop. A complete resolution of the blisters was obtained after only 3 weeks of treatment (Figure 1B).

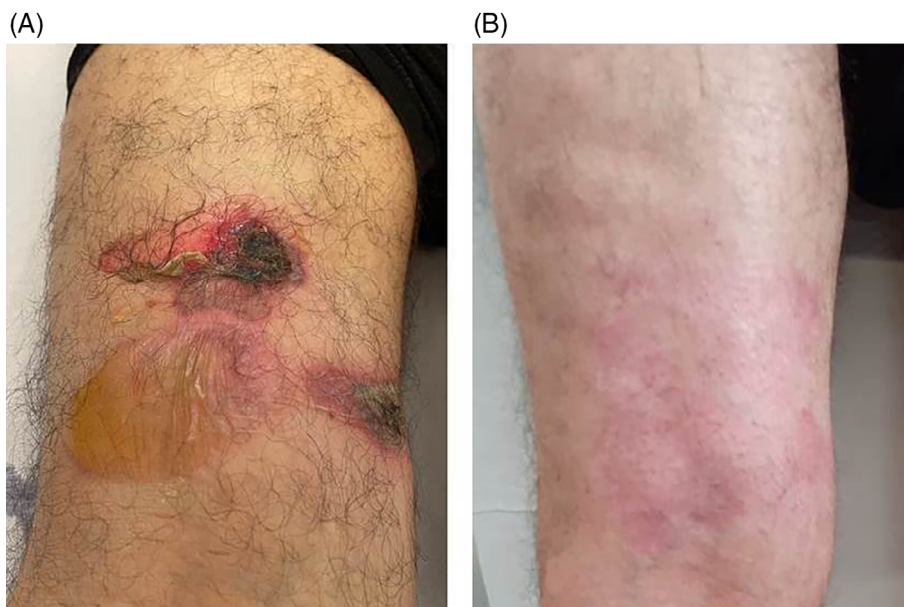

FIGURE 1 Erosions and blisters on the left leg (A); complete resolution after 3 weeks of treatment (B)

All authors state that the manuscript is original, it has not been published before and it is not currently being considered for publication elsewhere.

This is an open access article under the terms of the Creative Commons Attribution License, which permits use, distribution and reproduction in any medium, provided the original work is properly cited.

© 2021 The Authors. *Dermatologic Therapy* published by Wiley Periodicals LLC.

Herein we describe a case of BP triggered by Comirnaty (Pfizer–BioNTech COVID-19 vaccine). The temporal association between administration of vaccine and appearance of bullous lesion was a pointer that vaccine might be the trigger while reemergence of bullae following the second dose of vaccine confirmed the association. Naranjo algorithm was 9 (definite adverse drug reaction).

Owing to the ongoing COVID-19 pandemic a mass vaccination campaign has been initiated worldwide. Different types of vaccines are available nowadays.⁵ The adverse reactions occurring with messenger RNA (mRNA) COVID-19 vaccines mostly appear within the first 30 min after the vaccination and can likely be interpreted as immunoglobulin E-mediated hypersensitivity.^{6,7} The reported delayed cutaneous adverse events, other than injection site inflammation, are rare. Since a growing percentage of the population becomes vaccinated, delayed cutaneous reactions are likely destined to increase. To date few cases of delayed cutaneous reactions are reported. Among these, delayed urticaria⁷ and erythema multiforme like eruption, eczematous eruptions, generalized pruritic morbilliform and pityriasis rosea-like eruptions, urticarial vasculitis, leukocytoclastic vasculitis^{8,9} and psoriasis exacerbation.¹⁰ Also few cases of BP are reported.^{9,11}

The appearance of blisters after the first administration of Comirnaty should not be underestimated and carefully considered as an early sign of BP. However, given the risks of SARS-CoV-2 infection and the rarity of these events, clinicians should encourage full vaccination.

In our experience, BP triggered by Comirnaty can be easily managed with corticosteroid therapy with a rapid resolution achievable in only 3 weeks.

ACKNOWLEDGEMENT

Open Access Funding provided by Università degli Studi di Cagliari within the CRUI-CARE Agreement. [Correction added on May 23, 2022, after first online publication: CRUI funding statement has been added.]

AUTHOR CONTRIBUTIONS

All authors contributed equally to the manuscript preparation and revised the final version.

ETHICS STATEMENT

The patient gave consent for publication of this manuscript.

DATA AVAILABILITY STATEMENT


The data that support the findings of this study are available from the corresponding author upon reasonable request.

Massimo Dell'Antonia 

Speranza Anedda

Federica Usai

Laura Atzori 

Caterina Ferrelli 

Correspondence

Massimo Dell'Antonia, Dermatology Clinic, Department of Medical Sciences and Public Health, University of Cagliari, Via Ospedale 54, 09124, Cagliari, Italy.

Email: massimodellantonia@gmail.com

ORCID

Massimo Dell'Antonia  <https://orcid.org/0000-0003-0250-5750>

Laura Atzori  <https://orcid.org/0000-0002-8105-1402>

Caterina Ferrelli  <https://orcid.org/0000-0002-8223-6791>

REFERENCES

- Jindal A, Nayak SUK, Shenoi SD, Rao R, Monappa V. Bullous pemphigoid triggered by rabies vaccine. *Indian J Dermatol Venereol Leprol.* 2020 Jan-Feb;86(1):66-68. doi:10.4103/ijdv.IJDVL_666_18
- Maki N, Hashimoto T, Yamada T, Ishii N, Tsuruta D, Demitsu T. Case of pemphigoid with immunoglobulin G antibodies to BP180 C-terminal domain and laminin- γ 1 (p200) developed after pneumococcal vaccination. *J Dermatol.* 2021;48(1):101-105. doi:10.1111/1346-8138.15626
- Baroero L, Coppo P, Bertolino L, Maccario S, Savino F. Three case reports of post immunization and post viral bullous pemphigoid: looking for the right trigger. *BMC Pediatr.* 2017;17(1):60. doi:10.23736/S0392-0488.18.06006-6
- Cozzani E, Marzano AV, Caproni M, Feliciani C, Calzavara-Pinton P. Bullous pemphigoid: Italian guidelines adapted from the EDF/EADV guidelines. *G Ital Dermatol Venereol.* 2018;153(3):305-315. doi:10.23736/S0392-0488.18.06006-6
- Chung JY, Thone MN, Kwon YJ. COVID-19 vaccines: the status and perspectives in delivery points of view. *Adv Drug Deliv Rev.* 2021;170:1-25. doi:10.1016/j.addr.2020.12.011
- Shimabukuro T, Nair N. Allergic reactions including anaphylaxis after receipt of the first dose of Pfizer-BioNTech COVID-19 vaccine. *JAMA.* 2021;325(8):780-781. doi:10.1001/jama.2021.0600
- Patrino C, Napolitano M, Stingeni L, Fabbrocini G. Skin rashes after SARS-CoV-2 vaccine: which relationship, if any? *Immun Inflamm Dis.* 2021;9(3):622-623. doi:10.1002/iid3.428
- Stingeni L, Bianchi L, Zalaudek I, et al. Board members of SIDeMaST. Adverse cutaneous and mucous reactions from anti SARS-CoV-2 vaccines: recommendations from the Italian Society of Dermatology (SIDeMaST). *Ital J Dermatol Venereol.* 2021;156(2):115-117. doi:10.23736/S2784-8671.21.06992-3
- Larson V, Seidenberg R, Caplan A, Brinster NK, Meehan SA, Kim RH. Clinical and histopathological spectrum of delayed adverse cutaneous reactions following COVID-19 vaccination. *J Cutan Pathol.* 2021. doi:10.1111/cup.14104
- Megna M, Potestio L, Gallo L, et al. Reply to "psoriasis exacerbation after COVID-19 vaccination: report of 14 cases from a single Centre" by Sotiriou E. *J Eur Acad Dermatol Venereol.* 2021. doi:10.1111/jdv.17665
- Tomayko MM, Damsky W, Fathy R, et al. Subepidermal blistering eruptions, including bullous pemphigoid, following COVID-19 vaccination. *J Allergy Clin Immunol.* 2021;148(3):750-751. doi:10.1016/j.jaci.2021.06.026