

# Reactive infectious mucocutaneous eruption in children diagnosed with COVID-19

## Abstract

We describe the cases of two immunocompetent children who developed mucositis with oral, ocular, and genital involvement during acute COVID-19 illness. The pattern of mucosal involvement with no other cutaneous involvement was consistent with reactive infectious mucocutaneous eruption (RIME). No other intercurrent infections or new medications were identified, suggesting that COVID-19 was causative. Both patients noted improvement with systemic corticosteroid therapy.

## 1 | CASE REPORT

Patient 1, a 17-year-old boy, presented six days following a positive SARS-CoV-2 PCR test, and eight days following onset of systemic symptoms including fever and cough. He had a two-day history of conjunctivitis and ulceration of his oral mucosa (Figure 1A), erythematous circumferential erosions of the glans penis (Figure 1B) with no other cutaneous findings. Blood tests showed an elevated c-reactive protein (CRP) of 95.7 mg/L (normal range 0-5) and normal complete blood count (CBC).

Patient 2, a 14-year-old boy, presented to the hospital seven days following a positive SARS-CoV-2 PCR test, and nine days after onset of fever and cough. He had a five-day history of ulceration of the oral mucosa (Figure 2) with mild conjunctivitis. Ulceration of the glans penis developed on day two of admission. Blood tests showed an elevated CRP of 63 mg/L (normal range 0-5) and normal CBC.

The remainder of the mucocutaneous, lymphoreticular, cardiovascular, and respiratory examination was unremarkable in both patients. Neither patient had taken any medications prior to development of the eruption. HSV 1/2 PCR viral swabs, *Mycoplasma pneumoniae* IgM, CMV IgM, EBV IgM, hepatitis B surface antigen, hepatitis C antibody, HIV antibody, syphilis total antibody, and blood cultures were negative, and antistreptolysin O titer was <200 U/mL for both patients. Chest X-ray was normal in both patients.

Following dermatology consultation, both patients were diagnosed with SARS-CoV-2-associated reactive infectious mucocutaneous eruption (RIME).

Both patients were treated with intravenous hydrocortisone (100 mg three times daily for three days), betamethasone valerate 0.1% ointment once daily, hydrocortisone 2.5 mg buccal tablets four times daily, analgesia with paracetamol and ibuprofen, and intravenous hydration. Patient 1 was treated with prednisolone 1% eye drops and was discharged after four days. Due to the severity of Patient 2's oral ulceration, he was given lidocaine hydrochloride mouthwash and received total parenteral nutrition for five days. Patient 2 was discharged after 14 days once he was able to resume oral intake.

Both patients discontinued treatment at discharge and had complete resolution of mucositis one week after discharge.

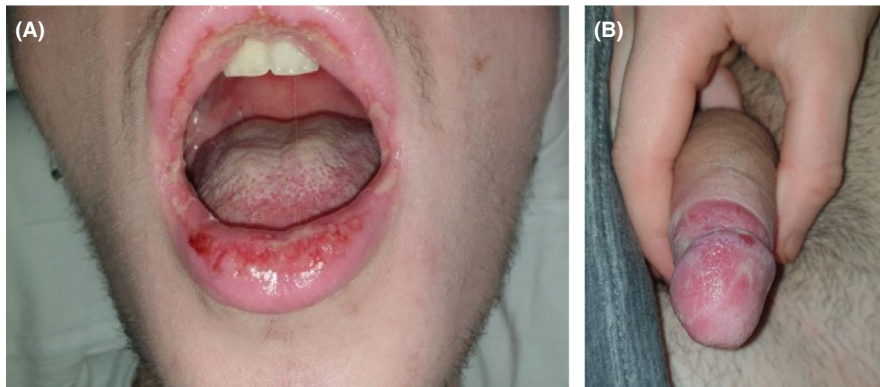## 2 | DISCUSSION

Dermatologic manifestations of COVID-19 have been divided into seven clinical patterns: morbilliform, pernio-like, urticarial, macular erythema, vesicular, papulosquamous, and retiform purpura.<sup>1</sup> The term RIME describes the clinical presentation of significant mucositis (oral, ocular, and anogenital) but absent to sparse cutaneous involvement, typically occurring as a late manifestation of exposure to *Mycoplasma* and other infectious agents such as *Chlamydia pneumoniae*, metapneumovirus, parainfluenza virus 2, rhinovirus, and enterovirus. The link between RIME and SARS-CoV-2 has not been widely reported, with two cases in adults,<sup>2,3</sup> and one report in a 17-year-old boy.<sup>4</sup> EM has been reported in children with COVID-19, but most cases describe targetoid cutaneous lesions without mucositis.<sup>5</sup>

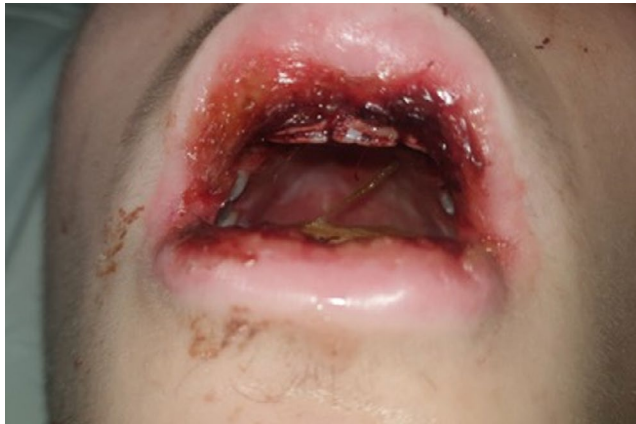The combination of recent PCR-confirmed SARS-CoV-2 infection, absence of other contemporaneous laboratory-confirmed infections, and prominent mucositis suggests SARS-CoV-2 as an infectious trigger for both patients' RIME. Clinicians should be aware that SARS-CoV-2 can precipitate RIME and that systemic corticosteroids may provide benefit.

This is an open access article under the terms of the Creative Commons Attribution-NonCommercial License, which permits use, distribution and reproduction in any medium, provided the original work is properly cited and is not used for commercial purposes.

© 2021 The Authors. *Pediatric Dermatology* published by Wiley Periodicals LLC.




**FIGURE 1** (A) Patient 1 with shallow erosions on the vermilion lips and hard palate and surrounding erythema. (B) Periurethral erythema and shallow erosions on the area glans penis and distal shaft



**FIGURE 2** Hemorrhagic crusting and extensive erosions involving the lips and hard palate in patient 2

#### KEYWORDS

COVID-19, mucosal erythema multiforme, viral eruptions

Stephanie Bowe MD<sup>1</sup>  
 Cathal O'Connor MD<sup>1,2</sup>   
 Catherine Gleeson MD<sup>1</sup>  
 Michelle Murphy MD<sup>1,2</sup>

<sup>1</sup>Department of Dermatology, South Infirmary Victoria University Hospital, Cork, Ireland

<sup>2</sup>University College Cork, Cork, Ireland

#### Correspondence

Cathal O'Connor, Department of Dermatology, University College Cork, Cork, Ireland.

Email: drcathaloconnor@gmail.com

#### ORCID

Cathal O'Connor  <https://orcid.org/0000-0001-7084-5293>

#### REFERENCES

1. Freeman EE, McMahon DE, Lipoff JB, et al. The spectrum of COVID-19-associated dermatologic manifestations: an international registry of 716 patients from 31 countries. *J Am Acad Dermatol.* 2020;83(4):1118-1129.
2. Binois R, Colin M, Rzepecki V, Prazuck T, Esteve E, Hocqueloux L. A case of erythema multiforme major with multiple mucosal involvements in COVID-19 infection. *Int J Dermatol.* 2021;60(1):117-118.
3. Fathi Y, Hoseini EG, Mottaghi R. Erythema multiform-like lesions in a patient infected with SARS-CoV-2: a case report. *Future Virology.* 2021;16(3):157-160. <https://doi.org/10.2217/fvl-2020-0333>
4. Holcomb ZE, Hussain S, Huang JT, Delano S. Reactive infectious mucocutaneous eruption associated with SARS-CoV-2 infection. *JAMA Dermatol.* 2021;157(5):603-605. <https://doi.org/10.1001/jamadermatol.2021.0385>
5. Andina D, Belloni-Fortina A, Bodemer C, et al. Skin manifestations of COVID-19 in children: part 2. *Clin Exp Dermatol.* 2021;46(3):451-461.